This dissertation has been 61-2937
microfilmed exactly as received

PEISSNER, Lorraine Cecelia, 1919-
COMPARATIVE STUDIES OF THE
HISTOLOGY AND PHYSIOLOGY OF
SALIVARY GLANDS IN SOME SPECIES
OF RODENTS.

The University of Oklahoma, Ph.D., 1961
Physiology

University Microfilms, Inc., Ann Arbor, Michigan

Downloaded from SHAREOK. Persistent Handle URL: https://hdl.handle.net/11244/1509

THE UNIVERSITY OF OKLAHOMA

GRADUATE COLLEGE

COMPARATIVE STUDIES OF THE HISTOLOGY AND PHYSIOLOGY OF SALIVARY GLANDS IN SOME SPECIES OF RODENTS

A DISSERTATION

SUBMITTED TO THE GRADUATE FACULTY

in partial fulfillment of the requirements for the

degree of

DOCTOR OF PHILOSOPHY

By

Lorraine Cecelia Peissner

Norman, Oklahoma

1961

COMPARATIVE STUDIES OF THE HISTOLOGY AND PHYSIOLOGY OF SALIVARY GLANDS IN SOME SPECIES OF RODENTS

APPROVED BY

Harriet Harvey

Cluff E. Hopla

Simon H. Wender

Leon S. Cieserko

Richard C. Goff

Jerome Selph

DISSERTATION COMMITTEE

ACKNOWLEDGEMENTS

The author wishes to express her appreciation to Dr. Harriet Harvey, Major Professor, for her assistance and direction of the research, and criticism of the manuscript; to personnel of the Zoology Department for supplying animals for the research project, and to the Department of Zoology for providing space and equipment.

Field animals were trapped and in most instances identified by Douglas R. Fickess to whom grateful recognition is due.

The writer is profoundly grateful to generous friends, more numerous than can properly be mentioned in this space, for information, advice, and guidance.

TABLE OF CONTENTS

	Page
LIST OF TABLES	v
LIST OF ILLUSTRATIONS	vi
CHAPTER	
I. INTRODUCTION	1
II. HISTOLOGIC STUDIES	3
Materials and Methods	3
Results	4
Discussion	18
III. ENZYMATIC STUDIES	25
Materials and Methods	25
Results	30
Discussion	48
IV. SUMMARY AND CONCLUSIONS	60
LITERATURE CITED	65

LIST OF TABLES

Table		Page
1.	Micrograms of Glucose per 100 Milligrams of Wet Tissue: Guinea Pigs (Submaxillary Gland and Parotid Gland)	32
2.	Micrograms of Glucose per 100 Milligrams of Wet Tissue: Guinea Pigs (Pancreas and Intestine)	33
3.	Micrograms of Glucose per 100 Milligrams of Wet Tissue: Laboratory Rats (Submaxillary Gland and Parotid Gland)	36
4.	Micrograms of Glucose per 100 Milligrams of Wet Tissue: Laboratory Rats (Pancreas and Intestine)	37
5.	Micrograms of Glucose per 100 Milligrams of Wet Tissue: Female Laboratory Mice (Submaxillary Gland and Parotid Gland)	39
6.	Micrograms of Glucose per 100 Milligrams of Wet Tissue: Female Laboratory Mice (Pancreas and Intestine)	40
7.	Micrograms of Glucose per 100 Milligrams of Wet Tissue: Male Laboratory Mice (Submaxillary Gland and Parotid Gland)	43
8.	Micrograms of Glucose per 100 Milligrams of Wet Tissue: Male Laboratory Mice (Pancreas and Intestine)	44
9.	Influence of HCl on Glycosidase Activity in Female Guinea Pig Tissue	49

LIST OF ILLUSTRATIONS

Enzymatic Studies

Figure		Page
1.	Glycosidase Activity per 100 Milligrams of Guinea Pig Tissue.....	34
2.	Glycosidase Activity per 100 Milligrams of Rat Tissue.....	38
3a.	Glycosidase Activity per 100 Milligrams of Laboratory Mouse Tissue (Females).....	41
3b.	Glycosidase Activity per 100 Milligrams of Laboratory Mouse Tissue (Males).....	45

Histologic Studies

Plate		
I.	Submaxillary Gland of Laboratory Mouse.....	67
II.	Submaxillary Gland of Woodchuck.....	68
III.	Submaxillary Gland of Fox Squirrel.....	69
IV.	Submaxillary Gland of Pocket Gopher and of Pocket Mouse.....	70
V.	Submaxillary Gland of Beaver.....	71
VI.	Submaxillary Gland of Brush Mouse.....	72
VII.	Submaxillary Gland of Grasshopper Mouse.....	73
VIII.	Submaxillary Gland of Cotton Rat.....	74
IX.	Submaxillary Gland of Pack Rat.....	75
X.	Submaxillary Gland of Muskrat.....	76
XI.	Submaxillary Gland of Guinea Pig.....	77

COMPARATIVE STUDIES OF THE HISTOLOGY AND PHYSIOLOGY OF SALIVARY GLANDS IN SOME SPECIES OF RODENTS

CHAPTER I

INTRODUCTION

The investigations reported in this dissertation fall into three major related aspects. Firstly, a comparative histological study of the salivary glands of certain members of the Order Rodentia was initiated. This phase of study was prompted by reports (Bensley, 1908; Honda, 1927; Harvey, unpublished data) of differences in gross anatomy, and, more strikingly, in microscopic anatomy of the submaxillary gland of various mammals.

Secondly, an attempt was made to determine whether salivary gland sex dimorphism was characteristic of rodents in general. A sex difference in laboratory rat and mouse submaxillary gland structure has been reported (Lacassagne, 1940a,c; Fekete, 1941). This dimorphism manifests itself both morphologically and physiologically in the following major dimorphic qualities: (1) tubule diameter, (2) terminal tubule cell granulation, and (3) the dependence of gross weight upon male hormone (Lacassagne, 1940a,b; Feyel-Cabanes, 1947; Frantz and Kirschbaum, 1949a) in both the maturing and the adult

gland (Harvey, 1952). Female hormone has been shown to influence the submaxillary gland weight, tubule cell granulation, and more especially, the structure and size of the acinar cells (Harvey, 1952).

Thirdly, interest in the potential physiological differences suggested by such dimorphism, led the author to conduct studies of the presence and activity of glycosidase in salivary glands of both sexes of laboratory rodents. Raynaud and Rebeyrotte (1949) observed that saliva from male mice possessed greater ability to release glucose from starch than did saliva from female mice. Likewise, castration of male mice decreased this enzymatic activity while administration of testosterone to females enhanced it. Amylolytic activity of salivary tissue and effects of gonadal hormones on this activity were investigated by Harvey (1957a, b). Results of these studies confirmed the findings of Raynaud and Rebeyrotte.

In light of the reported differences in amylolytic activity of salivary glands and salivary gland secretions, it became of interest to determine whether other glycosidases, namely, lactase, maltase, and sucrase, were present in salivary tissue of some species of laboratory animals and, if so, to what degree their activity might be affected by shifts in gonadal hormone levels.

CHAPTER II

HISTOLOGIC STUDIES

Materials and Methods

Salivary glands used in this study were from (1) mice and guinea pigs reared in our laboratory under conditions of standard diet fed ad libitum; and (2) other rodents trapped or shot in their natural environment without knowledge of time, quality, or quantity of their most recent feeding.

Tissues from animals sacrificed in the laboratory were immediately excised and placed in fixative solution. When it was not feasible to bring live specimens into the laboratory, glands were collected in the field not longer than twenty minutes after the death of the animal, placed in fixative, and brought to the laboratory for further processing. All tissues were fixed in modified Zenker-formol (Bensley) solution, sectioned at eight microns, and stained with Mallory's Triple Connective Tissue (MTCT) stain or periodic-acid-Schiff (PAS) reagent.

According to classification of Order Rodentia by Hall and Kelson (1959), the 55 animals included in this phase of study represented the following three sub-orders and six families:

Sub-Order Sciuromorpha: Family Sciuridae (squirrels)
Geomyidae (pocket gophers)
Heteromyidae (pouched mice)
Castoridae (beavers)

Sub-Order Myomorpha: Family Cricetidae (native rats and mice)
Muridae (true rats and mice)

Sub-Order Hystricomorpha: Family Cavidae (guinea pigs)

Results

Histologic details of the microscopic appearance of salivary glands from twelve species of rodents are presented in this paper. The submaxillary, sublingual, and parotid glands of normal adult male and female laboratory mice are used as prototypes or models to which glands of other species will be compared and, therefore, their histological descriptions will be considered first rather than in proper taxonomic position with other species of Order Rodentia.

Sub-Order: Myomorpha --- Family Muridae

Laboratory mouse (Mus musculus)

Submaxillary gland

The submaxillary gland is a compound, branched, tubuloacinous gland divided by connective tissue septa into several ovoid lobes and lobules.

Duct system:--A large excretory duct, which leads to the oral cavity, serves as the excurrent opening for all lobes. The main stem and principal branches are lined by

pseudostratratified columnar epithelium and as they branch into smaller interlobular ducts, the epithelial lining becomes a simple columnar tissue. This excretory portion of the gland further branches into the ultimate lobules as intralobular ducts (sometimes referred to as secretory ducts or striated tubules) lined by a single layer of columnar epithelial cells with a finely granular cytoplasm containing characteristic basal striations, which are believed to be parallel rows of mitochondria. Large spherical nuclei occupy a central or subcentral position. The intralobular ducts divide into terminal tubules, as shown in the diagram below, which are the sex-dimorphic components of the gland.

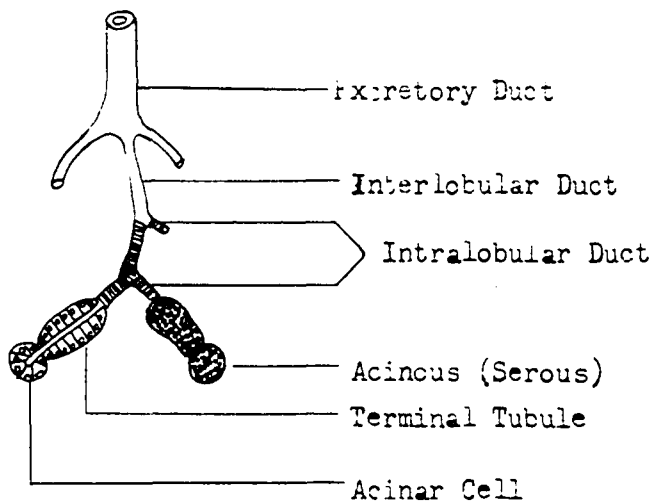

Diagram of the Submaxillary Gland of the Laboratory Mouse.

Terminal tubules:--The major sex dimorphism in the submaxillary of adult male and female mice is expressed by differences in cell height and quantity of large highly refractive granules within each cell, both of which are greater

in male than in female glands (Pl. 1, Figs. 1 and 2). In addition, there is a notable difference between terminal tubules in peripheral areas and those in central areas of the lobules in some adult male glands and in all female glands. When sections of male submaxillary gland are stained by MCTC stain, cells of central terminal tubules have subcentral nuclei, basal striations, numerous small dark granules, some larger unstained chromophobic granules, and occasionally a few large coarse red-orange granules. Cytoplasm of the peripheral cells, on the other hand, is generally so densely packed with the red-orange granules that basal nuclei are distorted or obscured, cell membrane is indistinct, and basal striations are concealed.

Central terminal tubule cells in female glands have little granulation of any sort, nuclei are located in the central region of the cytoplasm, and basal striations are clearly visible between nuclei and cell bases. In peripheral regions, cell cytoplasm frequently contains large spherical red-orange granules but to a much lesser extent than in similar cells of the male gland; nuclei are basal and striations are no longer apparent.

Acinar cells:--As the duct system terminates, terminal tubules connect with <u>serous acini</u> composed of small groups of cells, each of which has an opaque, spherical nucleus at the base. The narrow, almost obliterated, acinar lumina are seldom seen. These cells possess fine dark blue or purplish

granules in varying amounts and vacuoles are frequently present. The cells rest on a basement membrane and scattered between membrane and epithelium, stellate basal cells or "basket" cells are observed. Acini appear to be more numerous in the female than in the male gland.

Sublingual gland

Mouse sublingual glands lie on the antero-lateral surface of the submaxillary glands within the same connective tissue sheath. Unlike the multi-lobated submaxillary, the sublingual is composed of a single ovoid lobe which is divided by connective tissue septa into several lobules.

Duct system:--The excretory duct has a prominent lumen with epithelium that is pseudostratified in the larger units, changing to simple columnar epithelium followed by low basally striated cells within the lobules. As this striated portion of the duct system approaches the acini it becomes slender, forming intercalated ducts, as indicated in diagram.

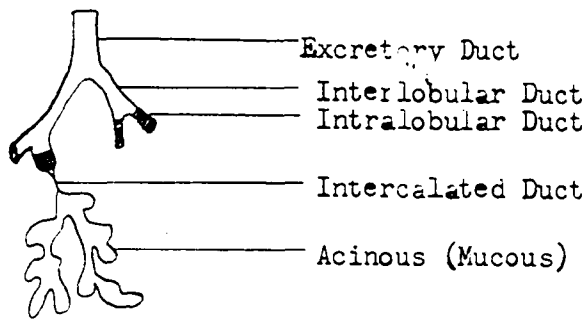

Diagram of the Sublingual Gland of the Laboratory Mouse

Intercalated ducts:--These ducts are distinctive by their small lumina, low cuboidal cells with round central nuclei and a small amount of cytoplasm which is devoid of granules. Since intercalated ducts are continuous with the acini, they apparently occupy a position in the duct system similar to that occupied by the terminal tubules of the submaxillary gland.

Acinar cells:--Acini are composed of mucous cells with nuclei flattened to the bases and the cytoplasm which appears clear. When subjected to MTCT stain, cytoplasm stains a pale blue; the PAS method colored a network of cytoplasm magenta or red purple, (PAS-positive), indicating the presence of neutral polysaccharides. Lumina of intralobular ducts contained material which stained a lighter shade of magenta, and would thus be considered to be PAS-positive. Nuclei were unstained by PAS treatment.

There appeared to be no difference between the sublingual glands from male laboratory mice and those from female mice.

Parotid gland

The several lobes of the mouse parotid gland are subdivided by connective tissue septa into numerous small elongated lobules. This flat and somewhat diffuse gland extends from the ventro-lateral surface of the neck to the shoulders.

Duct system:--The pseudostratified primary duct branches repeatedly and soon gives place to simple columnar epithelium

followed by striated ducts which lead into narrow intercalated ducts.



Diagram of the Parotid Gland of the Laboratory Mouse

Intercalated ducts:--These ducts of low cuboidal epithelium are longer than those of the sublingual gland and are continuous with the relatively large serous cells of the acini.

Acinar cells:--Chromophil material, which stains darkly with basic dyes, is observed in the cytoplasm of the serous cells around and below the nuclei. It is the presence of such chromophil material which differentiates parotid serous acinar cells from those observed in mouse submaxillary tissue.

Above the opaque spherical nuclei, relatively large cytoplasmic granules are usually discernible. It should be noted that throughout the literature (Stormont, 1932) these granules are referred to as zymogenic (enzyme antecedent) and parotid gland acini are classified as serozymogenic cells.

Both male and female parotid glands appear to be similar in all respects.

The microscopic anatomy of sublingual and parotid glands from the following rodents was studied after tissue sections were stained by MTCT method: fox squirrel (Sciurus niger), pocket gopher (Geomys bursarius), brush mouse (Peromyscus boylii), pack rat (Neotoma floridana), and guinea pig (Cavia porcellus). With the exception of the presence of adipose cells among sublingual and parotid acini, in male and female guinea pig tissues no observable species or sex differences were noted in this portion of the salivary complex.

In order to avoid repetition, the results of the survey of submaxillary gland structure to be presented in subsequent sections will deal only with characteristics which differ from those described for the submaxillary gland of laboratory mouse. Unless otherwise indicated, descriptions of staining properties of cellular structures refer to coloring by MTCT stain.

Sub-Order: Sciuromorpha --- Family Sciuridae

Woodchuck (Marmota monax).

The single specimen of a submaxillary gland from a woodchuck was from an adult male.

Serous acini display a very remarkable variation in amount of cytoplasmic granulation and in the staining affinities of the fine blue granules. Spheroid basal nuclei are shades of yellow to red (Pl. II, Fig. 3).

Intercalated ducts, lined by low cuboidal cells with rounded central nuclei and cytoplasm devoid of granules, are apparent. Terminal tubules are not observed.

Cells of striated intralobular ducts have central nuclei which in most instances are surrounded by a "halo" of clear cytoplasm. Nuclei, like those of the acinar cells, range in color from yellow to red, which suggests differences in the secretory state of the cells.

Fox squirrel (Sciurus niger).

Intralobular striated ducts branch into terminal tubules lined by cells with fine blue cytoplasmic granules and prominent basal striations; large round central nuclei stain variously from yellow through red.

Acinar cells of submaxillary glands from five males and three females show extreme variability in size, concentration, and staining properties of cytoplasmic granules. There is a strong hint that two cell types are present. One type displays distinct cellular delineation and contains minute granules which stain light blue; cytoplasmic vacuoles are numerous and nucleus is spheroid. The other less frequently observed cell has a heavy concentration of large coarse granules, the cell shape is distorted and the nucleus is obscured (Pl. III, Figs. 4 and 5). Some of these latter cells contain dark red granules, still others have granules which stain dark blue. However, in view of the observation that both types of cells appear to be present in the same acinus,

it is possible only one kind of acinar cell in various phases of secretion is being described. Differences in color of terminal tubule nuclei support this explanation.

Sub-Order: Sciuromorpha --- Family Geomyidae

Pocket gopher (Geomys bursarius).

Submaxillary glands from a male pocket gopher contain no terminal tubules such as are described for the mouse (Pl. IV, Fig. 6). Intralobular ducts terminate as short intercalated ducts. Occasional mucous cells occur among serous acini.

Sub-Order: Sciuromorpha --- Family Heteromyidae

Pocket mouse (Perognathus flavenscens).

Glands from three males were available for study. The submaxillary glands of the pocket mouse closely resemble the prototype gland of the laboratory mouse. With the exception of the termination of intralobular ducts as intercalated ducts, rather than terminal tubules, tissues from these two species are indistinguishable.

Sub-Order: Sciuromorpha --- Family Castoridae

Beaver (Castor canadensis).

Submaxillary tissue from a male beaver contains three types of acini: (1) serous, (2) mucous, and (3) mixed or serous demilune cells (Pl. V, Fig. 8). The great expanse of acinar material consists chiefly of serous cells which are characterized by their relative small size, intense staining qualities, rounded subcentral nuclei, and almost

-obscure lumina formed by these cells. Mucous cells are readily distinguished from serous cells by their larger size, chromophobic cytoplasm, and flattened basal nuclei. The relatively few mixed or serous demilune cells are seen for the first time in this survey of rodent submaxillary tissue. These are large mucous cells which appear to be "capped" by crescent-shaped serous cells.

The short duct system terminates as striated tubules of unusually small cells. Their large round nuclei are subcentrally located and are encircled by a heavy concentration of dark blue granules. Towards the apex of the cell, cytoplasm is devoid of granules.

No female submaxillary tissue was available for study.

Sub-Order: Myomorpha --- Family Cricetidae

Brush mouse (Peromyscus boylii).

Submaxillary glands from three field specimens, one male and two females (collected on the same day in April) were obtained for study of cellular details. Microscopic examination of tissue from the male and one female reveals these glands to be quite similar to one another as well as to the model gland of the laboratory mouse. Intercalated ducts are present. Terminal tubules, as those described in the prototype are not observed.

Tissue from the other female has a duct system similar to the one just described for brush mice. However, in addition to serous acini there appear clusters of cells with

coarse, dark red cytoplasmic granules in such concentration as to obscure nuclei, and obliterate cell boundaries in some instances. These cells are frequently close to the narrow intercalated ducts which appear to connect with the equally narrow lumen of the unusual acinus (Pl. VI, Fig. 10).

Grasshopper mouse (Onychomys leucogaster).

The cells of serous acini stain intensely blue; are frequently vacuolated. No structural differences are observed between the two sexes (Pl. VII, Figs. 11 and 12).

However, as the duct system terminates, sex-dimorphic terminal tubules are in evidence. Although the dimorphism is distinct, it is not nearly so dramatic as that observed in laboratory mice.

The cells of the peripheral terminal tubule in the male gland have a cytoplasm filled with large coarse red-orange granules, nuclei, which are flattened against the cell bases, are rarely visible. Central terminal tubules differ from those in the periphery by having cells with few large red-orange granules; numerous small blue granules, large round subcentral nuclei, and basal striations.

In the female, cells of terminal tubules in the periphery of the gland contain a heavier concentration of coarse, red-orange granules than do similar cells in a more central position. However, this granulation is never so great as to completely obliterate basal nuclei which are surrounded by chromophilic material. Basal striations are apparent in

some cells. The apex of the cell contains chromophobic cytoplasm with strands of dark blue material scattered therein. In the central region, the terminal tubule cells contain relatively few granules, central nuclei, and basal striations.

Unlike the submaxillary glands of laboratory mice, intercalated ducts are readily apparent in specimens from both sexes.

These observations are based on histologic studies of tissues from three males and two females of this species.

Cotton rat (Sigmodon hispidus).

Submaxillary glands from five male and five female cotton rats were available for this survey.

Intralobular ducts end as terminal tubules with large round central or subcentral nuclei and very fine red-orange cytoplasmic granules. Granulation is sometimes heavier in cells of peripheral tubules and perhaps even slightly greater in male than in female specimens. However, the differences are much too subtle to enable one to consider the cotton rat as having sex-dimorphic submaxillary glands (Pl. VIII, Figs. 13 and 14). Prominent intercalated ducts are present among the acini.

Serous acini display great variation in concentration of chromophilic materials. Staining properties of round, basal nuclei are also variable. These differences are believed to be due to various stages of secretion rather than to the presence of more than one type of acinar cells.

Pack rat (Neotoma floridana).

Serous acinar cells of submaxillary glands from five males and four females resemble those of the mouse prototype. Pack rat males and females vary, however, in that the acinar cells of the males are somewhat larger.

In the cells of terminal tubules, unusually large granules appear in the cytoplasm of the tall columnar cells between the prominent rounded basal nuclei and apices (Pl. IX, Figs. 15 and 16). Granules are more numerous in the male submaxillary than in the female gland. Although a peripheral-central difference in granulation is observed, it is not nearly so distinct as that described for the laboratory mouse.

Another feature which differentiates this tissue from laboratory mouse tissue is the irregular staining of the terminal tubule granules. Within the same section, in neighboring terminal tubules, it is possible to find large dark blue cytoplasmic granules which seem to be identical in position and structure to the red-orange granules. A difference in secretory phase is postulated.

When submaxillary tissues from male and female pack rats are subjected to a histochemical stain (PAS) all terminal tubule granules stain bright magenta, indicating the presence of neutral polysaccharides. Granules in the terminal tubules of the mouse submaxillary are free from color.

In order to investigate the hypothesis that an increase

in granulation is accompanied by an increase in terminal tubule diameter (as is true in the laboratory mouse submaxillary gland), cross-sectional diameters of ten terminal tubules from each of two males and two females were measured, with the following results: males had a mean tubule diameter of 40.71μ with a standard deviation of 5.24μ; females had a mean tubule diameter of 23.33μ with a standard deviation of 2.17μ. These preliminary observations suggest that, indeed, the sex dimorphic feature of greater tubule granulation in the male is accompanied by greater terminal tubule diameter.

Muskrat (Ondatra zibethica).

Submaxillary tissue from this species was limited to samples from two males.

Acini are relatively few in number. The gland is composed mostly of tortous terminal tubules, which are longer than those of the mouse. Cells are filled with coarse red-orange granules and basal nuclei are frequently obliterated. Peripheral-central tubule cell difference is apparent (Pl. X, Fig. 17).

Sub-Order: Hystricomorpha --- Family Cavidae

Guinea pig (Cavia porcellus).

The one feature which differentiates guinea pig submaxillary glands from all other submaxillary glands included in this study is the presence of numerous fat cells which lie between lobules and among the acini. This intercellular deposition of adipose tissue was seen in glands from nine

males and seven females of this species (Pl. XI, Fig. 18).

The duct system of the guinea pig submaxillary gland apparently lacks terminal tubules. Intercalated ducts are prominent and plentiful. Intralobular ducts tend to appear in clusters rather than being randomly distributed among the acini.

Serous acinar cells differ from those of the laboratory mouse by the presence of chromophilic material around the nuclei. Among these serous cells in the female gland there are occasional mixed acini with mucous cells capped by serous demilunes, which, it should be noted, are not observed in male submaxillary glands.

The presence of mixed acini in female tissue was confirmed by the PAS histochemical technique which is specific for mucous cells. Sublingual tissue, with its mucus-producing acini, was used for comparison in this study. No mucous cells were discernible with PAS stain in the male submaxillary gland.

Discussion

With glands of the salivary complex of the laboratory mouse as prototypes, microscopic structures of salivary tissue from twelve species of rodents were compared histologically.

Sublingual and parotid glands included in this survey were strikingly similar to those of the mouse, with the exception of those of the guinea pigs. In all guinea pig salivary glands examined, infiltration of adipose tissue was

evident. These fat cells were generously distributed between lobules and among acini. Although this feature is commonly seen in human salivary tissue (DiFiore, 1958), it has not been reported previously for any laboratory or field rodent. The possibility does exist that this unusual deposition of fat is species specific. However, until further examination of salivary glands of guinea pigs from other colonies is made, no such interpretation of this finding is permissible.

The excretory ducts present in the submaxillary glands studied vary somewhat in degree of ramification, but, structurally they appear to be essentially the same in all instances. Pseudostratified epithelium changes into simple columnar epithelium as the main duct branches into interlobular ducts, which, in turn, divide to form smaller intralobular ducts. It is at this point where the duct system terminates and secretory components of some glands begin that differences, if any, appear. Species differences in submaxillary tissue of rodents has been shown by this investigation to be the rule rather than the exception.

Acinar Cells

The serous salivary acini described for the laboratory mouse are formed by pyramidal cells with opaque basal nuclei, and a cytoplasm which is vacuolated and sometimes contains fine, blue granules. These cells are essentially the same throughout the gland, and have been similarly described by earlier workers (Stormont, 1932). However, such uniformity

is by no means representative of rodents in general.

Acinar elements of submaxillary glands from the grasshopper mouse and pack rat most closely resemble laboratory mouse tissue. The acini of the muskrat are also quite similar in appearance to those of the laboratory mouse, but are conspicuously fewer in number.

The simplest kind of variation from the model is observed in the granular material of the acinar cells of the woodchuck, pocket mouse, and cotton rat. These granules range in concentration from light to heavy, but, it should be noted, are always some shade of blue. In addition to differences in acinar cell granules, the nuclei of these cells also displayed various staining properties in the woodchuck and cotton rat, but not in the pocket mouse.

Acinar cells of the fox squirrel also possess various amounts of granulation, but these granules may be either blue or red; both types may be present within the same acinus. A similar shift in granular quality and quantity is found in the acinar cells of the brush mouse. In this instance, however, only one kind of granulation is found in the cells composing a single acinus.

Although these differences which are noted above might well be attributable to differences in secretory phases at the time the animals were sacrificed, the possibility exists that these differences might represent some type of transitional stage between the one- and two-cell type acinus.

Two species have been found to possess two types of acini. The pocket gopher has mucous acini randomly situated among the predominant serous acini. The female guinea pig has relatively few mixed acini or serous demilune cells among the acini which are chiefly serous in nature.

Of the species surveyed submaxillary gland reaches its peak of complexity in acinar development in the beaver where three distinct types of acini are observed. Throughout the field of serous acini, occasional groups of mucous cells, and some very distinct mixed acini with serous demilunes are interspersed. Although the proportion of these cells may differ somewhat, these three types of acini are present in the submaxillary gland of man (Di Fiore, 1958).

Intercalated Ducts

Descriptions of the histology of submaxillary tissue of the laboratory mouse by earlier workers (Stormont, 1932) show intercalated ducts among the acini, through which secretions from the acini are presumed to pass into the terminal portions of the intralobular ducts. These intercalated ducts are smaller in diameter than the serous acini; cells are cuboidal with a rounded central nuclei. Although tissue from at least fifty animals have been carefully scruntinized, this author has been unable to confirm the presence of these ducts in the submaxillary gland of mice from our laboratory. However, their presence has been noted in several of the other rodents included in this study.

Intercalated ducts have been found to occur among the acini of the woodchuck, pocket gopher, pocket mouse, brush mouse, grasshopper mouse, cotton rat, and guinea pig. The significance of the absence or presence of these ducts is unknown. Whether or not cells of intercalated ducts transform into mucous cells, as was postulated by earlier authors (Stormont, 1932), has not been firmly established.

Intralobular Ducts

It is recalled that in laboratory mice the intralobular ducts terminate as characteristic secretory terminal tubules. The cells of these tubules contain varying amounts of coarse, granulation depending upon the position of the tubules. Those in the periphery are frequently packed with granules, while those occupying a more central position are rather sparsely granulated.

Terminal tubules are not common to all rodents. Of the twelve species considered in this survey, only four species -- grasshopper mouse, cotton rat, pack rat, and muskrat -- have been found to have typical terminal tubules with cells containing coarse red-orange granules and exhibiting some degree of peripheral-central differentiation in the concentration of granules. Atypical terminal tubules, with cells possessing fine blue granules and no peripheral-central differentiation are present in the fox squirrel and beaver.

It is interesting to note that the coarse granulation in terminal tubules is confined to species representing two

families, Muridae and Cricetidae in sub-order Myomorpha.

Sex-dimorphism in Submaxillary Glands

In view of the extraordinary sex-dimorphic characters of the mouse submaxillary gland, a search for somewhat similar sex differences was made for each species for which sufficient tissues were available, in order to determine the extent of such a phenomenon within the Order Rodentia. The features which differ between male and female tissues are confined to cells which line terminal segments of intralobular ducts, and such differences are expressed in granule quantity, nuclear position, basal striations, and tubule diameter.

Male and female submaxillary tissue was available from six species of rodents (excluding the laboratory mouse): fox squirrel (Sciurus niger), brush mouse (Peromyscus boylii), western grasshopper mouse (Onychomys leucogaster), cotton rat (Sigmodon hispidus), pack rat (Neotoma floridana), and guinea pig (Cavia porcellus). Terminal tubule sex dimorphism was noted in the western grasshopper mouse and in the pack rat.

The grasshopper mouse and pack rat belong to the same sub-order as the laboratory mouse, i.e., Myomorpha. As is true for the submaxillary gland of the mouse, cells which line the terminal tubules of the male gland are taller and have a much heavier concentration of coarse granulation then do the corresponding cells within the female gland.

Although no confirmed report of sex dimorphism in submaxillary gland acini is found in the literature, it was

postulated that if such did exist, it would be observed in the size of acinar cell, position of nucleus, or amount, size, and/or kind of cytoplasmic granules.

Submaxillary tissue from female guinea pig has been found to differ from that of the male by the presence of occasional mixed acini among predominant serous acini. These mixed acini are composed of both serous and mucous cells. The serous cells form crescent-shaped masses, or demilunes, attached along the periphery of the group of mucous cells.

Another observation of sex-dimorphism in submaxillary gland acini occurs in conjunction with terminal tubule dimorphism noted in the pack rat. The serous acinar cells of the gland of the male pack rat are notably larger than those present in females of the same species.

For each instance of sex dimorphism which has just been cited, it should be noted that although the differences are distinct, and most interesting, they are never so dramatic as the dimorphic characters present in laboratory mice.

CHAPTER III

ENZYMATIC STUDIES

Materials and Methods

This phase of research was restricted to adult animals reared in our own laboratory and utilized thirty guinea pigs, twenty Sprague-Dawley rats, and one hundred fifty mice, colony-inbred for fourteen years.

Guinea pigs were divided into four groups of five each: normal females, pregnant females, lactating females, and normal males. Two groups only of laboratory rats were analyzed: normal males and females. Each group consisted of ten animals. Laboratory mice were divided into ten groups of fifteen each: normal male and female controls, normal males and females injected with testosterone propionate, gonadectomized males and females, gonadectomized males and females treated with testosterone propionate or with estradiol.

Gonadectomies and injections of gonadal hormones were used as tools to determine the effect of the sex endocrine organs in mice on the activity of the enzymes studied. Castration was followed by a thirty-day post-operative period before animals were sacrificed or before injections were

begun. Mice receiving gonadal hormones were injected daily for ten days prior to autopsy with 0.2 mg. testosterone propionate in 0.1 cc. sesame oil, or 20 R. U. estradiol benzoate[1] in 0.1 cc. sesame oil. All injections were administered subcutaneously.

From each group of animals, the submaxillaries and parotids, in toto, were the glands selected from the salivary complex for glycosidase analyses. The relatively minute amount of sublingual tissue available made such studies on this gland impractical at this time. The lower half of the pancreas and the upper portion of the small intesting (duodenum and jejunem) were subjected to analysis, hoping that the varying levels of enzymes found in salivary tissue might be better understood if these parts of the digestive system were also considered. Guinea pig, liver, skeletal muscle, and kidney were used as control tissues.

At the time of autopsy, animals were chloroformed and excised tissues were immediately weighed on a triple-beam balance, placed in distilled water (10x dilution wet wt./vol.), and homogenized in a chilled Waring blendor. The homogenate was then transferred to a beaker and, after the addition of a few drops of chloroform to subdue bacterial action, was allowed to remain at room temperature for twelve to eighteen hours.

Lactase, maltase, and sucrase activities were determined by a modification of a technique described by Heilskov (1951)

[1] 20 R. U. = 0.66 mg. estradiol benzoate

for identification of lactase in rabbit fetus intestine. Substrate and homogenate concentrations, optimum temperature, incubation time, and pH, as well as proper buffer, and homogenate aging, were established for each enzyme in guinea pig tissue. These conditions were subsequently held constant for all tissues of all species studied. For each homogenate and substrate studied, duplicate experimental and control tubes were used.

Experimental Tubes

After a 0.5 ml. aliquot of homogenate (submaxillary, parotid, pancreas, or intestine) was pipetted into each test tube, two mls. of substrate were added (lactose, maltose, or sucrose for lactase, maltase, and sucrase, respectively). Each tube was gently inverted to assure proper mixing of homogenate and substrate before being placed into a 37°C. constant temperature water bath for thirty minutes. Immediately following incubation, the tubes were put into a beaker of boiling water for three minutes to stop enzymatic action. When the contents of the tube had cooled to room temperature, 1 ml. of absolute methyl alcohol was added for the precipitation of glycogen, to lessen turbidity of mixture. Tubes were thoroughly shaken for two minutes. This step was followed by the addition of approximately 0.5 g. of activated charcoal to each tube to adsorb suspended particles in an effort to attain a clear solution for colorimetric readings. Tubes were again vigorously shaken for a two-minute period,

and contents immediately filtered through Whatman No. 5 filter paper for removal of charcoal and other particulate matter known to interfere with light transmission. A 1.0 ml. aliquot of each filtrate was then tested for the presence of glucose by use of the Glucostat[1] method described later.

Control Tubes

Control tubes were treated in the same manner as were the experimental tubes, except they were placed in boiling water before rather than after incubation.

Colorimetric Determination of Glucose

To determine the amount of glucose present per ml. of filtrate, a prepared enzymatic glucose reagent, Glucostat, was used. The advantage of a reagent such as this is its sensitivity to the presence of true glucose. Glucostat is a coupled enzyme system based on specific enzymatic oxidation of glucose by glucose oxidase:

$$\text{Glucose} \xrightarrow[O_2]{\text{Glucose Oxidase}} \text{Gluconic Acid} + H_2O_2$$

Hydrogen peroxide, in the presence of peroxidase, reacts with a chromogenic acceptor, orthodianisidine:

$$H_2O_2 \xrightarrow[\text{peroxidase}]{\text{O-dianisidine}} \text{Color}$$

---

[1]Trademark. Worthington Biochemical Corp., N.J.

At the end of a given period of time (in this case, fifteen minutes gave the best results) the color formed is proportional to the amount of glucose oxidized. The entire reaction is run at room temperature along with a standard glucose solution and a reagent blank.

The procedure developed for the use of Glucostat was as follows: into a series of Klett tubes, 2.5 mls. of distilled water were pipetted, followed by the addition of 1 ml. aliquots of the respective filtrates. Fifteen minutes after 2.5 mls. of substrate-reagent were introduced into each tube, the reaction was stopped and color was stabilized by the addition of one drop of 4N HCl. After five minutes the tubes were read in a Klett-Summerson colorimeter, in the region of 400 mμ (filter #420). The instrument was zeroed with a reagent blank containing 3.5 mls. of water and 2.5 mls. of Glucostat.

With each group of tests and/or each new batch of reagent a standard containing 0.10 mg. of glucose was included, since the amount of glucose obtained from each determination was used as an index of enzyme activity.

Influence of Free HCl on Glycosidase

In order to correlate enzyme activity with shifts in pH which occur at various sites along the upper portion of the digestive tract, the influence of free acid on lactase, maltase, and sucrase present in female guinea pig submaxillary, parotid, pancreatic, and intestinal tissue was investigated. The following strengths of free HCl were used: 0.2%, 0.1%,

0.05%, 0.025%, and 0.006% to achieve in eventual dilutions total acidities of 0.12%, 0.06%, 0.03%, 0.015%, 0.007%, and 0.003%. A series of six tubes was prepared for each substrate-homogenate combination studied. Into each tube was placed 2 mls. of the respective dilutions of HCl, 1 ml. substrate and 0.5 ml. homogenate. Tubes were thoroughly shaken after the separate additions of substrate and homogenate, then placed into a water-bath at 37°C. for thirty minutes.

The general idea for this experiment on serial dilutions of free acid was obtained from Mellanby and Woolley (1915), where a somewhat similar experiment was outlined to demonstrate increase in the hydrolytic ability of dog pancreatic juice in the presence of free acid.

Results

The following substrate and homogenate concentrations, optimum temperature, incubation time, and pH, as well as proper buffer, and homogenate aging, were established as described above, for female guinea pig tissues:

	Lactase	Maltase	Sucrase
Substrate			
concentration	1%	1%	1%
pH	4.8	6.8	6.3
buffer (0.2M)	Na-acetate	Na-phosphate	Na-phosphate
Homogenate			
concentration (wet wt/vol)	100 mg/ml	100 mg/ml	100 mg/ml
aging at room T°	none	12-18 hrs	12-18 hrs
Incubation time (min)	30	30	30
Incubation temp (°C)	37	37	37

In an attempt to establish whether the tissues of the digestive system included in this investigation actually produce the enzymes under consideration, or whether similar enzymatic activities are found in all organs as a result of their presence in blood and tissue fluids, specimens of liver, skeletal muscle and kidney were assayed. These data are summarized as follows:

Micrograms of Glucose per 100 Milligrams of Tissue

Tissue	Lactase	Maltase	Sucrase
Liver	121.4 (112.7-128.3)	0.0	0.0
Skeletal Muscle	5.6 (2.2-9.0)	0.0	14.3 (9.7-16.5)
Kidney	20.0 (19.0-23.6)	313.5 (291.4-324.1)	0.0

Guinea Pigs

Tables 1 and 2, and Figure 1, present micrograms of glucose obtained from lactose, maltose, and sucrose by action of the respective hydrolytic enzymes present in submaxillary, parotid, pancreatic, and intestinal tissue.

Lactase activity is consistently low in all instances. This same observation is likewise true for sucrase, with the exception of intestinal tissue. Intestinal sucrase activity in females is considerably lower than that found in males. However, this situation is reversed during the lactation period.

An obvious sex difference is noted in the production of

TABLE 1

MICROGRAMS OF GLUCOSE PER 100 MILLIGRAMS OF WET TISSUE

Guinea Pigs

Category	Submaxillary Gland			Parotid Gland		
	L*	M	S	L	M	S
Normal Females	4.3 (3.0-6.4)	1.8 (0.8-3.2)	1.1 (0.6-1.4)	3.1 (0.2-5.2)	35.0 (32.0-50.4)	0.8 (0.0-1.3)
Pregnant Females	6.2 (4.5-8.8)	37.7 (32.5-43.2)	0.8 (0.0-2.0)	3.2 (2.5-4.0)	23.1 (15.5-31.5)	1.9 (0.0-3.5)
Lactating Females	3.6 (3.0-4.3)	30.7 (26.1-35.3)	5.5 (4.7-6.3)	1.3 (0.0-2.6)	18.1 (14.0-22.2)	5.9 (2.5-9.3)
Normal Males	9.1 (6.6-11.0)	75.8 (52.7-92.4)	3.9 (1.9-8.8)	3.9 (3.0-5.6)	33.9 (29.0-39.8)	1.7 (0.0-3.4)

*Enzymatic Activity: L = Lactase; M = Maltase; S = Sucrase

TABLE 2

MICROGRAMS OF GLUCOSE PER 100 MILLIGRAMS OF WET TISSUE

Guinea Pigs

Category	Pancreas			Intestine		
	L*	M	S	L	M	S
Normal Females	2.1 (0.8-3.2)	5.6 (3.4-8.0)	1.3 (0.0-2.8)	26.0 (15.2-32.5)	295.2 (233.0-365.3)	147.1 (128.6-178.9)
Pregnant Females	4.0 (0.0-8.8)	14.0 (7.0-20.8)	0.7 (0.0-1.4)	13.2 (4.0-30.6)	297.7 (259.0-321.2)	133.7 (114.5-158.3)
Lactating Females	1.7 (0.4-3.0)	23.1 (18.6-27.6)	1.2 (0.0-2.4)	8.0 (5.3-10.7)	530.3 (519.0-541.6)	521.2 (512.7-529.6)
Normal Males	6.2 (5.6-7.7)	21.1 (10.9-28.5)	0.7 (0.0-2.1)	13.0 (11.9-14.4)	600.1 (543.8-655.3)	349.3 (222.7-453.3)

*Enzymatic Activity: L = Lactase; M = Maltase; S = Sucrase

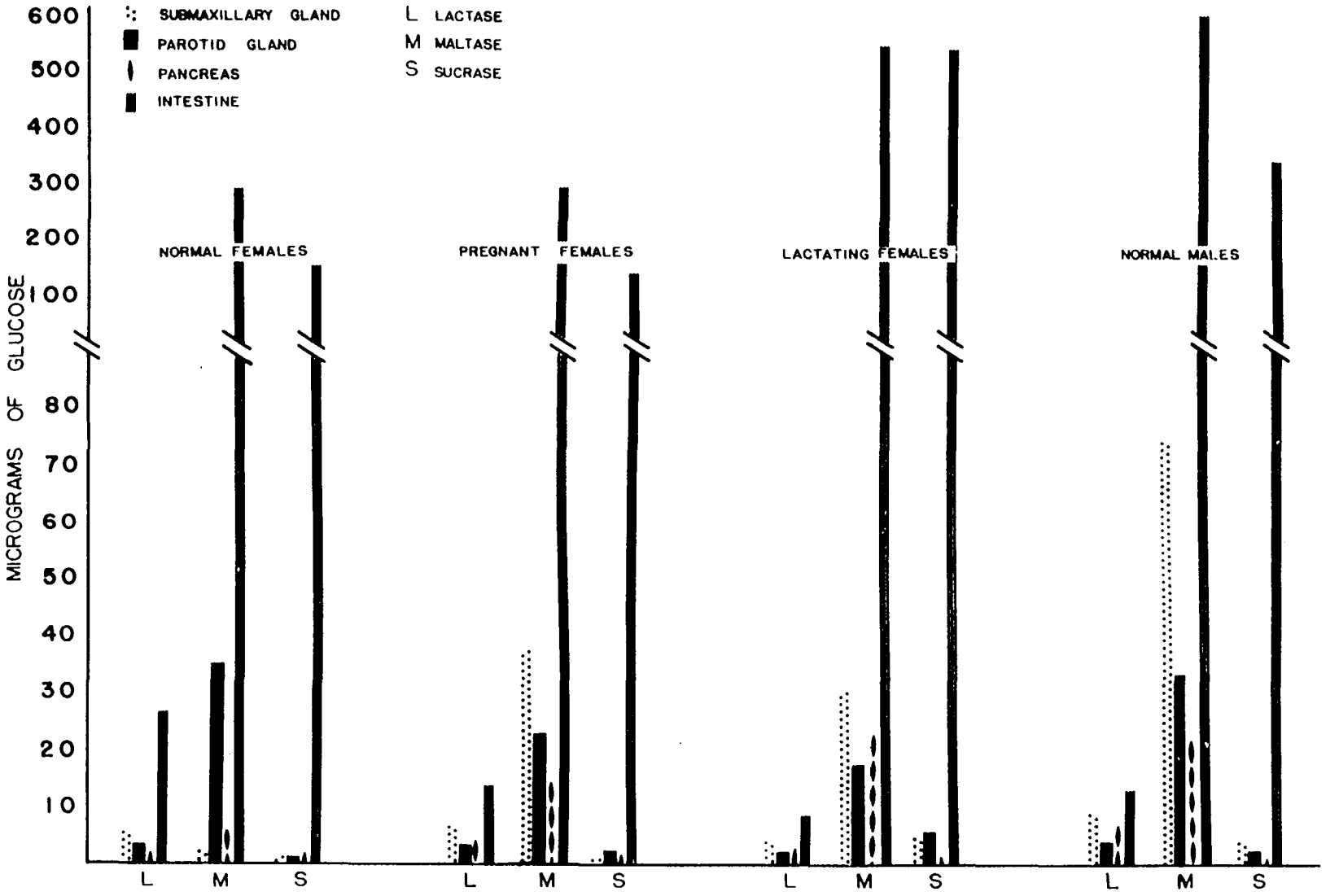

FIG. I. GLYCOSIDASE ACTIVITY PER 100 MILLIGRAMS OF GUINEA PIG TISSUE

maltose in the submaxillary gland; the level of activity in the male far exceeds that found in the female. A similar, but not nearly so striking, difference is seen in results obtained from assay of intestinal tissue.

Laboratory Rat

As shown in Tables 3 and 4, Figure 2, the level of lactase activity was low in all instances. Sucrase production in the accessory digestive glands was also of little significance, but a fair amount of activity was demonstrated in the upper intestine of both sexes.

Female rats produce less maltase in the submaxillaries, more in the parotids and pancreas, and less in the intestine than do males.

Laboratory Mice

Lactase.

Data presented in Tables 5 and 6, and Figure 3a, show lactase activity to be rather low in all female tissues except the intestine. Injections of male hormone into intact females brought about at least a two-fold increase in submaxillary, parotid, and pancreatic activity, while intestinal lactase was decreased well below normal level.

Ovariectomy alone had no influence on lactase level; when followed by injections of estradiol a slight rise in submaxillary, parotid, and pancreatic activity occurred, and intestinal lactase rose well above normal level. Injections

TABLE 3

MICROGRAMS OF GLUCOSE PER 100 MILLIGRAMS OF WET TISSUE

Laboratory Rats

Category	Submaxillary Gland			Parotid Gland		
	L*	M	S	L	M	S
Normal Females	11.3 (10.4-12.1)	8.8 (6.2-11.4)	9.3 (8.2-10.4)	7.4 (5.0-9.9)	58.7 (49.1-73.3)	1.6 (0.2-2.6)
Normal Males	19.6 (13.5-25.8)	35.4 (34.8-35.9)	2.2 (0.0-4.3)	4.6 (4.6-4.7)	39.3 (32.9-45.6)	0.0 (0.0-0.0)

* Enzymatic Activity: L= Lactase; M = Maltase; S = Sucrase

TABLE 4

MICROGRAMS OF GLUCOSE PER 100 MILLIGRAMS OF WET TISSUE

Laboratory Rats

Category	Pancreas			Intestine		
	L*	M	S	L	M	S
Normal Females	4.9 (3.9-5.9)	55.9 (44.1-67.7)	4.2 (3.9-4.6)	19.7 (17.3-22.1)	411.6 (367.6-4555.5)	99.0 (79.3-119.8)
Normal Males	4.1 (3.6-5.3)	12.7 (9.8-15.6)	0.3 (0.0-0.5)	12.6 (11.4-13.9)	498.9 (479.5-528.3)	101.0 (98.0-104.0)

*Enzymatic Activity: L = Lactase; M = Maltase; S = Sucrase

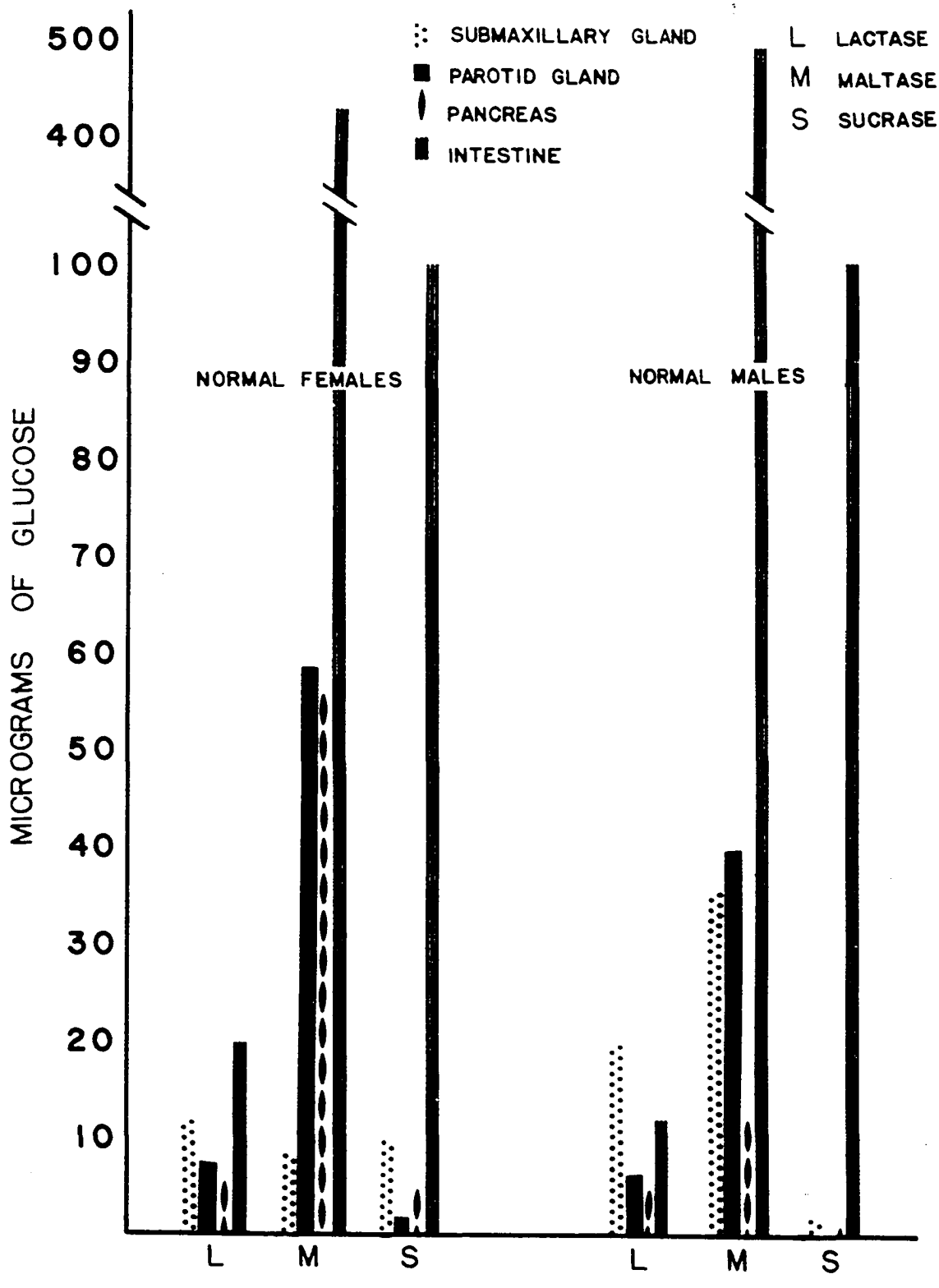

FIG. 2. GLYCOSIDASE ACTIVITY PER 100 MILLIGRAMS OF RAT TISSUE

TABLE 5

MICROGRAMS OF GLUCOSE PER 100 MILLIGRAMS OF WET TISSUE

Laboratory Mice

Category	Submaxillary Gland			Parotid Gland		
	L*	M	S	L	M	S
Normal Females	6.9 (5.2-8.6)	43.8 (31.7-55.8)	2.8 (1.5-4.1)	6.3 (5.1-7.6)	51.0 (41.2-61.8)	1.3 (0.0-2.6)
Females - t.p.	17.2 (14.6-22.2)	101.1 (93.5-110.7)	5.4 (4.3-8.2)	14.6 (8.8-19.0)	40.8 (29.1-55.0)	2.3 (0.2-4.0)
Ovariectomized Females	7.6 (5.2-10.0)	66.2 (54.8-71.2)	3.5 (1.2-4.8)	7.1 (6.1-8.3)	45.4 (28.0-59.6)	5.6 (3.1-8.0)
Ovariectomized Females - e.b.	13.4 (10.0-17.1)	75.5 (61.0-83.8)	0.6 (0.0-1.2	13.9 (9.9-15.6)	48.2 (37.8-55.7)	0.6 (0.4-0.8)
Ovariectomized Females - t.p.	9.5 (5.4-13.0)	101.4 (87.1-111.1)	3.2 (1.0-5.3)	8.9 (6.5-12.1)	28.9 (21.8-33.1)	3.2 (2.1-4.4)

*Enzymatic Activity; L = Lactase; M = Maltase; S = Sucrase

TABLE 6

MICROGRAMS OF GLUCOSE PER 100 MILLIGRAMS OF WET TISSUE

Laboratory Mice

Category	Pancreas			Intestine		
	L*	M	S	L	M	S
Normal Females	8.0 (7.5-8.6)	37.2 (36.8-38.5)	0.0 (0.0-0.0)	105.8 (91.1-120.6)	575.2 (498.8-651.5)	240.0 (209.7-270.3)
Females - t.p.	16.7 (13.0-18.1)	90.5 (81.2-100.0)	3.1 (0.5-5.4)	66.2 (49.9-73.1)	507.1 (461.6-533.3)	236.3 (224.8-250.0)
Ovariectomized Females	9.1 (4.6-12.4)	40.4 (29.0-51.6)	3.3 (2.5-4.7)	102.5 (93.6-117.5)	432.8 (390.7-450.6)	256.0 (250.9-271.2)
Ovariectomized Females - e.b.	13.4 (8.1-15.3)	70.9 (63.3-79.0)	0.0 (0.0-0.0)	165.6 (140.8-180.4)	399.7 (380.0-413.1)	284.6 (250.4-301.0)
Ovariectomized Females - t.p.	7.9 (6.9-8.3)	64.7 (61.2-68.9)	3.2 (1.7-5.0)	86.3 (80.4-89.7)	463.9 (451.7-480.0)	239.5 (230.6-270.1)

*Enzymatic Activity: L = Lactase; M = Maltase; S = Sucrase

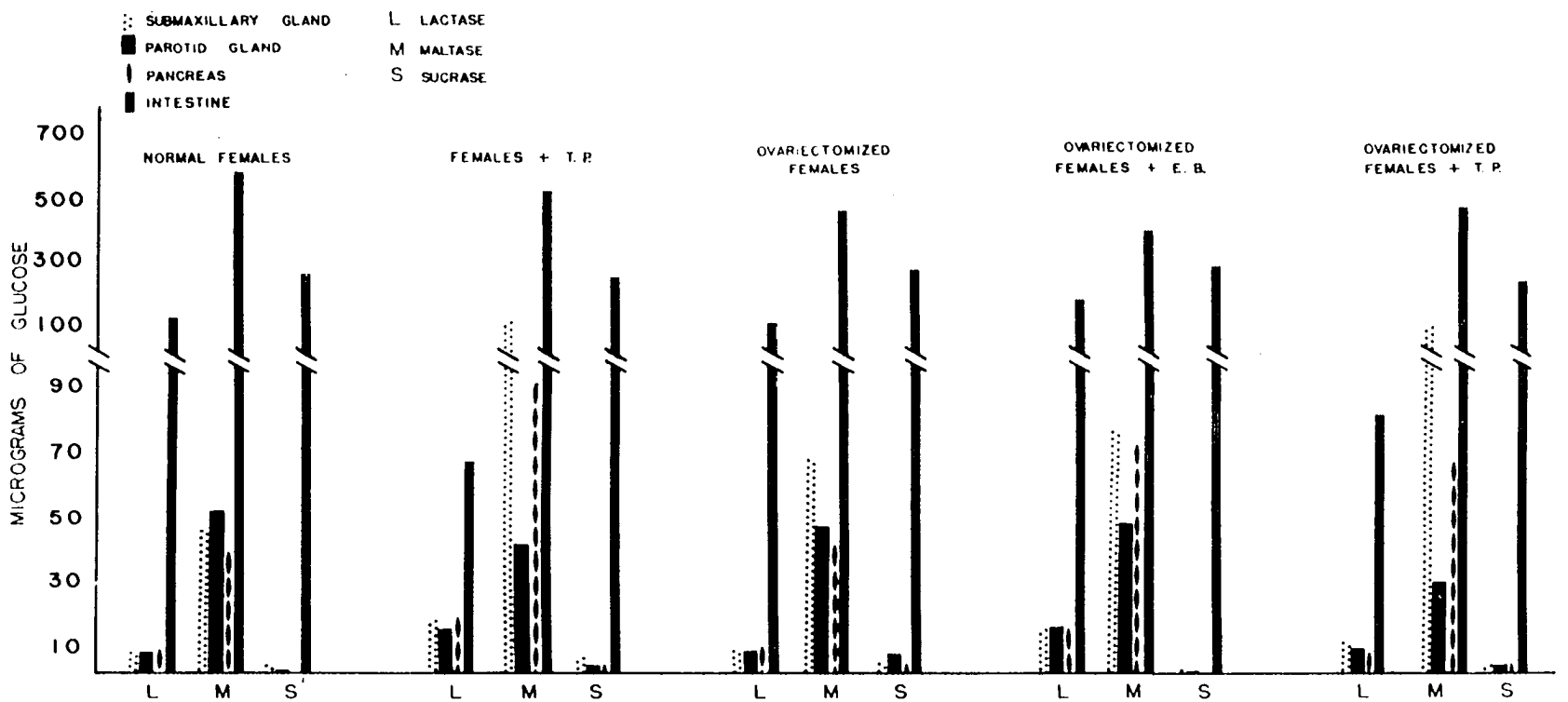

FIG. 3A. GLYCOSIDASE ACTIVITY PER 100 MILLIGRAMS OF LABORATORY MOUSE TISSUE

of testosterone to castrate females brought about similar shifts in activity as those recorded for the group receiving estradiol after ovariectomy, with one exception: the male hormone caused a decrease in intestinal lactase activity.

Administration of testosterone propionate to intact males had practically no effect on submaxillary, parotid, and pancreatic tissue (Tables 7 and 8, Fig. 3b), and brought about a very slight increase in intestinal tissue activity.

Gonadectomy in males had its greatest effect on intestinal lactase activity which was reduced to a considerably lower level than normal. The level of this enzyme remained unchanged in other tissues. Injections of estradiol benzoate in to castrated males resulted in the submaxillary, parotid, and pancreas reaching peak production of lactase in male mice, accompanied by a very significant reduction in intestinal lactase. When castrated animals were given injections of testosterone propionate, parotid and intestinal activity dipped to the lowest levels obtained for any of the ten groups of mice.

The greatest overall increase in lactase activity was found in ovariectomized mice which received injections of estradiol benzoate; the lease amount of lactase activity was observed in tissues from castrated males injected with testosterone propionate.

Maltase.

Submaxillary tissue from each experimental group of female

TABLE 7

MICROGRAMS OF GLUCOSE PER 100 MILLIGRAMS OF WET TISSUE

Laboratory Mice

Category	Submaxillary Gland			Parotid Gland		
	L*	M	S	L	M	S
Normal Males	14.4 (13.6-15.3)	52.8 (32.6-72.9)	2.8 (2.7-2.9)	7.6 (6.6-8.6)	48.6 (45.2-51.9)	2.1 (0.0-4.3)
Males - t.p.	13.4 (13.0-17.1)	0.0 (0.0-0.0)	0.0 (0.0-0.0)	6.3 (4.9-10.0)	18.1 (14.0-25.4)	0.0 (0.0-0.0)
Castrated Males	14.1 (12.7-16.8)	61.5 (51.3-71.4)	2.6 (0.3-4.9)	5.2 (3.0-6.9)	36.0 (30.0-41.6)	1.0 (0.0-2.0)
Castrated Males - e.b.	17.9 (14.8-20.2)	71.6 (59.2-79.9)	0.0 (0.0-0.0)	16.5 (13.9-18.9)	54.0 (48.9-51.0)	0.0 (0.0-0.0)
Castrated Males - t.p.	14.0 (11.1-17.2)	24.3 (17.9-29.2)	2.7 (1.1-4.3)	2.2 (2.2-2.3)	23.8 (19.4-27.8)	4.9 (2.5-6.9)

*Enzymatic Activity: L = Lactase; M = Maltase; S = Sucrase

TABLE 8

MICROGRAMS OF GLUCOSE PER 100 MILLIGRAMS OF WET TISSUE

Laboratory Mice

Category	Pancreas			Intestine		
	L*	M	S	L	M	S
Normal Males	9.2 (7.4-10.9)	56.2 (38.1-74.4)	0.8 (0.0-1.6)	103.5 (95.0-112.0)	507.5 (470.3-524.8)	281.8 (259.1-288.5)
Males - t.p.	8.7 (6.9-10.1)	18.1 (14.1-25.9)	0.0 (0.0-0.0)	115.1 (112.9-129.7)	557.2 (518.1-581.1)	183.4 (156.4-202.7)
Castrated Males	8.3 (5.5-10.1)	49.0 (29.7-65.0)	1.0 (0.6-1.4)	49.0 (31.7-70.3)	409.5 (400.0-415.2)	146.4 (108.2-167.4)
Castrated Males - e.b.	12.8 (8.0-15.5)	75.9 (69.9-79.6)	0.0 (0.0-0.0)	81.7 (70.3-89.9)	506.2 (472.8-520.1)	285.2 (262.1-310.9)
Castrated Males - t.p.	11.9 (8.1-12.8)	38.3 (21.0-47.9)	3.8 (0.9-4.4)	45.4 (36.0-51.2)	475.2 (466.6-485.0)	131.2 (109.3-150.5)

*Enzymatic Activity: L = Lactase; M = Maltase; S = Sucrase

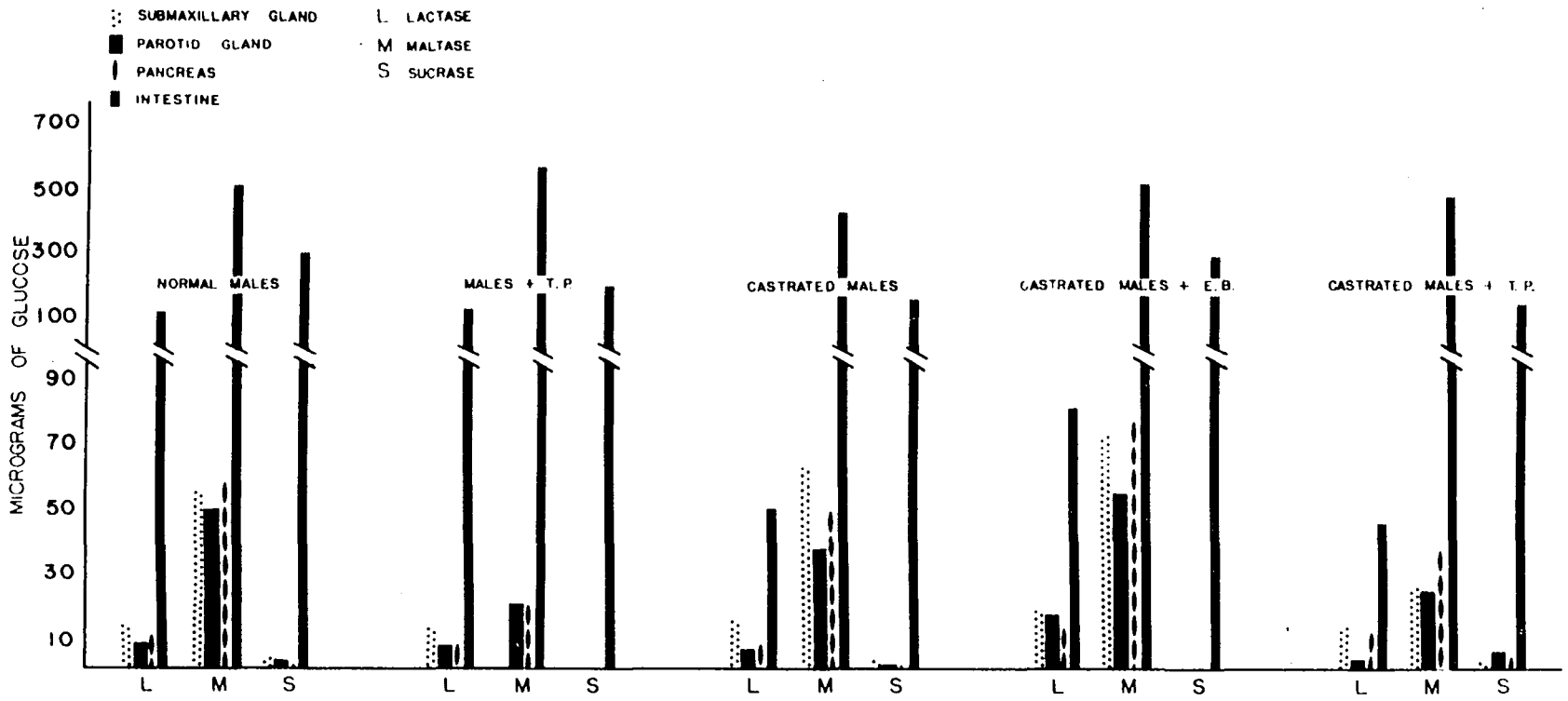

FIG. 3B. GLYCOSIDASE ACTIVITY PER 100 MILLIGRAMS OF LABORATORY MOUSE TISSUE

mice had higher maltase level than that found in control tissue (Tables 5 and 6, Fig. 3a).

The parotid remained essentially unaffected by injections of gonadal hormones and/or ovariectomy, except when spaying was accompanied by injections of testosterone propionate. In this instance, parotid activity fell below normal.

Pancreatic tissue seemed to respond in a positive manner in its production of maltase to: (1) ovariectomy plus administration of gonadal hormones, and (2) injections of testosterone propionate into intact females.

Intestinal maltase activity in all experimental groups fell well below that of the control animals.

The most striking feature about the male mouse (Tables 7 and 8, Fig. 3b) and its maltase production is that injections of testosterone propionate into intact animals caused submaxillary maltase to fall to zero, markedly lowered parotid and pancreatic maltase levels, and conspicuously raised intestinal maltase activity. Castration reduced maltase in all tissues except the submaxillary gland. On the other hand, when castrated animals received female sex hormone injections, there was an increase in the levels of maltase activity in submaxillary, parotid, and pancreatic tissue; no change was observed in the intestine. When such animals were given testosterone, a reverse situation occurred; a significant fall in maltase activity was recorded for all tissue.

Maltase activity in any given experimental group is

highest in intact females receiving testosterone. Castration in males reduced overall maltase activity to its lowest level; replacement therapy did not reverse this condition to control level.

Sucrase.

A consistently low level of sucrase activity was observed for submaxillary, parotid, and pancreatic tissues in all groups of female mice (Tables 5 and 6, Fig. 3a). However, gonadectomy alone or gonadectomy plus estradiol benzoate did stimulate intestinal sucrase somewhat.

Sucrase activity is absent or slight in submaxillary, parotid, and pancreatic tissue from normal males (Tables 7 and 8, Fig. 3b).

Problems of low levels of activity and inaccuracy of colorimetric determinations at either end of the absorbance or transmittance scales, make it difficult to recognize any influence exerted by experimental techniques on tissue glycosidase activity.

A high level of intestinal sucrase activity is recorded for the control group and for castrated males injected with estradiol benzoate. When exogenous testosterone is injected into intact males, intestinal sucrase production falls below normal. Sucrase activity in intestinal tissue falls even lower when males are castrated, and reaches its lowest ebb when castration is followed by administration of testosterone propionate.

Influence of Free HCl on Glycosidases

As is shown in Table 9, only at relatively high concentrations of free HCl is there an increase in the hydrolysis of lactose by female guinea pig pancreas and intestine. Salivary lactase is destroyed at HCl concentrations greater than 0.03%.

The action of homogenates on maltose is greatly enhanced in the presence of free acid. The degree of hydrolysis varies with the amount of HCl within the system. The greater the quantity of acid, the greater the hydrolysis, until the optimal point of 0.015% is reached.

Low levels of sucrase activity recorded for control tubes containing submaxillary, parotid, and pancreatic tissue are reduced to zero when free HCl is contained in the mixture. Intestinal sucrase level is increased 20% or more when exposed to free HCl, but this level remains fairly constant regardless of quantity of acid involved.

Discussion

Optimum pH ranges for animal glycosidases included in these studies are : lactase=4.5-5.2; maltase=5.8-7.4; and sucrase=5.5-7.5. Maltase and sucrase values correspond closely with those reported for hog intesting by Hawk *et al.* (1954). However, under the conditions of my experiments, the pH optimum for rodent lactase is somewhat lower than that reported for other mammals. According to Hawk, hog intestinal lactase has its optimum activity at pH 5.4-6.0, and this range was likewise found to be best for dog intestinal lactase

TABLE 9

INFLUENCE OF HCl ON GLYCOSIDASE ACTIVITY IN FEMALE GUINEA PIG TISSUE

Substrate	Homogenate	Total Acidities						
		0.12%	0.06%	0.03%	0.015%	0.007%	0.003%	0.00%
Lactose	Submaxillary	0.0*	0.0	2.2	1.8	1.3	1.3	2.0
	Parotid	0.0	0.0	1.3	0.4	1.8	0.9	1.5
	Pancreas	3.0	1.2	1.8	0.6	1.2	2.4	1.0
	Intestine	20.4	19.2	16.8	15.6	13.2	15.6	14.3
Maltose	Submaxillary	4.0	6.5	6.5	20.5	18.0	12.5	1.1
	Parotid	1.0	8.0	5.5	8.0	10.5	11.0	19.0
	Pancreas	0.0	7.5	14.5	16.0	16.0	12.5	2.9
	Intestine	264.7	520.0	502.0	736.5	639.0	701.0	154.0
Sucrose	Submaxillary	0.0	0.0	0.0	0.0	0.0	0.0	1.0
	Parotid	0.0	0.0	0.0	0.0	0.0	0.0	0.8
	Pancreas	0.0	0.0	0.0	0.0	0.0	0.0	0.9
	Intestine	98.4	97.2	99.6	104.4	97.2	90.0	71.3

*Values represent micrograms of glucose

(Cajory, 1933). Calf intestinal lactase is reported optimally active at pH about 5.5 (Heilskov, 1951).

In order to obtain the greatest amount of maltase and sucrase activity, the homogenates required an extration or "aging" period from twelve to twenty-four hours at room temperature; lactase activity was highest when a fresh suspension of tissue was used for analysis. Microscopic examination of homogenate revealed numerous intact cells immediately following the process of blending. It seems possible, therefore, that rodent lactase in its active form is closely associated with cell membranes. A similar relationship has been reported for hog intestinal mucosa by Hawk and his collaborators (1954), accompanied by the remark that although lactase is not usually found to be present in intestinal contents, it is detectable in fresh suspensions of ground tissues and, therefore, is assumed to exert its action at the surface of the mucosal cells or intracellularly. Heilskov (1952), on the other hand, found lactase in intestinal contents of calves and rabbits of the same order of magnitude as the activity per gram mucous membrane.

Maltase and sucrase displayed little or no activity in any of the rodent tissues assayed, during the first two hours of extraction. They attained their highest levels at approximately twelve hours and retained this activity for at least another twelve hours. Upon microscopic examination of the homogenate at the twelve-hour period a few intact cells were

visible. At the end of twenty-four hours, all cells had been disrupted.

Such observations suggest the possibility that these enzymes are present in precursor form and are activated only after extremely mild hydrolysis, following release from the cell membrane or intracellular constituents where they may or may not be tightly bound.

Although a similarly long extration period has been reported for hog intestinal maltase and sucrase, no explanation for this time factor has been offered (Hawk et al., 1954).

As is apparent from the results, great variations were found in glycosidase activities of different tissues. Following the establishment of substrate concentration, tissue dilution, incubation time, and incubation temperature necessary for salivary lactase activity, short studies were designed to determine the effect of these conditions upon pancreatic and intestinal lactase, and maltase and sucrase activity in corresponding tissues, to permit comparisons. Data obtained were not sufficiently different to warrant modification of the method established for lactase analysis.

Control Tissues

Liver, skeletal muscle, and kidney of female guinea pigs were used as control tissues in this study. Activity levels obtained suggest that lactase might be found in all organs of the guinea pig as a result of its presence in blood and tissue fluid. High maltase activity in the kidney is perplexing, and

certainly deserves further investigation. However, its absence in liver and skeletal muscle seems to rule out the possibility that large amounts of this enzyme are maintained in the blood and tissue fluids. A similar interpretation of the data might be applied to sucrase activity; its absence in liver and kidney is comforting.

Lactase

On the basis of determinations of lactase activity in tissues from the upper digestive tract of guinea pigs and rats, it was possible to establish that these rodents possess insignificant amounts of this enzyme. Lactase level in all mouse tissue, other than the intestine, is likewise probably too low to be of great importance to the animals in preparing food for absorption.

Mouse intestinal lactase is present in relatively large amounts, and although there appears to be no difference between control male and female tissues, the activity of lactase seems to be quite dependent upon gonadal hormone titer. The 50% decline in lactase activity following gonadectomy in males was not observed in females. Injections of testosterone propionate into both castrated males and females brought about a fall in activity. Conversely, the administration of estradiol benzoate enhanced lactase hydrolytic powers.

Influences of sex hormones on glycosidase activity have been reported previously. Raynaud and Rebeyrotte (1949) reported saliva from male mice to be more potent in its ability

to digest starch than saliva from female mice; castration of males inhibited this property. Harvey's studies (1957b) of tissue homogenates of mouse submaxillary and parotid glands, and pancreas, likewise showed male castration to reduce all amylase activity. Castration of females brought about similar results in the parotid gland, but the submaxillary gland and pancreas showed no significant change. When gonadectomized animals received injections of either sex hormone, amylolytic activity in all tissues rose to normal or above normal levels, except in the female parotid gland where activity declined upon the administration of testosterone propionate.

In general, mouse intestinal lactase activity followed a pattern similar to amylolytic activity described by Harvey, with the following exceptions: (1) no sex dimorphism is apparent in control animals, and (2) administration of testosterone to castrated males and females inhibits, rather than increases lactase activity in all tissues investigated.

Maltase

Analyses of guinea pig submaxillary gland, pancreas, and intestine, with respect to ability to hydrolyze maltose, indicate the existence of a sex dimorphism in the chemical nature of these tissues. Male tissues were many times more potent than were those from females. Measurement of parotid gland activity, however, revealed no significant sex difference.

Pregnancy appears to increase the production of maltase in the submaxillary gland and pancreas, to decrease synthesis

in the parotid gland, and to be without effect on intestinal mucosa. Lactation likewise reduced maltase activity in the parotid, but resulted in producing markedly high levels of maltase activity in the other tissues, the magnitudes of which closely approximate those found in male tissue.

These latter observations suggest an interplay between (a) the high titer of the hypophyseal hormone, prolactin, present in lactating females, (b) a low estrogen level, which is maintained during periods of lactation, and c) maltase synthesis. Studies on pigeons by Riddle (1938, 1940) and subsequent work by other members of his group, have shown two systemic actions of prolactin which might serve to strengthen the suspicion that such interrelationship is possible: (1) prolactin diminishes the output of gonadotropin from the pituitary gland and in this indirect manner produces atrophy of the gonads, and (2) growth of the intestinal tract and its appended structures is promoted. It seems feasible that the shifts in female guinea pig maltase activity levels observed during pregnancy and the lactation period might be ascribed to changes in estrogen levels. If such be true, than one could assume estrogen deficit to be capable of inhibiting maltase synthesis in the parotid gland, while stimulating its production by the submaxillary gland, pancreas, and intestine.

The high maltase levels recorded for normal male guinea pigs (Tables 1 and 2, Fig. 1) compared with low activity in female submaxillary, pancreatic, and intestinal tissue further

substantiates such an assumption. Values obtained upon analysis of parotid glands from control animals, however, would tend to discredit this hypothesis.

In the male submaxillary gland of the laboratory rat maltase activity is well above values obtained for this gland in the female. Such findings suggest a physiological parallel of reports of sex dimorphism in the microscopic structure of this gland. Intestinal lactase activity follows this same trend of being higher in males than in females. However, pancreatic tissue, and to a lesser extent, parotid glands, have a higher level of maltase activity in female specimens than in those obtained from males.

Since the literature contains no evidence regarding the presence of structural dimorphism in rat parotid gland, pancreas, or intestine, and in view of the limitations of this study, there is no readily available explanation for these observations.

Maltase activity in mouse tissue showed no spectacular difference in data obtained from control animals of both sexes, although intestinal maltase level in females was somewhat higher than in males.

Female mice proved to be unusually consistent in their response to gonadectomy alone, and gonadectomy followed by administration of estradiol benzoate and testosterone propionate. In each group, there was a parallel rise in submaxillary and pancreatic maltase activity to well above normal

values, as parotid and intestinal maltase activity fell significantly.

This submaxillary-pancreas and parotid-intestine counterbalance in maltase levels corresponds, in some instances to Harvey's findings (1957b) in her study of amylolytic activity in mouse submaxillary, parotid, and pancreatic tissue. Parotid amylase level decreased upon gonadectomy, while submaxillary and pancreatic activity remained unchanged. Again, when castrated females received testosterone, submaxillary and pancreas amylase levels rose to above normal levels, and parotid level decreased.

When male mice were subjected to excessive amounts of testosterone, by injection of the gonadal hormone into intact mice, submaxillary maltase activity was completely obliterated, parotid and pancreatic levels fell, but intestinal activity was substantially increased.

Gonadectomy resulted in a decline in activity in all tissues except submaxillary gland, in which the ability to hydrolyze maltose was enhanced. Injections of estradiol benzoate into castrates had no effect on intestinal maltase activity but increases in activity were found in the three accessory glands. Exogenous testosterone reduced all maltase activity levels.

These results indicate that male gonadal hormone tends to suppress maltase production, which is contrary to its influence on amylolytic activity (Harvey, 1957b), while female hormone

increased the capacity of male tissues to produce maltase, as it did for amylase.

Sucrase

Sucrase production by the submaxillary gland, parotid gland, and pancreas, was practically negligible when one considers the amount of this enzyme present in the upper portion of the small intestine from the laboratory rodents included in this study.

In general, sucrase activity determined in intestinal tissue suggests an influence of gonadal hormones on the activity of this enzyme in guinea pigs and mice, but not in rats.

In view of the slight decline in intestinal sucrase activity in pregnant guinea pigs, and the fact that activity in similar tissue from lactating females was three times higher than that demonstrated for control females, one could speculate that the synthesis of this enzyme might be affected by the presence or absence of female hormone. Estrogen levels gradually increase during gestation and diminish at parturition, at which time lactation normally begins (Turner, 1955). The fluctuations seen in the results for normal, pregnant, and lactating females and the difference between males and females make it appear fairly probable that the effect of estrogen on the presence or activity of sucrase in the small intestine of the guinea pig is inhibitory in nature.

The level of intestinal activity determined in male mice

is higher than that recovered from female intestine. Decreases in sucrase activity following castration in males correlate well with results obtained in lactase and maltase studies, and with the fall in amylolytic activity reported by Harvey (1957b) for submaxillary, parotid, and pancreatic tissues. Although amylase levels in these three glands equalled or surpassed control levels when castration was followed by replacement therapy, intestinal sucrase, lactase, and maltase remained below normal levels under such conditions.

Gonadectomy in females was followed by a confounding increase in intestinal sucrase activity, and this activity rose even higher upon injections of female gonadal hormone, while administration of testosterone was without affect. In view of these findings, the author doubts whether the sex hormone level, as such, determines to any marked degree the ability of female intestinal tissue to hydrolyze sucrose.

Influence of Free HCl on Glycosidases

Mellanby and Woolley (1915) hold that dog pancreatic juice per se contains only one carbohydrate enzyme, namely, amylase, and that it is the presence of free acid which enables this secretion to hydrolyze maltose to dextrose. They report that pancreatic juice alone has no action on maltose and show that the degree of hydrolysis of maltose by pancreatic juice in the presence of HCl progressively increases with the amount of acid added to the solution. Addition of HCl only to maltose produced no hydrolysis. They

further state that pancreatic juice alone, or in the presence of neutral salts (NaCl or $CaCl_2$), acids, or alkalies, has no action on lactose or sucrose.

Although tissue homogenates rather than secretions were used in my experiments, it is believed safe to assume that the laboratory rodent, unlike Mellanby's dog, does have pancreatic tissue which produces, and presumably secretes a fair amount of maltase as well as some lactase and sucrase.

The experiments reported here which deal with the influence of free HCl on the three glycosidases, confirm the observations of Mellanby and Woolley to some extent. The ability of female guinea pig homogenates to hydrolyze lactose remains relatively unaffected by the presence of free acid. Sucrase is completely inactivated by free acid in all tissues except the intestine where activity displays a slight increase above control values but this increase remains stable at all concentrations. The most dramatic results were obtained when maltose was the substrate under consideration. Not only was pancreatic maltase activity increased, but the submaxillary as well as the intestinal homogenates displayed at least a five-fold increase above control tissues in their ability to hydrolyze maltose. Parotid maltase, on the other hand, suffered approximately 50% inactivation at concentrations of free acid greater than 0.007%.

In Hawk, Oser and Summerson (1954) there is mention that salivary amylase is destroyed when free acid concentrations are above 0.0005%.

CHAPTER IV

SUMMARY AND CONCLUSIONS

Histologic Studies

1. With the salivary glands of the laboratory mouse as prototypes or models, this survey of the microscopic structures of salivary glands of twelve species of rodents revealed a high degree of variation in submaxillary gland structure with at least one distinguishing and differentiating feature per species. These differences were manifested by (a) presence of intercalated ducts or terminal tubules as the duct system terminates, (b) variation in size and in kind of acini -- one gland may be composed of a single cell type, some may have two types of acinar cells, and still others have three, indicating a change in function, influenced perhaps by habits and habitats.

2. Parotid and sublingual tissue, however, when available, showed a strong general resemblance in the histology of the respective glands.

3. Sex-dimorphic characters have been recognized in the submaxillary glands of three species of rodents other than laboratory mice. Terminal tubule diameter and granulation in the cells surrounding the terminal tubules are the dimorphic

features noted in the grasshopper mouse (Onychomys leucogaster) and pack rat (Neotoma floridana). Both constituents are larger in the male than in the female glands. Thus, the same dimorphic pattern is present in the submaxillary glands of these field rodents, as is found in their laboratory relatives, but the distinction is not nearly so striking.

The laboratory guinea pig (Cavia porcellus) is the third species in which a sex difference was noted. The dimorphic character in this instance is the presence of serous demilune cells which are scattered lightly among serous or serozymogenic acinar cells in the female but are not observed in the male.

Enzymatic Studies

1. A colorimetric method for estimation of lactase, maltase, and sucrase activity of animal tissues is described.
2. Optimum pH ranges for animal glycosidases included in these studies are: lactase=4.5-5.2; maltase=5.8-7.5; and sucrase=5.5-7.5. Female guinea pig submaxillary and parotid glands, pancreas, and intestine were utilized in these determinations.
3. Liver, skeletal muscle, and kidney from female guinea pigs were used as control tissues. Lactase activity was found in all control homogenates; maltase activity was present in kidney; sucrase activity was noted in skeletal muscle.
4. Lactase, maltase, and sucrase were present to a lesser or greater degree in submaxillary, parotid, pancreatic, and

intestinal tissue. Laboratory guinea pigs, rats, and mice were the animal employed in this study, and the greatest amount of activity determined for each enzyme was found in intestinal tissue from each group.

5. Lactase activity level was negligible in all tissues other than mouse intestine where it appears quite dependent upon shifts in gonadal hormone titer. Gonadectomy in males resulted in a 50% decline in lactase activity, but such procedure was without effect in females. Testosterone reduced intestinal activity in castrated males and females; estradiol enhanced lactase activity.

6. Male guinea pig tissues proved to be many times more potent in their ability to hydrolyze maltose than female tissues. Analysis of tissues from pregnant and lactating females suggest a possible interplay between high protactin titer, low estrogen level, and maltase synthesis. Estrogens are believed to be capable of inhibiting maltase production in the submaxillary gland, pancreas, and intestine.

7. A physiological parallel to structural sex dimorphism in the laboratory rat submaxillary gland was suggested by the high level of maltase activity in the male gland as opposed to the low level recorded for the female rat.

8. Results of ovariectomy alone was similar to the results of ovariectomy followed by injections of estrogens or androgens in mice. In each group of females a rise in submaxillary and pancreatic maltase activity occurred as parotid and intestinal

levels decreased.

9. Gonadectomy in male mice produced a slight decrease in maltase activity of all tissues with the exception of the submaxillary gland, in which activity was found to rise. Injections of female hormone resulted in an increase in all maltase activity other than that of the intestine which remained unchanged; exogenous male hormone had an overall inhibitory effect.

10. Only intestinal tissue is capable of hydrolyzing any significant amount of sucrose.

11. A physiological sex dimorphism was uncovered in the upper intestine of the guinea pig when this tissue was exposed to a sucrose substrate. Intestinal sucrase activity was greater in normal males than in normal females.

12. Lactating guinea pig intestinal tissue was practically as efficacious in hydrolyzing sucrase as was the control male tissue.

13. Since estrogens are reportedly at low levels during periods of lactation, it follows from (11) and (12) that hydrolysis of sucrose by guivea pig intestinal tissue may be suppressed by the presence of the female sex hormone.

14. Approximately equal amounts of sucrase activity were determined in the intestines of male and female rats; male mice, however, has a higher intestinal sucrase level than did the females.

15. Results obtained from experiments involving gonadectomies

and replacement therapy stifle any attempt to correlate an increase in hydrolysis of sucrose with the presence of male androgens. Estradiol benzoate injections into gonadectomized males and females elicited highest sucrase activity in both sexes.

16. The addition of HCl to homogenates of female guinea pig submaxillary glands, pancreas, and intestine greatly increased the ability of these tissues to hydrolyze maltose to glucose. The relative quantities of the monosaccharide formed was a function of the hydrogen ion concentration within the reacting medium. The greater the concentration of acid the greater was the quantity of glucose formed. The optimal quantity of hydrochloric acid under the conditions of these experiments, was the same for all three tissues, namely 0.015%.

Levels of lactase and sucrase activity remained relatively unaltered by the addition of HCl.

LITERATURE CITED

Bensley, Robert R. 1908. Observations on the salivary glands of mammals. Anat. Rec. 2:105-107.

Cajory, F. A. 1935. Intestinal lactase. J. Biol. Chem., 109:159.

Di Fiore, Mariano S. H. 1958. An atlas of human histology. Philadelphia: Lea & Febiger.

Fekete, E. 1941. Histology. In: The biology of the laboratory mouse, chap iii. Phila: Blakiston Co.

Feyel-Cabanes, T. 1947. L'action du cholesterol sur la glande tubuleuse de la sous-maxillaire de la souris male castree. Compt. rend. Soc. de biol., 141:331.

Frantz, M. J., and Kirschbaum, A. 1949. Submaxillary gland histology as an indicator of androgenic secretion in the mouse. Anat. Rec., Suppl., 103:538 (abstr).

Hall, E. Raymond, and Kelson, K. R. 1959. The mammals of North America. New York: Ronald Press Co.

Harvey, Harriet. 1952. Sexual dimorphism of submaxillary glands in mice in relation to reproductive maturity and sex hormones. Physiological Zoology, 25:205-222.

_____. 1957a. A comparative study of salivary gland and pancreatic amylolytic activity. The Anatomical Record. 128(3):560 (abstr).

_____. 1957b. The effect of sex hormones on the amylolytic activity of submaxillary, parotid, and pancreas of the laboratory mouse. Ibid., 128(3): 561 (abstr).

Hawk, P. B., Oser, B. L., and Summerson, W. H. 1954. Practical physiological chemistry. 15th ed. New York: The Blakiston Co., Inc.

Heilskov, N. S. C. 1951. Studies on animal lactase. I. Lactase activity determination. Acta physiol. Scand., 22:267-276.

_____. 1952. Studies on animal lactase. II. Distribution in some of the glands of the digestive tract. Ibid., 23:84-89.

Honda, Rikita. 1927. The general functional significance of the mitochondria in the submaxillary gland of the adult albino rat. Anatomical Record. 34:301-312.

Lacassagne, A. 1940a. Dimorphisme sexuel de la glande sous-maxillaire chez la souris. Compt. rend. Soc. de biol., 133:180-181.

_____. 1940b. Mesure de l'action des hormones sexuelles sur la glande sous-maxillaire de la souris. Ibid., 133:227-229.

_____. 1940c. Reactions de la glande sous-maxillaire a l'hormone male, chez la souris et le rat. Ibid., 133:533-540.

McManus, J. F. A. 1946. Histological demonstration of mucin after periodic acid. Nature. 158:202.

Mellanby, John, and Woolley, V. J. 1915. Part V. The carbohydrate ferments of pancreatic juice. J. Physiol., 49:246-264.

Raynaud, J., and Rebeyrotte, P. 1949. Compt. rend. de l'Acad. d. Sci., 228:1061.

Riddle, O. 1938. Prolactin, a product of the anterior pituitary and the part it plays in vital processes. Sci. Monthly, 47:97-113.

Stormont, D. L. 1932. The salivary glands. In: E. V. Cowdry: Special cytology, chap vi. New York: Paul B. Hoeber.

Turner, C. D. 1955. General endocrinology. Phila: W. B. Saunders Co.

PLATE I

SUBMAXILLARY GLAND OF LABORATORY MOUSE (*Mus musculus*)

Fig. 1. Male. Number and size of terminal tubules, in relation to acini, is notable. Nuclei of tubule cells are obliterated by concentration of large, coarse granules. x 470.

Fig. 2. Female. Peripheral terminal tubules, at right center, show coarse granulation and tubule diameter to be less than that of the male (Pl. 1, Fig. 1). Prevalence of acinar tissue should be noted. x 470.

PLATE I



1.



2.

PLATE II

SUBMAXILLARY GLAND OF WOODCHUCK (*Marmota monax*)

Fig. 3. Male. Cells surrounding prominent tubules of the terminal segment of intralobular ducts have central nuclei with variable staining properties. Note several cells with chromophobic material surrounding nuclei, producing a "halo" effect. Pyramidal acinar cells have large oval dense nuclei, and fine cytoplasmic granules. x 676.

PLATE II

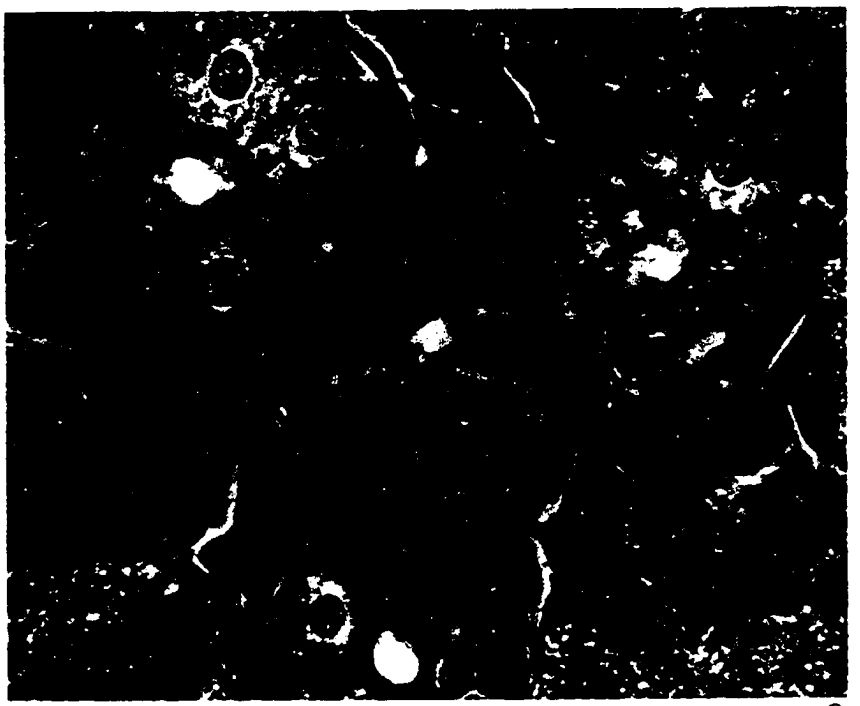

3.

PLATE III

SUBMAXILLARY GLAND OF FOX SQUIRREL (*Sciurus niger*)

Fig. 4. Male. Large central nuclei and basal striations in cells of tubules accentuate lack of coarse granulation. Serous acini are numerous. x 470.

Fig. 5. Female. This photomicrograph shows more clearly than Fig. 4, described above, the various staining properties of cytoplasmic granules in acinar cells, which are seen as dark and light areas in the lower part of the field. No sex difference is noted in this species. x 470.

PLATE III



4.



5.

PLATE IV

SUBMAXILLARY GLAND OF POCKET GOPHER (Geomys bursarius)

Fig. 6. Male. Tubules of the terminal segment of intralobular ducts are notably small, and contain fine granules. Serous acinar cells are prodominant throughout the gland, but occasional mucous cells (not shown here) are also present. x 676.

SUBMAXILLARY GLAND OF POCKET MOUSE (Perognathus flavescens)

Fig. 7. Male. Columnar cells surrounding terminal end of intralobular duct have basal striations, sub-central nuclei, and pale cytoplasm in area between nucleus and apex. Chromophobic secretory material is seen within large lumen. Dark and light areas in acini surrounding duct are due to variation in staining properties of serous acinar cells. x 676.

PLATE IV



6.



7.

PLATE V

SUBMAXILLARY GLAND OF BEAVER (*Castor canadensis*)

Fig. 8. Male. Two of the three types of acinar cell present in this gland are clearly seen. The extremely large pale mucous cell, capped by serous demilune cells (only part of which are seen at the bottom, just left of the center) is evident. The remainder of the field is occupied by serous acinar cells which are predominant throughout the gland. x 676.

PLATE V

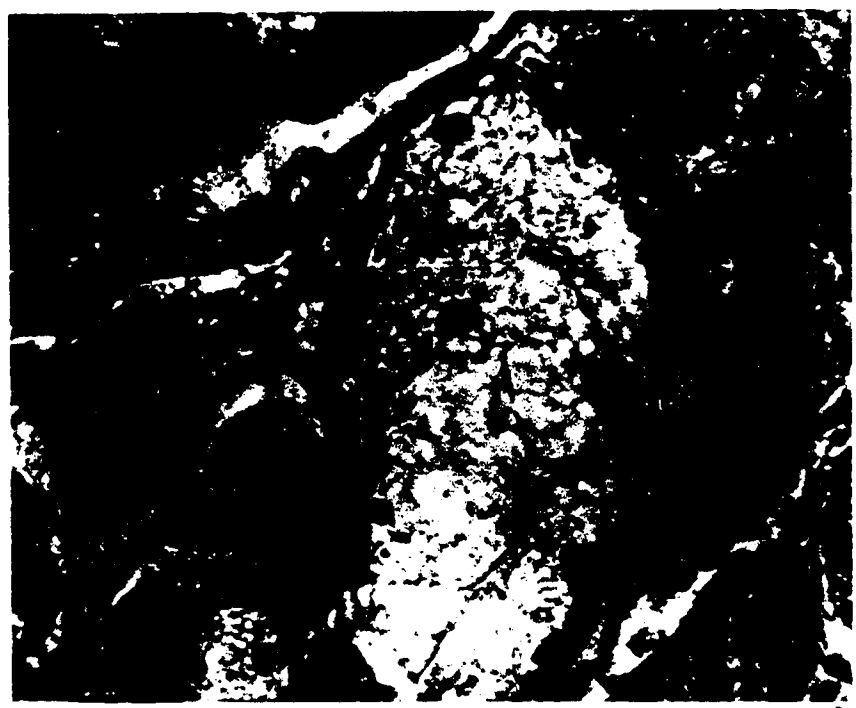

8.

PLATE VI

SUBMAXILLARY GLAND OF BRUSH MOUSE (*Peromyscus boylii*)

Fig. 9. Male. Intralobular striated ducts of small diameter contain no coarse granulation. Intercalary duct of low cuboidal cells is seen leading into the central tubule from the left. Remainder of photograph is occupied by serous acinar cells. x 676.

Fig. 10. Female. Difference in the staining properties and concentration of granules present in acinar cells is indicated. Presence of obvious small lumina (not clearly visible here) within groups of these cells which stain in bizarre fashion suggests an unusual acinous tubule. x 676.

PLATE VI



9

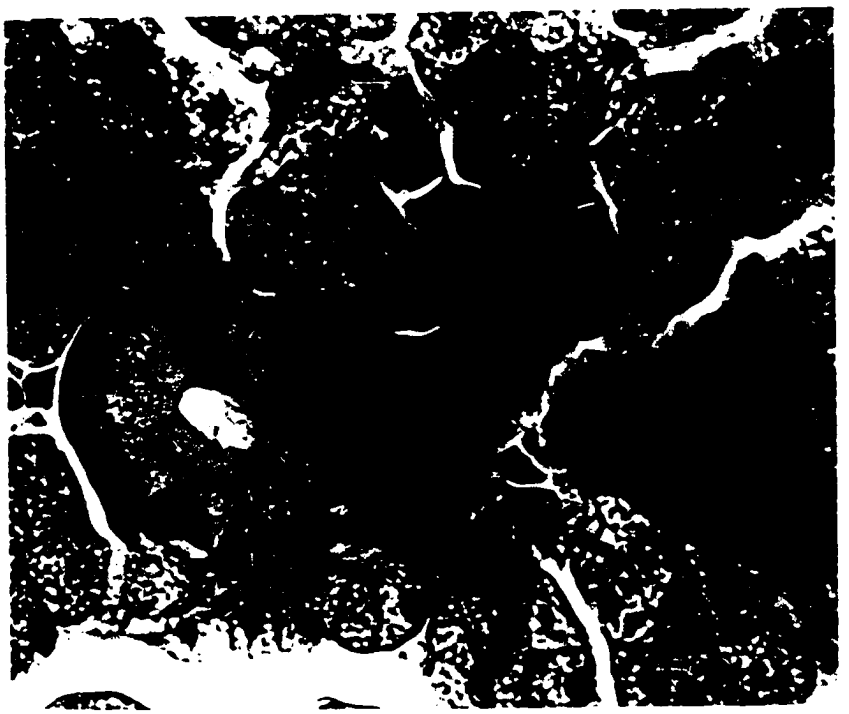

10.

--

PLATE VII

SUBMAXILLARY GLAND OF GRASSHOPPER MOUSE

(*Onychomys leucogaster*)

Fig. 11. Male. Opaque acini are distinct with prominent round basal nuclei. Variation in acinar cell staining properties is indicated. Tubule in upper part of field, at left center, displays large diameter, coarse granulation. x 676.

Fig. 12. Female. In the lower part of the field, right center, are two peripheral terminal tubules. Small tubule size, cell granulation, and large round nuclei are apparent. Serous acinar cells show close resemblance to those of the male of this species, although these cells do appear to be smaller in the female. x 676.

PLATE VII



11.



12.

PLATE VIII

SUBMAXILLARY GLAND OF COTTON RAT (Sigmodon hispidus)

Fig. 13. Male. Small granules in cells of terminal tubules are obvious. The tubule in the upper part of the field shows that in cross-section the tubule cell nucleus is central and basal striations are visible. Serous acini are also seen. x 676

Fig. 14. Female. Two tubules in this field show granulation to be less than in male cotton rat. Acinar cells with prominent basal opaque nuclei are apparent. x 676.

PLATE VIII

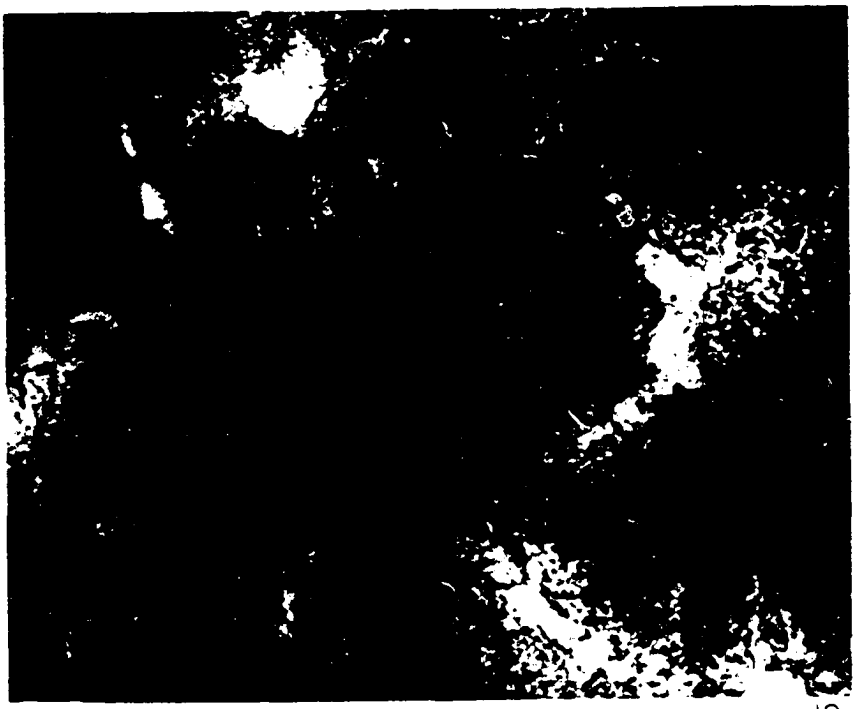

13.



14.

PLATE IX

SUBMAXILLARY GLAND OF PACK RAT (Neotoma floridana)

Fig. 15. Male. In spite of prominent granulation present within the large tubule cells, nuclei and basal striations are in evidence. Well defined acinar cells occupy the remainder of the field. x 470.

Fig. 16. Female. Tubule diameter is small, granulation within tubule cell is scarce, and acinar cells, which appear smaller than those of the male (Pl. IX, Fig. 15), are neither well defined nor constant in their staining properties. x 470.

PLATE IX

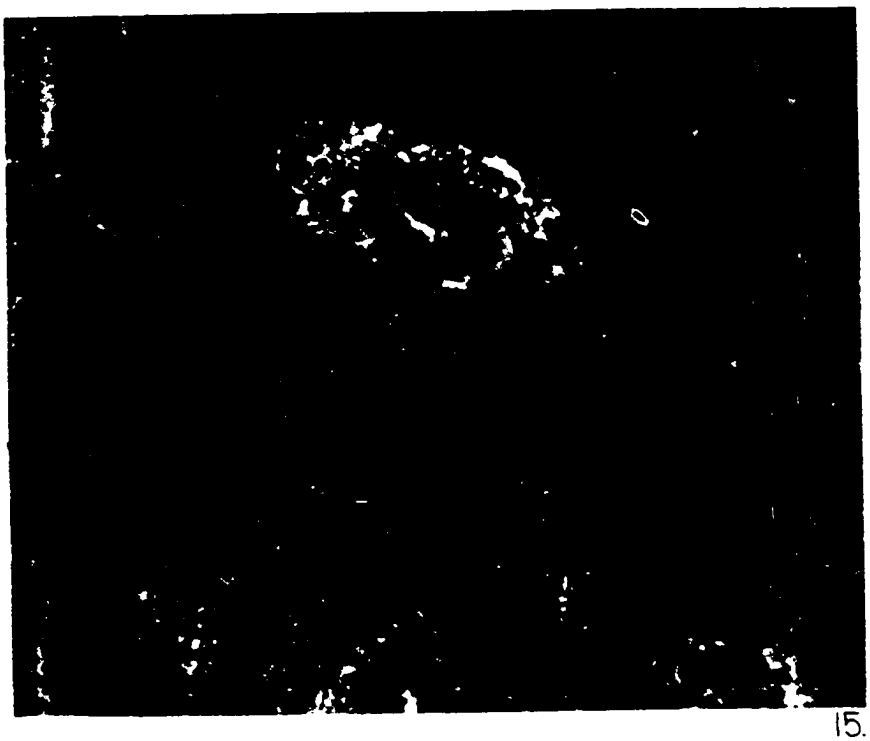

15.



16.

PLATE X

SUBMAXILLARY GLAND OF MUSKRAT (*Ondatra zibethica*)

Fig. 17. Male. Gland is composed chiefly of long, convoluted terminal tubules, the cells of which are filled with large, coarse granules. Acinar cells are serous with oval basal nuclei and fine cytoplasmic granules. x 676.

PLATE X



17.

PLATE XI

SUBMAXILLARY GLAND OF GUINEA PIG (*Cavia porcellus*)

Fig. 18. Male. In the lower right hand portion of this field is an area which was occupied by fat cells. Unfortunately the nuclei of these vacuolated cells do not show well in this section. Tubule cells are conspicuously free from coarse granulation. Typical serous cells are small and well-granulated. x 470

Fig. 19. Female. Grouping of intralobular ducts is represented in the right side of the field. Serous acinar cells show slight variation in amount of fine granulation. Mucous cells, which have so far been found scattered only in normal female tissue, do not appear in this section. x 470.

PLATE XI



18.



19.