THE UNIVERSITY OF OKLAHOMA

GRADUATE COLLEGE

AN ANATOMICAL AND RADIOLOGICAL INVESTIGATION OF THE FIRST TWO COSTAL CARTILAGES AND THEIR ARTICULATIONS

A DISSERTATION

SUBMITTED TO THE GRADUATE FACULTY

in partial fulfillment of the requirements for the

degree of

DOCTOR OF PHILOSOPHY

BY

JOHN B. CHRISTENSEN

Oklahoma City, Oklahoma

1958

Downloaded from SHAREOK. Persistent Handle URL: https://hdl.handle.net/11244/1370

AN ANATOMICAL AND RADIOLOGICAL INVESTIGATION OF THE FIRST TWO COSTAL CARTILAGES AND THEIR ARTICULATIONS

APPROVED BY

Ernest Kaelber

Walter Fall

John E. Allison

Kenneth K. Faulkner

Wiley T. Beaver

DISSERTATION COMMITTEE

ACKNOWLEDGMENT

The author takes this opportunity to extend his appreciation and gratitude to Dr. Ernest Lachman, for suggesting the problem and for his cooperation, counsel, and invaluable criticism during the course of this investigation.

Acknowledgment of indebtedness is also made to Dr. Kenneth Faulkner for his timely suggestions, to Dr. Allan Katzberg and Dr. Harold Muchmore for their assistance in preparation of the photomicrographs, and to other members of the faculty of the University of Oklahoma Medical Center.

Appreciation is also expressed to the Department of Anatomy for provision of facilities, equipment and materials, and to the University of Oklahoma for a Graduate Assistantship under which this work was done.

TABLE OF CONTENTS

	Page
LIST OF TABLES	v
LIST OF ILLUSTRATIONS	vi
Chapter	
I. INTRODUCTION	1
II. MATERIAL AND METHODS	11
III. RESULTS	25
IV. DISCUSSION	98
V. SUMMARY AND CONCLUSIONS	109
BIBLIOGRAPHY	113

LIST OF TABLES

Table		Page
1.	Formula for Buffered Formalin Solution	11
2.	Formula for Harris' Hematoxylin Stain	19
3.	The Intra-articular Ligament in the Second Sterno-chondral Articulation as Revealed by Gross Anatomical Study	28
4.	The Second Sterno-chondral Articulation and the Manubrio-sternal Articulation as Revealed by Gross Anatomical Study	30
5.	Location of Calcification in the First Costal Cartilage as Evidenced by Gross Radiographic Study	40
6.	Location of Calcification in the Second Costal Cartilage as Evidenced by Gross Radiographic Study	42
7.	Pattern of Calcification in the First Costal Cartilage as Evidenced by Gross Radiographic Study	44
8.	Pattern of Calcification in the Second Costal Cartilage as Evidenced by Gross Radiographic Study	46
9.	Percentage of Calcification and Density of the First Costal Cartilage as Evidenced by Gross Radiographic Study	47
10.	Percentage of Calcification and Density of the Second Costal Cartilage as Evidenced by Gross Radiographic Study	48

LIST OF ILLUSTRATIONS

Figure		Page
1.	Diagram of Specimen Taken at Autopsy	13
2.	Diagram Illustrating Variation in Position and Extent of the Intra-articular Ligament in the Second Sterno-chondral Articulation	27
3.	Macroradiographs of Region Studied	35
4.	Macroradiographs Illustrating Locations and Patterns of Calcification in the First and Second Cartilages	37
5.	Photomicrograph of Coronal Section of Sterno-chondral Junction and Manubrio-sternal Articulation of Newborn	51
6.	Photomicrograph of Coronal Section of Sterno-chondral Junction of Newborn	51
7.	Photomicrograph of Coronal Section of Costal Cartilage of Newborn	54
8.	Photomicrograph of Coronal Section of Sterno-chondral Cavity of Newborn	54
9.	Photomicrograph of Coronal Section of Costo-chondral Junction of Newborn	57
10.	Photomicrograph of Coronal Section of Rib of Newborn	57
11.	Photomicrograph of Coronal Section of Manubrio-sternal Articulation	59
12.	Photomicrograph of Coronal Section of Manubrio-sternal Articulation	59
13.	Photomicrograph of Coronal Section of Sterno-chondral Articulation of Adult	62
14.	Photomicrograph of Coronal Section of Articular Surface of Sterno-chondral Articulation of Adult	62

LIST OF ILLUSTRATIONS - continued

Figure		Page
15.	Photomicrograph of Coronal Section of Costal Cartilage at Sterno-chondral Articulation	65
16.	Photomicrograph of Coronal Section of Costal Cartilage	65
17.	Photomicrograph of Coronal Section of Sterno-chondral Cavity	67
18.	Photomicrograph of Coronal Section of Costal Cartilage	67
19.	Photomicrograph of Coronal Section of Costal Cartilage	70
20.	Photomicrograph of Coronal Section of Costal Cartilage	70
21.	Photomicrograph of Coronal Section of Costal Cartilage	72
22.	Photomicrograph of Coronal Section of Costal Cartilage	72
23.	Photomicrograph of Coronal Section of Sterno-chondral Articulation	75
24.	Photomicrograph of Coronal Section of Manubrio-sternal Articulation	75
25.	Photomicrograph of Coronal Section of Manubrio-sternal Articulation	77
26.	Microradiograph of Coronal Section of Costo-chondral Junction of Newborn	80
27.	Photomicrograph of Coronal Section of Costo-chondral Junction of Newborn	80
28.	Microradiograph of Coronal Section of Rib of Newborn	83
29.	Photomicrograph of Coronal Section of Rib of Newborn	83
30.	Microradiograph of Cross Section of Adult Rib	86
31.	Microradiograph of Cross Section of Adult Rib	86
32.	Microradiograph of Cross Section of Adult Rib	88
33.	Microradiograph of Cross Section of Adult Rib	88
34.	Microradiograph of Coronal Section of Sternum	91

LIST OF ILLUSTRATIONS - continued

Figure		Page
35.	Microradiograph of Coronal Section of Sternum	91
36.	Microradiograph of Coronal Section of Costal Cartilage ...	94
37.	Microradiograph of Coronal Section of Costal Cartilage ...	94
38.	Microradiograph of Coronal Section of Costal Cartilage ...	96

AN ANATOMICAL AND RADIOLOGICAL INVESTIGATION OF THE FIRST TWO COSTAL CARTILAGES AND THEIR ARTICULATIONS

CHAPTER I

INTRODUCTION

The anatomy of the sterno-chondral junctions and the costal cartilages has been investigated extensively. These regions have been studied as to their gross anatomy (Gladstone and Wakely, 1932; Ikeda, 1932; Trotter, 1934; Gray and Gardner, 1943; Ashley, 1954), their developmental changes (Pohlmann, 1933; Hass, 1943; Noback, 1944; Gershon-Cohen and Delbridge, 1945; Vastine, Vastine, and Arango, 1948), and their vascular supply (Linberg, 1925; Nikolajew, 1927; Hurrell, 1935). The x-ray pattern of both joints and calcification of cartilage has also been analyzed (Riebel, 1929; Michelson, 1934; Falconer, 1938; King, 1939; Youngstrom, 1953).

The sterno-chondral articulations, with the exception of the first, are freely movable and therefore can be classified as diarthroses (Gray, 1954). The costal cartilages, interposed between sternum and ribs, participate in the formation of the sterno-chondral joints. These joints are strengthened anteriorly and posteriorly by a series of fibrous fasciculi, the radiate sterno-costal ligaments (Cunningham, 1951). The fasciculi spread fanwise over the anterior and posterior surfaces of the

sternum. Laterally the costal cartilages are received into cup-like depressions of the ribs and form the costo-chondral junctions. The perichondrium of each costal cartilage is continuous laterally as the periosteum of the rib. The fusion of this cartilage with the rib occurs without any tissue or space being interposed and thus it forms a true synchondrosis (Morris, 1953).

The presence of sterno-chondral joint cavities is variable, being found most constantly in the second articulation. When cavities are found in the adult, there commonly occurs a transverse intra-articular fibrocartilaginous ligament. This ligament, located in various parts of the cavity, fluctuates in its extent from being vestigial in nature to filling the entire cavity. Henle (1871) found the intra-articular ligament to be variable in position, being sometimes higher than the horizontal midplane of the joint, sometimes lower, and sometimes lacking entirely. Tschaussow (1891), in a study of eighty-nine cadavers, found this ligament most constantly present in the second joint, occurring in eighty-six bodies. Musgrove (1892) did not find such a high incidence. In a study of eighteen cadavers, he observed the second joint on the right side divided by the intra-articular ligament into two cavities eleven times. On the left side he found two cavities in ten bodies. Bryce (1915) confirmed the findings of Musgrove. He described the intra-articular ligament as occurring in the second cavity in sixty per cent of the bodies studied. Hayner (1935) believed the ligament to be an actual extension of the fibrocartilage uniting the manubrium and body of the sternum. In the adult, Gray and Gardner (1943) found that the cavities were crossed

by strands or that one cavity was absent in fifty-one per cent of the specimens studied. Cavities above and below the intra-articular ligament were seen in thirty per cent of their cases. Eleven per cent had no cavity at the second costo-chondral articulation.

Pohlmann (1932) maintained that no cavities were present in embryonic sterno-chondral joints, and asserted that in all embryos there was a direct cartilaginous union of the sternal bar with the costal cartilages. Tschaussow (1891) reported that cavities were present at the fifth fetal month. Gray and Gardner (1943) found cavities present in the fetus at three and one-half months. Williams (1957) found well-formed cavities present in the second sterno-chondral joint at birth in the human specimens which he studied.

Trotter (1934) studied the movement of the joint at the manubrio-sternal articulation in eight hundred and seventy-seven cadavers. She determined the mobility at this articulation by manipulation and subsequent gross inspection. In individuals beyond thirty years of age she noted wide variation with no indication of an increase in synostosis with increase in age. The incidence of synostosis present in colored males, colored females, and white males was 9.8 per cent, 10.0 per cent, and 11.5 per cent respectively. In the group of white females she found 26.7 per cent showing synostosis. Ashley (1954) reported similar findings on fourteen hundred specimens except for a significant difference in white females. Here the incidence in white females was approximately ten per cent. He did not consider the synostosis to be a senile change. It was equally common in all ten year age groups after the age of thirty. He

believed the synostosis of this articulation to be of two different types. The first, which was termed "matrical", indicated obliteration during early life of a primary cartilaginous joint. This change he presumed to be a normal growth occurrence. The second change, he considered a "sclerotic" synostosis, resulting from obliteration during late adult life. This change he presumed to be pathological in nature.

Hurrell (1935), studying the vascularization of cartilage, compared the connective tissue elements present in the vascular canals within the cartilage with the deep perichondral connective tissue and concluded that the canals increase in extent by chondrolysis and that they do so in response to the demand of deeper cells for nutrition. Linberg (1925) followed the development of vessels in the costal cartilage in the human from five months to ninety-seven years of age. He found vessels present at the end of the first year. These pierced the perichondrium and were concentrated in the superficial layers of the costal cartilage. From the fifth to the tenth year the vessels had reached the middle of the cartilage mass. Later one or two frequently interrupted canals appeared in the long axis of the cartilage. The canals contained three or four thin-walled vessels surrounded by connective tissue. These vessels anastomosed with vessels of the perichondrium. They entered the cartilage from the superior and inferior surfaces along its entire extent, and progressed laterally to medially toward the sternal end of the cartilage. From the twentieth year marrow elements were present in these central canals. Towards the sixtieth year the marrow cells atrophied and the canals appeared to be filled with a viscous mass. The number of

canals diminished with age.

Haas (1914), in a histological study of the costo-chondral junction, observed the perichondrium at the junction to be continuous with the periosteum. He described the perichondrium, finding it impossible to discern the point of separation of perichondrium and cartilage. Gray and Gardner (1943) in studying the sterno-chondral articulation stated the articular surfaces of the sternum were fibrocartilaginous in nature. They discovered hyaline cartilage between this fibrocartilage and the compact bone of the sternum. Compact bone was lacking in some instances. The fibrocartilage was described as acellular, amorphic, and quite acidophilic. Strands of tissue crossing the cavity were also found to be fibrocartilaginous in nature. Ossification of the sternal extremity of the costal cartilage did not involve the fibrocartilage. Hass (1943) discovered an increase in the matrix-to-cell ratio in costal cartilage as calcification became evident. Initial granular deposits of calcium which were fibrous in character occurred in the long axis of the cartilage. Globular, non-descript, discontinuous, acellular clumps of abnormal matrix increased with age. In the amorphic mass, bone may appear to a greater or lesser degree. Organization was unlike that encountered in normal endochondral ossification. Ossification changes continued long after the closure of epiphyseal lines.

Calcific changes of the costal cartilages have probably been observed since the first post-mortem examination. The costal cartilages are unique in that these processes continue throughout life. In the radiologic literature the terms ossification and calcification have been

used interchangeably. Heinrich (1941) clarified this by explaining that both of these terms designate the appearance of otherwise radiographically invisible structures. They do not necessarily differentiate between different types of histological structures. In this thesis the terms used by individual investigators are retained in reporting their work. The term calcification will be used here to denote grossly visible changes.

Böhmig (1928) described calcification of the first costal cartilage noting a pattern which gave the appearance of an intermediate piece of bone with marginal spurs. Rist, Gally, and Trocme (1928), in a study of five hundred x-ray films, stated that ossification began in the male at seventeen years of age and in the female at nineteen years of age. From their study they concluded that the first cartilage was ossified in almost all individuals by the age of thirty-five in the male and forty-five in the female. Ernst (1929) outlined six ossification patterns for the first costal cartilage and considered them to be stages of a continuous process rather than individual types. According to this author calcification began at the costal surface and at the lower border of the cartilage and progressed medially and superiorly. Riebel (1929) stated that ossification of the first costal cartilage in all individuals had occurred by the age of thirty, and that this took place earlier in the male. Extensive ossification was also more common in the male. Köhler (1930) and Köhler and Zimmer (1956) stated that calcification started at the nineteenth year of age in the first costal cartilage and at the twenty-fourth year of age in the other cartilages. A sequence in

cartilages two to twelve was described in which calcification progressed inferiorly with the tenth cartilage showing more advanced calcification than the sixth which, in turn, showed greater involvement than the second. In addition they considered calcification in cartilages two to twelve to be quite separate from the process occurring in the first cartilage. They maintained that calcification began at the costo-chondral junction and at the lower border of the cartilage, thence progressing superiorly and medially. In the age group of thirty to thirty-five the first cartilage was calcified in ninety-five to ninety-nine per cent of the cases. In the forty to fifty year age group it was present in one hundred per cent of the cases. They believed calcification of costal cartilages to be a normal physiological process, with age being only of minor significance and concluded that long standing dietary calcium deficiency had an accelerating effect upon calcification. Michelson (1934) in an investigation of over five thousand chest x-rays, found calcification beginning at a younger age than Köhler and Riebel. It started at age sixteen in the male and continued throughout life. Most authors agree that calcification begins earlier and is more extensive in the male. Falconer (1938), in contrast to this, noted that the lowest age group for the start of calcification in the male was thirty-three years and in the female, forty-five years. King (1939) generally agreed with Köhler that calcification was rare before the age of twenty. Heinrich (1941), reported that the pattern of change in the first cartilage began at the costal facet, progressed along the lower border to the sternal facet and thence to the superior border, to form a ring of calcification.

The central region filled in thereafter to constitute an ossified intermediate piece of bone with uncalcified chasms at the costo-chondral and sterno-chondral junctions. Exostoses originated on the inferior border of the cartilage at these junctions and described an arc with the intermediate piece of cartilage. He reported that ossification never reached the sternum. No central ossification was detected until the inferior and superior borders had become involved. Several patterns were demonstrated, but all were considered to be part of a continuous process. Twice as many males as females showed calcification from the third to the sixth decade. One hundred per cent of the males were involved by the sixth decade. In females one hundred per cent incidence was not reached until the eighth decade. Characteristic patterns and sites of calcification were not obvious in cartilages two to twelve. Heinrich (1941), did not confirm Köhler's findings in regard to the sequence of changes in cartilages two to twelve. Total calcification was rarely seen. Brailsford (1948) agreed with King in describing ossification as rarely starting before the age of twenty. He stated that, in the first cartilage, ossification commenced as irregular vertical bands which gradually fused. The costal and sternal extremities were the last to ossify. He pointed out that the ossification process of costal cartilages began earlier and progressed more rapidly in the male, in contradistinction to the process of skeletal ossification which always was more advanced in the female. Fischer (1955) in a study of twenty-two hundred x-rays declared that calcification in the two sexes appeared in different forms. He maintained that in the male the predominant sites of calcification were at the

superior and inferior margins of the costal cartilage. However, in the third decade no typical pattern was evident. At this age different elements of his basic classification were seen in combination. In the female, calcification occurred most prevalently in the central portion of the cartilage in the form of spicules and dense spherical areas. From the sixth decade, the spicules coalesced to form central blocks. This became the predominant pattern in the female in advanced age.

Huyssen (1925) indicated that the extent of general calcification of costal cartilages may be usefully employed as an index of the degree of arteriosclerosis. He found that in spite of wide variations there was an interrelation of the two conditions, and that calcification of cartilage might be taken as an indication of the state of the vessels. In disagreement, Köhler and Zimmer (1956) found no demonstrable parallel of arteriosclerosis and calcification of costal cartilages.

Early investigators suggested that precocious ossifications of the first cartilage encroaching on the apex of the lung, was a cause of apical tuberculosis, and an etiological factor in emphysema. Wernscheid (1923), in analyzing six hundred and fifty-one cases of tuberculous patients, found that ossification occurred as early as nine years of age. Seventy-three per cent of his cases showed ossification, all of which had hilar involvement. He felt that ossification occurred as a sequela of tuberculosis and that this, by immobilizing the ribs, was a favorable factor in the cure of the disease. The findings of Bezancon, Jaquelin, and Tribout (1925) are in disagreement with the work of Wernscheid. In one hundred and five cases of tuberculous patients, they found ossification in only nine per cent of their cases. Rist, Gally, and Trocme

(1928) in a study of five hundred x-ray films found no relationship between ossification and tuberculosis. King (1939) felt that calcification was unrelated to pathology. He considered it to be a normal physiological process -- a vital response of cartilaginous tissue to strain and stress imposed on the thoracic cage.

This dissertation is concerned primarily with the region of the manubrio-sternal articulation, the costal cartilage of the first rib, the sterno-chondral articulation, and the costal cartilage and costo-chondral junction of the second rib. Their gross anatomy, microscopic anatomy, gross radiographic anatomy, and microradiographic anatomy will be reported. Where applicable a comparison will be made of the morphology as depicted by these several methods of inquiry.

CHAPTER II

MATERIALS AND METHODS

Specimens were obtained from the dissecting room cadavers of the Anatomy Department of the University of Oklahoma Medical Center, and from autopsy cases at the University Hospital and the Veterans Administration Hospital, both of Oklahoma City, Oklahoma. The sternum was removed from the cadavers in the following manner. The body of the sternum was transected two centimeters below the manubrio-sternal junction. The first and second ribs on both sides were transected four centimeters lateral to the costo-chondral junction and the entire section was removed from the cadaver. Only the right side of such a section was obtained from each autopsy case (Fig. 1). A total of twenty-five cadavers were used ranging in age from twenty-two years to seventy-nine years. Sixty-seven specimens were taken from autopsy cases ranging in age from a fetus of twenty-two weeks to a male eighty-two years old. The specimens taken at autopsy were fixed in a ten per cent buffered formalin solution (Table 1) which according to Gurr (1953) prevented the dissolution of calcium salts.

TABLE 1

FORMULA FOR BUFFERED FORMALIN SOLUTION

Neutral formalin (formaldehyde 40%)	100.0 ml
Tap water	900.0 ml
Sodium dihydrogen phosphate monohydrate A.R.	4.0 gm
Disodium phosphate anhydrous A.R.	6.5 gm

Figure 1. Diagram of specimen taken at autopsy. Body of sternum transected below the manubrio-sternal articulation. First and second ribs transected lateral to costo-chondral junction. A, first rib; B, first costal cartilage; C, second rib; D, second costal cartilage; E, sterno-chondral articulation; F, costo-chondral junction; G, manubrium; H, manubrio-sternal articulation; I, body of sternum.

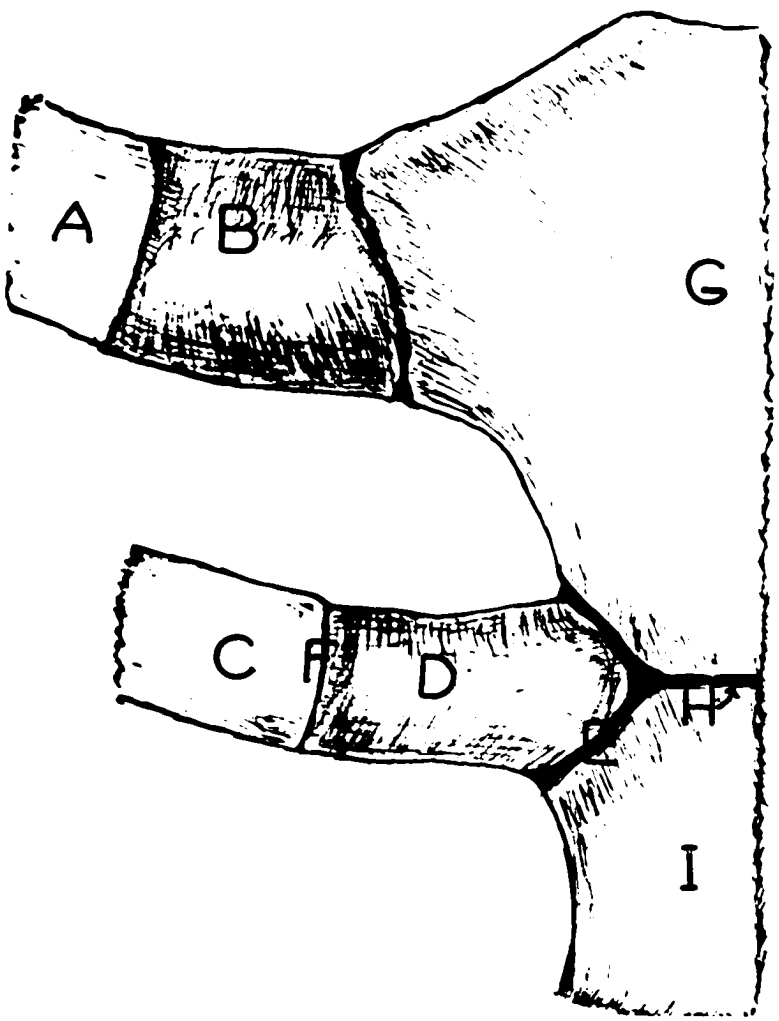

Figure 1.

Gross Anatomy

After a gross radiograph had been taken of the specimen, it was cut into two halves in the frontal plane. The second sterno-chondral cavity, the intra-articular ligament of the second cavity, the manubrio-sternal articulation, the costal cartilage and the costo-chondral junction were studied from both the cut surface and the external surface.

The state of the second sterno-chondral cavity was noted as to its:

1. Absence.
2. Presence as a single cavity. (Fig. 2a)
3. Presence as a double cavity. (Fig. 2b)
4. Presence in the lower portion of the articulation. (Fig. 2c)
5. Presence in the upper portion of the articulation. (Fig. 2d)
6. Presence continuing into the cavity of the manubrio-sternal articulation. (Figs. 2g, 2h)

The manubrio-sternal articulation was observed as to its:

1. Absence.
2. Presence as a synostotic articulation.
3. Presence as a movable articulation.
4. Continuity with the intra-articular ligament.

The intra-articular ligament of the second sterno-chondral cavity was noted as to its:

1. Absence. (Fig. 2a)
2. Presence at the midpoint of the cavity. (Fig. 2b)
3. Presence in the upper portion of the cavity:
    a. medially. (Fig. 2e)

b. laterally. (Fig. 2f)

c. as a few strands crossing the cavity. (Fig. 2d)

4. Presence in the lower portion of the cavity:

a. medially. (Fig. 2f)

b. laterally. (Fig. 2e)

c. as a few strands crossing the cavity. (Fig. 2c)

The costo-chondral junction was noted as:

1. A straight line.
2. A cup-shaped junction.
3. A projection of rib trabeculae into the cartilage.
4. A projection of cartilage into the rib trabeculae.

The costal cartilages were examined grossly with respect to:

1. Discoloration.
2. Position.
3. Extent.
4. Appearance of calcification areas.

Gross Radiography

Radiographs of all specimens were taken in our laboratory. A Westinghouse Fluoradex #16 Diagnostic X-ray Unit with a two hundred milliampere transformer, and a Westinghouse WSP - AC No. 978778 double focal spot (focal spot size 3.0 and 1.5 mm) tube were used to take these radiographs utilizing only the small focal spot. The radiographs were taken on five by seven inch No-Screen Eastman Kodak Safety X-ray Film at an eighty-four inch focus-film distance. The other factors were a peak kilovoltage of thirty-five, fifteen milliamperes, and fifteen

second exposure time. The films were developed in Kodak Liquid X-ray Developer, prepared in the standard manner, at 68 degrees F. for seven minutes, and fixed in Kodak Liquid X-ray Fixer for thirty minutes.

Calcification of the costal cartilages as revealed on the gross radiograph was evaluated from four different aspects (modified from Michelson, 1934):

1. The loci of calcification in the costal cartilages (Fig. 4) were identified as a basis for analysis and classified as follows:
    a. Calcification present in the central region of the cartilage. (Figs. 3b, 4c)
    b. Calcification present at the superior margin of the costal cartilage.
    c. Calcification present at the inferior margin of the costal cartilage. (Figs. 3c, 4d)
    d. Calcification concentrated at the costal extremity.
    e. Calcification concentrated at the sternal extremity. (Fig. 4b)
    f. Calcification extending solidly from the sternal extremity.
    g. Calcification extending solidly from the costal extremity.
    h. Calcification extending solidly from the costal extremity to the sternal extremity. (Figs. 4i, 4j)
    i. Uncalcified hiatuses through the calcified portion,

especially noticeable in areas where the changes were mostly osseous in appearance. (Figs. 3d, 4h, 4i)

2. The pattern of calcification was also noted. (Fig. 4) This included the following categories:
   a. Appearance as osseous trabecules. (Fig. 4j)
   b. Appearance as amorphic deposits. (Fig. 4g)
   c. Appearance as spicules. (Fig. 4d)
   d. Appearance as rods. (Figs. 3c, 4e)
   e. Appearance as a series of small blocks. (Figs. 3b, 4h)
   f. Appearance as several large blocks. (Fig. 4i)
   g. Appearance as granular deposits.
   h. Appearance as solid deposits. (Fig. 3c)
   i. Appearance as spurs and exostoses. (Figs. 3c, 4i)
3. The amount of calcification was evaluated in quantitative terms.
4. The density was qualitatively noted as being:
   a. Minimal.
   b. Intermediate.
   c. Maximal.

As will be evident from the body of the thesis, calcification in individual cartilages can be classified under various headings listed here.

Microscopic Anatomy

The cadaver specimens, due to the time lapse between death and their utilization on the dissecting tables, were not used in the microscopic or microradiographic studies.

For histological investigation each half of the specimen was cut into pieces corresponding to the following areas:

1. A transverse section of the second rib.
2. A longitudinal section of the second costo-chondral junction which included a portion of the rib and a portion of the costal cartilage.
3. A longitudinal section, where possible, of the second costal cartilage.
4. A section of the sterno-chondral junction which included a segment of the second costal cartilage, a segment of the manubrium, and a segment of the body of the sternum.
5. The remainder of the specimen above the section of the sterno-chondral junction was divided into portions that could be easily handled and yet remain identifiable.

These parts were washed in seventy per cent ethyl alcohol and decalcified in a five per cent solution of formic acid (McClung 1950). Several different decalcifying solutions were tested: formaldehyde and nitric acid (Carleton and Drury 1957); three per cent nitric acid (Carleton and Drury 1957; Gray, 1954); nitric acid and ethyl alcohol (Meyer 1956). Electrolytic decalcification methods were also attempted (Benson and Sanderson, 1953; Hale and Snook, 1949). The formic acid solution was found to be the most satisfactory of the several decalcifying solutions tried. Decalcification progress was checked and completion determined by x-raying of the cut segments. The time of decalcification varied between two and ten days. After decalcification, the pieces were washed, dehydrated, and

cleared in the following solutions: running water for forty-eight hours, eighty per cent ethyl alcohol for twenty-four hours, ninety-five per cent ethyl alcohol (two changes of four hours each), absolute ethyl alcohol (two changes of two hours each), and methyl benzoate from three to twelve hours. They were then placed in two changes of toluene for twenty minutes each, a fifty per cent solution of toluene and paraffin (two changes of one hour each) and infiltrated and embedded in paraffin (melting point 55°C).

Sections were cut on a Spencer #820 microtome at a thickness of twenty micra. Where size permitted they were placed on the slide in such a manner that the microradiograph and the stained ground bone section could be added later. Twenty micra was chosen as the thickness of the histological sections so that they would be approximately of the same thickness as the ground bone sections from which the microradiographs were taken. This thickness was also found to be most successful for grinding the sections of cancellous bone.

The standard staining technique utilizing the methods of hematoxylin and eosin were used for the study of morphological detail. The hematoxylin (Table 2) was prepared according to the formula of Harris (Carleton and Drury, 1957).

TABLE 2

FORMULA FOR HARRIS'S HEMATOXYLIN STAIN

Hematoxylin	1.0 gm
Ethyl alcohol (95%)	10.0 ml
Potassium alum	20.0 gm
Distilled water	200.0 ml
Mercuric oxide (to 'ripen' stain)	0.5 gm

A one per cent solution of eosin in seventy per cent alcohol was used to counterstain. The sections were mounted as above for histological investigation.

The chemicals used in the histological study were of Reagent or Analytical Reagent grade. They were obtained from Fischer Chemical Company, Mallinckrodt Chemical Company, and U. S. Industrial Chemical Company. The dyes were obtained from the National Aniline Division of the Allied Chemical and Dye Corporation.

Microradiography

For microradiographical investigation the frontal section of one-half of the specimen was divided as above, each of the pieces to correspond with a similar segment of the histological moiety. Infiltration and embedding was accomplished after the method of Belanger and Belanger (Boyd, 1955). Segments of several specimens were embedded in the same block in a large tray and these were subsequently cut into individual pieces with the band saw. Each individual piece was shaped to fit the vise of a specially constructed saw in such a manner that the face, or cut surface, of the segment would be parallel to the path of the circular saw blade.

Special equipment for sawing the sections was developed in this laboratory. The saw was powered by a one-sixteenth horsepower, 1760 rpm, electric motor, and was belt-driven from a pulley on the motor shaft to a pulley on the saw shaft, with a motor shaft to saw shaft ratio of four to one. One end of the saw shaft of the diameter of one-half inch was threaded to permit the use of a nut of one-fourth inch diameter to secure

a two inch saw blade.[1] The saw shaft was mounted between two self-adjusting pillow blocks. The apparatus for holding the plastic-embedded bone segment was fashioned from a machinist clamp welded to the directional shaft of a discarded dissection microscope. This contrivance was mounted at right angles to the cross-feed of a milling lathe, which permitted an even slow feed of the bone through the path of the cutting blade. The rough sections were cut at two hundred to three hundred micra. Sections could be cut to less than one hundred micra with this apparatus, but it was found that heat generated during the cutting of a block caused curling of the cartilage at the latter thickness.

The grinding apparatus, also developed in this laboratory, was powered by a one-fifteenth horsepower electric motor. To the shaft of this motor a three and one-half inch lightweight Dafner pulley was affixed. A soft-backed, fine resin-bonded, silicon, carbide abrasive paper[2] was attached to the flat surface of this pulley by double-coated Scotch Tape.[3] The grit of the paper used was 120, 240, 360, and 600. The rough section produced as above was affixed to a glass slide (one by three inch dimension) by means of double-coated Scotch Tape. These sections were held gently against the abrasive surface. A slight increase in pressure against the grinding surface was sufficient to stop the

---

[1]Two inch diameter, .032 inch thickness, No. 3017 'Cut off disc', Mfg. by Chicago Wheel and Mfg. Co.

[2]Wet-or-Dry, Tri-M-ite; Minnesota Mining and Mfg. Co.

[3]Scotch Pressure-Sensitive Tape No. 400, double coated tissue; Minnesota Mining and Mfg. Co.

motor. This safeguard insured against unwanted gouging as the grinding proceeded. The sections were ground until detail was discernible with the microscope and then polished with Crocus Cloth.[4]

The thickness of the section was determined by focusing the microscope on the upper and lower surfaces of the section. Recording the excursion of the calibrated, fine-focus adjustment made determination of the thickness possible. When the section was ground and polished to the desired thickness it was removed by immersing the slide in amyl acetate.

A microradiograph was then taken of the ground bone section. The section was affixed to the photographic plates with scotch tape. The tape was fastened to the plastic at the edges of the specimen so that nothing intervened between the x-ray source and the object radiographed. Styrafoil (deSousa and deSousa, 1954; Tirman and Banker, 1951) was found to be too radiopaque for this purpose.

The unit used in microradiography was assembled at this laboratory. The tube was a Dunlee S-24, mechanically sealed, permanently evacuated, beryllium window x-ray tube (Perry, 1956). This tube with a conventional stationary-type anode and a standard cathode design has a focal spot of eight-tenths millimeter. The tube has a target angle of twelve degrees and a one-fourth millimeter beryllium window. The tube is end-grounded and immersed in a glass container filled with oil for the purpose of cooling and insulation. It is energized from the transformer in the control stand of the standard fluoroscopic tube in this laboratory.

---

[4]Emery Polishing Paper; Norton Behr-Manning.

Connections were made such that one-half of the reading on the control unit was delivered to the tube. The standard control unit gave half-wave rectification on the microradiographic tube.

The x-ray tube was sealed by six bolts and a rubber gasket to a plate welded to one end of a steel cylinder three inches in diameter and fifteen inches long. An aperture in the steel plate the size of the window of the tube allowed the passage of the x-rays. The film plate placed at the opposite end of the cylinder, at the maximum distance of fifteen inches, was recessed between two plates of plastic. The bottom plastic plate was attached to a steel plate which was welded to the cylinder. By connecting a quarter inch pipe, welded near the base of the cylinder, to a mechanical vacuum pump the cylinder could be evacuated. If a vacuum was desired the seal was made with vacuum grease between the two plastic plates with the film plate resting in the recess described above. Using a duo-seal vacuum pump,[5] with continuous pumping it was possible to maintain a vacuum in excess of seven hundred twenty-five millimeters of mercury. A specially constructed mount was later introduced into the steel cylinder which diminished the target-film distance. Several of these devices were constructed to allow a choice of distances.

The photographic material used in microradiography was Eastman Kodak Spectroscopic Plates, emulsion numbers 548-0, 649-0 and 649-GH (Engström and Lindström, 1951). The optimal settings for our technique proved to be: seven and one-half inch target-film distance, ten milliamperes, and fifteen peak kilovolts. Exposure time varied between two

---

[5]Manufactured by W. M. Welch Mfg. Co., Chicago.

and four minutes depending on the emulsion type of film used.

The films were developed in Kodak D-19 Developer, prepared in the standard manner, for five minutes at sixty-eight degrees, and fixed in Kodak Acid Fixer for fifteen minutes. The microradiographs were then mounted on a microscopic slide adjacent to the hostological and ground bone sections as described above and studied with the microscope.

The ground bone specimens, after being microradiographed and prior to being mounted on the slide, were placed in a 0.25 per cent solution of hydrochloric acid. This decalcified the section slightly and allowed the surface to be stained. The section was then stained lightly with hematoxylin, and counterstained with eosin. The stained layer, being only a few micra in thickness, could be viewed with the higher magnifications of the microscope (Orban, 1957). Following the staining procedure, the section was mounted on a slide. Where size would permit, the histological section, the microradiograph, and the ground bone section were mounted on the same slide.

CHAPTER III

RESULTS

Gross Anatomy

The gross anatomy of the second sterno-chondral cavity, of the second costal cartilage, and of the manubrio-sternal articulation was studied in detail in fifty-three adult specimens. Incidental observations were also made on the costo-chondral articulation of the second rib. The group included thirty-eight white males, eight colored males, four white females and three colored females.

The Intra-articular Ligament of the Sterno-chondral Cavity and the Sterno-chondral Cavity of the Second Rib (Tables 3, 4 and Fig. 2)

Coronal sections of the sterno-chondral cavity of the second rib were studied from the cut surface. Nine per cent of the specimens showed no evidence of a cavity in this articulation. In these instances the articular surfaces of the costal cartilage adhered to the articular surfaces of the sternum. A double cavity separated by the intra-articular ligament was observed in over one-half of the cases (Fig. 2b). An absence of the intra-articular ligament resulting in a single cavity occurred in nine per cent of the specimens (Fig. 2a). The cavity was continuous with the manubrio-sternal articulation in sixty per cent of the cases. This continuity occurred when there was a single cavity with no intra-articular

Figure 2. Variation in position and extent of the intra-articular ligament in the second sterno-chondral articulation.

a. No intra-articular ligament. Single cavity continuous with manubrio-sternal interspace. A, costal cartilage; B, manubrium; C, body of sternum; D, single cavity; E, perichondrium and periosteum reflected over costal cartilage and sternum.

b. Intra-articular ligament dividing cavity into upper and lower portions. Manubriosternal interspace and cavities are not continuous. A, costal cartilage; B, manubrium; C, body of sternum; D, intra-articular ligament; E, upper portion of cavity; F, lower portion of cavity.

c. Upper portion of cavity obliterated. Lower portion of cavity crossed by tissue strands. A, costal cartilage; B, manubrium; C, body of sternum; D, obliterated upper portion; E, strands crossing lower portion.

d. Lower portion of cavity obliterated. Upper portion of cavity crossed by tissue strands. A, costal cartilage; B, manubrium; C, body of sternum; D, obliterated lower portion; E, strands crossing upper portion.

e. Intra-articular ligament located at medial aspect of upper portion of cavity, and lateral aspect of lower portion of cavity. A, costal cartilage; B, manubrium; C, body of sternum; D, medial ligament; E, lateral ligament; F, manubriosternal interspace.

f. Intra-articular ligament located at lateral aspect of upper portion of cavity and medial aspect of lower portion of cavity. A, costal cartilage; B, manubrium; C, body of sternum; D, medial ligament; E, lateral ligament; F, manubriosternal interspace.

g. Intra-articular ligament located at mid-point of cavity. Continuity of lower portion of cavity into manubriosternal interspace. A, costal cartilage; B, manubrium; C, body of sternum; D, intra-articular ligament; E, manubrio-sternal interspace.

h. Intra-articular ligament located at midpoint of cavity. Continuity of upper portion of cavity into manubriosternal interspace. A, costal cartilage; B, manubrium; C, body of sternum; D, intra-articular ligament; E, manubrio-sternal interspace.

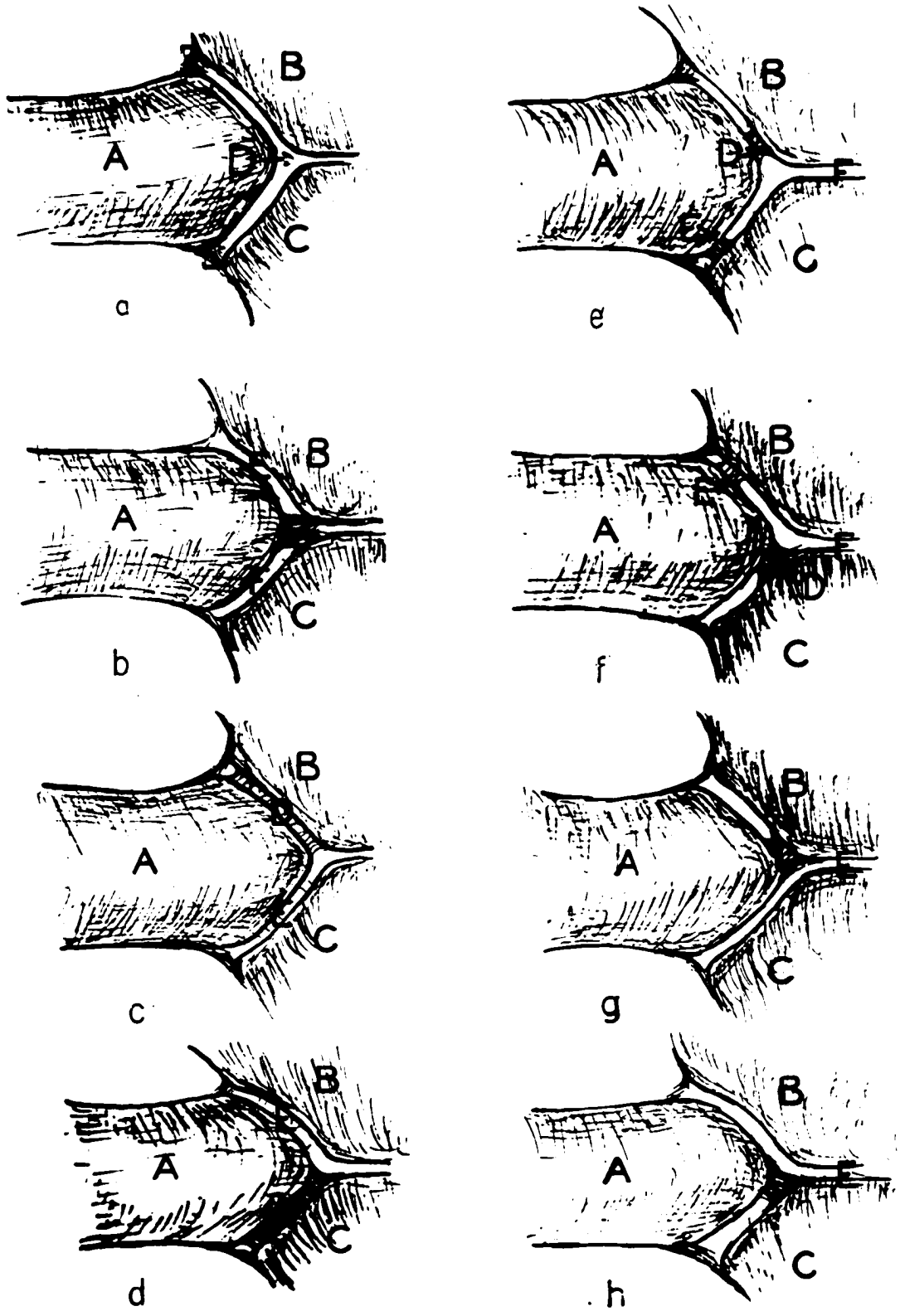

Figure 2.

TABLE 3

INTRA-ARTICULAR LIGAMENT IN THE SECOND STERNO-CHONDRAL ARTICULATION AS REVEALED BY GROSS ANATOMICAL STUDY

Age	Specimen Number	Extent of Ligament									
				Upper Cavity				Lower Cavity			
		Absent	Present at mid-point of cavity	Ligament obliterated cavity	Present medially	Present laterally	Represented by a few strands	Ligament obliterated cavity	Present medially	Present laterally	Represented by a few strands
White Males											
25	39		x								
27	30		x		x						
30	53			x							
37	40			x							
40	57			x				x			
40	E-47		x			x					
41	E-49			x							
44	T-27			x				x			
45	38		x								
45	58		x								
50	54		x				x				
51	21			x							
51	42			x							
52	E-40				x						
53	60				x						
54	E- 9		x				x				
56	D-38	x									
59	49					x					
59	13			x							
60	59		x								
62	56			x				x			
63	11	x									
63	55			x							
65	29			x				x			
67	41	x									
67	42		x								
68	35			x							
68	47					x					
68	E-46		x								
71	28		x			x					
75	E- 6		x								
76	C-31		x		x						
76	D- 5		x								
78	T-15			x				x			

TABLE 3-Continued

Age	Specimen Number	Absent	Extent of Ligament								
			Present at mid-point of cavity	Upper Cavity				Lower Cavity			
				Ligament obliterated cavity	Present medially	Present laterally	Represented by a few strands	Ligament obliterated cavity	Present medially	Present laterally	Represented by a few strands
White Males											
78	E-44		x	x							
79	E- 3						x				
81	45			x							
82	48				x						
Colored Males											
48	E-54		x		x						
64	46		x		x						
64	D- 7		x		x						
64	E-43		x	x							
64	D-45	x									
66	E-39		x		x						
76	D-41		x	x							
77	Q-16		x	x							
White Females											
18	51	x									
59	52		x								
60	W-37					x	x				x
76	D- 4		x		x						
Colored Females											
41	V-26		x			x					
56	D-19		x		x						
65	T-37		x		x					x	
Total	53	5	27	18	12	6	4	5		1	1
Per cent		9	51	34	23	11	8	9		2	2

TABLE 4

THE SECOND STERNO-CHONDRAL ARTICULATION AND THE MANUBRIO-STERNAL ARTICULATION AS REVEALED BY GROSS ANATOMICAL STUDY

Age	Specimen Number	Extent of the Cavity in Sterno-chondral Articulation						Manubrio-sternal Articulation			
		Cavity lacking	Single cavity	Double cavity	Only lower portion present	Only upper portion present	Continuous into manubrio-sternal joint	Continuous with intra-articular ligament	Not evident	Movable	Synostosed
White Males											
25	39			x			x			x	
27	20		x								
30	53				x			x	x	x	x
37	40			x			x			x	
40	57	x							x		x
40	E-47			x				x		x	
41	E-49				x		x	x		x	
44	T-27	x									x
45	38			x			x			x	
45	58			x			x	x		x	
50	54		x							x	
51	21			x				x			
51	42				x		x			x	
52	E-40			x			x			x	
53	60			x			x			x	
54	E- 9			x			x				x
56	D-38		x						x		x
59	49			x			x			x	
59	60			x			x	x		x	
59	13			x			x	x		x	
62	56	x							x		x
63	11				x		x			x	
63	55	x							x		x
65	29				x		x	x		x	
67	41		x							x	
67	43			x			x	x		x	
68	35				x						x
68	47			x			x			x	
68	E-46			x					x		x
71	28			x				x		x	
75	E- 6			x			x	x		x	
76	C-31				x		x	x		x	

TABLE 4-Continued

Age	Specimen Number	Extent of the Cavity in Sterno-chondral Articulation						Manubrio-sternal Articulation			
		Cavity lacking	Single cavity	Double cavity	Only lower portion present	Only upper portion present	Continuous into manubrio-sternal joint	Continuous with intra-articular ligament	Not evident	Movable	Synostosed
White Males											
76	E- 5			x			x	x		x	
78	T-15	x							x		x
78	E-44				x		x	x		x	
79	E- 3			x			x			x	
81	45				x		x	x		x	
82	48			x			x			x	
Colored Males											
48	E-54			x			x	x		x	
64	46			x			x	x		x	
64	E- 7			x				x		x	
64	E-43				x			x		x	
66	E-39			x			x	x		x	
76	D-41				x					x	
77	Q-16				x					x	
78	D-45		x								x
White Females											
18	51			x			x			x	
59	52			x			x			x	
60	W-37			x						x	
76	D- 4			x			x	x		x	
Colored Females											
41	V-26			x			x	x		x	
56	D-19			x			x	x		x	
65	T-37			x			x	x		x	
Total	53	5	5	31	12		32	24	7	41	11
Per cent		9	9	59	23		60	45	13	78	21

ligament (Fig. 2a), when the intra-articular ligament was present (Figs. 2g, 2h), and when only the lower portion of the cavity was visible (Fig. 2c). When a part of the cavity was obliterated, it was generally the upper portion.

The ligament was apparent at the mid-point of the joint cavity in fifty-one per cent of the cases (in the white male specimens this was evident in only forty per cent) (Fig. 2b). The upper portion of the cavity was completely obliterated, with the intra-articular ligament extending from the costal surface to the sternal surface in thirty-four per cent of the specimens (Fig. 2c). Occurrence of the ligamentous bands lateral to the mid-point of the cavity was observed in one-third of the cases (Figs. 2e, 2f). Only a few strands crossed the upper portion of the cavity in eight per cent of the specimens.

The Manubrio-sternal Articulation (Table 4)

This articulation was movable in seventy-eight per cent of the specimens studied. Fibrocartilage was not evident, i.e., the manubrium and the body of the sternum had the appearance of a single bone in thirteen per cent of the specimens. The manubrio-sternal fibrocartilage was continuous with the intra-articular ligament of the sterno-chondral cavity in fifty-five per cent of the cases.

General

The radiate sterno-costal ligaments at the sterno-chondral articulation were continuous with the articular capsule in all specimens studied. The anterior ligaments appeared stronger and more extensive than the

posterior ligaments. The periosteum when stripped from either the ribs or the sternum evinced continuity with the perichondrium of the costal cartilage. The articular fibrocartilages of the sterno-chondral joint were fused with the perichondrium of the costal cartilage and the periosteum of the sternum. Changes in the costal cartilage were discernible to the naked eye. Circumscribed, whitish, discolored areas were noted on gross inspection. The cartilages varied in color from yellow to brown, a yellowish-brown being the most prevalent. The cartilage at the costochondral junction grossly exhibited fusion with the rib. This fusion was present in about half of the cases as a straight line, and in half of the cases as a convex junction. In only two specimens studied did the rib trabeculation protrude into the cartilage. In no instance did the cartilage appear to project into the rib trabeculae.

Gross Radiographic Anatomy

Gross radiographs were taken of eighty-four specimens. Tables 5 and 6 and Figures 3 and 4 disclose the location of calcification in the first and second costal cartilages. Tables 7 and 8 and Figures 3 and 4 present the pattern of calcification in the first and second costal cartilages. Tables 9 and 10 record the percentage of calcification and relative density of the first and second costal cartilages. The classifications noted in Chapter II and presented in the tables overlap, e.g. alterations that are visible as large blocks might also display an osseous texture. A cartilage manifesting central calcification in line with the long axis of the costal cartilage, might also disclose superior or inferior marginal involvement (Figs. 3d, 4g). This should be understood in reading the

Figure 3. Gross radiographs of the region studied which included the sternum and the first and second ribs and cartilages. Note the difference in the extent of calcification of the first and second cartilage. Roentgenogram a, shows absence of calcification in the first and second cartilages. Roentgenogram b, shows small blocks of calcification in the first cartilage and central calcification along the long axis of the second cartilage. In roentgenograms c and d, trabeculae, unossified hiatuses and exostoses are visible in the first cartilage. In roentgenogram c, calcification is found along the inferior margin of the second cartilage. In roentgenogram d, calcification occurs in a random arrangement throughout the cartilage. Inframarginal, central, supramarginal, costal and sternal positions of calcified deposits are evident.



a



b



c



d

Figure 3.

Figure 4. Examples of macroradiographs illustrating locations and patterns of calcification in the first and second costal cartilages.

a. No change present. (2nd cartilage)

b. Change concentrated at sternal extremity. Note osseous appearance at this site. (2nd cartilage)

c. Change located centrally and in long axis of cartilage. (2nd cartilage)

d. Change at inferior margin. Note central spicule formation. (2nd cartilage)

e. Rod-shaped change midway between inferior margin and central location. (2nd cartilage)

f. Change involving both costal and sternal extremities. (2nd cartilage)

g. Change combining several elements of basic classification. Note costal and sternal involvement; inferior and superior marginal involvement, as well as central involvement. (2nd cartilage)

h. Change extending from costal and sternal extremities. Note formation of small blocks and uncalcified chasms. (1st cartilage)

i. Change showing the formation of uncalcified chasms. Note large block formation and exostoses at inferior margin. (1st cartilage)

j. Change showing solid extension from rib to sternum. Note similarity of trabecular pattern to that of rib and sternum. (1st cartilage)



Figure 4.

percentages on calcification changes. Fourteen of the eighty-four specimens were obtained from either fetuses, newborn infants, or children under five years of age. Calcification was not considered in this age group, consequently these specimens were not utilized in the percentage figures reported below. Of the remaining seventy specimens, all of which were adults, there were fifty white males, eleven colored males, six white females, and three colored females. In the analysis of the first costal cartilage, five specimens were not usable because of the manner in which they had been removed at autopsy. Due to the small number of cases in several of the age or racial groups, especially in those groups between fifteen and forty years, no attempt was made to correlate the gross appearance of calcification with age or race.

Location of Calcification in the First Costal Cartilage (Table 5)

Calcification reaching from the costal to the sternal margin was observed in sixty-two per cent of the specimens (Figs. 3d, 4j). Uncalcified hiatuses extending from the superior to the inferior border of the cartilage appeared in twenty-nine per cent of the instances (Figs. 3d, 4h, 4i). Seventeen per cent revealed calcification along the inferior margin of the costal cartilage (Fig. 4d). Calcifications extending solidly from the costal extremity, but not reaching the sternal extremity; calcification extending solidly from the sternal extremity, but not reaching the costal extremity; calcification along the superior margin of the cartilage; calcification concentrated at the sternal extremity; and central calcification in line with the long axis of the cartilage were

The classification symbols in Table 5 and Table 6 indicate the location of calcification:

o. A complete absence of calcification.

a. Calcification present in the central region of the cartilage.

b. Calcification present at the superior margin of the costal cartilage.

c. Calcification present at the inferior margin of the costal cartilage.

d. Calcification concentrated at the costal extremity.

e. Calcification concentrated at the sternal extremity.

f. Calcification extending solidly from the sternal extremity.

g. Calcification extending solidly from the costal extremity.

h. Calcification extending solidly from the costal extremity to the sternal extremity.

i. Uncalcified hiatuses through the calcified portion, especially noticeable in areas where the changes were mostly osseous in appearance.

TABLE 5

LOCATION OF CALCIFICATION IN THE FIRST COSTAL CARTILAGE AS EVIDENCED BY GROSS RADIOGRAPHIC STUDY

Age	Number of Cases	Classifications *									
		o	a	b	c	d	e	f	g	h	i
White Males											
0-5	6	6									
21-25	1				1						
26-30	3				1		1			2	1
36-40	2		1	1				1		1	
41-45	3						1			2	1
46-50	4	1								3	2
51-55	5			1	3		1		1	2	1
56-60	3			1	1		1			1	
61-65	9				1	1	1		1	5	1
66-70	5			1	1					4	3
70-	11			1	2	1			1	7	4
Colored Males											
0-5	4	4									
21-25	1	1									
36-40	1									1	1
46-50	1									1	1
61-65	3									3	
66-70	1									1	1
70-	4									4	1
White Females											
0-5	3	3									
16-20	1	1									
21-25	1	1									
46-50	1									1	
56-60	1									1	
70-	1									1	
Colored Females											
0-5	1	1									
41-55	1					1					
56-60	1			1	1						
61-65	1									1	1
Total	79	18	2	6	11	4	5	1	3	41	18
Per cent		6	3	9	17	6	8	2	5	62	29

*Classification symbols explained on page 39.

demonstrated in less than ten per cent of the specimens.

Location of Calcification in the Second Costal Cartilage (Table 6)

Calcification concentrated at the sternal extremity of the costal cartilage was manifested in fifty-eight per cent of the specimens studied (Fig. 4b). Involvement at the inferior margin was seen in twenty-seven per cent (Figs. 3c, 4d). Central calcification, in line with the long axis of the cartilage, was observed in twenty-four per cent of the specimens (Figs. 3b, 4c). Nineteen per cent of the cases disclosed calcifications concentrated at the costal extremity. Calcification at the superior margin of the cartilage was noted in ten per cent of the cases. Other alterations as recorded in Table 6 were exhibited in less than ten per cent of the specimens.

Pattern of Calcification in the First Costal Cartilage (Table 7)

Trabeculation, which was indistinguishable from the osseous appearance of the rib or sternum, was the most frequent type of calcification seen in the first costal cartilage (Figs. 3d, 4j). This pattern was visible in fifty-one per cent of the specimens. Calcification presented an amorphic appearance in forty-six per cent of the material (Fig. 4e). Calcification changes, organized as large blocks, were demonstrated in eighteen per cent of the cases (Fig. 4i). Eleven per cent of the specimens displayed calcification arranged as a series of small blocks (Fig. 4h). Other classifications as listed in Table 7 were observed in less than ten per cent of the specimens.

TABLE 6

LOCATION OF CALCIFICATION IN THE SECOND COSTAL CARTILAGE AS EVIDENCED BY GROSS RADIOGRAPHIC STUDY

Age	Number of Cases	Classifications *									
		o	a	b	c	d	e	f	g	h	i
White Males											
0-5	6	6									
21-25	1				1						
26-30	3	1			1	1				1	
36-40	2		1	1	1			1			
41-45	3		1		1	1		1		1	
46-50	4	1		2	1			3			
51-55	5		2		1	1		4			
56-60	3	1	1					1		1	
61-65	10	1	1	1	2	4		3	1		
66-70	6		1	1	2	1	1	4		1	1
70-	13		7	1	5	3		8	1		
Colored Males											
0-5	4	4									
21-25	1	1									
36-40	1							1			
46-50	1					1		1			
61-65	3				1			2		1	1
66-70	1					1		1			
70-	4		1		2			3		1	
White Females											
0-5	3	3									
16-20	1	1									
21-25	1	1									
46-50	1							1			
56-60	2		1	1	1			2			
70-	1		1					1			
Colored Females											
0-5	1	1									
41-45	1							1			
56-60	1							1			
61-65	1							1			
Total	84	21	17	7	19	13	1	40	2	6	2
Per cent		11	24	10	27	19	1	58	3	9	3

*Classification symbols explained on page 39.

The classification symbols in Table 7 and Table 8 indicate the following patterns of calcification:

o. Complete absence of calcification.

a. Appearance as osseous trabecules.

b. Appearance as amorphic deposits.

c. Appearance as spicules.

d. Appearance as rods.

e. Appearance as a series of small blocks.

f. Appearance as granular deposits.

h. Appearance as solid deposits.

i. Appearance as spurs and exostoses.

TABLE 7

PATTERN OF CALCIFICATION IN THE FIRST COSTAL CARTILAGE
AS EVIDENCED BY GROSS RADIOGRAPHIC STUDY

Age	Number of Cases	Classifications *									
		o	a	b	c	d	e	f	g	h	i
White Males											
0-5	6	6									
21-25	1			1							
26-30	3		1				2				
36-40	2		1	1							
41-45	3		1	3							1
46-50	4	1	3	1			1	1			
51-55	5		3	1		1	1	2			1
56-60	3		3	2		1	1				2
61-65	9	1	4	3	1			2		3	1
66-70	5		4	5							2
70-	11		8	4		2		3			4
Colored Males											
0-5	4	4									
21-25	1	1									
36-40	1		1	1							
46-50	1		1	1							1
61-65	3		3	3			2	1			
66-70	1		1	1							
70-	4		3	2							1
White Females											
0-5	3	3									
16-20	1	1									
21-25	1	1									
46-50	1			1						1	1
56-60	1							1			1
70-	1						1	1			
Colored Females											
0-5	1	1									
41-45	1			1				1			
56-60	1			1				1			
61-65	1		1	1				1			1
Total	79	19	38	33	1	4	8	14		4	16
Per cent		8	59	51	1	6	12	22		6	22

*Classification symbols explained on page 43.

Pattern of Calcification in the Second Costal Cartilage (Table 8)

The predominant change in the second costal cartilage was a lack of form or shape of the calcified deposits. This is noted in the tables as amorphic change, and was present in sixty-seven per cent of the specimens (Fig. 4d). Seventeen per cent evidenced osseous changes in the form of trabeculation (Fig. 4f). Eleven per cent showed calcification as small block formations (Fig. 4h). Of the remaining changes outlined in Chapter II and listed in Table 8 none exceeded an occurrence of ten per cent.

Percentage Calcification and Density of First Costal Cartilage (Table 9)

Calcification was extensive in the first costal cartilage. Eighty to one hundred per cent calcification appeared in fifty-eight per cent of the cases. Forty to sixty per cent involvement of the cartilage was the next most prevalent category. This was evident in eleven per cent of the cases. Less than ten per cent of the specimens were observed in the remaining classifications listed in Table 9. The density of the calcification was subjectively evaluated. Ninety-one per cent of the specimens manifested slightly less to slightly greater density than the corresponding costal or sternal trabeculae. This was recorded as intermediate density.

Percentage Calcification and Density of the Second Costal Cartilage (Table 10)

Calcification was much less extensive in the second costal cartilage. Eight per cent of the cases disclosed no calcification in the second costal cartilage. One to twenty per cent calcification occurred

TABLE 8

PATTERN OF CALCIFICATION IN THE SECOND COSTAL CARTILAGE AS EVIDENCED BY GROSS RADIOGRAPHIC STUDY

Age	Number of Cases	Classifications *									
		o	a	b	c	d	e	f	g	h	i
White Males											
0-5	6	6									
21-25	1								1		
26-30	3	1		2		1	1		1		
36-40	2			2			1				
41-45	3		1	3							1
46-50	4	1	1	3			2				
51-55	5		1	4		1			1		
56-60	3	1	1	2							
61-65	10	1	2	8	1		1	1			
66-67	6		1	6		1					
70-	13		2	11	1	1	1		1		
Colored Males											
0-5	4	4									
21-25	1	1									
36-40	1		1								
46-50	1			1							
61-65	3		1	2							1
66-70	1			1							
70-	4		1	3		1	1		1		
White Females											
0-5	3	3									
16-20	1	1									
21-25	1	1									
46-50	1		1								
56-60	2		1	1			1		1		
70-	1							1			
Colored Females											
0-5	1	1									
41-45	1		1								
56-60	1								1		
61-65	1			1							
Total	84	21	13	52	2	5	8	2	7		2
Per cent		10	19	74	3	6	11	3	10		3

*Classification symbols explained on page 43.

TABLE 9

PERCENTAGE OF CALCIFICATION AND DENSITY OF THE FIRST COSTAL CARTILAGE AS EVIDENCED BY GROSS RADIOGRAPHIC STUDY

Age	Number of Cases	Percentage Calcification						Density		
		0	1-20	21-40	41-60	61-80	81-100	Minimal	Intermediate	Maximal
White Males										
0-5	6	6								
21-25	1		1						1	
26-30	3			1			2		2	1
36-40	2		1				1		2	
41-45	3					1	2		3	
46-50	4	1					3		4	
51-55	5		1	1	2		1		5	
56-60	3			1	1		1		3	
61-65	9	1	1		1	1	5		7	
66-70	5			1			4		5	
70-	11		2		1		8		11	
Colored Males										
0-5	4	4								
21-25	1	1								
36-40	1						1		1	
46-50	1						1		1	
61-65	3				1	1	1		3	
66-70	1						1		1	
70-	4						4		3	1
White Females										
0-5	3	3								
16-20	1	1								
21-25	1	1								
46-50	1					1			1	
56-60	1				1				1	
70-	1					1			1	
Colored Females										
0-5	1	1								
41-45	1		1						1	
56-60	1		1						1	
61-65	1						1		1	
Total	79	20	8	4	7	5	38		58	2
Per cent		9	12	6	11	8	58		91	3

TABLE 10

PERCENTAGE OF CALCIFICATION AND DENSITY OF THE SECOND COSTAL CARTILAGE AS EVIDENCED BY GROSS RADIOGRAPHIC STUDY

Age	Number of Cases	Percentage Calcification						Density		
		0	1-20	21-40	41-60	61-80	81-100	Minimal	Intermediate	Maximal
White Males										
0-5	6	6								
21-25	1		1						1	
26-30	3	1	1				1		2	
36-40	2		2						2	
41-45	3		2			1			3	
46-50	4	1	2	1					3	
51-55	5		5						5	
56-60	3		2	1					3	
61-65	10	2	7			1			8	
66-70	6		3	2			1		6	
70-	13		9		4			1	9	2
Colored Males										
0-5	4	4								
21-25	1	1								
36-40	1		1						1	
46-50	1		1						1	
61-65	3	1	1			1			3	
66-70	1		1						1	
70-	4		2	1		1			4	
White Females										
0-5	3	3								
16-20	1	1								
21-25	1	1								
46-50	1		1						1	
56-60	2		2						2	
70-	1		1						1	
Colored Females										
0-5	1	1								
41-45	1	1								
56-60	1		1						1	
61-65	1		1						1	
Total	84	9	48	5	4	4	2	1	58	2
Per cent		13	69	7	5	5	3	1	83	3

in sixty-seven per cent of the specimens. Intermediate density was observed in eighty-six per cent of the specimens studied.

Microscopic Anatomy

Microscopic sections were taken of the specimens as outlined in Chapter II, pages 17 and 18. These sections were taken from a total of fifty-three specimens, fourteen of which were fetuses or newborn, the remainder being adults. The histological picture described below is based on these sections. No attempt has been made to investigate the microscopic anatomy from the aspect of race or sex.

Newborn Specimens

The sterno-chondral junction of the second rib. The sterno-chondral articulation of the second rib in the newborn was investigated in a total of fourteen specimens. Double cavities separated by the anlage of the intra-articular ligament on both sides appeared twice, and on one side four times. Single cavities appeared once above the position of the future intra-articular ligament and three times below. Clefts within the interspace between the sternum and the costal cartilage, that could not be classified as true cavities, appeared twice. Solid fusion was evident in two specimens. Fibrocartilage was invariably present uniting the pointed extremity of the costal cartilage to the sternum. This fibrocartilage, which stained strongly eosinophilic, was concentrated frequently at the mid-point of the sternal depression in the position of the future intra-articular ligament (Fig. 5). The central portion contained vascular elements surrounded by connective tissue (Figs. 5, 6). The fibrocartilage

Figure 5. Photomicrograph of coronal section of right sterno-chondral junction and manubrio-sternal articulation of newborn. Fibrocartilage at position of future intra-articular ligament stained darkly. A, costal cartilage; B, manubrium; C, anlage of manubrio-sternal articulation; D, body of sternum; E, position of future intra-articular ligament; F, sterno-chondral cavity. (20 micra section, H&E stain, magnification 20x)

Figure 6. Photomicrograph of coronal section of sterno-chondral junction of newborn. Same specimen as in Figure 4 under higher magnification. Note vascular elements in the position of the future sterno-chondral cavity. A, costal cartilage; B, manubrium; C, position of future intra-articular ligament; D, body of sternum. (20 micra section, H&E stain, magnification 35x)



Figure 5



Figure 6

fused with the sternum and the costal cartilage, and separated to enclose the cavities when they were present (lower part of Fig. 5). As in the adult, the costal cartilage presented flat articular facets. The articular surface in the more developed specimens stained slightly eosinophilic. A surface layer of a thickness of three to four cells was present. These cells had elongated nuclei, flattened in the plane of the articular surface (Fig. 7). This layer fused intimately with the underlying hyaline cartilage. When the cavities existed as mere interspaces and a surface layer did not exist as such, a zone was present which was as much as fifteen cells in thickness and which stained with an acid dye. Strands crossed the cavities uniting the opposing surfaces (Fig. 8). These cavities or interspaces fused medially and laterally with the fibrocartilage. Minimal changes were apparent in the hyaline cartilage. There was a loss of some basophilia and some disorientation of the hyaline cartilage. The peripheral areas of this zone stained poorly. The most obvious deviation in these specimens was a lack of eosinophilia in the area later occupied by the intra-articular ligament. Canals containing vascular elements were present within the body of the cartilage. These were more abundant in the sternal regions than in the costal region. The vascular elements within the canals were surrounded by connective tissue.

The costo-chondral junction. The microscopic appearance of the costo-chondral junction closely resembled that of a normal epiphysis. The cartilage in the medialmost region of the costo-chondral junction corresponded to the resting cartilage of the epiphysis, but further

Figure 7. Photomicrograph of coronal section of costal cartilage of newborn. Flattened external layer of three to four cells thickness seen on articular surface. A, joint cavity; B, articular surface; C, hyaline cartilage. (20 micra, H&E stain, magnification 130x)

Figure 8. Photomicrograph of coronal section of sterno-chondral cavity of newborn. Fibrocartilaginous strands seen crossing the cavity. A, manubrium; B, sterno-chondral cavity; C, fibrocartilaginous strands crossing sterno-chondral cavity; D, costal cartilage. (20 micra section, H&E stain, magnification 35x)



Figure 7



Figure 8

laterally displayed a zone of proliferating tissue in which multiple chondrocytes appeared in single lacunae. Progressing from this region toward the rib, the cartilage cells were arranged in well defined columns. This zone of hypertrophied cartilage was fifteen to twenty cells in length (Fig. 9). It extended to an area of trabeculae formed in calcified cartilage. These cellular columns were separated by a matrix which stained with a basic dye. Central cores of calcified cartilage were evident in areas where the trabeculae had formed (Fig. 10). The cartilage at the costo-chondral junction showed a slight expansion in width. The perichondrium fused with the periosteum, no abrupt change being discernible. No sharp line of demarcation was evident between the perichondrium and the hyaline costal cartilage. The inner layer of the perichondrium, consisting of oval cells with vesicular nuclei, contained scattered young chondrocytes. The middle layer consisted of compact, longitudinally-oriented cells which had plate-like nuclei. This layer was eight to ten cells in thickness. The outer layer was made up of irregularly arranged loose fibrous connective tissue.

Manubrio-sternal articulation. The anlagè of the manubrio-sternal articular cartilages was present in all of the specimens studied. This was evidenced as a transverse zone of altered cartilage. Minimal changes included a loss of some basophilia, with little disorientation of the sternal cartilage on either side. Fibrils were present which were oriented vertically from the manubrium to the body of the sternum (Fig. 11). Fibrous elements were seen between normal appearing cartilage cells, resulting in a diminution of the number of cartilage cells present per

Figure 9. Photomicrograph of coronal section of costochondral junction of newborn. Hypertrophied cartilage cells appear similar to epiphyseal junction. Note columnar alignment adjacent to calcified spicules. A, columns of hypertrophied cartilage cells; B, calcified cartilage spicules. (20 micra section, H&E stain, magnification 20x)

Figure 10. Photomicrograph of coronal section of rib of newborn. Osseous structure is superimposed on central cores of calcified spicules. A, osseous structure of rib trabeculae; B, central core of calcified spicules. (20 micra section, H&E stain, magnification 35x)



Figure 9



Figure 10

Figure 11. Photomicrograph of coronal section of manubrio-sternal articulation. Note decreased cell-matrix ratio and developing fibers with resulting fibrocartilaginous appearance. A, manubrium; B, anlage of manubrio-sternal articulation; C, body of sternum. (20 micra section, H&E stain, magnification 35x)

Figure 12. Photomicrograph of coronal section of manubrio-sternal articulation. Higher magnification of Figure 11. Fibrous elements become apparent in region of developing manubrio-sternal articulation. (20 micra section, H&E stain, magnification 130x)



Figure 11



Figure 12

unit area (Fig. 12). With further development the zone became more fibrocartilaginous in appearance. The fibrils then were oriented transversely, and stained more eosinophilic. The cellular elements increased per unit area and spaces appeared in the central mass of this zone. Laterally the fibrocartilage continued as the anlagé of the intra-articular ligament.

Adult Specimens

The sterno-chondral junction of the second rib. The fibrocartilage of the articular facets on the manubrium and the sternal body of the sterno-chondral articulation was found to be continuous with the fibrocartilage of the manubrio-sternal joint. A strongly eosinophilic layer one to two cells in thickness was present superficial to the compact bone of the sternum. The fibrocartilaginous layer, the fibers of which were arranged at right angles to the compact bone, was located external to the eosinophilic layer (Fig. 13). The cellular elements in this layer were found similar to normal hyaline cartilage and blended into a somewhat normal appearing hyaline region which underlaid the articular surface. The articular surface was composed of a fibrous layer three to four cells in thickness. These cells had elongated flattened nuclei, and were oriented parallel with the articular surface (Fig. 14). The articular facet has a lower matrix-to-cell ratio than found in the manubrio-sternal articulation. The articular surface of the costal cartilage in this region stained more eosinophilic than did the body of the costal cartilage. Osseous changes were seen in the central mass of this

Figure 13. Photomicrograph of coronal section of sterno-chondral articulation of adult. Junction of fibrocartilaginous layer with compact bone can be seen. Note orientation of fibers at right angles to surface of bone. Eosinophilic layer situated superficial to junction illustrated at C. A, joint cavity; B, articular surface; C, junction of fibrocartilage and compact bone; D, compact bone. (20 micra section, H&E stain, magnification 20x)

Figure 14. Photomicrograph of coronal section of articular surface of sterno-chondral articulation of adult. Note elongation of cells near surface. A, joint cavity; B, articular surface. (20 micra section, H&E stain, magnification 100x)



Figure 13



Figure 14

region, but not to the extent that they were present peripherally (Fig. 15). Calcification in the central region was oriented in many instances around vascular elements (Fig. 16). The cartilage cells became round and more vesicular in nature. The intracellular matrix became highly eosinophilic. While generally amorphic in character, fibers appeared frequently in the intracellular matrix. The cartilage at the sternochondral articulation generally had a hyaline appearance. Various degrees of disorganization suggestive of degenerative changes were also evident. There was also a loss of cellular elements and an increase in amorphic appearance. Fibrous strands were seen crossing the sternochondral cavity. A small number of cellular elements were present in these structures (Fig. 17). These strands possessed the same staining characteristics as the surface articular layers of the costal cartilage and the fibrocartilage of the articular facets of the sternum.

Calcification of the costal cartilage. The most striking microscopic finding in the calcification pattern of the costal cartilages was the apparent lack of organization. In initial calcification a change in the cartilage from its normal basophilic staining characteristic to that of an eosinophilia, a slight loss of organization, and a multiplication of cartilage cells per lacuna was seen. Connective tissue was present at some of these sites, oriented around vascular elements. Intermediate between the eosinophilia of initial calcification and the dissolution of terminal calcification, were areas in which the organization was further broken down. The cartilage cells were rounded, vesicular in nature, and present in groups per lacuna. These cells were farther apart

Figure 15. Photomicrograph of coronal section of costal cartilage at sterno-chondral articulation. Note osseous spicule formation and abnormal appearance of hyaline cartilage. A, bone spicule; B, abnormal hyaline cartilage. (20 micra section, H&E stain, magnification 50x)

Figure 16. Photomicrograph of coronal section of costal cartilage. Vascular elements are seen in region of calcification. A, vascular elements; B, normal cartilage; C, ossification change. (20 micra section, H&E stain, magnification 20x)



Figure 15



Figure 16

Figure 17. Photomicrograph of coronal section of sternochondral cavity. Fibrocartilaginous strands are seen crossing cavity. A, joint cavity; B, fibrous strands crossing joint cavity; C, fibrocartilage of sternum; D, articular surface of costal cartilage. (20 micra section, H&E stain, magnification 20x)

Figure 18. Photomicrograph of coronal section of costal cartilage. Initial calcification can be seen. Note slight loss of organization; multiple cartilage cells per lacuna, and reticular appearance of intercellular matrix. (20 micra section, H&E stain, magnification 50x)



Figure 17



Figure 18

from each other than normally. The matrix stained brilliantly eosinophilic and gave a reticular appearance (Fig. 18). Widespread calcification centrally was evidenced by amorphic eosinophilic deposits. Isolated cartilage cells could be seen in such an area, but the appearance was mostly that of a homogeneous disrupted mass (Fig. 19). In the second costal cartilage, trabeculation (osseous change) was seldom seen in the central area. In the margins of the costal cartilages, calcification often appeared as bony spicules. Peripherally where calcification was in contact with the perichondrium (periosteum) trabeculation was very similar to the rib proper differing only in the presence of islands of atypical cartilage (Fig. 20). In this location innumerable variations in the appearance of the calcification also existed. When calcification progressed to the formation of osseous trabeculae, organization returned and took on the appearance of regular cancellous bone in the area involved. In the region of the developing trabeculae cartilage cells became vesicular and hypertrophic, reminiscent of the change present in normal ossification. The cartilage was invariably abnormal evidencing alterations in staining characteristics, multiple cells per lacuna, hypertrophy of individual cells, and an increase of the matrix-to-cell ratio.

Calcification in the first rib was most irregular in its appearance and ossification changes (trabecular formation) were widespread. Isolated bodies of cartilage with the appearances noted above were completely surrounded by osseous trabeculae (Fig. 21). Unossified chasms or channels bordered both by bone and by calcified cartilage appeared in these areas of trabeculation with little orientation (Fig. 22).

Figure 19. Photomicrograph of coronal section of costal cartilage. Disorganization is seen in area of calcification. Connective tissue elements are present, few cartilage cells are seen, and area has disrupted appearance. A, connective tissue elements in area of calcification; B, abnormal cartilage. (20 micra section, H&E stain, magnification 50x)

Figure 20. Photomicrograph of coronal section of costal cartilage. Note presence of osseous trabeculae in marginal calcification with islands of atypical cartilage. A, osseous trabeculae; B, cartilage islands. (20 micra section, H&E stain, magnification 35x)

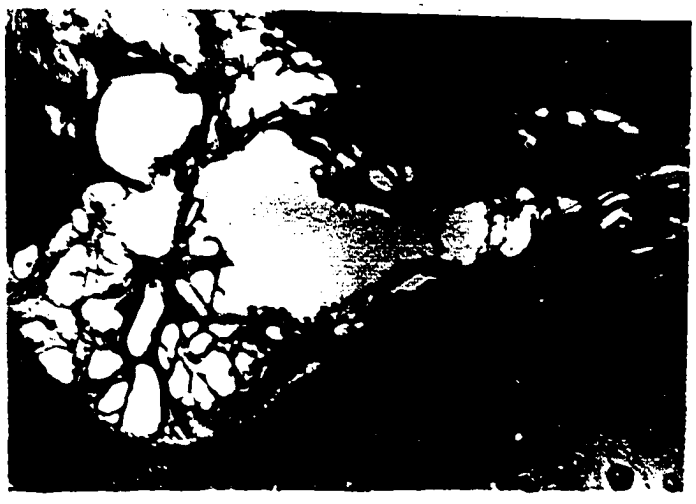

Figure 19



Figure 20

Figure 21. Photomicrograph of coronal section of costal cartilage. Osseous trabeculae are seen adjacent to region of abnormal appearing cartilage. A, osseous trabeculae; B, abnormal hyaline cartilage. (20 micra section H&E stain, magnification 20x)

Figure 22. Photomicrograph of coronal section of costal cartilage. Amorphic mass bordered on both sides by osseous tissue. On the gross radiograph this mass appeared as uncalcified chasms in first costal cartilage. A, compact bone; B, amorphic mass; C, clefts in amorphic mass. (20 micra section, H&E stain, magnification 50x)



Figure 21



Figure 22

The manubrio-sternal articulation. The articular surface between the manubrium and the body of the sternum consisted of fibrocartilage overlying the compact bone of these two structures. This fibrocartilage continued laterally into the sterno-chondral cavity as sternal articulating facets for the costal cartilage (Fig. 23). The orientation of the fibers in the cartilage was generally at right angles to the articular surface. The line of junction between the fibrocartilage and compact bone was indistinct. Staining characteristics were slightly basophilic and eosinophilic (Fig. 24). The ratio of matrix to cells in the manubrio-sternal fibrocartilage was high. The fibrocartilage was often seen to be continuous from the surface of the sternal body to the surface of the manubrium. When this occurred, the orientation of fibers appeared to be parallel to the manubrio-sternal articulation as well as vertical to this junction. The picture of initial calcification, described above in the section on costal cartilage, could also be seen in the manubrio-sternal fibrocartilage. This was represented by an increase in the eosinophilia which infiltrated the matrix between the cells. Occasionally islands of trabeculation were seen within the cartilage. More frequently trabeculation was observed as an extension of the osseous portion of the sternum. The fibers of the manubrio-sternal fibrocartilage were seen in most instances to fuse with the costal cartilage, thus contributing to the formation of the intra-articular ligament. The compact bone of the sternum was variable in thickness. In fact, in some areas the compact bone was almost entirely lacking and the marrow cavity was seen to border on the fibrocartilage (Fig. 25).

Figure 23. Photomicrograph of coronal section of sterno-chondral articulation. Continuity is seen between fibrocartilage of manubrio-sternal articulation and sternal facet of sterno-chondral articulation. A, compact bone of body of sternum; B, fibrocartilage of manubrio-sternal articulation; C, compact bone of sternal facet of sterno-chondral articulation; D, fibrocartilage of sternal facet of sterno-chondral cavity; E, sterno-chondral cavity; F, manubrio-sternal joint cavity. (20 micra section, H&E stain, magnification (20x)

Figure 24. Photomicrograph of coronal section of manubrio-sternal articulation. Junction of fibrocartilaginous layer with compact bone can be seen. Note orientation of fibers at right angles to articular surface. A, compact bone; B, junction of compact bone and fibrocartilage; C, fibrous elements in fibrocartilage. (20 micra section H&E stain, magnification 35x)



Figure 23



Figure 24

Figure 25. Photomicrograph of coronal section of manubrio-sternal articulation. Absence of compact bone is seen. Marrow cavity is adjacent to fibro-cartilage. A, manubrio-sternal fibrocartilage; B, marrow cavity; C, junction of compact bone and fibrocartilage. (20 micra section, H&E stain, magnification 50x)



Figure 25

In case of obliteration of the manubrio-sternal articulation, the fibrocartilage was replaced by an intermittent fibrous-appearing connective tissue. However, small areas of normal fibrocartilage were present in the region but followed no pattern. Bone spicules were seen to infringe upon the area in varying degrees.

Microradiographic Anatomy

Microradiographs were taken of cross sections of the second rib (26 specimens), and of coronal sections of the first costal cartilage (6 specimens), the second costo-chondral junction (18 specimens), the sterno-chondral articulation (14 specimens), and the manubric-sternal articulation (22 specimens).

Newborn

In the newborn only the costo-chondral junction and the sternal ossification centers are radiopaque and hence comprise the microradiographic investigation of these specimens.

Costo-chondral junction. Radiographs were taken of the costo-chondral junction of the newborn. A study of the junction showed radiopaque circles which were united at their circumference in such a manner as to give a beaded appearance (Fig. 26). The circumference of these circles displayed a high degree of x-ray absorption with the central portion showing little or no opacity. Filamentous, reticular connections of lesser opacity joined the beaded chains. Adjacent to this region, in the direction of the rib proper, calcified spicules were seen which upon histological examination evidenced little cellular detail (Fig. 27).

Figure 26. Microradiograph of coronal section of costochondral junction of newborn. Calcification typified by beads of radiopacity in region of hypertrophied cartilage cells. Bony rib located in direction of lower part of picture; cartilage of rib located in direction of upper part of picture. (40 micra section, magnification 35x)

Figure 27. Photomicrograph of coronal section of costochondral junction of newborn. Histological section comparable to microradiograph of Figure 25. A, columns of hypertrophied cartilage cells; B, areas of calcification comparable to radiopague area of Figure 25; C, spicules of calcified cartilage. (20 micra section, magnification 35x)



Figure 26



Figure 27

These spicules were more radiopaque than the trabeculae of the rib proper. In the rib a higher degree of organization was apparent in the trabeculae and lines of greater absorption were conspicuously present (Fig. 28). These did not have the appearance of the interlamellar lines of greater absorption seen in adult bone, but were of the nature of remnants of the calcified spicules observed in the area between the rib proper and the cartilage of the costo-chondral junction (Fig. 29). Organization of the trabeculae in the fetal rib showed the lacunae more rounded, lamellation not so evident, and variation in opacity greater than in the adult.

Adult

In the adult specimen in addition to osseous tissue, calcified cartilage was demonstrable. Opacities were studied in the microradiographs of the rib, the costo-chondral junction, the manubrio-sternal articulation, and the sterno-chondral articulation. In every instance both compact bone and spongy bone were evident.

Bone.

Compact bone. Morphological detail of the compact bone in these regions was very similar. Lacunae of the osteocytes were seen as oval or spindle shaped areas on the film. The film appeared blackened at lacunar sites. Rows of lacunae were concentrically arranged within the Haversian system around the central canal which appeared blackened on the film. Canaliculi were not visible on the microradiogram. The Haversian systems were seen to vary in their content of mineral salts. This variation was present throughout the cross section of the bone

Figure 28. Microradiograph of coronal section of rib of newborn. Remnants of calcified spicules from costo-chondral region represented by lines of increased opacity within trabeculae. A, osseous trabeculae; B, remnants of calcified spicules. (40 micra section, magnification 35x)

Figure 29. Photomicrograph of coronal section of rib of newborn. Histological section comparable to microradiograph of Figure 26. A, osseous trabeculae; B, remnants of calcified spicules. (20 micra section, magnification 35x)



Figure 28



Figure 29

irrespective of sub-periosteal, sub-endosteal or central location (Fig. 30). Thus in cross sections of the compact layer of interstitial lamellae various degrees of x-ray opacity were seen close to each other. The last formed sub-periosteal layers appeared as opaque as the inner zones. The interstitial lamellae, between Haversian systems exhibited a uniformly high degree of opacity. Within individual Haversian systemsthere was a gradation in mineral content. This was most evident in less mineralized systems. As mineralization increased, the density of the osteon became uniform. The area immediately surrounding the lumen of the Haversian canal was most opaque and absorption of x-rays decreased toward the periphery of the Haversian system (Fig. 31). A narrow area at the outer circumference of the Haversian system showed a high degree of radiopacity. Borders of resorption cavities are quite sharply defined and appear to invade bone tissue irrespective of age (Fig. 32). They are actively infringing upon Haversian systems. The endosteal surface of compact bone constantly appeared smoother than the periosteal surface. Concentration of lacunae were seen at the points at which the trabeculae were in contact with cortical bone (Fig. 33).

Spongy bone. Along the trabeculae of spongy bone, lacunae were arranged in longitudinal layers. These layers were seen to vary in their extent of mineralization, again without regard to peripheral or central location. Lines of increased x-ray absorption were oriented in the long axis of the trabeculae. The periphery of the trabeculae evidenced the same smooth appearance as the endosteal surface of compact bone. The marrow cavities were completely radio-translucent (Fig. 34).

Figure 30. Microradiograph of cross section of adult rib. Compact bone seen as layers of varying opacity. Note translucency of lacunae, smooth endosteal surface and roughened periosteal surface. A, endosteal surface; B, periosteal surface; C, Haversian canal. (50 micra section, magnification 35x)

Figure 31. Microradiograph of cross section of adult rib. Variation in x-ray absorption seen within individual Haversian systems. Note differences in opacity between individual lamellae, and the increased opacity of layer next to Haversian canal. A, variation in opacity within individual Haversian system; B, layer next to Haversian canal. (40 micra section, magnification 35x)



Figure 30



Figure 31

Figure 32. Microradiograph of cross section of rib of adult. Borders of resorption cavity seen to be sharply defined. Note increased opacity of interstitial lamellae. A, resorption cavity; B, interstitial lamellae; C, marrow cavity. (40 micra section, magnification 35x)

Figure 33. Microradiograph of cross section of adult rib. Concentration of lacunae at point at which trabecula is in contact with cortical bone. A, trabecula; B, cortical bone; C, concentration of lacunae. (40 micra section, magnification 35x)

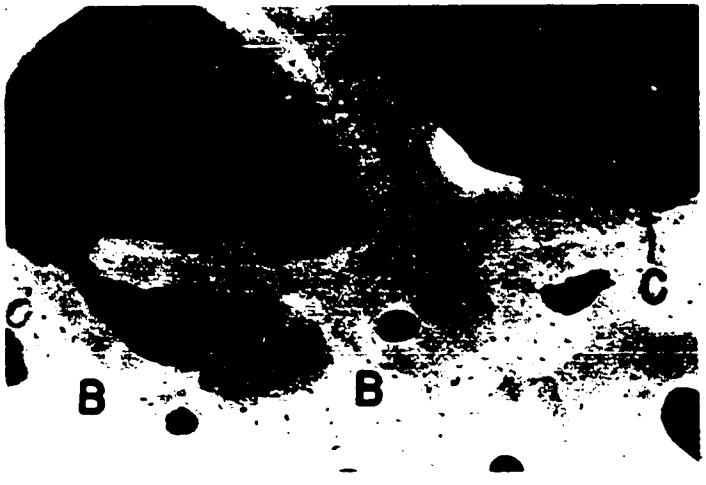

Figure 32



Figure 33

Calcified cartilage. Cartilage becomes radio-opaque whenever mineral deposition occurs. The extent of this deposition was investigated. Microradiographs were taken of representative sections of various patterns and locations of calcification as they were demonstrated on the gross radiographs of adult bone.

Articular surfaces of the manubrio-sternal and sterno-chondral articulations. The fibrocartilage of these articulations was investigated with respect to its appearance on the microradiograph. The articular surfaces of the manubrio-sternal articulation and of the sterno-chondral articulation revealed an uneven, jagged layer immediately external to the compact bone (Fig. 35). This jagged layer evidenced a high degree of x-ray absorption. There was no apparent organization in this region of increased opacity. The layer contained several small round radio-translucent circles of variable size. They were usually three to four times the size of the osseous lacunae although some were much larger. Filmy extensions and connections of radiopacity were observed throughout this layer. The extent of this area of increased opacity varied from narrow linear representation to an area comparable in thickness to the thickness of the compact bone of these articulations. Regions were seen in which the compact bone underlying the jagged layer of the articular surface was completely lacking.

Costal cartilage. Calcification of the first and second costal cartilage was studied from microradiographs of the area between the costo-chondral junction and the sterno-chondral articulation. Varying

Figure 34. Microradiograph of coronal section of sternum. Lacunae of spongy bone arranged into longitudinal layers. Note variation in opacity between adjacent lamellar layers and smooth surfaces of the trabeculae similar to endosteal surface. A, longitudinal rows of lacunae; B, smooth surface bordering marrow cavity; C, absorption differences in lamellar layers. (40 micra section, magnification 35x)

Figure 35. Microradiograph of coronal section of sternum. Articular surface of manubrio-sternal articulation displays uneven jagged layer immediately external to compact bone. This layer evidences a high degree of x-ray absorption. A, jagged layer; B, compact bone; C, trabecula. (50 micra section, magnification 20x)



Figure 34



Figure 35

amounts of radiopacity were observed in the cartilage proper. Most frequently this region was slightly radiopaque, even if no calcification could be demonstrated on gross radiographs. This slight radiopacity, when observed, was present throughout the cartilaginous area. Minimal opacity caused by calcification appeared, when present, as sheets or clusters consisting of many small circular or oval structures (Fig. 36). These small units were most radiopaque at their circumferences. Their location appeared to coincide with the articular surface of the costal cartilage. In some instances the radiopacity increased in extent so that these small circles resembled doughnut-like structures, with the opacity representing approximately one-third of the diameter of the unit. Areas were seen in which the whole oval structure was radiopaque. However, the most dense area was always at the periphery and opacity decreased toward the center. Areas of intermediate density in the cartilage were also observed. They resembled the areas of minimal calcification but contained larger deposits of mineral salts. They were similar to the jagged layer of the articular surface of the bone described above. These areas appeared as a reticulum of circles with connecting threads of radiopacity. In some instances they assumed a granular appearance. Areas of maximal radiopacity due to increased calcification could also be found in the area of the cartilaginous articular surface. These appeared as amorphic masses of dense radiopacity. Small circular cavities of radio-translucency were apparent in these regions (Fig. 37). On occasion areas of osseous trabeculae were seen in continuity with these dense areas (Fig. 38). These trabeculae did not appear to possess

Figure 36. Microradiograph of coronal section of costal cartilage. Minimal calcification represented by circular areas of increased radiopacity. (40 micra section, magnification 35x)

Figure 37. Microradiograph of coronal section of costal cartilage. Maximal radiopacity amorphically arranged. Note circular areas of radiotranslucent cavities. (50 micra section, magnification 35x)



Figure 36



Figure 37

Figure 38. Microradiograph of coronal section of costal cartilage. Trabeculation seen adjacent to areas of extensive calcification. Note minimal amount of organization and difference in opacity between trabecula and area of calcification. A, trabeculae; B, area of maximal calcification. (50 micra section, magnification 35x)



Figure 38

the degree of organization present in osseous tissue proper, but were easily recognized as bone. They were seen most commonly in the central region of the costal cartilage with only minor degrees of lamellary organization.

CHAPTER IV

DISCUSSION

Investigation of the sterno-chondral junction in the fetus and newborn indicated possible developmental causes for adult variations in the appearance and location of the intra-articular ligament and the cavitation present in this articulation. Cavities in the sterno-chondral junction of the fetus and newborn were reported by Tschaussow (1891), Gray and Gardner (1943), and Williams (1957). Pohlmann (1933) did not find cavities present in the newborn. He considered the existence of these cavities, reported in the literature to be artifacts caused by the technique of preparation of the specimens. Williams (1957) found cavities above and below the intra-articular ligament. In the newborn he also noted obliteration of the upper portion with patency of the lower portion of the articulation, and obliteration of the lower portion with patency of the upper portion. His description of the sterno-chondral articulation in the newborn was confirmed by this investigation. The position and extent of the intra-articular ligament, the extent of cavitation in the sterno-chondral articulation, and the relationship of the upper and lower portions of the sterno-chondral cavity seen in the adult were observed in varying developmental stages in the fetus.

In this investigation, double cavities present in adult specimens

were considered as such even if strands of tissue crossed the upper or lower portion of the cavity or a partial ligament existed lateral to the mid-point of the cavity. Double cavities were found in the newborn in fifty per cent of the specimens studied. The incidence in this work of double cavities in the newborn confirms the findings of Williams (1957). The percentage of double cavities in the adult specimens was slightly higher, occurring in fifty-five per cent of the specimens. The observations in the adult specimens agree closely with the findings of Musgrove (1892) and Bryce (1915), but the percentage of double cavities in the material was approximately twice that noted by Gray and Gardner (1943). The latter were not explicit in their definition of what they considered double cavities. This difference might therefore be one of classification.

Fusion of the sternal and costal articular facets of the sterno-chondral cavity with subsequent obliteration was observed in the adult (Figs. 2c, 2d). The incidence of this finding agrees with observations made by Gray and Gardner (1943). An homologous situation was present in the newborn, in cases in which no cavity was seen to occur. In disagreement Williams (1957) found cavitation in all of his human newborn specimens. The complete absence of the intra-articular ligament occurred in the adult in the same frequency (ten per cent) as did complete obliteration of the sterno-chondral cavity. Gray and Gardner (1943) also found this to be the case. Absence of the intra-articular ligament results in a single cavity (Fig. 2a). This condition was not observed in the newborn.

The radiate sternal ligaments appeared to be continuous with the articular capsule in all specimens studied. This is in complete agreement with the classical description of this structure (Cunningham, 1951). It was found in this investigation that the articular fibrocartilage of the sterno-chondral joint fused laterally with the perichondrium and the periosteum of the costal cartilage and sternum, respectively, as reported by Hass (1943).

The histological study of the sterno-chondral articulation confirmed the findings of Haas (1914) in revealing the articular surface to be fibrocartilaginous. An eosinophilic layer, two to three cells in thickness, superficial to the compact bone of the sternal facet displayed a high degree of radiopacity. Circles of translucency were seen on the microradiograph in this layer in the same location as the hypertrophied cartilage cells in the histological section. In disagreement with Gray and Gardner (1943) continuity of fibrocartilage uniting the sternal articular facets and the articular facets of the costal cartilage occurred where the intra-articular ligament was observed grossly. This continuity varied from complete obliteration of the cavity to intermittent strands of tissue crossing the cavity. The tissue crossing the cavities differed from the fibrocartilage of the articular facets in an increase of the matrix-to-cell ratio of the tissue.

Gray and Gardner (1943) maintained that calcification did not extend into the fibrocartilage of the sterno-chondral articulation. However, in this study, calcification in the form of osseous trabeculae was occasionally seen in the fibrocartilage of the sternal facet. These

trabeculae appeared to be projections from the underlying compact bone. Areas of fibrocartilage were seen to project between the trabeculae and the bone of the sternal facet to give the islands of ossification a mushroom like appearance. In addition to these trabeculae, calcification in the fibrocartilage was further confirmed by the zone of increased radiopacity between the fibrocartilage and the compact bone (Fig. 35). In agreement with Gray and Gardner (1943) compact bone of the sternal facets was occasionally entirely lacking in some areas. The marrow cavities in these cases were in direct contact with the fibrocartilage.

The manubrio-sternal articulation was immobile in approximately one-fourth of the specimens studied. This figure agrees with Trotter's observation (1934) in white females, but is higher than her findings in white males, colored females, and colored males. Ashley (1954) reported immobility in ten per cent of individuals dying beyond the age of thirty, irrespective of race or sex.

Pohlmann (1933) reported an interspace between the manubrium and the body of the sternum in the manubrio-sternal articulation. He observed complete separation of these two parts of the sternum by the interspace, lateral and medial position of the interspace, and continuity of the interspace with the cavity of the sterno-chondral junction. His findings were confirmed in this investigation. Continuity between the manubrio-sternal interspace and the sterno-chondral junction occurred when a single cavity was present (Fig. 2a), when the intra-articular ligament was present (Figs. 2g, 2h), and when only the lower or upper part of the cavity was patent (Figs. 2c, 2d).

Continuity was observed between the fibrocartilage of the manubrio-sternal articulating surface and the mid-point of the costal cartilage. Hayner (1935) stated that the intra-articular ligament was virtually an extension of the manubrio-sternal fibrocartilage onto the costal cartilage. His observations were substantiated by this investigation. Continuity was also observed in the fetal articulation.

The highly staining layer described above at the junction of the compact bone and fibrocartilage of the sterno-chondral cavity was also observed in the manubrio-sternal articulation. Thus three components of the manubrio-sternal articulation and the sterno-chondral articulation were observed to be continuous; the compact bone, the layer of increased opacity situated between the compact bone and the fibrocartilage, and the fibrocartilage. The layer situated superficial to the compact bone appeared to be an area of calcification because of its similarity in degree of radiopacity to that evidenced in other sites of calcification.

Extensive calcification in the form of trabeculation (Fig. 3j) was observed in the gross radiographical study of the first costal cartilage in three-fifths of the specimens. The histological and microradiographic study showed this trabeculation to be osseous in nature. The developing patterns reported by Böhmig (1928), Ernst (1929), Heinrich (1941), and Köhler (1930) could not be explored in this study, due to the predominance of older individuals in our material. One-half of our specimens were over sixty years of age. The small number of cases in the younger age groups makes it impossible to comment on the sequence in pattern of developing calcification.

Amorphic calcification occurred frequently in the first cartilage. This should be clarified by stating that, in the gross radiograph, areas of trabecular texture were observed to be interrupted by areas of solid calcification. Such a change was tabulated both as trabeculation and as being amorphic in character.

Uncalcified hiatuses in the first cartilage were seen in approximately one-fourth of our specimens (Figs. 4h, 4i). Heinrich (1941) stated that these chasms, which occur constantly at the sternal and costal junctions, resulted in the formation of an intermediate piece of bone. However, it was found in this study that these hiatuses occurred not only at the sternal and costal junctions but within the medial portion of the cartilage as well (Fig. 3h). This is in agreement with the findings of Stehr (1936). In keeping with the work of Ernst (1929), Stehr (1936), and Heinrich (1941) exostoses were found to be prevalent on the inferior margin whenever these uncalcified chasms occurred (Figs. 4h, 4i). The histological sections showed these chasms to possess borders of bone and atypical cartilage. When this extent of change was observed in the costal cartilage, islands of abnormal cartilage were invariably seen in the ossified cartilage with little normal cartilage being present. The extent, location, and form of persisting cartilage islands does not suggest an organized, oriented process.

The earliest calcification in the first cartilage occurred in a twenty-five year old white male. This was later than the date of beginning calcification reported by Köhler (1930), Michelson (1934), King (1939) and Brailsford (1948), and earlier than that reported by

Falconer (1938) and Riebel (1929).

In the second cartilage calcification occurred most consistently at the sternal extremity (Fig. 4b). Next in frequency were central calcifications along the long axis of the cartilage (Fig. 4c), calcific deposits along the inferior margin (Fig. 4d), and at the costal extremity (Figs. 4f, 4g). Trabeculation was seldom observed on histological and microradiologic sections. Calcification of a minimal nature occurred in three-fourths of the cases which would confirm the findings of Heinrich (1941) as well as the scheme of Köhler (1930)in which the second cartilage was seen to show the smallest amount of calcification.

On the gross radiograph, calcification in the first two cartilages exhibited the same amount of opacity as the osseous trabeculae of the rib or sternum. In the microradiograph, however, the density was conspicuously greater wherever the deposits were shown to be amorphic (Fig. 38). This difference in opacity of the costal calcifications on gross radiography and microradiography can be explained by the fact that on the microradiograph the thickness of the osseous sections through ribs or sternum and the thickness of the costal calcifications in equalized. This results in a greater degree of absorption of x-rays by the denser calcifications as contrasted against the loosely textured trabecular bone. On gross radiography the osseous structures compensate by their larger diameter for this textural difference.

In disagreement with the findings of Fischer (1955) and Heinrich (1941) calcification was entirely absent in one-tenth of the specimens studied. From a total of 70 specimens two evidencing no calcification

in the first cartilage, and three displaying absence of calcification in the second cartilage were over sixty years of age. One specimen was in the forty-six to fifty year age group and the remainder were under twenty-five years of age. Köhler (1930) and Ernst (1929) report finding lack of calcification only occasionally in older age groups. It was surprising therefore to find three individuals of advanced age, in our limited number of specimens, with no demonstrable calcifications.

It is suggested that the term ossification in radiological literature originated from the study of calcification of the first costal cartilage. The use of this term, if it is to include histological characteristics, should be limited to the first cartilage. Histologically ossification is not complete even in the first cartilage. Islands of calcified cartilage are always present. The only similarity in calcification patterns between the first and second cartilages was the inframarginal occurrence. It should be realized that since the extent of calcification in the first cartilage usually is so much greater than in the second, a comparison of the characteristics of calcification in the two cartilages is difficult. The calcification pattern of the first cartilage may have resembled that of the second at some earlier stage of its development, since the calcification change in the first cartilage always seemed to be more advanced than that in the second. In the light of their studies, Ernst (1929), Köhler (1930), and Heinrich (1941) came to the same conclusions.

Calcification has been interpreted as a degenerative change by Huyssen (1925), Falconer (1938) and Grieg (1931), and a normal physiologic

response of the cartilage to stress and strain by Köhler (1930) and King (1939). Its occurrence at an early age, in ninety to ninety-five per cent of the population, and in healthy individuals seems to indicate that calcification is a normal physiological process. In contradistinction, the microscopically demonstrable lack of organization, together with the bizarre patterns seen on gross radiograph and microradiographs would tend to support the concept of a degenerative change. In conclusion, if the process is to be considered a normal physiological change, then it should be realized that the attainment of this normal response, i.e., trabeculation and ossification follows an atypical course.

A study of fetal bone on routine histological sections gave insight into calcification as revealed by microradiography. Round circles of radiopacity present in minimal calcification can be correlated with the location of hypertrophied cartilage cells. While the hypertrophied cartilage cells showed no mineral content on the histological slide they appeared in the microradiograph as surrounded by circles of radiopacity (Fig. 36). These areas of radiopacity were present wherever calcification occurred. They were especially conspicuous in minimal calcification when the individual units of calcification could be discerned (Fig 36). Mineral deposits present between cells in the region of developing bone resulted in columns giving a beaded appearance (Fig. 26). Increase in opacity in a corresponding region of the normal epiphysis was reported by Sissons (1950). From the microradiograph it can be deducted that calcification occurs not within the cartilage cell

itself, but rather in the intercellular matrix. This agrees with the classical histological description of intercellular calcification, (Ham, 1953; Maximov and Bloom, 1952; Cowdry, 1950). The role played by calcified spicules in bone formation is indicated by the presence of remnants of these spicules within the osseous trabeculae of the rib proper (Fig. 28).

The presence of varying amounts of radiopacity throughout the compact layer of bone indicates that osteons vary in their degree of mineralization. Engström and Wegstedt (1951) concur in this observation. The opacity of the subperiosteal primary bone further reveals that this bone, shortly after its formation, attains a high degree of mineralization which remains relatively constant. This confirms the observations of Amprino and Engström (1952) and Engström, Bellman and Engfeldt (1955) who found that the subperiosteal layers absorb x-rays to the same degree as the inner zones of the compacta. No decrease of x-ray absorption in the area of the resorption cavities suggests that demineralization does not occur prior to the activity of resorption. In agreement, Amprino and Engström (1952) found that the marginal layer of the resorption cavity, even when actively resorbing osteoclasts were present, was as radiopaque as the neighboring bone tissue. In concurrence with Engström and Engfeldt (1953) translucency at the lacunar sites indicates the presence of osteocytes.

Bohatirchuk (1954) treats the absence of canaliculi in the microradiograph as evidence of their being non-existent and caused by artifacts on histological sections. It is our interpretation that canaliculi were

not seen because they were too small in comparison with the thickness of the section and hence gave no increase in transparency compared to the surrounding matrix. This concept was initially advanced by Amprino and Engström (1952).

The microradiographic appearance of the roughened external surface of the subperiosteal bone indicates that mineralization evidently continues into the periosteum of the bone (Fig. 30). The interstitial cementing lines surrounding each osteon were highly x-ray absorbent. This concurs with the observation of Engström, Bellman and Engfeldt (1955). The increase in radiopacity at these sites indicates a greater mineral content per unit area in the interstitial cementing lines.

Microradiography is unexcelled in the demonstration of the distribution of mineral salts in undecalcified bone. It is the method of choice in investigations concerning the mineral content of bone since it does not require demineralization previous to the processing of bone for microscopic study. With more refined equipment, Engström and coworkers have shown microradiographical quantitative studies to be valuable and consistent with other biophysical and chemical methods (Engström, 1949; Engström, et. al., 1949; Engfeldt, et. al., 1952; Engström, 1951). In concurrence with Mitchell (1951), however, it is thought that microradiography should be considered not a substitute for, but rather a supplement to, routine histological technique, as exemplified by the investigations presented herein.

CHAPTER V

SUMMARY AND CONCLUSIONS

1. Gross anatomical, histological, gross radiographical, and microradiographical techniques were utilized to study the anatomy of the sterno-chondral articulation of the second rib, the manubrio-sternal articulation, the costal cartilage of the first rib, and the costal cartilage and costo-chondral junction of the second rib.

2. The sterno-chondral cavity of the second rib appeared as a double cavity in fifty-nine per cent of the specimens. The upper portion of the sterno-chondral cavity was obliterated with the intra-articular ligament extending from the costal to the sternal surface in thirty-four per cent of the cases. In these instances, the lower portion remained patent. Obliteration of the entire cavity and absence of the intra-articular ligament with a resultant single articular cavity were observed in nine per cent of the cases. The cavity continued into the manubrio-sternal articulation in sixty per cent of the specimens. Conditions were observed in the newborn to indicate that adult variations might be of developmental origin rather than a degenerative or adaptive change.

The articular surfaces of the sterno-chondral cavity were composed of fibrocartilage. On the microradiogram, a layer of tissue superficial to the compact bone evidenced a high degree of radiopacity. The

compact bone of the sternal facets varied in thickness.

3. The intra-articular ligament was present at the mid-point of the sterno-chondral cavity in fifty-one per cent of the cases (in the white male specimens this was evident in only forty per cent). This ligament divided the cavity into upper and lower portions. Strands of tissue were observed crossing the cavity from the sternal to the costal surfaces in eight per cent of the specimens. The ligament was displaced laterally in thirty-four per cent of the cases.

4. The manubrio-sternal articulation was movable in seventy-eight per cent of the specimens. The manubrium and sternum were separated by an interspace in the manubrio-sternal articulation. Complete separation of these two parts of the sternum by the interspace, lateral and medial position of the interspace, and continuity of the interspace with the cavity of the sterno-chondral junction were observed. Continuity between the manubrio-sternal interspace and the sterno-chondral junction of the second rib occurred when there was a single cavity present, when the intra-articular ligament was present, and when only the lower or upper part of the cavity was patent. Fibrocartilage of this articulation was not evident, i.e., the manubrium and body of the sternum had the appearance of a single bone, in thirteen per cent of the specimens.

5. Calcification extending from the costal to the sternal margins in the form of trabeculation was the most prevalent pattern encountered in the first costal cartilage. This occurred in sixty-two per cent of the specimens. The histological and microradiographical study showed this trabeculation to be osseous in nature. Uncalcified hiatuses

visible within the calcified portion in twenty-nine per cent of all specimens occurred not only at the sternal and costal junctions but within the central portion of the cartilage as well. Exostoses were found to be prevalent along the inferior margin whenever these uncalcified chasms occurred. Seventeen per cent of the specimens revealed calcification along the inferior border of the costal cartilage. The earliest calcification in the material was seen in the first cartilage in a twenty-five year old white male.

6. In the second cartilage, calcification occurred most consistently at the sternal extremity being found in fifty-eight per cent of the specimens. Next in frequency were central calcification along the long axis of the cartilage in twenty-seven per cent, calcific deposits along the inferior margin in twenty-four per cent and, at the costal extremity in nineteen per cent. Amorphic deposition of calcium was the type most frequently seen. In the second costal cartilage sixty-seven per cent of the specimens showed one to twenty per cent calcification.

7. While trabeculation throughout the first costal cartilage was observed frequently, this was seldom evident in the second costal cartilage. When it was observed, it was located peripherally.

8. Histologically the areas of calcification appeared disorganized. This disorganization consisted of an increased eosinophilia, diminution of cellular content, and hypertrophy of cells. Vascular elements were invariably present in areas of calcification.

9. Microradiographically, calcification was conspicuous by an

increased degree of x-ray absorption. Patterns of calcification were observed encircling areas of radio-translucency. The latter were considered to be hypertrophied cartilage cells with calcification occurring intercellularly.

10. Cellular detail is not visible on the microradiogram, but variation of mineral deposits is evident in the interstitial lamellae, the lamellae of spongy bone, and between individual osteons. Variation in mineral deposition in the constituent parts of the osteon (the lamellar layers, the lacunae, the interstitial cementing substance, and the lining of the Haversian canal) is easily recognized on the microradiograph. This makes the method an important tool in the study of bone and calcification patterns which effectively supplements histological procedure.

BIBLIOGRAPHY

Amprino, R., and Engström, A. 1952. Studies on x-ray absorption and diffraction of bone tissue. Acta anat. 15:1-22.

Ashley, G. T. 1954. Morphological and pathological significance of synostosis at manubrio-sternal joint. Thorax 9:159-166.

Benson, J., and Sanderson, J. R. 1953. Simplified bone decalcifier. U. S. Armed Forces M.J. 4:1215-1219.

Bezançon, F., Jacquelin, A., and Tribout. 1925. "De l'ossification des cartilages costaux dans la tuberculose pulmonaire et des erreurs d'interprétation qui en resultent sur films. Rev. Tuberc. 6:525-536. Cited by King, J. B. 1939. Calcification of costal cartilages. Brit. J. Radiol.12:2-12.

Böhmig, R. 1928. Über die kataplastischen Veränderungen im Rippenknorpel des menschlichen Körpers. Beitr. path. Anat. 81:172.

Bohatirchuk, F. 1954. Some microradiographical data on bone ageing. Brit. J. of Radiol. 27:177-182.

Boyd, G. A. 1955. Autoradiography in Biology and Medicine. Academic Press, New York.

Brailsford, J. F. 1948. Radiology of Bones and Joints. Williams and Wilkins, Baltimore.

Brash, J. C. 1951. Cunningham's Textbook of Anatomy. Ninth Edition, Oxford University Press, London.

Bryce, T. H. 1915. Quain's Elements of Anatomy. Longmans, Green, New York.

Carleton, H. M., and Drury, R. A. B. 1957. Histological Technique. Oxford University Press, London.

Cowdry, E. V. 1950. Textbook of Histology. Fourth Edition, Lea and Febiger, Philadelphia.

deSousa, A., and deSousa, J. F. 1956. An experimental study in microcholangiography. Brit. J. of Radiol. 29:377-380.

Engström, A. 1951. Cytochemical analysis of elements by roentgen ray. Acta radiol. 36:393-396.

Engström, A. 1949. Microradiography. Acta radiol. 31:503-521.

Engström, A., Bellman, S., and Engfeldt, B. 1955. Microradiography: A review. Brit. J. of Radiol. 28:517-532.

Engström, A., and Engfeldt, B. 1953. Lamellar structure of osteons demonstrated by microradiography. Experientia. 9:19.

Engström, A., Hamberger, C. A., and Welin, S. 1949. Roentgen-ray microspectrographic investigation of the inflammatory destruction of the mastoid bone. Brit. J. of Radiol. 22: 309-324.

Engström, A., and Lindström, B. 1951. The properties of fine-grained photographic emulsions used in microradiography. Acta. radiol. 35:33-44.

Engström, A., and Wegstedt, L. 1951. Equipment for microradiography with soft roentgen rays. Acta radiol. 35:345-355.

Engfeldt, B., Engström, A., Helander, C. G., Wilton, A., and Zetterström, R. 1952. Biophysical studies of bone tissue. Acta Path. et Micro. Scand. 31:256-261.

Ernst, G. 1929. Die Verkalkungsvorgänge an den Rippenknorpeln. Fortschr. a. d. Geb. d. Röntgenstrahlen. 39:485-494.

Falconer, B. 1938. Calcification of hyaline cartilage in man. Arch. Path. 26:942-955.

Fischer, E. 1955. Verkalkungsformen der Rippenknorpel. Fortschr. a. d. Geb. d. Röntgenstrahlen. 82:474-481.

Gershon-Cohen, J., and Delbridge, R. E. 1945. Pseudoarthrosis, synchondrosis and other anomalies of first ribs. Am. J. Roentgenol. 53:49-56.

Gladstone, R. J.,and Wakely, C. P. G. 1932. Morphology of sternum and its relation to ribs. J. Anat. 66:508-564.

Goss, C. M. 1954. Gray's Anatomy of the Human Body. Twenty-sixth Edition, Lea and Febiger, Philadelphia.

Gray, Peter. 1954. The Microtomist's Formulary and Guide. Blakiston, New York.

Gray, D. J., and Gardner, E. D. 1943. Human sternochondral joints. Anat. Rec. 87:235-253.

Gurr, E. 1953. A Practical Manual of Medical and Biological Staining Technique. L. Hill, London.

Greig, D. M. 1931. Clinical Observations on the Surgical Pathology of Bone. Oliver and Boyd, London.

Hale, A. R., and Snook, T. 1949. An inexpensive and convenient source of direct current designed for electrolytic bone decalcification. Anat. Rec. 103:571.

Ham, A. W. 1953. Histology. Second Edition, J. B. Lippincott, Philadelphia.

Haas, S. L. 1914. Regeneration of cartilage and bone with a special study of these processes as they occur at the chondrocostal junction. Surg. Gynec. and Obst. 19:604-617.

Hass, G. M. 1943. Studies of cartilage; morphologic and chemical analysis of aging human costal cartilage. Arch. Path. 35: 275-284.

Hayner, J. C. 1935. Regional Anatomy. William Wood, Baltimore.

Heinrich, A. 1941. Alternsvorgänge im Röntgenbild. Georg Thieme, Leipzig.

Henle, F. G. J. 1871. Handbuch der Systematischen Anatomie des Menschen. F. Vieweg und Sohn, Braunschweig.

Hurrell, D. J. 1935. Vascularisation of cartilage, J. Anat. 69:47-61.

Huyssen, Ch. A. 1925. Untersuchungen zur Frage des Zusammenhanges der Rippenknorpel und der Gefässverkalkungen (im Sinne der Arteriosclerose). Schweiz. Med. Wchnschr. 54:1010-1015, cont. 54: 1037-1040.

Ikeda, T. 1932. Histological study on the region of chondrocostal junction of consecutive age in humans. Sei-I-Kwai M.J. (abstr. sect.) 51:1-6.

King, J. B. 1939. Calcification of costal cartilages. Brit. J. of Radiol. 12:2-12.

Köhler, A. 1939. Röntgenology, the Borderlands of the Normal and Early Pathological in the Skiagram. Bailliere, Tindal and Cox, London.

Köhler, A., and Zimmer, E. A. 1956. Borderlands of the Normal and Early Pathologic in Skeletal Roentgenology. English translation by J. T. Case of Tenth German Edition. Grune and Stratton, New York.

Linberg, B. E. 1925. Zur Pathologie der posttyphösen Rippenchondritis. Virch. Arch. f. Path. Anat. 258:367-404.

Maximow, A. A., and Bloom, W. 1952. Textbook of Histology. Sixth Edition, W. B. Saunders, Philadelphia.

McClung, C. E. 1950. Microscopical Technique. Third rev. Edition. Paul B. Hoeber. Harper, New York.

Meyer, P. C. 1956. Histological identification of osteoid tissue. J. Path. and Bact. 71:325-333.

Michelson, N. 1934. Calcification of first costal cartilage among whites and Negroes. Human Biol. 6:543-557.

Musgrove, J. 1892. Costo-sternal articulations. J. Anat. and Physiol. 27:1-4.

Nikolajew, O. 1927. Zur Frage der Gefässversorgung der Rippenknorpel. Anat. Bericht. 9:460.

Noback, C. R. 1944. Developmental anatomy of human osseous skeleton during embryonic, fetal and circumnatal periods. Anat. Rec. 88:91-125.

Orban, J. B. 1957. Oral Histology and Embryology. Fourth Edition, C. V. Mosby, St. Louis.

Perry, J. T. 1956. Mechanically sealed beryllium windows for permanently evacuated x-ray tubes. Rev. of Sci. Instrum. 27:759-762.

Pohlmann, H. 1933. Entwicklung, Wachstum, und Altersveränderungen der Intersternalsynchondrose mit Berücksichtigung der zweiten Sternocostalverbindung. Ztschr. Konstitutionslehre. 17:641-687.

Riebel, F. 1929. Ossification of costal cartilages; their relation to habitus and disease. Am. J. Roentgenol. 21:44-47.

Rist, E., Gally, L., Trocme, C. 1928. L'ossification des cartilages costaux dans l'espèce humaine; étude d'anatomo-radiologie statistique. Presse med. 36:641-644.

Schaeffer, J. P. 1953. Morris' Human Anatomy. Eleventh Edition, Blakiston, New York.

Sissons, H. A. 1950. Microradiography of bone. Brit. J. of Radiol. 23:2-7.

Stehr. L. 1936. Über die Verkalkung der Rippenknorpel und ihre Einwirkung auf die Brustatmung. Fortschr. a. d. Geb. d. Röntgenstrahlen. 54:360-373.

Tirman, W. S., and Banker, H. W. 1951. A simple method of microradiography using ordinary diagnostic x-ray equipment. Science. 113:530-531.

Trotter, M. 1934. Synostosis between manubrium and body of the sternum in whites and Negroes. Am. J. of Phys. Anthropol. 18:439-442.

Tschaussow, M. 1891. Zur Frage über die Sternocostalgelenke und den Respirationstypus. Anat. Anz. 6:512-524.

Vastine, J. H. II, Vastine, M. F., and Oriol Arango. 1948. Genetic influence on osseous development with particular reference to deposition of calcium in costal cartilages. Am. J. Roentgenol. 59:213-221.

Wernscheid, H. 1923. Über die Verknöcherung der Rippenknorpel. Medizin. Klinik. 19:572-574.

Williams, M. 1957. Morphology of sternochondral joints of mammals. J. of Morph. 101:275-306.

Youngstrom, K. A. 1953. Calcified costal cartilage. U. S. Armed Forces M. J. 4:455-456.