UNIVERSITY OF OKLAHOMA

GRADUATE COLLEGE

EXAMINING PRESERVATION OF PATHOLOGICAL LESIONS IN CREMATED HUMAN SKELETAL REMAINS FROM THE ARCHAIC PERIOD SITE OF PHALERON, GREECE

A THESIS

SUBMITTED TO THE GRADUTE FACULTY

in partial fulfillment of the requirements for the

Degree of

MASTER OF ARTS

By

Megan C. Walsh
Norman, Oklahoma
2024

EXAMINING PRESERVATION OF PATHOLOGICAL LESIONS IN CREMATED HUMAN SKELETAL REMAINS FROM THE ARCHAIC PERIOD SITE OF PHALERON, GREECE

A THESIS APPROVED FOR THE
DEPARTMENT OF ANTHROPOLOGY

BY THE COMMITTEE CONSISTING OF

Dr. Jessica Cerezo-Román, Chair

Dr. Thomas Fenn

Dr. Susan Alcock

© Copyright by MEGAN C. WALSH 2024
All Rights Reserved.

Acknowledgements

I am sincerely grateful to Dr. Jessica Cerezo-Román, my advisor, for her invaluable support throughout the thesis process. Without her patience, guidance, and support this work would not have been possible. Thank you for sharing your passion for cremation analysis with me. The time I spent with you in Athens was the most I have ever learned and was an experience I will not soon forget, constructing this thesis was an added bonus. I look forward to working with you in the future and continuing to learn from you in our future endeavors.

Thank you to both Dr. Thomas Fenn and Dr. Sue Alcock for their contributions, regarding this thesis and my professional growth. You each have taught me innumerable things about archaeology, writing, and how to navigate academia as a young professional. I will leave this graduate program a better scholar because of the wisdom and advice you have kindly bestowed upon me. In addition, a thank you Dr. KG Anderson for the coffee chats and great conversations about fossil hominids and primates.

A massive thank you to my family. To my parents who have bolstered my courage to take risks, have supported me in every facet of my life, and have endured many hours of conversation about burned bone and ancient Athens. To my siblings Caleb and Maddy, who can't tell a radius from an ulna but think what I do is "super cool." Everything I do is to make you proud.

Thank you to Horvey, Robin, and Britt who I call my grad school friends but have easily become lifelong besties, you each have inspired me in so many ways. Words cannot express my gratitude to each of you. Thanks to Rachel, Hannah P., Hannah R., and Nadia for keeping me grounded and sane throughout this process. Last, but not least thank you to Joseph Rovinsky who

constantly reminds me of my potential and inspires me every day, I hope to become even half the person you are someday.

This research was made possible by funding and support from the Phaleron Bioarcheological Project, Malcom H. Wiener Laboratory for Archaeological Science of the American School of Classical Studies at Athens, University of Arizona, and the National Science Foundation (NSF BCS-1828645). Additionally, the University of Oklahoma Graduate Student Senate Research Grant, the M.E. and L.R. Opler Endowment/Morris E. Opler Memorial Scholarship distributed by the University of Oklahoma Department of Anthropology, and the Robberson Research Grant. Excavation and availability of archaeological information was made possible by Μαρίνα Βελεγρακη, Anna Alexandropoulou, and Stella Chryssoulaki. Accommodations and curation of remains for this analysis was facilitated by Dimitris Michailidis, Panagiotis Karkanas, and the faculty of the American School of Classical Studies at Athens. A special thank you to Dr. Jane Buikstra, the Primary Investigator for the Phaleron Bioarchaeological Project. Dr. Buikstra's exemplary work serves as a constant source of inspiration, and the privilege of learning from her expertise has truly been invaluable. Thank you for allowing me the opportunity to work on this project.

Table of Contents

CHAPTER 1: INTRODUCTION 1

Research Questions and Hypotheses 1
Question I *1*
Question II 2
Question III 2

Organization of Thesis 3

CHAPTER 2: BACKGROUND 4

Cremation in the Archaeological Context 4
Terminology 5

History of Cremation Analysis 7

Formation Process, Taphonomy, and Preservation 13
Thermal Alteration and Preservation 14

Paleopathology 16

Pathological Studies of Cremations 21

Phaleron 23
The Phaleron Bioarchaeological Project 25
Burials of Phaleron 26

CHAPTER 3: METHODS AND MATERIALS 28

Cremations of Phaleron 28

Cremation Analysis 29
The Biological Profile 29
Taphonomy 30
Inventory 31
Sex Estimation 32
Age-at-Death Estimation 34

Pathological Analysis 36

Observational Statistics 40

CHAPTER 4: RESULTS 42

Preservation 42
Preservation of Bones by Skeletal Region 45

Pathology 49

Cranial Lesions 53
Porotic Hyperostosis 54
Cribra Orbitalia 57
Cranial Periosteal Reaction 59

Axial Lesions 62

Schmorl's Nodes 63
Axial Skeleton Periosteal and Lytic Reactions 66
Appendicular Lesions 67
Appendicular Skeleton Periosteal Reaction 68
Extremities Lesions 75
Extremities Periosteal Reaction 76
Degenerative Joint Disease And Osteophytes 77
Spinal Osteophytes 79
CHAPTER 5: DISCUSSION 81
Revisit the Reseach Questions 81
Question I 81
Question II 89
Question III 90
Applications to Bioarchaeology and Cremation Studies 97
Limitations 99
Future Directions 100
CHAPTER 6: CONCLUSION 104
Future Directions of this Research 105
REFERENCES 107
APPENDIX A: SKELETAL RECORDING FORMS 131
APPENDIX B: EXPANDED PRESERVATION OF ELEMENTS BY SKELETAL REGION 171

List of Tables

Table 1 Total Preservation of Sample……42

Table 2 Average Preservation of Bones from the Cranium for Each Individual (n=38)……...45

Table 3 Average Preservation of Bones from the Axial Skeleton for Each Individual (n=38)….46

Table 4 Average Preservation of Bones from the Appendicular Skeleton for Each Individual (n=38)…….47

Table 5 Average Preservation of Bones from the Extremities for Each Individual (n=38)……..47

Table 6 Full Sample Skeletal Assessments of the Presence, Absence, or Unobservability of Pathological Lesions……..50

Table 7 Absence, Presence, and Unobservability of Lesions Throughout the Skeleton and Preservation for Every Individual in the Sample……...50

Table 8 Observed Lesion Frequency in Sample Individuals: Porotic Hyperostosis……..54

Table 9 Location and Preservation of Fragments with Porotic Hyperostosis……54

Table 10 Observed Lesion Frequency in Sample Individuals: *Cribra Orbitalia*……..56

Table 11 Location and Preservation of Fragments with *Cribra Orbitalia*……57

Table 12 Observed Lesion Frequency: Cranial Periosteal Reaction in Individuals……..59

Table 13 Individuals with Present Cranial Periosteal Rection……..59

Table 14 Observed Lesion Frequency: Schmorl's Nodes in Individuals……..63

Table 15 Preservation of Vertebrae with Present Schmorl's Nodes……..64

Table 16 Observed Lesion Frequency: Axial Skeleton Periosteal Reaction in Individuals……..65

Table 17 Observed Lesion Frequency: Axial Skeleton Lytic Reaction in Individuals…….65

Table 18 Observed Lesion Frequency: Appendicular Skeletal Periosteal Reaction in Individuals…….67

Table 19 Individuals with Presence of Appendicular Periosteal……...69

Table 20 Preservation of Appendicular Elements with Present Periosteal……....71

Table 21 Observed Lesion Frequency: Extremities Periosteal Reaction in Individuals……75

Table 22 Presence of Degenerative Joint Disease by Joints in the Skeleton…….77

Table 23 Spinal Osteophyte Presences by Vertebrae……78

List of Figures

Figure 1 Photograph of Cremation IV-670: Example of Partial Skeleton 43

Figure 2 Photograph of Cremation IV-263: Example of Fragmentary Skeleton 44

Figure 3 Photograph of Cremation IV-769 (Individual B): Example of Fragments of Bone 44

Figure 4 Presence, Absence, and Unobservability of Cranial Lesions 54

Figure 5 Photograph of Porotic Hyperostosis on an Unsided Parietal Fragment from IV-277 56

Figure 6 Microscopic View of Porotic Hyperostosis on an Unidentified Cranial Vault Fragment from IV-791 56

Figure 7 Photograph of Cribra Orbitalia on Orbital Roof of IV-665 58

Figure 8 Microscopic View of Cribra Orbitalia on Orbital Roof of IV-729 59

Figure 9 Photograph of Sclerotic Bone (Periosteal Reaction) of the Maxillary Sinus of IV-729 61

Figure 10 Microscopic View of Sclerotic Bone (Periosteal Reaction) of the Maxillary Sinus of IV-729 61

Figure 11 Absence, Presence, and Unobservability of Pathological Lesions in the Axial Skeleton 63

Figure 12 Photograph of Schmorl's Node on 5th Lumbar from IV-787 64

Figure 13 Photograph of Lytic and Periosteal Reaction on 1st Lumbar from IV-787 67

Figure 14 Absence, Presence, and Unobservability of Pathological Lesions in the Appendicular Skeleton 68

Figure 15 Photograph of Sclerotic Periosteal Reaction in Tibia Fragments from IV-787 69

Figure 16 Photograph of Woven Bone on the Ulna from IV-755 74

Figure 17 Microscopic View of Sclerotic Bone with Microporosity on a Humerus from IV-789 74

Figure 18 Absence, Presence, and Unobservability of Pathological Lesions on the Extremities 75
Figure 19 Photograph of Sclerotic Bone in an Unidentified Pedal Fragment from IV-750 (Ind A) 76
Figure 20 Marginal Lipping (Evidence of DJD) on the Distal Humerus (Elbow) from IV-548 .. 79
Figure 21 Photograph of Spinal Osteophyte Formation on the 5th Lumbar Vertebra from IV-548 80
Figure 22 Preservation of the Cranium by Bone and Side……...161
Figure 23 Preservation of the Axial Skeleton by Bone……162
Figure 24 Preservation of the Vertebral Column (Axial) by Bone……..163
Figure 25 Preservation of the Appendicular Skeleton by Bone……...164
Figure 26 Preservation of the Left Arms (Appendicular) by Bone…….165
Figure 27 Preservation of the Right Arms (Appendicular) by Bone……...166
Figure 28 Preservation of the Left Legs (Appendicular) by Bone……...167
Figure 29 Preservation of the Right Legs (Appendicular) by Bone……168
Figure 30 Preservation of the Hands (Extremities) by Bone……...169
Figure 31 Preservation of the Feet (Extremities) by Bone……..170

Abstract

Preservation of pathological lesions is an underexplored aspect of cremation analysis. This thesis focuses on the preservation of pathologies in a sub-sample of primary cremations (n=38) from the Archaic Period (800-480 BCE) archaeological site of Phaleron, Greece. Phaleron is an important site to the Athens/Attica region due to its impressive size and the regional lack of large contemporaneous skeletal samples from the Archaic Period.

This thesis strives to critically examine preservation, pathological lesions, and fine-tuned methods for data collection in cremations, guided by three major research questions: 1) Which skeletal regions and bones are the most well-preserved in cremation? 2) How might standard bioarchaeological methods be modified for a refined analysis of paleopathology in highly fragmented and burned human skeletal remains? 3) What pathological lesions are observable in cremations?

This investigation was executed through a meticulous inventory and reconstruction process. A careful analysis was conducted on the entire skeleton, skeletal regions, bones, and fragments from each individual to estimate preservation. Each cremation was analyzed through this standardized methodology so that results were comparative, despite variable preservation throughout the sample. Pathological data collection, centered on the categorical variables of present, absent, and unobservable of pathological lesions, was recorded through the skeletal regions. When the pathological data was considered in tandem with total skeletal/skeletal element preservation, a more robust understanding of pathological lesion preservation became more clear. In this case, the unobservable variable was as telling as the presence/absence of pathological lesions.

The total preservation assessment concluded that the majority of the sample (52.6%) were fragmentary skeletons or <25% complete and included at least one complete element. A total of 36.8% of individuals were categorized as partial skeletons (25-75% complete) and 10.5% of the sample was represented by a few fragments of bone. The results of the skeletal region and bone preservation suggest that bones that are thick and dense as well as those incased in flesh are the most well-preserved in cremations. Bones of the cranial vault (cranium), thoracic and lumbar vertebrae (axial skeleton), long bones (appendicular skeleton), and tarsals (extremities) were among the most well-preserved skeletal elements. In some cases, preservation was more contingent on size of fragment as opposed to number of fragments. For example, the cervical vertebrae were identified in higher frequencies than the thoracic and lumbar while the thoracic and lumbar were represented in larger more reconstructable fragments, allowing for the observation of pathological lesions.

Pathological lesions that manifest on well-preserved elements were the most identified in the sample. Lesions associated with non-specific and repetitive biomechanical stress were identified throughout the sample. These lesions include porotic hyperostosis (occipital), *cribra orbitalia* (orbital roof/frontal), Schmorl's nodes (lower vertebrae), and periosteal reaction throughout the skeleton, but most notable in long bones. In addition, degenerative joint disease and spinal osteophytes were noted in cremations throughout the sample. Preservation allowed for the observation of absence/presence of pathological lesions in 89.5% of individuals, with 71.1% reflecting presence of one or more pathological lesions. Lesions were observable in both fragmentary and partial skeletons, but unobservable in the individuals represented by a few fragments of bone. Importantly, the observed pathologies are reflective of the minimum number of pathological lesions present in each individual.

Overall, this study affirms that with methodical examination and slight methodological modification pathological lesions can be observed with relative clarity in highly burned and fragmented human skeletal remains. These results contribute to the growing body of cremation literature focused on more biologically driven research questions. Future directions for this project include the addition of the cultural, social, mortuary context from the site of Phaleron to further explore preservation of cremations and themes related to health and disease in ancient Athens and Attica.

Chapter 1: Introduction

The Phaleron cemetery, discovered in the early 20th century and excavated from 2012-2020, is an Archaic Period (800-480 BCE) archaeological site located in Phaleron Bay, Greece. The excavation at Phaleron unearthed approximately 1,900 burials, making it one of the largest samples and most significant skeletal assemblages from the Archaic Period in Greece (Buikstra 2023). Before the true extent of Phaleron was discovered, large burial assemblages from the Archaic Period had been sparsely identified. Much of the knowledge of Archaic Period burials and burial practices had some from small assemblages in sites such as Keramiekos and the Agora (Camp 2001). The skeletal assemblage from Phaleron has the potential to significantly contribute knowledge both regionally and temporally to the current understandings of the Archaic Period in Athens/Attica, Greece (Buikstra 2023).

RESEARCH QUESTIONS AND HYPOTHESES

Approximately 10% of the 1,900 burials at Phaleron have been identified as primary cremations (Prevedorou and Buikstra 2019). This thesis examines preservation of pathological lesions from a subsample (n=38) of highly fragmented and burned human skeletal remains. The objective of this thesis is to understand and quantify preservation of skeletal elements, pathological lesions, and their correlations in the primary cremations from Phaleron. Therefore, it is pertinent to lay out the research questions and hypotheses that guided the investigation. This project strived to answer the following research questions:

Question I: In cremated human skeletal remains, which skeletal elements or regions remain well-preserved? Are any well-preserved skeletal elements common sites for the manifestation

of pathological lesions? Are any common sites of skeletal pathology lost or poorly preserved in cremations?

Hypothesis I: Skeletal elements that are denser and thicker, as well as those encased in flesh, muscles, tendons, and ligaments will preserve the best post-incineration. Therefore, pathological lesions that manifest in these skeletal regions will be the most observable. Adversely, skeletal elements that are thinner and frailer may be poorly preserved post-incineration. In the event these bones are poorly preserved, pathological data will be unobservable.

Question II: ***How might standard bioarchaeological methods, paleopathological data collection, and analysis (created for mostly complete, well-preserved, and unburned skeletons) be applied and/or modified to study cremated human skeletal remains?***

Hypothesis II: Traditional paleopathological data collection may be conducted with little modification for burned and fragmented human skeletal remains. Further analysis and interpretations of pathology in cremations will require slight adaptation, including close attention to the transformations imposed by thermal alteration.

Question III: ***Amongst the sample, which lesions can be observed when analyzing cremated human skeletal remains? Of the lesions that can be observed, what insights might they contribute to the understanding of pathology, disease, and health in ancient Athens and Attica?***

Hypothesis III: The lesions that manifest on elements that preserve well post-incineration, will remain observable in cremations. These findings will represent the minimum observation of pathological lesions in each individual, as some lesions will be undetectable post-incineration. Nonetheless, these finding will lead to understandings of pathology and disease in the individuals that were analyzed.

ORGANIZATION OF THESIS

This thesis begins with the relevant background focusing on cremation research, paleopathology, and preservation followed by a focus on the Phaleron site, Archaic Period (800-480 BCE) Athens/Attica, and the Phaleron Bioarchaeological Project in Chapter Two. Chapter Three outlines in detail the standardized methodological approach taken to inventory and analyze each individual within the sample. The results of the holistic preservation analysis, overall observed pathological lesion frequency, and pathologies by skeletal region are presented throughout Chapter Four. Chapter Five utilizes the findings in Chapter Four to address the research questions and hypotheses outlined above, and further elaborates on applications to bioarchaeology and cremation research, limitations of the analysis, and future directions of cremation research at large. Chapter Six synthesizes the thesis and discusses future directions for research regarding the cremations from Phaleron.

Chapter 2: Background

This chapter presents the relevant background information to the project, which is composed of themes regarding cremation, preservation, paleopathology, and the subsequent intersections of these topics. The first section begins with the broad definition and discussion of terms concerning cremations in the archaeological record followed by how cremations are studied within bioarchaeology. Preservation, taphonomy, and the formation process of archaeological remains are discussed briefly and narrowed to focus on thermal alteration to bone and its effect on preservation of cremations. The chapter continues by outlining paleopathology in bioarchaeology, what pathological lesions can be observed in the human skeleton, and how pathologies have been studied in cremation projects. The latter half of the chapter focuses more specifically on the site of Phaleron from Archaic Period, Athens (800-480 BCE), beginning with a brief outline of the social, political, and cultural shifts of the Archaic Period and focusing more expansively on the excavation, curation, and on-going research of the larger "Phaleron Bioarchaeological Project." The chapter concludes focusing specifically on the burial context of inhumations and the cremations found at Phaleron.

CREMATION IN THE ARCHAEOLOGICAL CONTEXT

Cremation is a mortuary ritual that includes the exposure of a body to fire, for an extended period of time. This ritual is highly variable dependent upon the cultural context, time period, and geographical location of the cremation ritual (Williams 2015). Despite how variable cremations are there are some universal commonalities that may be discussed. The cremation process transforms the body from unburned to burned. This burning can be a complete process reducing the entire skeleton to bone fragments and ash. Alternatively burning of the body might

be partial or accidental (Williams 2015). The human remains for this project were burned intentionally as part of the mortuary ritual and are represented as burned, fragmented bone (see Chapter 4 for preservation).

The incineration process may cause a myriad of transformations affecting the soft tissue, hard tissue, and histology of the bone. Focusing specifically on the skeleton, exposure to fire often causes bone to shift in color, warp, crack, fragment, and change in chemical composition (Correia 1997; Thompson et al. 2017). These transformations are highly dependent upon how the cremation ritual is executed and the individual being burned. These factors may include, the duration of burning (Bohnert et al. 1998), maximum temperature of the fire (Bonucci and Graziani 1975), body position on the pyre (Steward 1979; Symes et al. 2008), body mass index of the individual (May 2011), and if the individual was burned with or without flesh (Buikstra and Swegle 1989; Gonçalves et al. 2011; Symes et al. 2008), differentially contribute to how a body is effected by the cremation process. Pyre construction, climatic conditions, and handling of the body during and after cremation also effect preservation. These factors include but are not limited to burning materials, accelerant, weather conditions, humidity, stirring of the body on the pyre, and cooling methods including pouring water or wine on the pyre (Cerezo-Román 2013; Cerezo-Román et al. 2017; DeHaan 2018; McKinley 2015, 2016; O'Donnell 2016; Thurman and Willmore 1982; Walker et al. 2008; Williams and Wessman 2017). Any combination of these variables may lead to differences in patterns of thermal alteration, preservation, and observability of elements in burned human skeletal remains. Even individuals burned in the same cremation context may reflect differences despite being burned in the same way (Richard 1977).

Terminology

Specialists throughout the field utilize terminology concerning cremations to mean a variety of similar, but slightly different things (Quinn et al. 2014). This portion serves to define and standardize the terminology used in this thesis. The term cremation is used most generally, to describe an individual that was burned or otherwise intentionally exposed to fire as part of the mortuary ritual (Cerezo-Román 2013). Cremation, individual, and the categorization number given in the field (e.g. IV-58) are used interchangeably throughout the thesis to signify a single set of burned skeletal remains.

Pyre and primary cremation are used interchangeably throughout the thesis refers to a cremation deposit that is composed of burned human skeletal remains as well as direct evidence of fire (Cerezo-Román 2013). Additionally, the connotation of a pyre or primary cremation is that the body was placed and burned *in situ*. This may allow for greater preservation but does not insure the articulation or complete presence of all skeletal elements (Cerezo-Román 2013).

In contrast, secondary cremation refers to burned human skeletal remains that were removed from their primary deposit context and placed elsewhere (Cerezo-Román 2013). Each secondary cremation begins as a pyre or primary cremation, but once removed become a secondary cremation deposit (Cerezo-Román 2013). While there are no secondary cremations in the study sample, they are often contrasted with primary cremations in discussions of preservation.

Throughout this thesis, the term inhumation refers to deposits in which unburned individual(s) were buried, and where decomposition occurred (Cerezo-Román 2013). Although the sample for this project did not include any inhumations, the investigation examines the differences and commonalities in the methods and interpretations of cremations and inhumations.

HISTORY OF CREMATION ANALYSIS

Cremation analysis is often conducted by bioarchaeologists, archaeologists, and forensic anthropologists, therefore it is important to discuss the positionality of bioarchaeology within the broader discipline of anthropology as well as where cremation analysis is situated within the subfield. Buikstra (1977) coins the term "bioarchaeology," although the study of human skeletal remains in antiquity substantially predates such definition. Buikstra's 1977 publication encourages an "inter-disciplinary" approach in which both physical (now biological) anthropological and archaeological methods and theories are combined and deployed in studying human skeletal remains. Since the late 70's bioarchaeology has flourished into a subdiscipline of biological anthropology analyzing human skeletal remains from the past, with several specialties and foci including but not limited to: paleopathology, dental anthropology, and cremation analysis (Larsen 2015). The human skeleton is arguably one of the greatest, most direct remanent of our past and in research helps us to understand health, diet, occupations, migration, paleodemography, and much more.

The study of cremations arises around the mid-twentieth century. Wilton Krogman (1949) first takes an interest in burned and fragmented bones from an Ohio Mound, noting that some bones were recognizable despite their fragmented state. Krogman (1949) conducts an experiment on fleshed bone, green bone, and dry bone to examine fraction patterns from exposure to fire. While Krogman (1949) concludes that it is possible to destroy a human body with fire, this study emphasized key features of cremation that are still researched today. These factors include the maximum temperature of the fire, source of heat exposure to the body, and the relationship between agitation to burning remains and fragmentation (Krogman 1949).

This research encourages scholars such as Raymond Baby (1954) and Lewis Binford (1963) to examine highly fragmented and burned human skeletal remains. Baby (1954) explores warping and cracking in fleshed vs. dry bone. Stating that when dry bones are burned, they present with superficial checking, fine longitudinal striae, deep longitudinal fracturing, and absence of warping. Adversely, bones burned with flesh presented with warping, diagonal transverse fracturing, and deep checking (Baby 1954). These findings were corroborated by Lewis Binford (1963) nearly ten years later. The research of Baby (1954) and Binford (1963) help to establish cremation analysis in the 1950's and 1960's.

In the following decades this interest begins to grow into a specialty, garnering more attention from (bio)archaeologists which brings about methodological refinement to the study of cremations. Major themes of research included color and chemical composition change, skeletal completeness, warping, shrinking, and fragmentation. During this time Bonucci and Graziani (1975) focus on identifying stages of burning as bones become dehydrated. Color changes of bones as they progress through the stages of cremation are cataloged and described by Shipman (et al. 1984) and Dunlop (1978). Shipman (et al. 1984) finds that through exposure to heat, bones progress through a continuum of colors, from brown to white (calcined). Dunlop (1978) notes that metal present at the time of burning may correlate to colors such as pink (copper), green (iron), and yellow (zinc).

Shrinkage is analyzed as it relates to both maximum temperature of the fire (Dokládal 1971; Van Vark 1970, 1974, 1975) and flesh/moisture in the remains (Buikstra and Swegle 1989; Johnson 1985; Grupe and Herrmann 1983; Steward 1979). Further, maximum temperature of the fire is explored as it relates to the sequence of flesh destruction, bone exposure, and chemical transformation of bone (Herrmann 1977; Richard 1977). Richard (1977) notes bone exposure

and the progression of flesh destruction above 680 degrees Celsius, identifying that bones that are encased in tissue may be more well-preserved. Herrmann (1977) explores burned bone microscopically, noting changes in the chemical structure including loss of organic material and fusion of bone mineral crystal above the 700-800 degrees Celsius. Steward (1979) builds upon these findings and stresses the importance of careful examination which may be telling of body positioning in the fire and if a body was burned fleshed or dry.

A replicative cremation experiment was conducted by Thurman and Willmore (1982) with both flesh and fresh but defleshed (or green) human humerii to observe effects of burning. Their study found that burned fleshed bones presented with warping, transverse fractures, and diagonal cracking. Adversely, green bone presented with much less warping and serrated fractures near epiphyses and parallel-sided margins throughout the bone (Thurman and Willmore 1981). Bradtmiller and Buikstra (1984), microscopically explore burned bone and variables of the burning process that may impact age estimation. Using samples of fleshed and dry bone, Bradtmiller and Buikstra (1984) find that bone burned at 600 degrees Celsius retain histological structures that may be used for age estimation.

In addition to these studies, an attention to skeletal completeness, cremation weights, and minimum number of individuals (MNI) of deposits becomes a topic of interest in cremation research. Cremation weight research largely suggests a fairly complete cremation of an adult from an archaeological assemblage should weight approximately 1,500 grams or more (Cerezo-Román 2015). Therefore, cremations less than 1,500 grams may suggest a less complete individual and a weight much larger may suggest an MNI greater than one. This weight varies between cremations of adults and subadults (Bass and Jantz 2004; Cerezo-Román 2015; McKinley 1989, 1994, 2000; McKinley and Bond 2001; Murray and Rose 1993; Sonek 1992;

Trotter and Hixon 1974). There may be substantial weight disparities between archaeological bone deposits as noted by McKinley (2000, 2001). McKinley (2000, 2001) finds that an archaeological cremation deposit may weight anywhere from 57 grams to 3000 grams. They suggest this weight disparity could be due to the presence of an individual represented by just a fraction of their complete skeleton or the presence of multiple individuals (McKinley 2000, 2001). Adult cremation weights will also vary depending upon the sex, ancestry, stature, and/or presence of pathological conditions that affect bone density such as osteoporosis (Bass and Jantz 2004; Sonek 1992; Trotter and Hixon 1974).

This brief summary of cremation research only begins to illustrate the growth of the discipline over the last half century. For more comprehensive reviews see Correia (1997) and Ubelaker and Shamlou (2023). Moreover, many of these themes still play a central role in contemporary cremation research (as discussed below). Additionally, the analysis of burned human skeletal remains has amassed significant attention in forensic anthropology as a means to identify victims (Fairgrieve 2007). Burned human remains in the forensic context are often victims of house fires, wildfires, murder, or mass disasters (Fairgrieve 2007).

Cremation analysis to this point is largely conducted by specialists that have extensive training in the analysis of highly burned and fragmented human skeletal remains. Cremation specialists' emphasize the "transformation by fire" (Quinn et al. 2014). On a material level cremation fundamentally transforms bones causing fragmentation, warpage, shrinkage, biochemical and color change. resulting in an altered yet inherently recognizable form of human skeletal remain (Quinn et al. 2014). Such transformation of bone requires additional methods including reconstruction and thermal alteration analysis in addition to the standard biological profile (see Chapter 3). In this way, while cremation analysis is complex, time-consuming, and

seldomly as straightforward in comparison to the analysis of inhumations, it offers a wealth of knowledge.

Twenty-first century cremation research can generally be grouped by two major themes or goals—studies of the mortuary ritual of cremation framed in social theory and the creation and refinement methods of cremation analysis. A major focus of cremation studies utilizes theoretical perspectives to understand the mortuary ritual of cremation and how the cremation process is informative of social themes. These theoretical frameworks include but are not limited to archaeology of ideology and power, human agency, social identity and personhood, religion and cosmology, and social memory as noted by Cerezo-Román and Williams (2014). Many edited volumes consider these themes such as *Cremation and the Archaeology of Death* (Cerezo-Román et al. 2017), and *Transformation by Fire: The Archaeology of Cremation in Cultural Context* (Kuijt et al. 2014). Such edited volumes explore regionally and temporally diverse cremation rituals through a social theoretical framework. Cerezo-Román (2015) takes such an approach to cremation research in order to understand personhood and funerary customs in the Hohokam area of southern Arizona. In this study, the biological profile(s) of 764 individuals are reconstructed and contextualized in the framework of the broader funerary customs of the region, and careful attention is paid to the post-humous treatment of the remains. Cerezo-Román (2015) finds that, overtime, aspects of personhood change in accordance with post-humous treatment of the cremations.

The creation, modification, and refinement of methods used in cremation analysis is another major component of research conducted by cremation specialists. This is done through the modification of methodological approaches utilized in the bioarchaeology of unburned skeletons to be more applicable to burned human skeletal remains (Cerezo-Román 2020;

Willams 2023). This approach is accompanied by the creation and addition of methods tailored specifically for cremations used to estimate biological profile variables, such as sex (Hlad et al. 2021). In addition to these methods for skeletal analysis, some specialists work to further understand the incineration process on the human body and subsequent thermal alterations (Adserias-Garriga 2023; Ellingham et al. 2023 Klales et al. 2023; Thompson 2023). This includes color description and change (Ellingham and Zapico 2023; Galloway et al. 2024; Symes et al. 2008; Symes et al. 2014; Walker 2008), fragmentation (Duday et al. 2000), skeletal completeness (McKinley 2004), and pre-burning conditions of the human remains (Duday and Guillon 2006; Symes et al. 2008; Symes et al. 2013; Thompson 2023). This research is often conducted by cremation specialists in bioarchaeology and forensic anthropology, usually through means of experimental archaeology. These foci of cremation research significantly contribute to our understandings of the social-cultural aspects of cremations and the effects of fire on human skeletal remains. With that in mind, the largest critique of cremation research is the lack of standardization of cremation researchers globally, all of which use different methods and terminology in their analysis of cremations (Gonçalves and Pires 2017; Quinn et al. 2014).

This thesis is most similar to the latter cremation research. While a new approach to cremation analysis is not proposed, a combination of methods from Buikstra and Ubelaker (1994), the Arizona State Museum (2018), and the works of Cerezo-Román (2013, 2020) are utilized to focus specifically on preservation of pathological lesions. With these methods, including the careful reconstruction/inventory and close attention to preservation and thermal alterations (see Chapter 3), this thesis hopes to contribute to the larger understanding of what pathology data may be collected from primary cremations.

FORMATION PROCESS, TAPHONOMY, AND PRESERVATION

When discussing cremation analysis, it is important to consider preservation, taphonomy, and the formation process. Cremation analysis is heavily reliant on the elements that preserve and how affected they are by taphonomic changes. Estimation of sex and pathological data collection are often the most difficult in light of these changes (Cerezo-Román 2013).

Taphonomy is first coined by Efremov (1940) and was broadly used to describe the transformation caused by biotic and abiotic pressures in the archaeological record. The original usage was concerned with the "natural" influences, but more recently there has been a recognition of human behavior and activities that may affect deposits. Consequently, there has been a shift in bioarchaeology to address both "natural" (ie: animal activity and withering) and "cultural" (ie: specific mortuary ritual and postmortem body treatment) impacts on burials in the archaeological record (Büyükkarakaya et al. 2019).

Attention to the formation process, an approach pioneered by Michael Schiffer (1983), considers the larger processes that create taphonomic traces on artifacts and bones. These processes, both natural and cultural, must be considered when observing archaeological assemblages. Schiffer argues that inferences on poorly preserved and badly deteriorated deposits may be made confidently and contribute to our understanding of the past (Schiffer 1983). Factors such as density, shape, damage, quantity, horizontal and vertical distribution, density of the deposit, depositional disorganization, and reassembly are all factors that may be considered when observing the taphonomic changes in an archaeological assemblage. These factors may then be extended to pyres and secondary cremations (Schiffer 1983).

While Schiffer established and studied factors of the formation process and taphonomy, Henri Duday explores these themes as they relate to burials and cremations. Henri Duday (et al.

2009), introduces archeothanatology which enriches such conversations concerning preservation of the human skeleton post-burial. Archeothanatology takes a specialized approach to the interpretation of bodies through *mortuary* taphonomy. The central theme of archeothanatology is that the context of a burial is shaped by the deposition and taphonomic pressures on the body up until the grave is excavated (Gligor 2014). Archeothanatology considers both the mortuary ritual, such as body positioning and means of deposition, in tandem with natural pressures, such as gravity, to glean a comprehensive understanding of the burial process and its effects on preservation of the human skeleton (Duday 2009, Gligor 2014). In his seminal work, *The Archaeology of the Dead: Lectures in Archeothanatology*, Duday (2009) addresses cremations through an archaeothanatological lens. The authors discuss the transformations the skeleton undergoes when incinerated including deformation (warping), color change, and fragmentation. A central theme in this discussion is reconstructing the chronology of the deposition, especially in cases with more than one individual present (Duday 2009). These changes must be considered when conducting age and sex estimations, and especially in collecting pathological data from cremations.

Thermal Alteration and Preservation

As aforementioned, the cremation ritual imposes thermal alterations to skeletal remains which result in distinct changes to the preservation of bone. Bones, being composed of both organic and inorganic material, undergo a predictable chronology of change as the organic material burns away and the bone tissue becomes dehydrated, including chemical shifts and color change, warping/cracking and shrinkage, and fragmentation (Correia 1997; Thompson 2005). These changes often occur in tandem with one another as the body progresses through stages of

heating. In order to study cremations, understanding these changes and how they might differentially affect and change preservation is pertinent.

There are four stages of heating at which many of these changes take place. Beginning with dehydration stage, occurring around 150-600 degrees Celsius, at which water is removed from the bone. The loss of organic components of bone happens around 500-800 degrees Celsius, called the decomposition stage. Followed by the inversion stage from 700-1100 degrees Celsius, where bones lose all carbonates. Finally, the fusion stage which melts crystals in the bone around 1600+ degrees Celsius (Bonucci and Graziani 1975; Correia 1997; Shipman et al. 1984: Thompson 2004).

Color change can be considered the macroscopic evidence of chemical shifts in bone as it is exposed to fire (Delvin and Herrmann 2015). Burned bone progresses from brown, gray-blue, black, gray, gray-white, and white (Bonucci and Graziani 1975; Shipman et al. 1984). The color progression is dependent largely upon the temperature of the fire and length of burning (Symes et al. 2008). Cremations often present with one or more of these colors, and moreover a single fragment of bone can express any combination of color changes (Mayne 1990).

Warping, shrinking, and cracking are consistently noted within cremated samples and have been studied by numerous researchers (Baby 1954; Binford 1963; Buikstra and Swegle 1989; Symes et al 2008). Many of these studies strive to determine if a body was burned with flesh, partially moist, or dry which is largely debated in the field (Cerezo-Román 2013). Baby (1954) and Binford (1963) argue that warping is characteristic evidence of a body being burned with flesh (or at least some moisture). While Buikstra and Swegle (1989) argue that presence of warping and \is not exclusive to green (or fleshed) bodies. Gonçlaves (et al. 2011) further supports Buikstra and Swegle's conclusion and moreover suggests the warping, in both dry and

green bone, may be indicative of collagen preservation in bone. This debate aside, deformation of bone in the form of warping, cracking, and fracturing is a thermal alteration that affects observability and preservation in cremated human skeletal remains.

PALEOPATHOLOGY

The definition of paleopathological studies in bioarchaeology is often described simply, as the "study of ancient disease." In this case, disease transcends the simple classification of illness, rather incorporates any pathology that may diminish health or cause an impairment to normal function (Buikstra 2010). Broadly paleopathologists examine pathological lesions that manifest on human skeletal remains. Lesions can be related to a number of pathological conditions and etiologies and present most rudimentarily as abnormalities in bone. This is largely reflected through abnormal bone growth (sclerotic) or bone loss (lytic). Paleopathologists may identify lesions are evidence of bacterial, fungal, parasitic, and protozoan infections. Circulatory, hematological, endocrine, growth (dysplasia), and metabolic disorders may produce observable lesions in the skeleton. In addition, congenital and neuromechanical anomalies, diseases of the joints, neoplastic conditions, and trauma may result in lesions that are observable in the skeleton. (Buikstra 2010, 2019). Paleopathological studies are most commonly done on human skeletal remains from the archaeological context but may also include mummies and specially preserved human remains such as "bog bodies" (Buikstra 2010; Lynnerup 2019). Additionally, paleopathological methods have recently been applied to modern samples (O'Donnell et al. 2020). Therefore, the emphasis on "ancient" in the definition of paleopathology may be a gross oversimplification of the wealth the discipline has to offer.

The study of paleopathology is profoundly interdisciplinary, combining methods and theories from biological, biomedical, social sciences, and humanities. This interdisciplinary approach allows for the description, classification, and diagnosis of lesions in the human skeleton so they may be extrapolated to explore health and disease in antiquity (Ortner 2011). The human skeleton acts as the primary source of data for paleopathological studies but are often paired with secondary sources including historical documents, iconographic depictions, grave goods, and oral/ethnographic accounts for descendant communities (Buikstra 2010). Further, paleopathological data must be contextualized within the broader archaeological and geographical framework from which the human remains originate, in order to examine a wider range of research questions and address interdisciplinary themes (Ortner 2003). This application of context makes paleopathological data more meaningful than simple descriptions of osteological lesions. See Chapter 3 for an expanded discussion of methods for paleopathological data collection.

In brief, paleopathological analysis requires an advanced knowledge of the trajectory of disease, an intimate understanding of the body's response to different illnesses, and detailed observations and descriptions of bony lesions (Ortner 2003). The researcher will describe the lesion through standardized terminology, making careful observations of the location on the skeleton, size of the lesion, healed vs. active, and type of bone change either proliferative (additional bone deposition) or lytic (bone loss) (Ortner 2003). After the lesion(s) have been accessed a rigorous differential diagnosis may be conducted, considering the lesions holistically in order to eliminate the least likely maladies, and narrowing to a "diagnosis" that fits the recorded pathological changes (Buikstra et al. 2017).

The interest and later study of what we now define as paleopathology studies has persisted for more than 200 years. Ubelaker (1982) argues the seeds of paleopathology as a research interest were sown in 1774 by Johann Fredrich Esper, a German naturalist, who identifies an osteoblastoma in a cave bear. The observation of paleopathology in human skeletal remains begins in the early 19th century (Angel 1981). These observations were often made by physicians, surgeons, and pathologists, that applied their contemporary knowledge of disease manifestation to skeletons from antiquity, with little respect to archaeology (Angel 1981; Grauer 2017). Most frequently their observations were brief, anatomical annotations of skeletal abnormalities compared to what was understood to be the "normal" human skeleton. During this time, these anatomical descriptions were not utilized to further explore the broader biological or pathological processes that were the cause of the lesions being described (Buikstra and DeWitte 2019). Grauer's 2017 publication "A century of paleopathology" cites Rudolph Virchow, Pierre Paul Borca, Armand Ruffer, Grafton Elliot Smith, and Frederic Wood Jones as 19th century visionaries that lay the groundwork for 20th and 21st century paleopathological studies. Cook and Powell (2006) find that the term paleopathology is coined in 1892 by R.W. Schufeldt and later defined as "the science of pathological conditions in the organs of extinct or petrified animals;" in the 1894 Standard Dictionary, vol 2 (Moodie 1923; Grauer 2017). The work of these early luminaries, allowed for the field of paleopathology to be well established in the early 20th century, making its formal debut in the *American Journal of Physical Anthropology* in 1920 (Grauer 2017).

Throughout the 20th century paleopathological studies shift as scholars' perception and understanding of disease change as noted by Grauer (2017). Early 20th century paleopathological studies conducted by medically trained anthropologists sought "evidence" of disease, relying

heavily on the dichotomy of "healthy individuals" vs. those that were "diseased (Grauer 2017)." Ruffer's (1921) studies with Egyptian mummies and Hooten's (1930) work amongst the Pecos Pueblos are excellent examples of these early medically minded approaches to the study of paleopathology. Such scholarship utilized large sample sizes, contextualized disease within the broader historical/archaeological framework, described lesions, and offered diagnoses while operating under a narrow understanding of disease transmission; often attributing disease to singular causative agents such as simple pathogens, poor diet, and environmental factors (Armelagos and Van Gerven 2003; Grauer 2017).

Contemporary paleopathological studies examine pathological data through the lens of social theory. Framing paleopathological data in social theory allows bioarchaeologists to transcend simple classifications of lesions to understand disease more intimately as it relates to social interactions, economic systems, and cultural change and practices in antiquity (Blakely 1987; Nystrom 2015; Rakin-Hill 2016). Further, bioarchaeologists may begin to understand how disease impacted the daily lives of the individual they are analyzing. The integration of feminist, gender, and queer theory to paleopathology in the late 20th and early 21st century has allowed for a more holistic view of health and disease with consideration to social identities and intersectionality (Agarwal 2012, 2016; Agarwal and Beauchesne 2011; Bengston and O'Gorman 2016; Cohen and Bennett 1993; Geller 2009; Grauer and Stuart-Macadam 1998; Martin et al. 2010; Sofaer 2006; Tung 2015). The application of theory including frameworks of socio-economic class (Blakely 1987; Nystrom 2015; Rakin-Hill 2016), human agency and identity (Stone et al. 2022), the Developmental Origins of Health and Disease Hypothesis (DoHAD) and life-course approached (Agarwal and Beauchesne 2011; Crespo 2020; Garland 2020; Gowland 2015; Ham et al. 2021), embodiment theory (Stone et al. 2022), and themes from bioarchaeology

of care have helped foster transdisciplinary research as well as contribute more robust and nuanced interpretation of disease in antiquity (Grauer 2018). Many of these themes are explored in edited volumes such as Agarwal and Glencross (2011) *Social Bioarchaeology*. Findings that have utilized social theory have kept the study of paleopathology relevant in contemporary bioarchaeological studies. The deep timescale offered by paleopathology allow researchers to foresee health trends in the present, predict the course of disease in the future, and critically analyze social structures and identities that surround illness in the past thus allowing them to be deconstructed in the present (Buikstra 2010).

In addition to social theory, paleopathological methodology has grown significantly with the introduction and availability of non-invasive technologies. Technologies including X-Rays, CT, and micro-CT allow for imaging of the bone without the need to disrupt the structure which would traditionally be considered "non-invasive (Chhemm et al. 2008; Saab et al. 2008)." Although, these radiographic methods can damage any remaining aDNA so they may not be as non-invasive as once believed, for this magnetic resonance imaging or MRI is more appealing (Buikstra 2010). Molecular (aDNA analysis of pathogens) and paleohistological approaches are also invasive methods but are highly utilized to study ancient disease in the 21st century (Aufderheide 2003; Drancourt and Raoult 2005).

Paleopathological studies commonly fall under four categories depending on the research objectives as defined in Buikstra (2010): 1) Paleopathological studies that methodologically or technical advance the discipline; 2) Case studies which detail an individual or small assemblages, adding regional or temporal knowledge of disease distribution and/or honing diagnostic techniques; 3) Studies that focus on a specific disease, often aimed at understanding dispersion throughout time and space and host-parasite evolution; 4) Investigations of population health,

which establishes a baseline and observes the health of a broader sample (Buikstra 2010). The study at hand strives to contribute and advance the methodological study of paleopathology in cremated human skeletal remains as well as identify lesions that preserve post-incineration.

PATHOLOGICAL STUDIES OF CREMATIONS

There is a notable lack of cremation studies with a specific focus on pathologies. While pathology data is collected and listed as part of the biological profile findings in many cremation projects, very few critically analyze or focus specifically on the data (Gonçalves and Pires 2017). This may be attributed to the lack of standardization in methodology in cremation analysis, the focus on studying the mortuary ritual, and the (sometimes presumed) lack of preservation on pathological lesions in cremation samples. Some notable investigations concerning preservation and pathological lesions in cremations include Salo (et al. 2022), Owens (2010), Veselka (et al. 2021), Mackiewicz and Szczurowski (2023), Reinhard and Fink (1994), and Scheelen-Nováček (et al. 2021).

Salo (et al. 2022) reports evidence of porotic hyperostosis, *cribra orbitalia,* periosteal bone formation, and osteoarthritis in their analysis of a cremation sample from Bronze Age Finland. The authors correlate these pathological finds with changes to subsistence strategies in the transition to more permeant settlements (Salo et al. 2022). Although this study discusses pathologies identified in cremated human remains, there is little discussion of the preservation or post-incineration condition of the remains of the sample.

Owens (2010) combines methodological approaches from biological anthropology and forensic science to estimate age, sex, health, and cause of death in cremated individuals. Throughout the investigation Owens (2010) mentions the lack of literature on pathological

lesions in cremations but finds that pathological lesions are identifiable in both non-calcined and calcined fragments. This finding opposed their hypothesis that bones burned at a lower temperature would reflect preservation of pathological lesions in a higher frequency (Owens 2010).

Mackiewicz and Szczurowski (2023) work to identify which skeletal elements are best identifiable after cremation in a sample from Paszowice, Poland. They find that fragments of the vertebrae and long bones are the most well preserved in cremations samples, as well as structures composed of compact bone including the temporal bone. In addition to preservation, they note evidence of degeneration throughout their sample of secondary cremations (Mackiewicz and Szczurowski 2023).

Reinhard and Fink (1994) is a notable study that considers the effects of incineration on the preservation and observability of pathological lesions, similar to this thesis. Their study is comparative, observing pathological preservation in both cremated and inhumated deposits from the Southwest. Reinhart and Fink (1994) find that certain pathologies were reliably reflected in cremated human skeletal remains. These pathologies included degenerative disease and porotic hyperostosis which were seen with great precision, whereas lesions associated with dental disease and *cribra orbitalia* (and the corresponding skeletal elements) were unobservable after the cremation process. They conclude that differing cremation practices may affect the preservation of pathologies more than others and that with an advanced knowledge of regional (and global) mortuary ritual, one might predict which cremation practices allow for or limit the collection of pathological data (Reinhart and Fink 1994).

Veselka (et al. 2021) explore diet, divergence, and disease in cremations in 5th and 6th century cremations from Echt, the Netherlands. This investigation combines known

paleopathological and demographic data with strontium isotope ratios and strontium concentrations on skeletal elements from a sample of 73 cremations to explore these themes. Through this investigation the authors find that nutritional deficiency likely contributed to the high prevalence of porotic hyperostosis amongst the sample. Further, the authors link this nutritional deficiency to decreasing food supply caused by climatic conditions (Veselka et al. 2021).

Scheelen-Nováček (et al. 2021) investigates a sample of 22 well-preserved cremations from the Roman Imperial Site of Gessel in Northern Germany. The authors observe lesions including cribra orbitalia, porotic hyperostosis, pitting of the sphenoid, porous ventral surfaces of the femoral head and of the vertebral bodies in five subadult cremations. The authors utilize light microscopic analysis to conclude these lesions are likely evidence of bone marrow expansion consistent with anemia. Further, individuals in the sample presented with cranial and post-cranial lesions consistent with scurvy and rickets. The lack of regional and temporal context limits the authors deduction to an etiological cause for the metabolic disease. Nutritional deficiencies, parasitic infections, and/or malaria are listed as potential causal agents, or a combination of co-morbidities (Scheelen-Nováček et al. 2021).

PHALERON

The cremated human skeletal remains for this investigation come from the site of Phaleron located in Attica at Phaleron Bay approximately four kilometers away from the Acropolis of Athens, Greece (Karakostis et al. 2021). Well-established ceramic chronology suggests the cemetery was active from the 8th to 4th century BCE, with the highest utilization during the Archaic Period (Prevedorou and Buikstra 2019). In short, the Archaic Period (800-480

BCE) serves as a major transitional period, formalizing traditions and creating foundational practices in Athens and Attica that persist through ancient Greek history and even to present (Osborne 2009; Prevedorou and Buikstra 2019). The Archaic Period marks the rise of the city-state in Athens (the polis). With rise of the polis comes the organization of governmental institutions, a recognition and celebration of major gods in Attica, the creation of Athens first written laws, the beginnings of Greek literature (Homer's *Iliad* and *Odyssey*, for example), and the foundations of democracy (Camp 2001; Osborne 2010; Prevedorou and Buikstra 2019).

In antiquity, Phaleron served as the original port city of Athens prior to the early fifth century (Osborne 2009; Prevedorou and Buikstra 2019). Presently, the site at Phaleron is well known for its impressive size and special burials that deviate from the standard mortuary rituals, including burials which suggest violent deaths, captivity, and execution (Ingvarsson and Ylva 2019; Prevedorou and Buikstra 2019). The cemetery at Phaleron has been known by scholars since the early 20th century and was partially excavated by the Greek Archaeological Survey in the early 1900's (Pelekidis 1916). The true extent of the cemetery was not recognized until the modern construction of the Stavros Niarchos Foundation Cultural Center, which exposed a vast number of grave features which required extensive salvage excavation efforts led by Stella Chryssoulaki (Chryssoulaki et al. 2014; Chryssoulaki 2017; Prevedorou and Buikstra 2019). The excavations at Phaleron spanned between 2012 and 2020 and uncovered approximately 1,900 burials (Buikstra 2023; Prevedorou and Buikstra 2019). The cemetery at Phaleron is an incredible contribution to our knowledge of ancient Greece given its size, density, and temporal range.

Hitherto the discovery of Phaleron, large scale burials sites from the Archaic Period were sparse. Most knowledge of burial customs from the Archaic Period comes from larger cemeteries

around Athens and Attica, such as Keramikos and the Agora (e.g. Morris 1987). These cemeteries have much longer occupational periods, of which Archaic Period burials make up small sections (Morris 1987). The bioarchaeological investigation of Phaleron is still ongoing but has potential to both solidify and clarify our knowledge of burial traditions in the Archaic Period that have been outlined from other sites, while also supplying bioarchaeologists with further data allowing for a more fine-tuned and nuanced understanding of both the lives (and deaths) of those that have been buried at Phaleron.

The Phaleron Bioarchaeological Project

The Phaleron Bioarchaeological Project (PBP) was founded in 2015, by Dr. Jane Buikstra at the Malcom H. Wiener Laboratory for Archaeological Studies of the American School of Classical Studies at Athens, in collaboration with the Arizona State University and the Ephorate of Piraeus and Islands (CIAS Research Center for Anthropology and Health 2023). The PBP, an international and collaborative project, was created to contextually analyze the archaeological findings from Phaleron through a bioarchaeological interpretive framework. The project is working to analyze around 1,200 burials from the 2012-2013 field seasons (Buikstra 2023). Researchers in specialties such as bioarchaeology, forensic anthropology, archaeology, and historians compose the diverse team of the PBP.

The Phaleron Bioarchaeological Project is a unique project given the size of the assemblage and scale of the project. Additionally, the PBP takes tremendous care of the remains post-excavation to ensure minimal damage throughout the curation process. Prevedorou and Buikstra (2019) outline techniques used in the project to accomplish such goals including careful training of the curators, non-damaging cleaning techniques, minimal use of chemicals, heavy

documentation at all steps of the project, and a strict protocol given to each curator. This approach allows for researchers to glean as much information as possible from the human skeletal remains (and other artifacts) while also minimizing curation damage and maximizing preservation.

Given the transdisciplinary nature of the project, there are many on-going research projects and few publications centered on the findings at Phaleron. Karakostis (et al. 2021) considers evidence of manual activities by individuals at Phaleron. Utilizing adequately preserved hand bones from 48 burials, Karakostis (et al. 2021) finds that those that were found in an "atypical burial" had distinct evidence of power-grasping tendencies when compared to those in typical burials. This finding suggests the individuals that were buried atypically were likely long-term heavy laborers. Buikstra (2023) uses the on-going research of the Phaleron Archaeological Project to evaluate the range of approaches and skeletal attributes used to infer manual activities of the past. In this publication, Buikstra (2023) further discusses the broader research interests of the project including the exploration of identities and life histories of non-elites during the rise of the polis. This is accomplished through examining osteological features of age-at-death, sex, stature, pathologies, and activity indicators of which will be contextualized in order to extrapolate nuanced themes of identities including gender, health, kinship, social age, and occupation (Buikstra 2023).

Burials of Phaleron

Burials from Phaleron are reflective of the diversity of burial and mortuary practices during this time. Burials include simple inhumations in sandy soil (both minimally furnished and unfurnished), infant pot burials, primary cremations with pyres, and simple stone lined graves, as

well as the aforementioned “deviant burials” (Karakostis et al 2021; Prevedorou and Buikstra 2019). The primary cremations serve as the focus of this investigation. The cremations at Phaleron make up approximately 10% of the burials at the cemetery (Prevedorou and Buikstra 2019).

Chapter 3: Methods and Materials

This chapter begins with an introduction to the cremated skeletal sample from the Archaic Period (ca. 800-480 BCE) site of Phaleron. It proceeds to detail the methodologies that were utilized in the analysis of the cremations including skeletal inventory, the reconstruction of the biological profile, and thermal alteration analysis. The subsequent sections will focus more specifically on the collection of pathological data as it relates to cremated human skeletal remains and discuss the choice of frequency analysis as opposed to more intensive statistical analysis.

CREMATIONS OF PHALERON

As mentioned in the previous chapter, the cremated human skeletal remains for this investigation come from the Archaic Period site of Phaleron. At the site there are a diversity of burial practices and mortuary rituals conducted contemporaneously throughout the Archaic Period. Burials from the site include simple inhumations in sandy soil, infant pot burials, primary cremations, simple stone lined graves, and burials of individuals with signs of violent death and crucifixion (Karakostis et al 2019; Prevedorou and Buikstra 2019). Primary cremations, as discussed here, represent the pyre sites, where the decedent was burned as part of the mortuary ritual (Cerezo-Román 2013).

The cremated human skeletal remains were analyzed over the span of two field seasons by Dr. Jessica Cerezo-Román (fall 2021 and summer 2022) and myself (summer 2022) at the M.H. Wiener Laboratory of Archaeological Science at the American School of Classical Studies at Athens located in Athens, Greece. The sample used in this study consists of 38 individuals from the 36 pyres that have been analyzed to date. There are more cremations that were

excavated at Phaleron but are pending analysis, subsequently they are not included in this study. In addition, individuals that were unburned or otherwise considered intrusive burials have been excluded from the total sample size.

The selection and application of the methodology discussed below is often applied to unburned human skeletal remains as well as cremations. What makes this methodological approach distinct is the close attention to thermal alteration resulting from the incineration process within its cultural context as well as the meticulous inventory and reconstruction of the sample cremations. The methods utilized have been standardized, corrected for interobserver error, and accounted for population differences.

CREMATION ANALYSIS

The Biological Profile

Our main objective in cremation analysis was to create the biological profile of each individual that was analyzed (see Appendix A for relevant skeletal data collection forms used in this study). Recording protocols and data collection for this project were derived from the Bioarchaeological Laboratory of the Arizona State Museum (ASM) (2018), *Standards for Data Collection from Human Skeletal Remains* (Buikstra and Ubelaker 1994), and the works of Dr. Jessica Cerezo-Román (2013, 2020).

The traditional biological profile is an assessment of an individual's skeletal characteristics including an inventory of present skeletal elements and their condition, estimated biological sex, age-at-death assessment, dental inventory and analysis, craniometrics, post-cranial measurements, and pathology assessments including but not limited to trauma, skeletal

manifestations of pathogenesis, and degenerative joint disease (Buikstra and Ubelaker 1994, Dirkmaat et al 2012).

The reconstruction of the biological profile for the individuals studied in this project was highly dependent upon how thermally altered the remains were and which areas of the skeleton were most affected by the incineration process. Data collection for each pyre remained consistent and standardized throughout the study regardless of the preservation of the skeletal remains. If essential elements to make assessments were absent, obstructed, or poorly preserved it was recorded.

The workflow of the biological profile *modified for cremation analysis of adults* for this investigation was conducted as follows: (refitting of the skeletal elements), inventory, dental inventory (when applicable), sex estimation, age-at-death estimation, osteometrics (when applicable), pathological analysis, and thermal alteration/fragmentation analysis (Buikstra and Ubelaker 1994; Cerezo-Román 2013, 2020). The sample for this investigation is comprised only of adult individuals, therefore, no methods applied to subadults will be discussed or included in this research.

Taphonomy

Taphonomy was accessed based on the conditions of the remains (see Appendix A recording sheet). Each individual was examined for taphonomic changes unrelated to the cremation ritual. This included the documentation of cracking, breaking, brittle, exfoliation, warping, cutmarks, gnaw marks, root or insect damage, staining, and soil adhering of the bones (ASM 2018). Within this study, distinct changes to bones caused by the incineration process were recorded as thermal alteration (see below) as opposed to taphonomic change. Therefore,

any natural or cultural taphonomic changes that were recorded amongst the sample were changes that are not associated with the cremation ritual.

Inventory

The inventory for this investigation was preceded by the "refitting" stage. The fragmented bones were refit in order to quantify which skeletal elements were present and to assess the degree of completeness for each individual (Cerezo-Román 2013, 2020). This component of analysis was the most time consuming. During the curation stage (see Prevedorou and Buikstra 2019) pyres were bagged and labeled in a standardized way. Refitting began by removing all of the bone fragments from the bags and placing them on an examination table. From there the fragments were sorted by approximate anatomical region (ie: cranium, axial, appendicular skeleton). Once the fragments were sorted by anatomical region, they were refit in order to reconstruct the present elements (Cerezo-Román 2013, 2020). As refitting progressed identification of skeletal elements (which were documented as: cranium, dentition, sternum, ribs, vertebrae, scapula, pelvis, humeri, radii ulnae, clavicles, femora, tibiae, fibulae, patellae, and extremities) as well as side (left or right), became possible. In the event fragments were unrecognizable, they were sorted as unidentified long bone fragments and unidentified fragments.

After all fragments had been examined and refit, the individual was placed in anatomical position in order to complete the inventory form, bone chart, and photographs. The inventory form included a comprehensive list of each bone and specialized landmarks. Each bone was sided either left, right, or unidentified and coded for preservation (complete >75%; partially present 75-25%; fragmentary <25%, or unobservable). For the appendicular skeleton, elements

were recorded in anatomical segments including proximal epiphysis, proximal midshaft, midshaft, distal midshaft, and distal epiphysis (Cerezo-Román 2013, 2020). This level of precision allowed for a robust understanding of skeletal completeness for each individual. The bone chart was completed in tandem with the inventory form. The bone chart consisted of a blank skeleton in anatomical position that was shaded according to the presence of each bone that was identified with certain degree of confidence. These forms offered a visual and quantitative understanding of completeness and laid in place the foundation for the remaining cremation analysis.

Sex Estimation

Protocols for recording and collecting data to estimate sex of adults were based on a number of sources outlined in Bukistra and Ubelaker (1994), the Bioarchaeological Laboratory Manual of the Arizona State Museum (2008), and the research of Dr. Jessica Cerezo-Román (2013, 2020).

Biological sex is estimated from sexually dimorphic traits which become pronounced at the onset of puberty, most often in the pelvis and skull (Garvin et al. 2014, Klales 2022). Sex estimation in cremation analysis is highly contingent on preservation and degree of fragmentation (Correia 1997). Sex estimation for this investigation was conducted with great caution and attention to thermal alteration (Fairgrieve 2007).

For the pelvis, the method proposed by Phenice and subsequent revisions by Klales (2020), was selected for sex estimation. Phenice (1969) and Klales (2020) observe the ventral arch, subpubic concavity, and ischiopubic ramus of the os coxa. The Phenice method scores each of these features as one (female), two (ambiguous), three (male), or blank (unobservable). Klales

(2020) takes a more general approach, scoring each feature from 1 to 5 based on morphological differences (Klales 2020). The culmination of these factors allows observers to estimate biological sex with up to 90% accuracy (Phenice 1969, Klales 2020). This method is considered to be one of the most accurate nonmetric analyses for sex estimation (Phenice 1969; Klales 2020). These methods required each element to be intact or mostly preserved to make a holistically accurate sex estimation, for this reason many of the individuals in the sample were unable to be sexed through this method due to lack of visibility in the pelvic region. In addition to Pheince (1969) and Klales (2020) estimations were taken from the greater sciatic notch and the preauricular sulcus, when observable (Buikstra and Ubelaker 1994; Milner 1992; Walker 2005). The addition of these sexually dimorphic nonmetric pelvic traits were added as a further line of evidence to Pheince (1969) and Klales (2020) or in the individuals where these methods were not applicable due to poor preservation. There were cases throughout the sample in which the none of the nonmetric traits in the pelvis were observable or the data collected was not persuasive enough to make an estimation, these individuals were documented as undetermined.

Sex estimations of nonmetric traits in the skull were documented using methods outlined in Buikstra and Ubelaker (1994) with revisions by Walker (2005, 2008). These traits were scored from one (minimal expression) to five (maximal expression). The traits included the nuchal crest of the occipital bone, mastoid process, supraorbital margin, glabella, and mental eminence (the chin) (Walker 2008).

Measurements taken from the femoral and radial head were also utilized as a further line of evidence for sex estimation when preservation allowed. Steele and Bramblett (1988) find that the femoral head is sexual dimorphic due to its articulation with the pelvis. Their study finds that femoral heads of males are consistently over 45mm whereas females are less than 45mm (Steele

and Bramblett 1988). Measurements of the femoral head added another line of evidence for sex estimation in addition to the aforementioned sexing methods. Importantly, these measurements were conservatively considered with regards to shrinkage due to incineration and population specific sexual dimorphic differentials.

The final sex estimation was made from the overall assessments collected from the sexually dimorphic traits in the os coxae and skull, as well as overall degree of robusticity. In accordance with Buikstra and Ubelaker (1994), depending on their overall characteristics individuals were estimated as female (one), probable female (two), ambiguous or unidentified sex (three), probable male (four), male (five) or undetermined sex (zero).

Age-at-Death Estimation

Age-at death estimation is assessed through a myriad of skeletal morphological features that are reflective of development, growth, and degree of maturation (Buikstra and Ubelaker 1994). Age-at-death in burned remains, like that of the sex estimation, is highly dependent on the degree of distortion and destruction (Correia 1997). For this investigation, age-at death estimations of adults were collected through nonmetric analysis throughout the skeleton as outlined in Buikstra and Ubelaker (1994), and when possible, through transitional analysis (Boldsen et al 2002, Langley et al. 2016; Milner and Boldsen 2012,).

Buikstra and Ubelaker's (1994) publication compiled a comprehensive assessment of age markers throughout the entire skeleton, considering both developmental and degeneration indicators in a holistic manner. The combination and consideration of multiple lines of evidence produces the most accurate estimations of age-at-death. The approach for this investigation was

to record as many of these skeletal changes from each individual when the elements were present and observable.

In the pelvis, the pubic symphysis and the auricular surface were considered. The pubic symphysis is an immovable joint that goes through distinct and timely changes throughout the course of life, making it one of the most accurate landmarks for nonmetric age estimation (Buikstra and Ubelaker 1994). Both the Todd (one through ten) and the Suchey-Brooks (one through five) pubic symphysis scoring systems, which describe the transformation of the pubic symphysis by age range, were utilized in this project (McKern and Stewart 1957; Suchey-Brooks 1990; Todd 1920). Scores of the auricular surface, the articulation point of the sacrum, were also considered. Estimations were scored from one through eight, each score corresponding to an age range (Meindl and Lovejoy 1989).

Cranial suture closure, including those of the external cranial vault, internal cranial vault, and palatine were scored when applicable, for complete list of sutures see Appendix A (Baker 1984; Mann et al. 1987; Meindl and Lovejoy 1985; Todd and Lyon 1924, 1925). Closure was scored on a scale of zero (open) to three (complete obliteration) as outlined by Meindl and Lovejoy (1985).

Post-cranially, fusion of epiphyseal unions were examined in the clavicle, sacrum, iliac crest, and vertebrae as well as within the long bones such as the radii, ulnae, humeri, femora, fibulae, and tibiae (Buikstra and Ubelaker 1994). Epiphyseal unions were scored from zero (open) to two (complete union) (Ubelaker 1989).

In addition to the methods listed in *Standards for Data Collection from Human Skeletal Remains*, transition analysis of age estimation was conducted when possible. Transition analysis is a statistical approach to age-estimation utilizing scores of morphological traits throughout the

skeleton (Boldsen et al. 2002; Milner and Boldsen 2012; Milner et al. 2016; Milner et al. 2021). Transition analysis requires the observability of many skeletal regions throughout the body in order to make an accurate statistical estimation. When possible, skeletal features from the pubic symphysis and the sacroiliac joint, as well as cranial suture closure (for full list of landmarks and sutures, see Appendix A) were assessed scored, and considered in transition analysis. Transitional Analysis Versions two and three were utilized in this analysis. In the case of heavy fragmentation or complete absence of essential elements, age estimates remained conservative, such as "older than 15 years at death" or "adult."

PATHOLOGICAL ANALYSIS

For this project, pathological documentation of cremated human skeletal remains followed the same protocols outlined for unburned human remains (Buikstra and Ubelaker 1994). Macroscopic observations were performed by examining each skeletal region starting from the cranium and working inferiorly, looking for any bony lesions or abnormalities in each bone fragment, for every individual. Importantly, this analysis documented abnormal change to bone that may be related to pathogenesis, degeneration, or stress in the human skeleton. The documentation of these changes, or lesions, serve as a comprehensive list of affected areas of the skeleton and are by no means a diagnosis of the conditions that may have caused such changes.

The pathological checklist, broken down by cranium, axial and appendicular skeleton, and extremities was completed for each individual (see Appendix A for skeletal data recording forms). The checklist included a list of common lesions that corresponded to the respective anatomical areas. Each skeletal region was examined, and data was recorded as absent, present, or unobservable. Notably, data was recorded as absent when fragment preservation allowed for

the assessment of pathological lesions, and none were identified. Whereas unobservable was selected in cases where severe obstruction or complete absence of the necessary elements prevented a confident assessment of absence/presence of pathological lesions.

When lesions were identified they were rigorously documented through a standardized procedure which included annotated drawings, measurements, photographs, and description of the lesion(s). Once a lesion was identified it was drawn to scale on millimeter graph paper and annotated. Annotations of the lesion included the bone of which the lesion was present on, approximate location of the lesion on the bone, measurements, and a short description of the lesion. Once drawn, the lesion as well as the entire fragment of bone was measured in millimeters using Mitutoyo digital calipers. Measurements were added to both the drawing of the lesion and pathological checklist description section of the individual. Photographs were taken of each bone fragment with present lesions, using a variety of zoom lenses. The photographs were taken from all anatomical positions (anterior, posterior, distal, and medial) needed to observe the full spread of the lesion. Lastly, the lesion was thoroughly described using standardized pathological terminology (Buikstra and Ubelaker 1994, Ortner 2003, Ubelaker 1999). The reference texts and standardized pathological terminology used to describe the lesions came from a variety of well-established and accepted bioarchaeology publications including Buikstra and Ubelaker (1994), Ortner (2003), Wilczak (2011), Stuart-Macadam (1982, 1985, 1989), Sofaer Derevenski (2000), Mulhern and Jones (2011), Wilczak and London (2011), Buikstra (2010), Dudar (2011), and Ubelaker (1999) among others.

Fragments that were suspected to have present lesions were then analyzed microscopically, using a Dino-Lite Edge Digital Microscope model AM73915MZTL, to verify

the lesions were indeed pathological in nature as opposed to damage caused by taphonomy or thermal alteration. Microscopic photographs were captured for later reference.

Additionally, lesions associated with degenerative joint disease throughout the skeleton were documented on a specialized recording form. (See Appendix A). Degenerative joint disease (DJD) is primarily caused by repetitive motion and stress on joints and joint surfaces, overtime this stress can lead to observable changes including porosity, marginal lipping, and polishing/eburnation (White et al. 2012). The stages of DJD were scored a-e as described in Ubelaker (1999), where a=normal auricular surface, b=appearance of small deposits of bone on articular margins, c=small pits, d=polishing/eburnation, and e=other. Spinal osteophytosis received a specialized recording from as well to document the extent of bony activity. This form included scoring spaces for osteophytosis (Ubelaker 1999), extent of osteophytes (Dudar 2011), and degenerative joint disease on vertebral articular surfaces (Ubelaker 1999).

THERMAL ALTERATION ANALYSIS

Thermal alteration analysis was conducted on each individual to further quantify preservation of the skeletal remains and understand which areas of the skeleton were most affected by the incineration process. The thermal alteration analysis data collection indexed color changes, fragmentation and warping patterns, and weight of the cremated individual. The thermal alteration analysis deployed in this project approached the skeleton in a holistic way, distinguishing between the full skeleton, the appendicular vs. axial skeleton, as well as isolated elements including the cranium, dentition, ribs, vertebrae, scapula, pelvis, arms (humeri, radii, and ulnae), legs (femora, tibiae, fibulae, and patellae), unidentified long bone fragments,

unidentified fragments, and extremities. This rigorous approach allowed for the most minute changes in the skeleton to be noted.

Primary and secondary color was recorded using the Munsell Soil Color Chart, which allows for a standard point of reference when describing color changes in the skeleton. The Munsell color was coded on the bone chart (ie: calcined was blue, brown was red, black was black) to offer a visual representation of the color changes (Cerezo-Román 2013, 2020). The state of calcination and whether the bones are chalky was recorded as either yes or no. Warping (heavy, moderate, minimal, none) and cracking (horizontal, vertical, and concentric) was noted and described. Each skeletal element/region was weighted using a scientific precision scale and recorded in grams. The fragments from each region were then counted. The counts and weights for each skeletal region were then summed to achieve the approximate total weight and fragment count for the entire skeleton. The maximum and average length of the fragments was taken using Mitutoyo digital calipers and recorded in millimeters from each element/region and was noted. Lastly, burning degree was denoted on a scale from zero to four. As outlined in Holck (1969) burning degree was scaled as zero (apparently unburnt), one (sooting), two (slight burning), three (moderate burning), and four (strong burning). Each of these variables were recorded for the full skeleton, the appendicular and axial skeleton, and the above elements (Cerezo-Román 2013).

Fragmentation analysis was conducted as it is most common within European cremation analysis. Data was collected by carefully sieving the cremations. Three standard sieves were utilized: 9.5mm, 4.75mm, and 2mm, each stacked atop one another. The bone fragments were placed in the 9.5 mm sieve and carefully and meticulously sieved through. The largest element that remained in each sieve was identified and recorded as well as total weight of from each

sieve (Cerezo-Román 2013, 2020). This allowed for an understanding of average fragment size, either large, average, or small through the skeleton (Gonçalves et al. 2015; McKinley 1993).

This analysis was specifically created for the observation of thermally altered remains and is not conducted on unburned individuals. The aforementioned observations are used in cremation studies to discern body positioning during incineration, length of burning, maximum heat of the fire, degree of fragmentation, determine whether or not the body was burned with flesh or as dry bones, and ante/post-firing handling and treatment of the body (Cerezo-Román 2013, 2020; Thompson et al. 2017). This methodology was most important and relevant for this project because it allowed for the holistic quantification of skeletal preservation, by skeletal element, skeletal region, and total preservation.

OBSERVATIONAL STATISTICS

As pathological preservation was the primary focus of this investigation, pathological data was selected as the primary quantitative variable. Therefore, further frequency analysis was conducted on the pathological data collected from each individual. The raw data, relative/percent frequency data, as well as accompanying charts and graphs were generated using Microsoft Excel spreadsheets. Pathological data was coded as absent (A), present (P), and unobservable (U). Once the data was coded into Excel, raw frequencies were produced by simply counting the number of those that were absent, present, and unobservable as well the total number of individuals within the sample. Further, relative (represented as a decimal) and percent frequencies (represented as a percent) were calculated by the number of occurrences of absence, presence, and unobservability compared to the total number of individuals in the sample.

Observational statistics were preferred for this investigation as opposed to more intensive statistical analysis, such as odds ratio or chi-squared, due to the small size of the sample. The heighted risk of Type I error negates the need for more robust statistical analysis and would not critically enhance interpretations and conclusions regarding the research questions. In this case, observational statistics were more powerful in representing the findings.

Chapter 4: Results

This chapter outlines the findings derived from the holistic preservation and pathological analysis of cremated human skeletal remains excavated from Phaleron. The presentation of results begins with general preservation of the entire sample followed by the preservation of each skeletal region from each individual. Moving into an overview of the pathology analysis which observes the absence, presence, and unobservability of any lesion in the entire skeleton. The focus is then shifted to distinct anatomical regions including the cranium, appendicular skeleton, axial skeleton, and extremities, with an emphasis on documenting absence, presence, and unobservability of lesions in each area. Findings for degenerative joint disease (DJD) and osteophytes are presented independently as they are caused by repeated stress as opposed to distinct pathological processes (White et al. 2012).

PRESERVATION

Preservation is essential to the observability of paleopathological lesions in cremated human skeletal remains. This portion outlines the general preservation of the sample, which was highly variable and dependent on the pyre. The majority of the cremations in the sample, 20 out of 38, or 52.6% (Table 1), were categorized as fragmentary, meaning less than 25% of the total skeleton was present, but at least one complete element/partial element was reconstructed (Figure 2). Fourteen cremations (36.8%) were categorized as partial skeleton, which suggests greater than 25% to 75% of the skeleton was represented after reconstruction, including more than one complete/partially complete skeletal element(s) (Figure 1). Four cremations (10.5%) were categorized as fragments of bone, or less than 25% of the skeleton was present in fragments, with no complete elements (Figure 3). These cremations were too poorly preserved to

collect any pathological data and were categorized in the unobservable (for *any* pathological lesions) category. No individuals in the sample were categorized as complete or 75-100% complete. For a comprehensive list of preservation of each individual, see Table 7.

Table 1 Total Preservation of the Sample

Preservation	Frequency	Percent Frequency (%)
Partial Skeleton (25-75%)	14	36.8%
Fragmentary Skeleton (<25% includes at least one complete element)	20	52.6%
Fragments of Bone (<25%, small amounts of fragmented bone)	4	10.5%

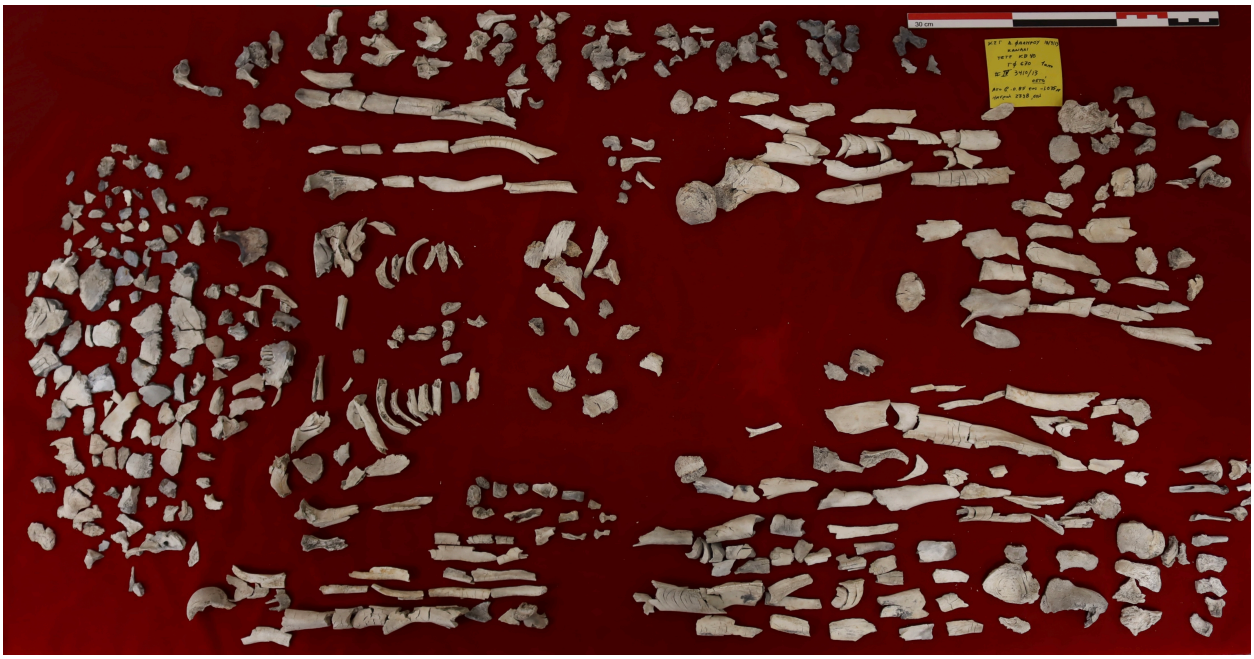

Figure 1 Photograph of Cremation IV-670: Example of Partial Skeleton



Figure 2 Photograph of Cremation IV-263: Example of Fragmentary Skeleton



Figure 3 Photograph of Cremation IV-769 (Individual B): Example of Fragments of Bone

Preservation of Bones by Skeletal Region

This portion presents a generalized view of skeletal element preservation by region for each individual. The results in Tables 2, 3, 4 and 5 are an average of both the left and right side and are presented as both frequency and percentage of individual's skeletal elements that were coded as unobservable (or absent), fragmented, partial, and/or complete. For more precise detail on preservation of each bone please see Appendix B (or Figures 22-32).

Nearly all of the bones in this cremation sample were fragmented, the inclusion of partial and complete is to give insight into the elements that may have preserved slightly better than some of the others or had enough fragments which allowed for the partial or complete reconstruction of the bone. Despite the fact that there are four categorical variables listed in Tables 2-5 it is important to consider that those coded as fragmented/partial/complete are present and those are coded as unobservable were either absent or otherwise unidentifiable throughout the sample.

The most well-preserved bones in the cranium included the bones of the cranial vault, such as the frontal, occipital, parietals, and temporal bone. Fragments of the cranial vault were identified in approximately 50% of the sample. Followed by the mandible, maxilla, sphenoid, and zygomatics. Fragments of endocranial and facial bones including nasals, palatine, ethmoid, vomer, and lacrimals were rarely identified as fragmented (and never as partial or complete) and/or completely unobservable (Table 2).

Amongst the axial skeleton, the bones of the vertebrae were relatively well-preserved. The bones of the cervical vertebrae were identified most often but were highly fragmented as opposed to the thoracic and lumbar which were identified in a lower frequency but preserved in fragments that were larger and more distinguishable. The bones of the sternum including the

manubrium and sternal body were preserved in seven individuals with zero presence of the xiphoid. The hyoid was identified as fragmented in four individuals and as partial in one individual (2.6%). Rib fragments were identified in 25 (65.8%) individuals with zero partial or complete ribs found. The sacrum was identified as fragmented in 10 individuals and as partial in one individual. The coccyx was identified as fragmented in one individual with unobservability in the other 37 individuals of the sample (Table 3).

The bones of the appendicular, like the other skeletal regions presented with variable preservation. Amongst the pelvis the ilium was the most well-represented, followed by the ischium, and pubic bones. The bones of the arms and legs had similar frequencies of preservation, (sans the fibula) and were largely coded as fragmented (Table 4).

As for the extremities, the bones of the carpals were among the least well-represented. The tarsals, especially the calcaneus and talus, had variable preservation throughout the sample but were more represented throughout. The metacarpals and metatarsals reflect similar frequencies of preservation. The manual phalanges were among the most well-preserved bones of the extremities, especially the proximal phalanx. Whereas the pedal phalanges were poorly preserved in most individuals in the sample (Table 5).

Table 2 Average Preservation of Bones from the Cranium for Each Individual (n=38)

Bones of the Cranium	Unobservable	Fragmented	Partial	Complete
Frontals	14 (36.8%)	23 (60.5%)	0 (0.0%)	1 (2.6%)
Parietals	18 (47.4%)	19 (50.0%)	1 (2.6%)	0 (0.0%)
Occipital	17.5 (46.1%)	19 (50.0%)	1.5 (3.9%)	0 (0.0%)
Temporals	19 (50.0%)	19 (50.0%)	0 (0.0%)	0 (0.0%)
Mandible	19	18	0	1

	(50.0%)	(47.4%)	(0.0%)	(2.6%)
Zygomatics	27 (71.1%)	9.5 (25.0%)	0.5 (1.3%)	1 (2.6%)
Maxillae	24.5 (64.5%)	11.5 (30.3%)	1 (2.6%)	1 (2.6%)
Nasals	34 (89.5%)	3.5 (9.2%)	0.5 (1.3%)	0 (0.0%)
Lacrimals	37.5 (98.7%)	0 (0.0%)	0 (0.0%)	0.5 (1.3%)
Palatines	34 (89.5%)	3 (7.9%)	0 (0.0%)	1 (2.6%)
Sphenoids	27 (71.1%)	10 (26.3%)	0 (0.0%)	1 (2.6%)
Ethmoids	37 (97.3%)	1 (2.6%)	0 (0.0%)	0 (0.0%)
Vomers	36 (94.7%)	1 (2.6%)	0 (0.0%)	1 (2.6%)

Table 3 Average Preservation of Bones from the Axial Skeleton for Each Individual (n=38)

Bones of the Axial Skeleton	**Unobservable**	**Fragmented**	**Partial**	**Complete**
Hyoids	31 (81.6%)	4 (10.5%)	1 (2.6%)	0 (0.0%)
Manubriums	31 (81.6%)	7 (18.4%)	0 (0.0%)	0 (0.0%)
Sternal Bodies	31 (81.6%)	7 (18.4%)	0 (0.0%)	0 (0.0%)
Xiphoids	38 (100.0%)	0 (0.0%)	0 (0.0%)	0 (0.0%)
Ribs	13 (34.2%)	25 (65.8%)	0 (0.0%)	0 (0.0%)
Cervical Vertebrae	24.75 (65.1%)	12.5 (32.9%)	0.25 (0.6%)	0.5 (1.3%)
Thoracic Vertebrae	30 (78.9%)	7.75 (20.4%)	0.25 (0.6)	0 (0.0%)
Lumbar Vertebrae	28.5 (75.0%)	8 (21.1%)	0.5 (1.3%)	1 (2.6%)
Sacra	27 (71.1%)	10 (26.3%)	1 (2.6%)	0 (0.0%)
Coccyxes	37 (97.4%)	1 (2.6%)	0 (0.0%)	0 (0.0%)

Table 4 Average Preservation of Bones from the Appendicular Skeleton for Each Individual (n=38)

Bones of the Appendicular Skeleton	Unobservable	Fragmented	Partial	Complete
Scapulae	23 (60.5%)	15 (39.5%)	0 (0.0%)	0 (0.0%)
Clavicles	25 (65.8%)	12 (31.6%)	1 (2.6%)	0 (0.0%)
Ilia	26.5 (69.7%)	9.5 (25.0%)	1 (2.6%)	0 (0.0%)
Pubic Bones	32.5 (85.5%)	4.5 (11.8%)	1 (2.6%)	0 (0.0%)
Ischia	29 (76.3%)	9 (23.7%)	0 (0.0%)	0 (0.0%)
Humerii	22.1 (58.1%)	14.3 (37.6%)	0.4 (1.1%)	1.2 (3.2%)
Radii	26.2 (68.9%)	10.7 (28.2%)	0.3 (0.7%)	0.8 (2.1%)
Ulnae	25.4 (66.8%)	12.1 (31.8%)	0 (0.0%)	0.5 (1.3%)
Femora	21.5 (56.6%)	15.5 (40.8%)	0.3 (0.7%)	0.7 (1.8%)
Tibiae	24.2 (63.7%)	13 (34.2%)	0.2 (0.5%)	0.6 (1.6%)
Fibulae	32.8 (86.3%)	4.9 (12.9%)	0.2 (0.5%)	0.1 (0.3%)
Patellae	28 (73.7%)	6.5 (17.1%)	1.5 (3.9%)	0 (0.0%)

Table 5 Average Preservation of Bones from the Extremities for Each Individual (n=38)

Bones of the Extremities	Unobservable	Fragmented	Partial	Complete
Scaphoids	36 (94.7%)	2 (5.3%)	0 (0.0%)	0 (0.0%)
Lunates	37 (97.4%)	1 (2.6%)	0 (0.0%)	0 (0.0%)
Trapeziums	35 (92.1%)	1 (2.6%)	1 (2.6%)	1 (2.6%)
Trapezoids	37 (94.7%)	0 (0.0%)	0 (0.0%)	1 (2.6%)
Capitates	35 (92.1%)	0 (0.0%)	2 (5.3%)	1 (2.6%)
Hamates	36 (94.7%)	2 (5.3%)	0 (0.0%)	0 (0.0%)

Triquetrals	35 (92.1%)	1 (2.6%)	1 (2.6%)	1 (2.6%)
Pisiforms	35 (92.1%)	2 (5.3%)	0 (0.0%)	1 (2.6%)
Metacarpals	19 (50.0%)	16 (42.1%)	2 (5.3%)	1 (2.6%)
Prox. Manual Phalanges	21 (55.2%)	15 (39.5%)	2 (5.3%)	0 (0.0%)
Inter. Manual Phalanges	29 (76.3%)	7 (18.4%)	2 (5.3%)	0 (0.0%)
Dis. Manual Phalanges	33 (86.8%)	3 (7.9%)	0 (0.0%)	2 (5.3%)
Calcanei	25 (65.8%)	12 (31.6%)	0 (0.0%)	1 (2.6%)
Tali	27 (71.1%)	9 (23.7%)	0 (0.0%)	2 (5.3%)
Cuboids	33 (86.8%)	5 (13.2%)	0 (0.0%)	0 (0.0%)
Naviculares	31 (81.6%)	6 (15.8%)	1 (2.6%)	0 (0.0%)
Med. Cuneiforms	36 (94.7%)	2 (5.3%)	0 (0.0%)	0 (0.0%)
Inter. Cuneiforms	37 (97.4%)	0 (0.0%)	1 (2.6%)	0 (0.0%)
Lat. Cuneiforms	37 (97.4%)	1 (2.6%)	0 (0.0%)	0 (0.0%)
Metatarsals	24 (63.2%)	14 (36.8%)	0 (0.0%)	0 (0.0%)
Prox. Pedal Phalanges	30 (78.9%)	7 (18.4%)	1 (2.6%)	0 (0.0%)
Inter. Pedal Phalanges	36 (94.7%)	1 (2.6%)	1 (2.6%)	0 (0.0%)
Dis. Pedal Phalanges	37 (97.4%)	1 (2.6%)	0 (0.0%)	0 (0.0%)

PATHOLOGY

This section serves as a general overview of the pathological analysis findings. Pathological data collection was done on each cremation regardless of the state of preservation. Each individual was assessed utilizing a standardized checklist of common lesions found throughout the skeleton (see Appendix A). In the event there were lesions present that were not

represented on the checklist, they were described in the notes section and documented accordingly.

The categorical variables of absent, present, and unobservable were utilized throughout the project. Absence and unobservability are important to distinguish from one another. Absence in this study implies the presence of a skeletal element required to make pathological assessments but an absence of any lesion(s). Unobservability indicates that the skeletal element(s) required to make pathological estimations were poorly preserved at the surface or the bone fragments were entirely absent (Buikstra and Ubelaker 1994).

Throughout the sample, thirty-four individuals (89.5%) exhibited one or more skeletal elements/regions that are commonly inspected for pathological lesion manifestation. These regions/elements were well-preserved enough to collect potential pathological data that could be categorized as absent or present. Four individuals in the sample (10.5%) were categorized as unobservable. This indicates that every element/region in the skeleton that is reflective of pathology was absent or too poorly preserved, therefore no pathological data was collected (Table 6).

The overall skeletal pathology assessment denotes the absence or presence of *any* skeletal lesion throughout the skeleton (Table 7). This binary estimation was not reflexive of quantity or type of pathological lesion rather if there was any presence (or absence) of pathology in the entire skeleton. Twenty-seven (71.1%) of 38 individuals in the sample presented with one or more pathological lesions throughout the skeleton. Seven (18.4%) showed a total absence of any pathological lesions, but had elements present in the skeleton that could have manifested skeletal lesions.

Table 6 Full Sample Skeletal Assessments of the Presence, Absence, or Unobservability of Pathological Lesions

Pathological Lesion(s)	Frequency	Percent Frequency (%)
Present	27	71.1%
Absent	7	18.4%
Unobservable	4	10.5%

Table 7 Absence, Presence, and Unobservability of Lesions Throughout the Skeleton and Preservation for Every Individual in the Sample

Cremation	All Skeletal Lesion(s) Absent/Present/Unobservable	Preservation	Lesion(s)
IV-58 (Ind A)	Present	Partial Skeleton	Cranial Periosteal Reaction & Appendicular Periosteal Reaction
IV-95 (Ind A)	Present	Partial Skeleton	*Cribra Orbitalia*, Appendicular Periosteal Reaction, & Degenerative Joint Disease
IV-263	Present	Partial Skeleton	Cranial Periosteal Reaction & Appendicular Periosteal Reaction
IV-275 (Ind A)	Present	Partial Skeleton	Appendicular Periosteal Reaction
IV-275 (Ind B)	Absent	Fragmentary Skeleton	--
IV-277	Present	Partial Skeleton	Porotic Hyperostosis
IV-285 (Ind A)	Absent	Fragmentary Skeleton	--
IV-288 (Ind A)	Present	Fragmentary Skeleton	Cranial Periosteal Reaction
IV-427	Present	Partial Skeleton	Cranial Periosteal Reaction & Appendicular Periosteal Reaction
IV-434 (Ind A)	Present	Fragmentary Skeleton	Appendicular Periosteal Reaction
IV-542 (Ind A)	Present	Partial Skeleton	Appendicular Periosteal Reaction

IV-548 (Ind A)	Present	Partial Skeleton	Appendicular Periosteal Reaction & Schmorl's Node(s)
IV-576 (Ind A)	Present	Fragmentary Skeleton	Appendicular Periosteal Reaction
IV-592	Absent	Fragmentary Skeleton	--
IV-665 (Ind A)	Present	Partial Skeleton	*Cribra Orbitalia* & Appendicular Periosteal Reaction
IV-670 (Ind A)	Present	Partial Skeleton	Porotic Hyperostosis & Appendicular Periosteal Reaction
IV-681 (Ind A)	Present	Fragmentary Skeleton	Appendicular Periosteal Reaction
IV-698	Absent	Fragmentary Skeleton	--
IV-702	Present	Fragmentary Skeleton	Appendicular Periosteal Reaction
IV-717 (Ind A)	Present	Fragmentary Skeleton	Appendicular Periosteal Reaction
IV-729	Present	Partial Skeleton	Porotic Hyperostosis, *Cribra Orbitalia*, & Cranial Periosteal Reaction
IV-734 (Ind A)	Unobservable	Fragments of Bone	--
IV-735 (Ind A)	Absent	Fragmented Skeleton	--
IV-736	Present	Partial Skeleton	Appendicular Periosteal Reaction & Schmorl's Node
IV-750 (Ind A)	Present	Fragmentary Skeleton	Appendicular Periosteal Reaction & Extremities Periosteal Reaction
IV-750 (Ind B)	Unobservable	Fragments of Bone	--
IV-750 (Ind C)	Unobservable	Fragments of Bone	--
IV-755	Present	Fragmentary Skeleton	Appendicular Periosteal Reaction, & Appendicular Proliferative Reaction
IV-760	Present	Fragmentary Skeleton	Appendicular Periosteal Reaction

IV-768	Present	Partial Skeleton	*Cribra Orbitalia* & Cranial Periosteal Reaction
IV-769 (Ind B)	Unobservable	Fragments of Bone	--
IV-770 (Ind A)	Absent	Fragmentary Skeleton	--
IV-780	Absent	Fragmentary Skeleton	--
IV-785	Present	Fragmentary Skeleton	Porotic Hyperostosis
IV-786	Present	Fragmentary Skeleton	Appendicular Periosteal Reaction
IV-787	Present	Partial Skeleton	Appendicular Periosteal Reaction, Schmorl's Node, Axial Periosteal Reaction, & Axial Lytic Reaction
IV-789	Present	Fragmentary Skeleton	Appendicular Periosteal Reaction
IV-791	Present	Fragmentary Skeleton	Porotic Hyperostosis, Cranial Periosteal Reaction, & Appendicular Periosteal Reaction

CRANIAL LESIONS

The standardized pathological checklist included eight of the most common cranial lesions in/on the skull (Buikstra and Ubelaker 1994, ASM 2018, Cerezo-Román 2013,2020). These lesions included porotic hyperostosis, *cribra orbitalia*, premature synostosis, osteomas, periosteal reactions, lytic reactions, proliferative reactions, and trauma. If lesions were present that were not listed on the checklist, they were documented in the notes section.

Lesions that were absent or unobservable throughout the sample have been omitted from the graphs. Of the nine common cranial pathological lesions porotic hyperostosis, *cribra orbitalia*, and periosteal reaction were the only that were consistently observable (Figure 4).

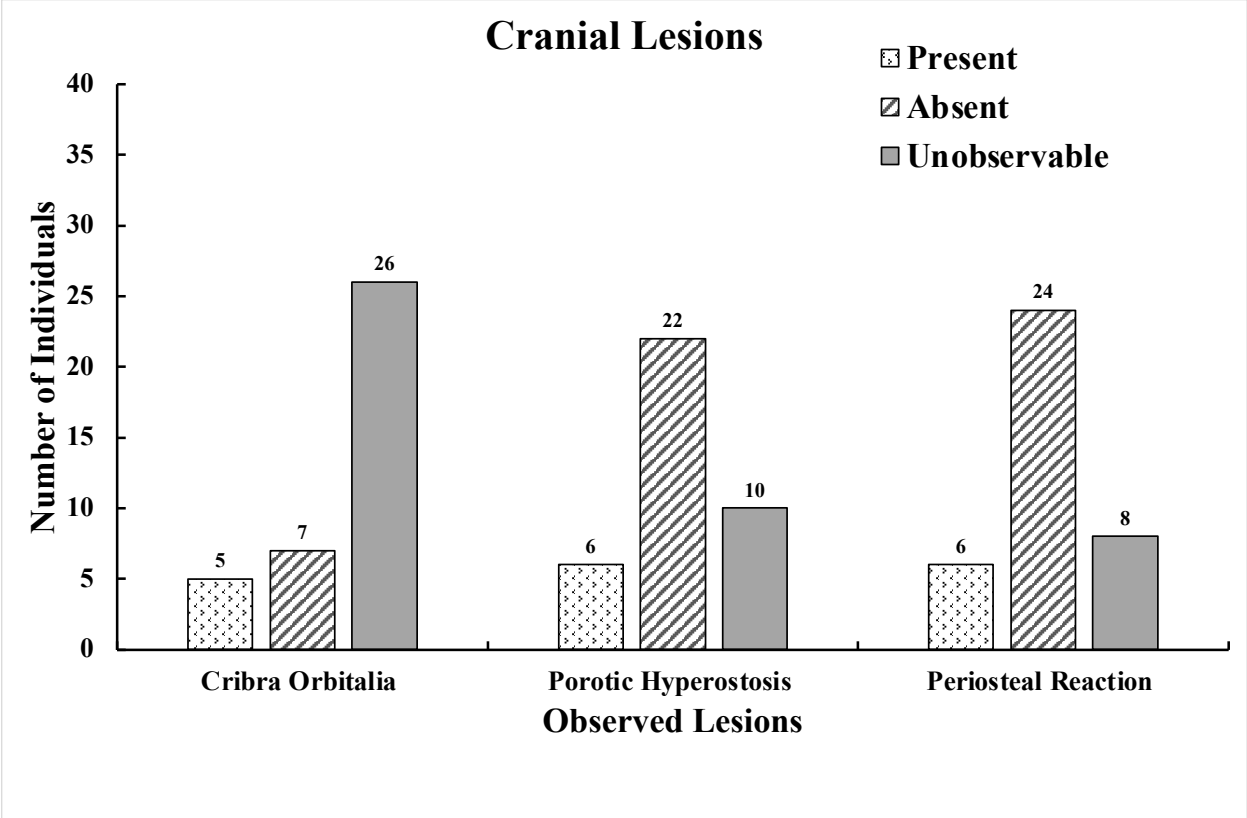

Figure 4 Presence, Absence, and Unobservability of Cranial Lesions

Porotic Hyperostosis

Porotic hyperostosis (PH)) is a descriptive term for the porous enlargement of bone in the skull, identified by morphological changes, including the thickening of bone and porosity (Figures 5 and 6) (Ortner 2003). Porotic hyperostosis often presents bilaterally on the skull vault, affecting the parietals and occipital bone (Ortner 2003).

Throughout the sample, 10 individuals (26.3%) had poor preservation of the parietal and occipital bones. Therefore, they were classified as unobservable. Twenty-two individuals (57.9%) had presence of the occipital/parietals, but had no presence of thickened bone or porosity, these individuals were classified as absent. Six individuals (15.8%) had well-preserved parietals/occipital bones and had presence of porotic hyperostosis (Table 8).

The location of porotic hyperostosis on the cranial vault was variable throughout the six individuals with the presence of the lesion (Table 9). Two individuals presented with PH on fragments of the occipital bone (IV-548 and IV-785) and two individuals on unsided fragments of the parietals (IV-277 and IV-670). The presence of PH in the other two individuals was found in unidentified cranial vault fragments, likely parietals (IV-729 and IV-791). This distinction is important as the lesion and bone type (cranial fragment) was identifiable, but the identification of which cranial vault bone and side was indiscernible given preservation. When inventoried all bones with PH were classified as fragmentary meaning they were 1-25% present.

Table 8 Observed Lesion Frequency in Sample Individuals: Porotic Hyperostosis

	Frequency of Individuals	Relative Frequency	Percent Frequency (%)
Present	6	0.158	15.8%
Absent	22	0.579	57.9%
Unobservable	10	0.263	26.3%

Table 9 Location and Preservation of Fragments with Porotic Hyperostosis

Cremation	Location of Porotic Hyperostosis on the Skull	Preservation of Skull Fragment with Observed Lesion
IV-277	Parietals (unsided)	Fragmentary
IV-548	Occipital	Fragmentary
IV-670	Parietals (unsided)	Fragmentary
IV-729	Unidentified Cranial Bone Fragments	Fragmentary
IV-785	Occipital	Fragmentary
IV-791	Unidentified Cranial Bone Fragments	Fragmentary



Figure 5 Photograph of Porotic Hyperostosis on an Unsided Parietal Fragment from IV-277


Figure 6 Microscopic View of Porotic Hyperostosis on an Unidentified Cranial Vault Fragment from IV-791

Cribra Orbitalia

Cribra orbitalia (CO) is identified as porosity and thickening of the orbital roof (or orbits) of the frontal bone, this lesion presents bilaterally (Figures 7 and 8) (Stuart-Macadam 1989; Ortner 2003). *Cribra orbitalia* manifests through the same processes as porotic hyperostosis, so if an individual presents with one of the lesions, they likely present with the other as well.

The orbits of 26 (68.4%) individuals were not preserved and/or present, they were classified as unobservable. Seven individuals (18.4%) had preserved orbits, but no presence of CO, they were categorized as absent. Five individuals (13.2%) had observable orbits and showed presence of *cribra orbitalia* (Table 10).

Table 10 Observed Lesion Frequency in Sample Individuals: *Cribra Orbitalia*

	Frequency of Individuals	Relative Frequency	Percent Frequency (%)
Present	5	0.132	13.2%
Absent	7	0.184	18.4%
Unobservable	26	0.684	68.4%

Cribra orbitalia was identified on the right side in IV-95 and IV-277, in both individuals the left side was present but too fragmented for any observability. The adverse was true for IV-729 which presented with *cribra orbitalia* on the preserved left side, but the right side was too damaged to make any observations of CO. Individual of pyre IV-665 presented with bilateral *cribra orbitalia*, identified in both well-preserved orbits. As opposed to IV-768 that had presence of CO in an unsided orbit. Interestingly, both porotic hyperostosis and *cribra orbitalia* were identified in IV-277 and IV-729. All orbit fragments were classified as fragmentary when coding for preservation (Table 11).

Table 11 Location and Preservation of Fragments with *Cribra Orbitalia*

Cremation	Location of *Cribra Orbitalia*:	Preservation of the Orbit Fragments with Observed Lesions:
IV-95	Right Orbit	Fragmentary
IV-277	Right Orbit	Fragmentary
IV-665	Right and Left Orbit	Fragmentary
IV-729	Left Orbit	Fragmentary
IV-768	Unsided Orbit	Fragmentary



Figure 7 Photograph of *Cribra Orbitalia* on Orbital Roof of IV-665



Figure 8 Microscopic View of *Cribra Orbitalia* on Orbital Roof of IV-729

Cranial Periosteal Reaction

Periosteal reaction is a generalized, non-specific term used to describe damage to the periosteum onset by pathology, inflammation, and/or trauma (Figures 9 and 10). The lesion presents as the subsequent new bone growth and porosity around the affected area (Roberts 2019). A periosteal reaction can present as active, in the process of healing (mixed woven/sclerotic) or healed at the time of death. Woven bone is an active periosteal reaction, meaning the bone was remodeling and poorly incorporated at the time of death. Sclerotic bone is an inactive or healed periosteal reaction, the lesion is well incorporated to the bone but still reflects evidence of bone growth in the affected area (Roberts 2019). Periosteal reaction can be present anywhere in the skeleton and is not regionally specific to the skull.

Twenty-three individuals (63.2%) had the absence of cranial periosteal reaction, and eight individuals' crania were too poorly preserved to accurately assess for periosteal reaction,

they were classified as unobservable. Seven individuals in the sample had presence of periosteal reaction located in varying locations throughout the skull (Table 12).

Table 12 Observed Lesion Frequency: Cranial Periosteal Reaction in Individuals

	Frequency of Individuals	Relative Frequency	Present Frequency (%)
Present	7	0.184	18.4%
Absent	23	0.605	60.5%
Unobservable	8	0.211	21.1%

Most cases of periosteal reaction amongst the sample affected the endocranial surface of the facial bones and the anterior/interior neurocranial bones. The sphenoid was affected in three individuals The maxillary sinuses were affected in three individuals. Periosteal reaction was also identified in the zygomatic, temporal, frontal, and mandible. The bones with cranial periosteal reaction were mostly coded as fragmentary, with the exception of the right maxilla from IV-288 (Table 13).

Table 13 Individuals with Present Cranial Periosteal Rection

Cremation	Affected area(s)	Preservation of Fragments with Lesion	Lesion Presented as
IV-58	Zygomatic (right) & Sphenoid (right)	Fragmentary & Fragmentary	Porosity
IV-263	Sphenoid (unsided)	Fragmentary	Porosity
IV-288	Maxilla (right)	Partially complete	Pitting/Porosity
IV-427	Sphenoid (right) & Temporal (right)	Fragmentary & Fragmentary	Porosity
IV-729	Maxilla (Right) & Frontal	Fragmentary & Fragmentary	Porosity & Woven
IV-768	Mandible (Right)	Fragmentary	Porosity
IV-791	Mandible (Left)	Fragmentary	Abnormal Bone Deposition and Porosity



Figure 9 Photograph of Sclerotic Bone (Periosteal Reaction) of the Maxillary Sinus of IV-729


Figure 10 Microscopic View of Sclerotic Bone (Periosteal Reaction) of the Maxillary Sinus of IV-729

AXIAL LESIONS

The axial skeleton is comprised of the bones in the skull, vertebral column (cervical, thoracic, and lumbar vertebrae), ribs, and sternum. For this investigation, the axial skeleton was divided into cranium (see above) and post-cranium. The standardized pathological checklist for the (post-cranial) axial skeleton listed nine common lesions found in the axial skeleton. These lesions included ankylosis (vertebrae specific), arch defects (vertebrae specific), compression factures (vertebrae specific), Schmorl's nodes (vertebrae specific), periosteal reactions, lytic reactions, osteoporosis, trauma, and reaction of plural aspect of the ribs (Buikstra and Ubelaker 1994, ASM 2018, Cerezo-Román 2013,2020). If pathological lesions were identified throughout the axial skeleton that were not listed on the pathological checklist they were noted and documented using the same process as those that were on the checklist. The lesions identified in the sample throughout the axial skeleton include Schmorl's nodes, periosteal reaction, and lytic reaction (Figure 11).

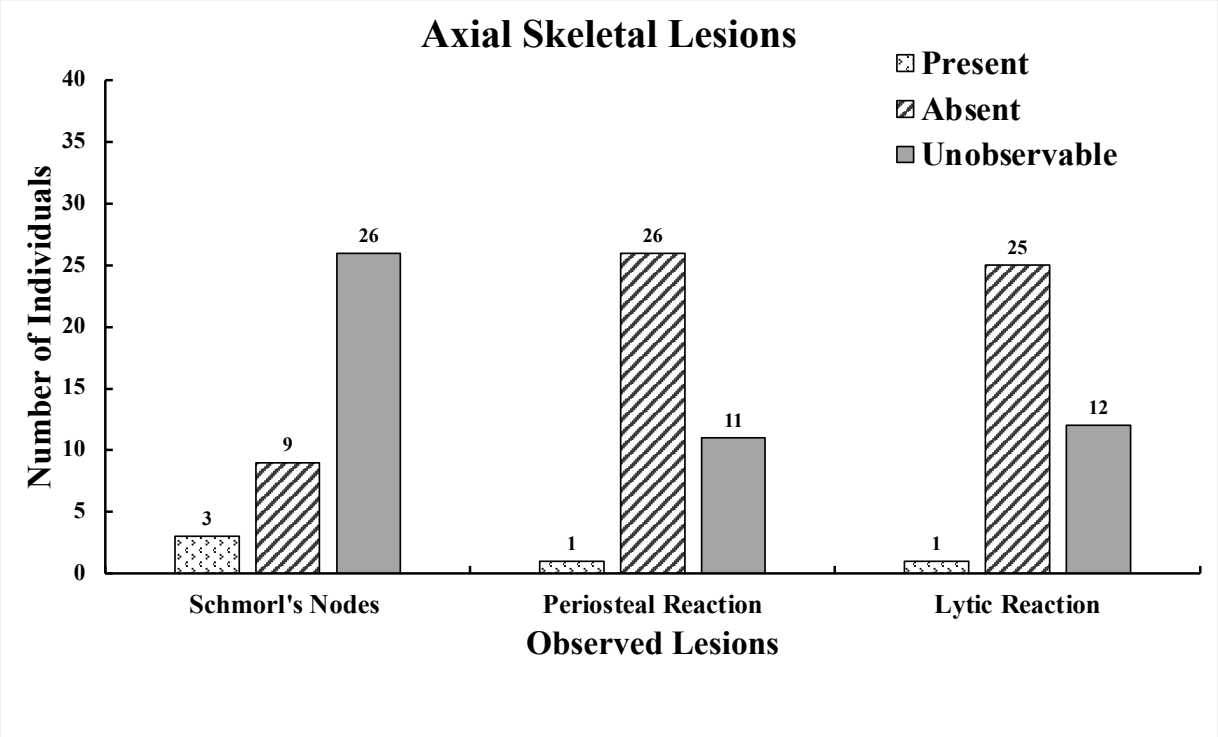

Figure 11 Absence, Presence, and Unobservability of Pathological Lesions in the Axial Skeleton

Schmorl's Nodes

Schmorl's nodes are caused by the herniation of the intervertebral discs. Osteological, this manifests as erosion on the superior surface of the vertebral body (Figure 12) (Ortner 2003). Schmorl's nodes most commonly affect the thoracic and lumbar vertebrae but can also affect the cervical vertebrae (Ortner 2003).

Of the sample, twenty-six individuals (68.4%) had absence and/or poorly preserved surfaces of the superior/inferior surface of the vertebral bodies, these individuals were classified as unobservable. Nine individuals (23.7%) had preserved surfaces of the vertebral body but lacked the presence of a Schmorl's node, these individuals were classified as absent (Table 14).

Three individuals (7.9%) in the sample presented with Schmorl's nodes (Table 10). IV-548 had present Schmorl's nodes on the superior/inferior surfaces of the T12, L1, L4, and L5

vertebral bodies. The superior and inferior surface of the L4 and L5 vertebral bodies was affected in IV-736. IV-787 presented with Schmorl's nodes on the T12, L1, L2, L3, L4, and L5. In addition to Schmorl's nodes IV-787 presented with lytic and periosteal reactions on the aforementioned vertebrae (see following section). Preservation of the vertebrae with present Schmorl's node(s) was variable throughout the affected individuals (Table 15).

Table 14 Observed Lesion Frequency: Schmorl's Nodes in Individuals

	Frequency of Individuals	Relative Frequency	Percent Frequency (%)
Present	3	0.079	7.9%
Absent	9	0.237	23.7%
Unobservable	26	0.684	68.4%



Figure 12 Photograph of Schmorl's Node on 5th Lumbar from IV-787

Table 15 Preservation of Vertebrae with Present Schmorl's Nodes

Affected Vertebrae and Preservation						
Cremation	**12th Thoracic**	**1st Lumbar**	**2nd Lumbar**	**3rd Lumbar**	**4th Lumbar**	**5th Lumbar**
IV-548	Fragmentary	Fragmentary	Fragmentary	Fragmentary	Fragmentary	Fragmentary
IV-736	.	.	.	.	Fragmentary	Fragmentary
IV-787	Partial	Complete	Complete	Complete	Complete	Complete

Axial Skeleton Periosteal and Lytic Reactions

Lytic reactions are related to bone loss or reabsorption as part of the bone remodeling process (Figure 13) (Ortner 2003). Lytic reactions and periosteal reactions may appear in tandem with one another or independently. Only one account of presence for both lytic and periosteal reaction was identified for the axial skeleton (2.6%) (Tables 16 and 17).

The sole affected individual, IV-787 likely has presence of lytic and periosteal lesions as a secondary reaction to the Schmorl's node. The lesions, which presented as bone loss and porosity, were present on both the superior/inferior surface and anterior portion of the vertebral bodies. The 12th thoracic and 1st, 2nd, 3rd, 4th, and 5th lumbar vertebrae all reflected presence with comparable severity, suggesting these vertebrae were all equally affected.

Table 16 Observed Lesion Frequency: Axial Skeleton Periosteal Reaction in Individuals

	Frequency of Individuals	Relative Frequency	Percent Frequency (%)
Present	1	0.026	2.6%
Absent	26	0.684	68.4%
Unobservable	11	0.289	28.9%

Table 17 Observed Lesion Frequency: Axial Skeleton Lytic Reaction in Individuals

	Frequency of Individuals	Relative Frequency	Percent Frequency (%)
Present	1	0.026	2.6%
Absent	25	0.658	65.8%
Unobservable	12	0.316	31.6%



Figure 13 Photograph of Lytic and Periosteal Reaction on 1st Lumbar from IV-787

APPENDICULAR LESIONS

The appendicular skeleton is composed of the bones of the appendages, including the arms (humerii, radii, and ulnae), scapulae, clavicle, the legs (femora, patellae, tibiae, and fibulae), and pelvis (ilia, ischia, and pubic bones). The bones of the hand and feet are traditionally included in the appendicular skeleton but are highlighted independently as "extremities" in the following section. The standardized pathological checklist included seven common pathological lesions found in the appendicular skeleton including periosteal reaction, lytic reaction, proliferative reaction, osteoporosis, trauma, osteomyelitis, and exostoses (Buikstra and Ubelaker 1994; ASM 2018; Cerezo-Román 2013, 2020). If additional appendicular skeletal lesions were identified, they were noted and documented. The only lesion identified in the appendicular skeleton was periosteal reaction (Figure 14).

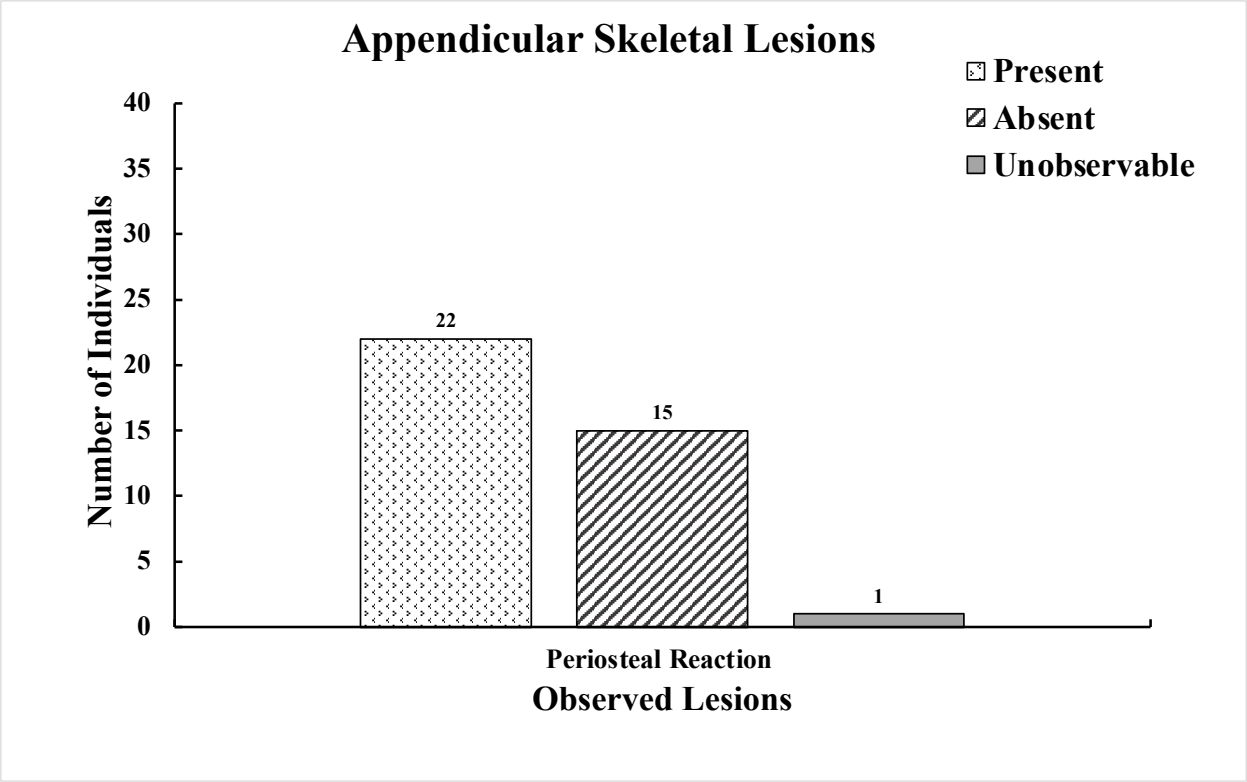

Figure 14 Absence, Presence, and Unobservability of Pathological Lesions in the Appendicular Skeleton

Appendicular Skeleton Periosteal Reaction

Periosteal reaction in the appendicular skeleton is the most common pathological lesion that is identified in archaeological human skeletal remains (Roberts 2019). Among the sample only one individual (2.6%) was too poorly preserved to identify absence or presence of periosteal reaction, they were classified as unobservable. Lesions associated with periosteal reaction were absent in fifteen individuals (39.5%) in the sample, but these individuals had the fragments necessary to make the assessment of absent (Table 18).

Table 18 Observed Lesion Frequency: Appendicular Skeletal Periosteal Reaction in Individuals

	Frequency of Individuals	Relative Frequency	Percent Frequency (%)
Present	22	0.579	57.9%

Absent	15	0.395	39.5%
Unobservable	1	0.026	2.6%



Figure 15 Photograph of Sclerotic Periosteal Reaction in Tibia Fragments from IV-787

Twenty-two individuals (57.9%) in the sample had presence of periosteal reaction in variable areas throughout the appendicular skeleton. This makes periosteal reaction in the appendicular skeleton the most prevalent pathological lesion found in the sample, throughout the entire skeleton. Expression of the lesions varied including macro/micro porosity, sclerotic bone, and woven bone (Table 19).

Of the twenty-two individuals with present periosteal reaction. Twenty-eight occurrences of periosteal reactionary lesions were identified in fragmented bones from the appendicular skeleton. The majority of these occurrences (20 out of 28 or 71.4%) were found in fragments from the leg bones. Fragments from six left, six right, and one unsided tibiae accounted for the

highest number of occurrences (13). Followed by periosteal lesions in the femora, four from the right side and two on unidentified fragments, and one occurrence in a fragment from in an unsided fibula. The bones of the arm had six occurrences of periosteal reaction. Four in the humerii (two left, one right, and one unsided) and two occurrences in ulnae fragment (one left and one unsided). The remaining two periosteal lesions were present on unidentified long bone fragments (Table 19).

Sclerotic bone lesions were the most common with 24 occurrences (Figure 15 and 17). Although the sclerotic lesion varied including 18 occurrences without porosity, five with microporosity, and one with macro and microporosity. Presence of periosteal woven bone was identified three times, once with microporosity and twice without (Figure 16). Interestingly there was one occurrence of a mixed periosteal lesion with both sclerotic and woven bone (Table 19). ‘

Preservation of the identified bones with periosteal reaction was highly variable depending on the individual. Moreover, each bone had variable preservation throughout. Each long bone was analyzed for preservation by proximal epiphysis, proximal portion, mid-shaft, distal portion, and distal epiphysis. Most were coded as fragmentary, meaning 1-25% of the area was present, or unobservable there was complete absence of the area. Some coded as partial meaning 25-75% of the portion was present, or complete (75-100%). Elements that were unsided or had non-specific identification (ie: possible) were coded as dashes (-) because they could not be identified more specifically. Therefore, the bone they came from could not be estimated for total preservation (Table 20).

Table 19 Individuals with Presence of Appendicular Periosteal

Cremation:	Affected Bone Fragments (and Side):	Presented as:

IV-58	Femur (Right)	Sclerotic bone
IV-95	Tibia (Left)	Sclerotic bone
IV-263	Tibia (Left) Ulna (Left)	Sclerotic bone/Microporosity Woven bone
IV-275 (Ind A)	Femur (Right) Tibia (Right)	Sclerotic bone Sclerotic/Microporosity
IV-427	Possible Fibula (Unsided)	Sclerotic bone
IV-434	Tibia (Unsided)	Sclerotic bone/Macro and microporosity
IV-542 (Ind A)	Humerus (Left)	Sclerotic bone
IV-548 (Ind A)	Unidentified Long Bone Fragments	Mixed Sclerotic and Woven bone
IV-576	Tibia (Left)	Sclerotic bone
IV-665	Tibia (Right)	Sclerotic bone
IV-670	Femur (Right)	Sclerotic bone
IV-681	Humerus (Right)	Sclerotic bone
IV-702	Tibia (Right) Tibia (Left)	Sclerotic bone Sclerotic bone
IV 717 (Ind A)	Tibia (Left)	Sclerotic bone/Microporosity
IV-736	Femur (Right)	Sclerotic bone
IV-750 (Ind A)	Potential Humerus (Unsided)	Sclerotic bone
IV-755	Ulna (Right) Tibia (Left) Tibia (Right) Femur (Unsided)	Woven bone/Microporosity Sclerotic bone Sclerotic bone Woven bone
IV-760	Unidentified Long Bone Fragments	Sclerotic bone
IV-786	Tibia (Right)	Sclerotic bone
IV-787	Tibia (Right)	Sclerotic bone/Microporosity
IV-789	Humerus (Left)	Sclerotic bone/Microporosity
IV-791	Femur (Unsided)	Sclerotic bone

Table 20 Preservation of Appendicular Elements with Present Periosteal Reaction

		Preservation of Long Bones with Pathology				
Cremation	**Bone with Present Pathology**	**Proximal Epiphysis**	**Proximal Portion**	**Mid-Shaft**	**Distal Portion**	**Distal Epiphysis**
IV-58	Femur (Right)	Fragmentary	Fragmentary	Fragmentary	Fragmentary	Unobservable
IV-95	Tibia (Left)	Unobservable	Fragmentary	Fragmentary	Fragmentary	Unobservable
IV-263	Tibia (Left)	Unobservable	Fragmentary	Fragmentary	Fragmentary	Unobservable
IV-263	Ulna (Left)	Unobservable	Fragmentary	Fragmentary	Fragmentary	Unobservable
IV-275 (Ind A)	Femur (Right)	Fragmentary	Fragmentary	Fragmentary	Fragmentary	Fragmentary
IV-275 (Ind A)	Tibia (Right)	Fragmentary	Fragmentary	Fragmentary	Fragmentary	Fragmentary
IV-427	Possible Fibula (Unsided)	-	-	-	-	-
IV-434	Tibia (Unsided)	Unobservable	Fragmentary	Fragmentary	Fragmentary	Unobservable
IV-542 (Ind A)	Humerus (Left)	Fragmentary	Fragmentary	Fragmentary	Fragmentary	Unobservable
IV-548 (Ind A)	Unidentified Long Bone Fragments	-	-	-	-	-
IV-576	Tibia (Left)	Fragmentary	Fragmentary	Fragmentary	Fragmentary	Unobservable
IV-665	Tibia (Right)	Unobservable	Fragmentary	Fragmentary	Fragmentary	Unobservable
IV-670	Femur (Right)	Complete	Fragmentary	Fragmentary	Fragmentary	Fragmentary

IV-681	Humerus (right)	Unobservable	Unobservable	Unobservable	Fragmentary	Fragmentary
IV-702	Tibia (right)	Fragmentary	Fragmentary	Fragmentary	Unobservable	Unobservable
IV-702	Tibia (left)	Fragmentary	Fragmentary	Unobservable	Unobservable	Unobservable
IV 717 (Ind A)	Tibia (Left)	Unobservable	Fragmentary	Fragmentary	Fragmentary	Unobservable
IV-736	Femur (Right)	Fragmentary	Partial	Fragmentary	Fragmentary	Fragmentary
IV-750 (Ind A)	Potential Humerus (Unsided)	-	-	-	-	-
IV-755	Ulna (Right)	Unobservable	Fragmentary	Fragmentary	Fragmentary	Unobservable
IV-755	Tibia (Left)	Unobservable	Fragmentary	Fragmentary	Unobservable	Unobservable
IV-755	Tibia (Right)	Unobservable	Fragmentary	Fragmentary	Fragmentary	Fragmentary
IV-755	Femur (Unsided)	-	-	-	-	-
IV-760	Unidentified Long Bone Fragments	-	-	-	-	-
IV-786	Tibia (Right)	Unobservable	Fragmentary	Fragmentary	Unobservable	Unobservable
IV-787	Tibia (Right)	Fragmentary	Fragmentary	Fragmentary	Fragmentary	Unobservable
IV-789	Humerus (Left)	Unobservable	Unobservable	Fragmentary	Unobservable	Unobservable
IV-791	Femur (Unsided)	-	-	-	-	-



Figure 16 Photograph of Woven Bone on the Ulna from IV-755



Figure 17 Microscopic View of Sclerotic Bone with Microporosity on a Humerus from IV-789

EXTREMITIES LESIONS

Extremities are a part of the broader appendicular skeleton but were analyzed as a category of their own. Extremities are composed on the bones of the hand (manual carpals, manual metacarpals, and manual phalanges) and the bones of the feet (tarsal carpals, tarsal metacarpals, tarsal phalanges). The standardized pathological checklist for the extremities included five common pathological lesions in the extremities. These lesions included periosteal reaction, lytic reaction, proliferative reactions, trauma, and exostoses (Buikstra and Ubelaker 1994, ASM 2018, Cerezo-Román 2013, 2020). Periosteal reaction of the extremities was the only lesion identified (Figure 18 and 19).

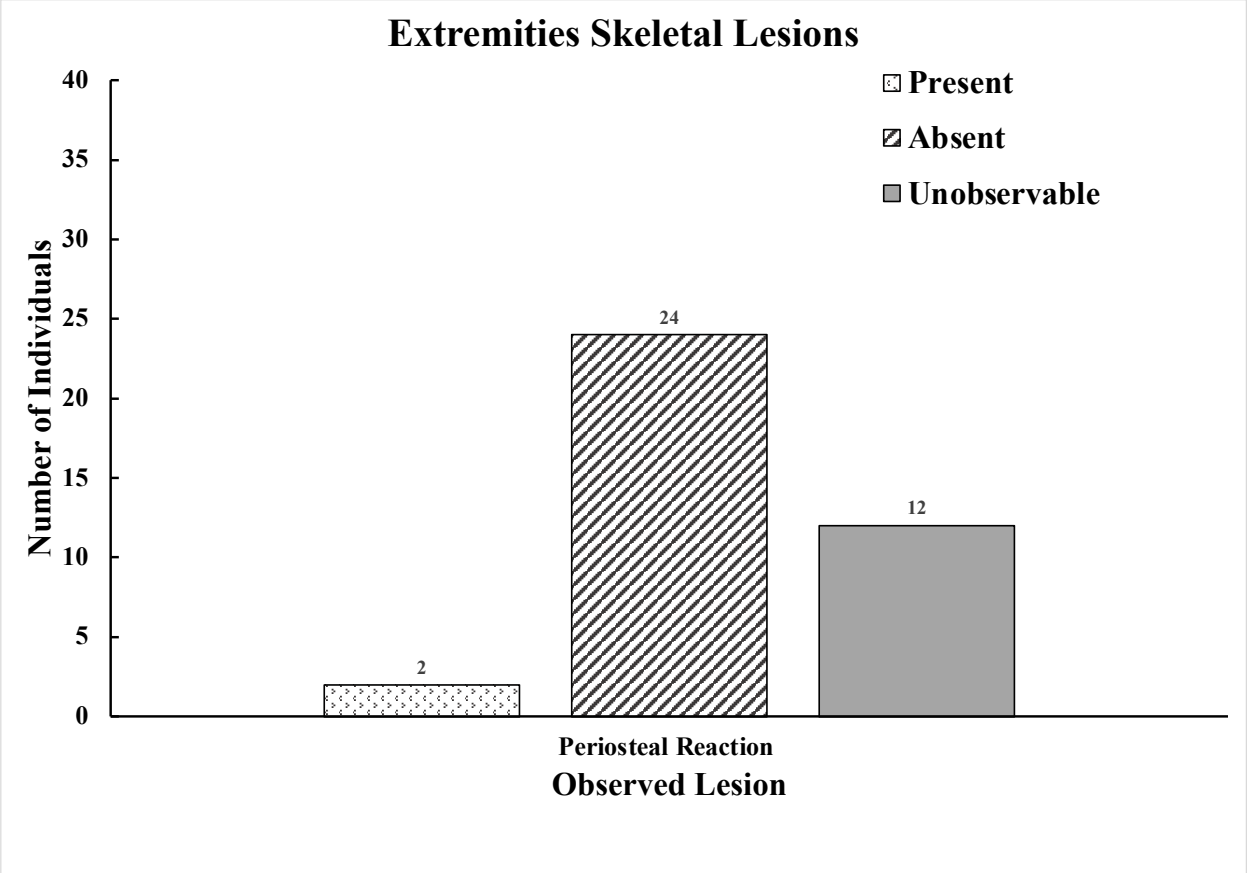

Figure 18 Absence, Presence, and Unobservability of Pathological Lesions on the Extremities

Extremities Periosteal Reaction

Twenty-four individuals (63.2%) in the sample reflected an absence of periosteal reaction in their present extremities, they were categorized as absent. Twelve individuals (31.6%) lacked the preservation required to make assessments of periosteal reaction in the extremities, they were classified as unobservable (Table 21). Two individuals (5.3%) had presence of lesions associated with periosteal reaction in the preserved extremities of the foot, they were classified as present. IV-750 (Ind A) presented with occurrence in an unidentified extremity fragment, likely a pedal phalanx or metatarsal. IV-755 presented with woven bone deposits on the right talus.

Table 21 Observed Lesion Frequency: Extremities Periosteal Reaction in Individuals

	Frequency of Individuals	Relative Frequency	Percent Frequency (%)
Present	2	0.053	5.3%
Absent	24	0.632	63.2%
Unobservable	12	0.316	31.6%



Figure 19 Photograph of Sclerotic Bone in an Unidentified Pedal Fragment from IV-750 (Ind A)

DEGENERATIVE JOINT DISEASE AND OSTEOPHYTES

Degenerative Joint Disease (DJD) is caused by repetitive stress to the joint surfaces throughout the skeleton (Figure 20) (White et al. 2012). For this reason, the categorical variables (absent, present, and unobservable) used throughout the regional areas of the skeleton for pathological data collection were less applicable and recording presence in fragments was more essential whereas absence/unobservability was more difficult to assign. Spinal osteophytes, or bony outgrowths, form throughout the vertebral column where repeated stress occurred (Dudar 2011). Like DJD, presence of spinal osteophytes (Figure 21) was prioritized because absence vs. unobservability was more difficult to discern. Regardless, presence of DJD or spinal osteophytes designates that the fragment was well-preserved and had evidence of a lesion.

Degenerative Joint Disease

Seven individuals (18.4%) throughout the sample presented with degenerative joint disease. These identified occurrences were varied throughout joints of the skeleton and in variable stages of expression. Results are presented by which joint was affected for each individual with presence of DJD (Table 22).

Table 22 Presence of Degenerative Joint Disease by Joints in the Skeleton

Cremation	Skull	Shoulder	Phalanges	Knee	Elbow	Wrist	Hip	Ankle
IV-58	-	-	-	-	-	-	-	Present
IV-95 (Ind A)	Present	-	-	-	-	-	-	-
IV-275	-	-	-	-	-		-	Present
IV-427	-	-	-	-	Present	-	-	
IV-548 (Ind A)	-	-	-	Present	Present	Present	-	-
IV-670 (Ind A)	-	Present	-	-	-	-	-	-
IV-755	-	-	-	Present	-	-	Present	-



Figure 20 Marginal Lipping (Evidence of DJD) on the Distal Humerus (Elbow) from IV-548

Spinal Osteophytes

Spinal osteophytes were present in seven individuals (18.4%) throughout the sample (Table 23). Osteophyte formation was most prevalent on lumbar vertebrae, followed by thoracic vertebrae, and cervical vertebrae.

Table 23 Table 12 Spinal Osteophyte Presences by Vertebrae

Cremation	Cervical	Thoracic	Lumbar
IV-58	Present	-	-
IV-288 (Ind A)	-	-	Present
IV-434 (Ind A)	Present	Present	-
IV-548 (Ind A)	-	Present	Present

IV-670 (Ind A)	-	-	Present
IV-729	-	Present	-
IV-770 (Ind A)	-	-	Present



Figure 21 Photograph of Spinal Osteophyte Formation on the 5th Lumbar Vertebra from IV-548

Chapter 5: Discussion

This chapter offers an expanded discussion on the findings from the paleopathological analysis of the cremated human skeletal remains from Phaleron. This discussion begins with revisiting the research questions and hypotheses which are then answered utilizing the findings from the study. The applications of the findings to the field of bioarchaeology and cremation analysis research are considered. The chapter concludes with outlining the limitations to the study and future directions of research.

REVISIT THE RESEACH QUESTIONS

This section is organized by the research questions outlined in Chapter 1 and addresses these questions and their hypotheses using the findings presented in Chapter 4. Most broadly, this section elaborates on preservation, pathological lesions, and their intersection within the sample.

Question I: *In cremated human skeletal remains, which skeletal elements or regions remain well-preserved? Are any well-preserved skeletal elements common sites for the manifestation of pathological lesions? Are any common sites of skeletal pathology lost or poorly preserved in cremations?*

Total skeletal preservation of each individual cremation was variable throughout the sample. A small portion (four individuals) were represented as fragments of bones. These fragments allowed for very limited analysis. The fragments were identified as to which bone they came from (ie: left femur fragment) and photographed but often had no elements that were indicative of biological sex and/or pathology. Conservative age estimations were occasionally possible if the fragments of bones consisted of epiphyseal fusion sites or other areas broadly affected by development.

The majority of the sample was categorized as fragmentary skeletons; this categorization signified that <25% of the skeleton was present and observable and one or more elements were identified and reconstructed. The distinction of fragmentary skeleton is not descriptive as to which elements were preserved, but rather the degree of completeness of the entire skeleton. Every individual within this group had variable preservation regionally throughout the body. Most individuals categorized as fragmentary had some number of fragments from the cranium, axial and appendicular skeleton, and the extremities of variable preservation and observability. The same is true of those categorized as partial skeletons (<25-75%) (see Table 1).

Preservation of the skeletal elements by region was also highly variable throughout the sample (see Tables 2-5 and Figures 22-32). Nearly all bones were coded as fragmented throughout every region of the skeleton. The categorization of fragmented is non-specific as to how large or small the fragments were, but merely that the bone was represented in fragments. In this way, the categorization of "fragmented" is not synonymous with poorly preserved or unobservable for pathological lesions. Rather, this categorization offers a holistic overview of how bones were represented (either largely fragmented, partial, or complete) from each individual. Preservation in this case is reliant on how large the fragments were and what areas of the bones were present (in a fragmented state).

The bones of the cranial vault were among the most well-preserved and best represented within the cranial region, with presence of cranial vault fragments in approximately 50% of the sample. Many of these fragments were large, easily identifiable, and reconstructable (Table 2). Conversely, the facial bones and endocranium were less preserved and represented throughout the sample.

Within the axial skeleton bones of the spinal vertebrae were often the most well preserved. The cervical vertebrae were present in a higher frequency but were notably in smaller, less reconstructable fragments as opposed to those of the thoracic and lumbar. The ribs, sternum, and sacrum which were present amongst the sample, but were more fragmented and poorly preserved (Table 3). This allowed for little observation of these elements as they were not nearly as reconstructable.

Variable preservation was identified amongst elements of the appendicular skeleton such as the scapula, clavicle, and pelvic bones. The lack of preservation in the pelvis, including elements such as the ventral arch, subpubic concavity, and ischiopubic ramus led to unidentified sex estimations throughout the sample. The bones of the arms and legs reflected similar frequencies of preservation. The long bones were some of the most well-preserved elements (despite the seemingly unremarkable frequencies) in the sample because their fragments were much larger and more identifiable than fragments from other skeletal regions (Table 4).

Among the extremities the bones of the carpals were the least well preserved of the extremities. Conversely, the calcaneus and talus of the tarsals were well-preserved. The metacarpals and metatarsals had comparable levels of preservation likely due to their similarities in bone composition. The manual phalanges, especially the proximal phalanges, were some of the most-well preserved and represented bones of the extremities as opposed to the pedal phalanges which were largely unobservable (Table 5).

The bones that were the most well-preserved within the cremation sample correlate to their density, biomechanical composition, and position within the body. Within the skull, the occipital, parietals, and temporal bones protect the brain, therefore they are denser bones that can withstand more damaging forces, as opposed to the facial bones which are much lighter. The

orbits (of the frontal) were preserved in some individuals but were unobservable in the majority of the sample, likely because they lack density and are not as protected by tissue like the cranial vault (White et al. 2012). Among the vertebrae, preservation was greatest in the lower thoracic and lumbar. These vertebrae are weight bearing bones making them thicker and sturdier (White et al. 2012). In contrast the cervical vertebrae, despite bearing the weight of the skull, are much lighter to aid in the movement of the neck and head, therefore their preservation is less likely than that of the thoracic and lumbar (White et al. 2012). Long bones, especially those of the lower appendages, are often preserved post-incineration due to their density and position amongst muscle, ligaments, and tendons (White et al. 2012). Long bones, especially epiphyseal ends are encased in tissue and cartilage (joints), leaving them less exposed to the incineration process. Preservation of the tarsals, specifically the calcaneus and talus are likely due to their density and encasement in tissue. The tarsals are dense to bear weight as well as provide stability and support in bipedal locomotion, and further are encased in muscle which allow for flexion and extension of the foot and ankle joint (White et al. 2012). Alternatively, the carpals are much less dense which allows for more delicate and precise mobility of the hand, subsequently making them less likely to preserve in the cremation process (White et al. 2012). On the other hand, the preservation of the metacarpals and phalanges are likely due to the pugilistic position a body takes when being burned. If an individual is cremated in the supine position the hands will curl into a fist towards the chest, which protects the palmar surface of metacarpals and phalanges (Symes et al. 2008).

In addition to the density, thickness, and position of elements in the body, the pugilistic position may also contribute to the preservation of regions throughout the body. This position is named after the defensive stance of a boxer (Bass 1984). Exposure to high temperature initiates

the shrinkage of muscle bundles, specifically those that are responsible for flexion (Bass 1984). Each region of the body is divided by joint groups as they flex in accordance to their relative musculature during thermal alteration, resulting in the flexion of the hands, elbow, knees, hips, feet, and neck. This posture differentially allows for the protection of some elements and forced exposure of others (Symes et al. 2008). The pugilistic position is utilized as a guide to understand which elements are initially burned, secondarily burned, and last to burn. This does not mean elements that are initially burned are completely unobservable, rather they are exposed to fire for the longest amount of time which may affect their preservation (Symes et al. 2008). The pugilistic position likely aided in the preservation of skeletal elements from this sample, especially in the midshaft of the long bones and the phalanges.

In summation, skeletal elements that are more thick and dense, as well as those encased in tissue were more preserved throughout the sample than elements that were less dense/thick and less protected by muscles, ligaments, and tendons (Richards 1977). As aforementioned, bones such as the occipital, lumbar vertebrae, femora, and tibiae were far more likely to preserve than lighter bones. This means there was more opportunity to make observations on the absence or presence of lesions such as porotic hyperostosis, Schmorl's nodes, and periosteal reaction of the appendages. Importantly, elements that did not preserve well, such as the ribs, carpals, scapula, and pelvis, may have once had pathological lesions present prior to the incineration process but these are subsequently unobservable due to surface damage or complete fragmentation/loss within the fire. The importance of the variable of unobservable is that it allows us to catalogue the inability to make any observation concerning absence or presence of lesions throughout the skeleton.

High frequencies of fragmented elements were secondary in importance to fragment size. Optimal preservation included elements that were represented in a high frequency throughout the sample as well as present in large fragments such as bones from the cranium (Table 2). High frequency of presence and large fragment size allowed for the most reconstruction and observability of bones such as the occipital and parietals. This may be contrasted with the facial bones, which were almost entirely unobservable and when present the bones were highly fragmented (Table 2). Fragments of bone that were present in high frequencies but in small fragments such as the ribs were considered less well-preserved because they were often less reconstructable (Table 3). This is also true of the vertebrae. The lumbar and thoracic were present in a lower frequency throughout the sample but were more well-preserved given the size of fragments (Table 3). As opposed to the cervical vertebrae which were present in many individuals, but highly fragmented (Table 3). The bones of the appendages are another example, frequency of presence (including fragmentary, partial, and complete) appears low but in the individuals with presence of long bones, the fragments were large and reconstructable (Table 4). This made the long bones more observable for pathological lesions, therefore more informative to this investigation. With these findings, it may be advantageous to create more terms for "fragmented" bones in cremations that expands upon the simple categorization of fragmented.

In addition to pathological lesions, preservation allowed for the identification of abnormal bone formation caused by repeated biomechanical stress that was consistent with degenerative joint disease and spinal osteophyte formation. Vertebrae are more likely to preserve within cremations due to their density, their position in the body, and (if burned in the supine position) their distance from the fire (Symes et al. 2008; White et al. 2012). Joints throughout the body often preserve well as they are heavily encased in muscles, which in life allow individuals a full

range of motion, and in cremation allow for more protection from the fire (White et al. 2012). Conversely facial bones, carpals, and ribs are some of the bones that were less preserved amongst the sample given the duration of burning and temperature of the fire. Therefore, any pathologies that may have been present were completely unobservable. A major limitation in making observations of degenerative joint disease or spinal osteophyte formation is the inability to observe the full joint or vertebrae. In many cases within the sample the observed lesion was present on a portion of a fragment which obstructed further documentation concerning progression or stage and breadth of the affected area. Moreover, when assessing for degenerative joint disease, several bones coalesce to create a joint (for example the knee consists of the distal anterior/posterior portion of the femur, the medial anterior/posterior portion of the tibia, and the patella), in many cases individuals only presented with observable lesions on fragments of one bone that created the joint. This resulted in straightforward, nondescript assessments of presence in the fragments with degenerative joint disease.

These findings validated Hypothesis I (see Chapter 1). These results are consistent with the findings of broader research concerning cremation and preservation post-incineration, many of which report findings of *cribra orbitalia*, porotic hyperostosis, periosteal reaction, and degenerative joint disease (Mackiewicz and Szczurowski 2023; Owens 2010; Reinhard and Fink 1994; Salo et al. 2022; Scheelen-Nováček et al. 2021; Veselka et al. 2021). Salo (et al. 2022) identifies PH and CO within their sample in similar frequencies to the findings of this study, but the authors do not critically discuss the preservation of skeletal regions. Owens (2010) finds that pathological lesions are observable in fragments throughout all stages of heating and chemical shifts to bone. In this way, Owens (2010) is approaching preservation through color change as opposed to inventory like this investigation, but notes that pathological lesions are observable

post-incineration. Mackiewicz and Szczurowski (2023) find that bones of the vertebrae and long bones preserve the best in cremations. The authors stress the observability of lesions associated with degenerative joint disease in their sample, both of these findings concerning preservation and pathological lesions were identified in the cremations from Phaleron. Reinhard and Fink (1994) find that lesions of porotic hyperostosis, periosteal reaction, and degenerative joint disease remain reliably well-preserved in their sample cremations. The authors note that these pathologies likely preserve due to the dense nature of the bones they are found on. The findings of Reinhard and Fink (1994) were validated in the results of this investigation, although the sample cremations at Phaleron reflect better preservation of the orbits, making *cribra orbitalia* more observable. Veselka (et al. 2021) and Scheelen-Nováček (et al. 2021) note the observability of pathologies relating to non-specific stress and degenerative joint disease which were identified in this study. On the other hand, both investigations lack broader discussions of elemental preservation and utilize further advanced methodologies to contextually analyze their samples. Studies such as Veslka (et al. 2021) and Scheelen-Nováček (et al. 2021) may serve as models for future research for the cremation sample from Phaleron.

Despite the fact that elemental preservation may be predictable in cremation analysis each study should nonetheless take a thorough, unbiased, and standardized approach when inventorying and analyzing cremations. The observation of pathologies is highly contingent upon preservation, but preservation is dependent upon many factors concerning the cremation ritual. These factors include, but are not limited to the duration of burning, maximum temperature of the fire, body positioning, the amount of flesh and tissue on the body, and size of the individual. Any of these factors may contribute to degree of preservation.

Question II*: *How might standard bioarchaeological methods, paleopathological data collection, and analysis (created for mostly complete, well-preserved, and unburned skeletons) be applied and/or modified to study cremated human skeletal remains?

In some individuals, analytical assessments such as sex estimation, precise age-at-death estimation, and complete pathological observations were impossible due to lack of preservation of essential elements, taphonomic changes, and/or thermal alteration. This is not an uncommon occurrence in highly burned and fragmented human skeletal remains as noted by Cerezo-Román (2013). Every individual was analyzed utilizing the standardized methodological approach as discussed in Chapter 3 to create the biological profile and collect pathological data, despite their preservation. These methods are thorough not only in holistically observing the entire cremation, but also by region and element throughout the skeleton. Therefore, cremations classified as fragments of bone were just as rigorously analyzed as partial skeletons. This allowed for comparative results regardless of preservation classification. These methods also left little to no room for inattention to even the smallest pathological lesion(s) due to the meticulous reconstruction, inventory process, identification, and analysis of the fragments.

The standard bioarchaeological methods for paleopathological data collection and construction of the biological profile is possible in cremated human skeletal remains, which is consistent with Hypothesis II (see Chapter 1). Modifications to the standardized approach should include the reconstruction/refitting stage of the fragments, an exceedingly detailed inventory and color-coded bone chart, systematic documentation of pathological lesions identified on each fragment, and thermal alteration analysis. In order to collect pathological data from cremated human skeletal remains one must have an advanced understanding of cremations and the associated factors that may mitigate or extenuate bone changes caused by thermal alteration. Factors such as color changes, shrinkage, warping, cracking, and fragmentation are distinct

transformation to bone caused by fire and must be documented and included in the construction of the biological profile in order to make estimations concerning biological sex, age-at-death, and pathology. Close attention should also be paid to taphonomic changes that may impact preservation.

Question III: ***Amongst the sample, which lesions can be observed when analyzing cremated human skeletal remains? Of the lesions that can be observed, what insights might they contribute to the understanding of pathology, disease, and health in ancient Athens and Attica?***

Throughout the sample 34 out of 38 cremations (or 89.5%) were well-preserved enough to observe for absence, presence, or unobservability throughout the entire skeleton. Of the 34 well-preserved individuals, 27 (or 71.1%) reflected presence of one or more pathological lesions. The majority of these lesions presented as periosteal reaction throughout the skeleton, as well as regionally specific lesions such as *cribra orbitalia*, porotic hyperostosis, and Schmorl's nodes. Importantly, many of these lesions are considered "non-specific indicators of stress." Additionally stress related "lesions" such as degenerative joint disease and spinal osteophyte formation were present amongst the sample.

Cribra orbitalia (CO) and porotic hyperostosis (PH) was identified in several individuals in the sample. More specifically, five individuals presented with CO and six presented with PH. Despite the similar frequencies of presence, PH had more absences (22 absent, 10 unobservable) of the lesions as opposed to unobservability in CO (7 absent, 26 unobservable). Porotic hyperostosis manifests macroscopically as bilateral, asymmetric porosity of the cranial vault caused by the thinning of the external laminae (Brinkley 2018; Brinkley et al. 2020; Chaichun et al. 2021; Rothschild et al. 2023; Rothschild and Lambert 2022; Ortner 2003). Progressive porotic

hyperostosis is often accompanied by porosity of the orbits called *cribra orbitalia*. These lesions are first and foremost considered non-specific indicators of stress, meaning their presence is evidence of a stress event of variable origins (Ortner 2003; O'Donnell et al. 2020). PH and CO may result as a primary or secondary effect of a pathological process. Traditionally, PH and CO, were considered to be evidence of anemia, more specifically iron-deficiency anemia, although this is a limited perspective (Grauer 2019). PH and CO may also be indicative of hemorrhage events, cause by diseases such as scurvy and rickets; generalized lack of nutrient relating to starvation or complete lack of one or more vitamins; a secondary reaction following a localized inflammation caused by trauma or infection of the scalp/nasal sinuses; recently it has been considered to be a secondary expression of upper-respiratory infections (Brinkley et al. 2018; Brinkley 2020; Brinkley et al. 2018; Chaichun et al. 2021; Grauer 2019; Rothschild et al. 2023; Rothschild and Lambert 2022; Ortner 2003; O'Donnell et al. 2020; Pilloud and Schwitalla 2020). The preservation of the occipital, parietals, and orbits allowed for the observation of these lesions within the cremations. Differential diagnosis as to the etiological cause for the CO and PH lesions is beyond the scope of this project but is discussed in the "future directions" portion of the chapter. Importantly, CO and PH are often identified through the bilateral nature of the lesion. In most cases within the sample, an individual would have cranial vault fragments or orbits from one side of the skull and lack preservation on the other side, prohibiting the identification and description of the complete affected area (see Tables 5 and 7). Identification of lesions only observable in one side of the cranium was done carefully but were considered present.

Periosteal bone reaction is also considered a localized non-specific indicator of stress, which presents as new bone formation, and is one of the most commonly identified pathological lesions

in archaeological samples (Roberts 2019). Presence of periosteal bone reaction is most broadly indicative of a disturbance to the periosteum. Periosteal bone reaction within the sample was the most identified lesion, especially amongst the bones of the lower appendages. Presence of periosteal reaction bone reaction was identified in varying regions of the skeleton including six times in the cranium, once in the axial skeleton, twenty-two times in the appendicular skeleton, and twice in the extremities. The common occurrence of periosteal reaction, paired with the fact that sites for manifestation are often well-preserved in cremations, made the frequency of presence in individuals throughout the sample unsurprising. Etiologies for the cause of these periosteal lesions are numerous including inflammation, infection, trauma, and/or hemorrhage (Grauer 2019; Jungmann and Schaeffeler 2023; Pilloud and Schwitalla 2020; Walker et al. 2023). The ultimate cause of periosteal reaction in the sample is difficult to pinpoint given the wide array of ways to obtain the lesion and issues of preservation. Although, periosteal reaction is one of the more ambiguous, non-specific indicators of stress, the lesions were interesting when the stage of healing at the time of death was considered. Periosteal lesions can present as active (woven bone), healed (sclerotic bone), and mixed (woven and sclerotic) (Bousson et al. 2023; Brinkley 2020; Duda et al. 2023; Grauer 2019). The majority of periosteal reactionary lesions were categorized as sclerotic or healed as opposed to active (see Table 15). Such healing may be reflective of resiliency as those with healed lesions would have to be healthy enough to sustain the healing process before the time-of-death (see limitations and future directions of this chapter) (O'Donnell et al. 2020).

Schmorl's nodes are lesions that form following the collapse of the intervertebral discs, presenting on the superior and inferior vertebral bodies as smooth walled lesions (Faccia and Williams 2008; Eski et al. 2022; Wagner et al. 2000). Schmorl's nodes may be present on any

vertebrae from the spinal column as intervertebral discs can herniate throughout but are most common on the weight-bearing lower thoracic and lumbar vertebrae. Schmorl's nodes may be a result of congenital defects, trauma, repeated stress, and/or senescence (Mardini et al. 2023; Resnick and Niwayama 1978). These lesions in the sample were identified in the lower spinal column including the thoracic and lumbar vertebrae on both the superior and inferior vertebral bodies (see Table 11). These lesions are most consistent with occupational stress and repetitive motion causing the herniation of discs (Robb et al. 2001). These lesions were identified due to the excellent preservation of the vertebral bodies (see Table 11); even those that were classified as fragmentary had adequate preservation of both the superior and inferior portions of the vertebrae. Schmorl's nodes are often found in tandem with spinal osteophyte formation and broader degeneration of the spine (Üstundağ 2009), both of which were identified in IV-548.

Degenerative joint disease (DJD) and spinal osteophyte formation were present throughout joints and vertebrae in the sample (see Tables 18 and 19). DJD was sparingly identified in the skull, shoulder, knee (two occurrences), elbow, wrist, hip, and ankle (two occurrences) (see Table 18). DJD is caused by wear on the joints over time. The most common cause for joint degeneration is long-term occupational stress and senescence. Degenerative joint disease accounts for a large number of lesions identified in archaeological samples (Matczak et al. 2023; Waldron 2019). Spinal osteophyte formation was characterized in the sample through bony outgrowths on the vertebrae, most commonly on the lumbar, then thoracic, and cervical vertebrae (see Table 19). Like DJD, spinal osteophyte formation is common in individuals with consistent occupational stress, osteoarthritis, and senescence (Mardini et al. 2023; Ortner 2011).

To summarize, pathological lesions throughout all regions of the body were observable with relative clarity. Notably, lesions that develop in areas of the body that are known to preserve

well post-incineration are among those that are most observable in the sample. For the appendicular skeleton, periosteal reaction was most commonly found on the proximal/distal ends and mid-shafts of long bones, which are known to preserve well in cremation as they are encased in muscles and ligaments. Preservation of the epiphyseal portions also allowed for the observation of degenerative joint disease throughout the sample. On the skull, bones of the cranial vault are often preserved in cremation due to the thickness and density of the bone, allowing for the observation of porotic hyperostosis and periosteal reaction (Fairgrieve 2007). Conversely, orbits may be obscured by the cremation process due to their fragility. This is reflected in the fact that *cribra orbitalia* is present amongst the sample with a higher degree of unobservability. The preservation of the axial skeleton, more specifically the vertebral column is highly variable depending upon the cremation ritual. The Schmorl's nodes identified within the sample were found among the lower thoracic and lumbar vertebrae which are robust and dense making them more likely to be present post-incineration as opposed to the cervical or superior thoracic vertebrae (Fairgrieve 2007). The preservation of the vertebrae also allowed for the observation of spinal osteophyte formation on the lumbar, thoracic, and cervical vertebrae. Bones that make up the hands and feet have variable preservation but may be spared by the cremation process because of their density and the pugilistic position the body takes during the burning process (Fairgrieve 2007).

Lesions associated with non-specific stress such as *cribra orbitalia*, porotic hyperostosis, and periosteal reaction were observable within the sample. Bone abnormalities relating to repetitive biomechanical stress to the skeleton including degenerative joint disease, spinal osteophyte formation, and Schmorl's nodes were also identifiable. It is important to note that the pathological data collected from the burned and fragmented human skeletal remains is

representative of the *minimum* observations of pathological lesions within each individual as noted by Cerezo-Román (2013). By no means are these observations holistically representative of the pathology that may have been present at one time, partially proving Hypothesis III correct. Most basically the findings from this investigation contribute the frequency and type of pathological lesions in the cremations from Phaleron.

As far as what might they tell us about ancient Athens, we might presume that health was somewhat variable, but skewed towards individuals experiencing one or more stress events which may include infections, metabolic disease, inflammatory or hemorrhage events, generalized stress, and/or trauma during the rise of the polis. This is illustrated by the fact that 71.1% of the sample has presence of one or more pathological lesion(s). Additionally, markers of biomechanical stress, including degenerative joint disease, spinal osteophyte formation, and Schmorl's nodes, were found throughout the sample. These finding may indicate hard manual labor and/or prolonged occupational stress over time. Differential diagnoses are beyond the scope of this project (see below), so more clinical diagnoses as to the etiological cause for the lesions were not determined. This study lays the foundation for further research on trends of disease and health in the cremation sample from Phaleron, which may contribute to our broader understanding of these trends in Archaic Period.

Moreover, those that had preserved elements that were absent for pathological lesions may not be true reflections of absence as discussed in the Osteological Paradox (Wood et al. 1992). Those that present as absence of pathological lesions may might not have been affected with an aliment reflecting true absence. It is also possible that individuals with absence of lesions would have been in such poor health that they perished before the manifestation of pathological lesions was possible, this would suggest they were among the least healthy individuals in the sample yet

with no evidence of disease. In this way, the absence of present pathological lesions is not the total absence of disease in the individuals, these concepts are known as hidden heterogeneity and fragility (Wood et al. 1992). Conversely, those that are more-well preserved and have presence of healed pathological lesions, may be representative of the individuals that were immunologically resilient and in good health, enough to withstand the poor health event and survive long enough to heal. This would imply the individuals with present lesions may be among the healthiest of the sample (Wood et al. 1992).

Among the lesions found in the sample, the concept of the Osteological Paradox is most prevalent to *cribra orbitalia*, porotic hyperostosis, and periosteal reaction. These lesions may take some time to manifest in the body but may be caused by a fast-acting pathological agent(s) that would cause an individual in poor health to perish quickly when exposed, such as an infection. If an individual was in poor health or otherwise compromised prior to the exposure of an infection, they might perish before lesions manifest. Other lesions identified in the sample are less applicable to the Osteological Paradox as discussed by Wood (et al. 1992). Lesions related to aging or long-term occupational stress are caused by wear and tear to the body over long periods of time as opposed to fast acting pathological conditions. If an individual has total absence of degenerative joint disease or spinal osteophytes one might assume they did not live long enough to acquire these lesions. Therefore, lesions associated with degeneration of the body are less affect by concepts of hidden heterogeneity.

Fully addressing the Osteological Paradox, is beyond the scope of this study, but these factors must be considered when drawing conclusions on health and disease in the past. The findings of this study addressed some of these issues by being aware of the limitations of pathological analysis in cremations and through deep consideration as to precisely what

conclusions can be drawn from the data that was collected. Further discussion of ways to confront the paradox are discussed below.

APPLICATIONS TO BIOARCHAEOLOGY AND CREMATION STUDIES

Some practical applications that come from this study should include the emphasis of the standardized approach for all cremations within a sample. The standardized approach for this investigation, composed of methods from Buikstra and Ubelaker (1994), the Arizona State Museum (2018), and Cerezo-Román (2013, 2020), included all methods that would be employed on a fully preserved, complete skeleton. Each cremation, regardless of preservation was analyzed for all variables of the biological profile. In the event they were missing or had poorly preserved elements they were noted as unobservable as opposed to skipping the documentation all together. Such unobservable data was integral to the project. Adding this third categorical variable allowed for comparative results throughout the entire sample, regardless of preservation and illustrated which regions of the skeleton were most affected in the incineration process, making the unobservability data as valuable as absence and presence data.

In doing pathological research on cremations, one must possess an acute understanding of changes to bones caused by pathology, burning, and taphonomy. Moreover, one must be able to identify these changes as they appear alongside one another and have the ability to identify the etiology for the changes to the bone. An advanced knowledge of lesion formation and pathological processes is required in order to identify lesions in cremations, especially those that manifest bilaterally. In many cases, lesions may be present and observable on well-preserved fragments from one side, while the other side is absent or otherwise unobservable. In this way, pathological analysis in cremations is assumptionary and can only be done with a proper

knowledge and understanding of pathological lesions. If a lesion, like porotic hyperostosis for example, presents as coalesced porosity with thickening of the external laminae on fragments from the right side, while the left side is completely unobservable, the individual may be categorized as present for porotic hyperostosis. This must be documented accordingly (ie: individual presents with PH on fragments from the right side, left side unobservable). While the presence of porotic hyperostosis may be identified, further observations such as spread, degree or estimations of the entire affected area as recommended by Stuart-Macadam (1982, 1985, 1989) are not possible in some cremations. This logic also extends to estimations concerning degenerative joint disease and spinal osteophyte formation as previously discussed.

The suggestions as listed above are relevant to all cremation research. Standard bioarchaeological data collection was written for "the ideal skeleton" which would be a single, well-preserved, fully intact, unburned skeleton. In some studies, this is the reality of the sample population, but not for cremation analysis. Therefore, the construction of the biological profile and paleopathological data collection must be modified in some ways to be more meticulous. These modifications transcend cremation research and are applicable to bioarchaeological studies which include highly fragmented, poorly preserved unburned human skeletal remains and studies conducted on co-mingled burials.

Cremations as a whole are considered extremely difficult to analyze within bioarchaeology. Cremation is considered a specialty amongst bioarchaeologists, despite the fact that cremation rituals have been practiced in cultural contexts all over the world, for thousands of years (Williams 2005). In some ways, standard bioarchaeologists (or those that study only unburned human skeletal remains) consider cremations to be too damaged to glean any meaningful data, especially considering pathology (Ubelaker 2023). This study finds that despite

the challenges imposed by the incineration process, paleopathological analysis on cremated human skeletal remains can yield valuable information. This investigation serves to illustrate that with rigorous reconstruction, careful examination of anatomical regions, and advanced understanding of changes to bone, meaningful pathology data may be collected.

LIMITATIONS

Preservation and taphonomy are natural limitations to the amount of pathological data that may be collected from burned and fragmented human skeletal remains, as extensively discussed throughout this chapter. A cremation will never be fully reflective of the pathological lesions that may have been once there, rather the findings represent the minimum number of observations. The lesions that are observable, however, still contribute to our broader knowledge and understanding of non-specific and biomechanical stress in the sample.

Selection bias is also a limitation of pathological studies in cremations. The pathological lesions found amongst the cremations were only observable in the elements that preserve post-incineration. This study recognizes these limitations by including preservation as a key component in the research questions and by not drawing any unsupported conclusions about disease and health in the past beyond what is supported by the pathological lesions that were identified. This study recognized that the analyzed individuals likely had pathological lesions that became unidentified due to the changes imposed by fire and taphonomy.

In addition to confronting the Osteological Paradox (as mentioned above), addressing co-morbidities is exceptionally difficult in cremations. The field of pathology has more recently begun to stress the importance of identifying co-morbidities, stating that our understandings of health may be too simplistic (Brinkley et al. 2020). Co-morbidities refer to when more than one

aliment or poor health events happen at the same time, often exacerbating the effects of one another. This could lead to the manifestation of pathological lesions reflective of one or more causes of unknown etiology. Metaphorically speaking, this is like a pathological case of the chicken and the egg. A contemporary example of a co-morbidity would be contracting COVID-19 and upper-respiratory influenza at the same time. Paleopathologically, addressing co-morbidities could be discerning the case of porotic hyperostosis in an individual that presents with evidence of concurrent scurvy and anemia. Addressing co-morbidities, again, is beyond the scope of this project, but would be exceedingly difficult in cremations. In many cases, in order to address co-morbidities, it is advantageous to have a relatively well-preserved skeleton. This may be possible in cremations categorized as partial or complete skeletons but would not be applicable to those categorized as "fragments of bone."

FUTURE DIRECTIONS

A major step for cremation analysis would be the construction of an expansive, standardized methodological publication for highly burned and fragmented human skeletal remains, similar to that of Buikstra and Ubelaker's (1994) *Standards for Data Collection from Human Skeletal Remains*. Publications briefly outlining a standardized approach to cremation analysis do exist such as Cerezo-Román (2020). Such publications should be expanded to create a laboratory guide to cremations that includes the current methods for reconstruction, inventory, taphonomy, sex and age-at-death estimations, pathological data collection, and thermal alteration analysis. A laboratory manual such as this would help to standardize the approach to cremations amongst specialists and contribute to the accessibility of cremation methods for bioarchaeologists that are non-specialists,

Non-specific indicators of stress are one of the most observable lesions present in unburned and burned archaeological human skeletal remains, including periosteal reaction, *cribra orbitalia*, and porotic hyperostosis. Recent studies have found success examining the degree of healing in *cribra orbitalia* and porotic hyperostosis in understanding fragility in skeletal samples. O'Donnell (et al. 2020) finds that those with active lesions at the time of death were the most frail, those with healed lesions were the least frail, and any individual with presence of lesions (regardless of the degree of remodeling) was at an increased risk for mortality. The application of such research to cremations, like those from this investigation, may offer a deeper understanding of health in the past, despite the fact that the observable lesions are largely non-specific. Additionally, it would help to further address factors of the aforementioned Osteological Paradox. It would be exceedingly interesting to see if these findings were also reflected in sclerotic, woven, and mixed periosteal reactions in both burned and unburned human skeletal remains.

In the well-preserved or partially complete cremations the application of Ortner's differential diagnosis would help to pinpoint certain "clinical diagnoses" of pathologies in cremations. Differential diagnoses have been sparingly conducted on cremated human skeletal remains given the fact that some areas of the skeleton may be completely unobservable post-incineration. The differential diagnosis is constructed by observing the type of bone abnormality and their distribution throughout the skeleton. The observer must be well acquainted with disease processes as well as physiological factors that may affect the body's response to disease (Ortner 2011). In essence, differential diagnosis considers all of the underlying diseases that could cause the lesions present on the skeleton. From there, the researcher will use the description of the pathology, paleopathological reference texts, and their knowledge of disease as well as the

context to estimate the disease or ailment that caused the skeletal lesion (Ortner 2011; Buikstra 2017). Although a diagnosis may be helpful, especially when exploring specific diseases such as syphilis or tuberculosis, they are not necessarily required to produce powerful scholarship regarding pathology in cremations but could help to understand the underlying health conditions of the samples. Even more applicable could be a skeletal regional approach to differential diagnosis in cremations. German bioarchaeologists have made strides in doing differential diagnosis on cremated cranial vault fragments, with some success (Nováček and Schultz 2021). This would entail employing the methods of differential diagnosis to skeletal regions such as the skull, appendicular and axial skeleton, and/or extremities. The pitfall to this approach would be the lack of a holistic perspective to the differential diagnosis which may miss co-morbidities, but nonetheless would produce even more robust pathological data from cremations.

The application of osteobiographies to well-preserved cremations would be more enlightening in terms of social bioarchaeology. Osteobiographies utilize the human skeleton, pathologies, and taphonomic features and employ social theory in order to explore normative experiences and "successions of status" of individuals, often non-elites, within their communal, societal, or cultural framework (Robb 2002). The constructions of osteobiographies of cremations, especially those that are well-preserved, would contribute to our understandings of intersectional social identity including the nuances of gender, class, health, and age (Robb 2022).

Lastly, the future of cremation investigations (including this one) should include multi-variable and scalar comparative studies. This study found that with slight modifications and additions cremations can be analyzed using the same methodology for analysis of inhumations. Comparison of cremations and inhumations from the same site including which pathological lesions are present and their frequency may help to further understand broader population health

and fill in the gaps when pathological lesions are poorly preserved in cremations. This research, in addition to differential diagnoses, may help to identify underlying diseases that are present within the cremation sample, under the assumption the cremations and inhumations were individuals from the same past population. This would be most fitting for sites with cremations and inhumations that were conducted contemporaneously in antiquity, such as Phaleron.

Such comparative studies may then be applied to other regional sites and even different cultural contexts. The comparison to regional sites may help to glean larger understandings of health and disease across time and space, both between individuals that were cremated or inhumated, whereas non-regional or cross-cultural comparisons may help to illustrate how differences in the cremation ritual may differentially affect preservation of pathologies in cremations.

Chapter 6: Conclusion

This thesis utilized a standardized methodological approach, combining methods outlined in Buikstra and Ubelaker (1994), ASM (2018), and the works of Cerezo-Román (2013, 2020) to examine the preservation of pathological lesions in cremated human skeletal remains from the Archaic Period Site of Phaleron. Methods for data collection remained standard amongst all individuals, regardless of their preservation in order to acquire comparative results. Precision of pathological data was highly variable and dependent on preservation of each individual. Assessment of the entire skeleton, skeletal region, each bone, and fragment for preservation and pathological lesions allowed for precise data collection. This approach helped to reveal greater relationships between pathological lesions and preservation within cremations.

The results of this thesis suggest that bones that are thick and dense preserve well in cremations. In addition, bones that are incased in tissue are less fragmented and more represented. This was reflected through the preservation of bones of the cranial vault, thoracic/lumbar vertebrae, and lower appendages in the sample as opposed to the lack of preservation in the facial bones, ribs, and carpals. Subsequently, pathological lesions that manifest on elements that preserve well post-incineration were the most observable. These findings are consistent with similar research on cremations, pathologies, and preservation (Mackiewicz and Szczurowski 2023; Owens 2010; Reinhard and Fink 1994; Salo et al. 2022; Scheelen-Nováček et al. 2021; Veselka et al. 2021).

Preservation allowing for the observation of pathological lesions was more dependent on the size of the fragment as opposed to the frequency of fragments. For example, the lumbar and thoracic vertebrae were noted in a lower frequency than the cervical fragments. The lumbar and thoracic were present in larger, more reconstructable fragments, allowing for more observability.

Regardless of this finding, all fragments, no matter the size, were analyzed for pathological lesions.

Lesions were identified in each skeletal region (cranium, appendicular skeleton, axial skeleton, and extremities) in one or more individuals throughout the sample. These lesions including porotic hyperostosis, *cribra orbitalia*, and periosteal reaction are reflective of non-specific stress. Additionally, lesions associated with prolonged, repetitive biomechanical stress were identified in the sample, including Schorl's nodes, osteophyte formation, and degenerative joint disease. Importantly, these findings represent the minimum number of observable pathological lesions in each individual. Throughout the sample, 71.1% of individuals had presence of one or more pathological lesions, 18.4% of individuals were well-preserved enough to make assessments of pathological lesions but reflected absence of any lesions, and 10.5% were too poorly preserved to make any estimations on presence or absence of pathological lesions (coded as unobservable).

Analyzing pathologies in cremated human skeletal remains presents inherent difficulties, yet it remains a valuable avenue for understanding disease in the past. This may only be done through focused research that meticulously reconstructs and carefully analyzes each fragment of bone. This approach must remain standard amongst all individuals of the sample, as carried out in this investigation. Moreover, a holistic approach focusing on the entire skeleton, skeletal region, bone, and each fragment will allow for the observations of lesions that may be associated with non-specific and biomechanical stress.

FUTURE DIRECTIONS OF THIS RESEARCH

The next step in this research is to continue analysis on the remaining cremations in the sample from Phaleron and incorporate them into the data set presented in this thesis. Following their inclusion of the remaining cremations from Phaleron, the addition of the mortuary context and pyre construction (currently being carried out by Dr. Jessica Cerezo-Román),and the wider site and regional context will guide the research. When the analyzed individuals are contextualized within these frameworks, the findings may be representative of broader health trends at the rise of the polis. Moreover, comparative research with the inhumated individuals from Phaleron may also shed light on which pathologies were lost to the cremation process and offer more evidence for population specific ailments that are reflected as non-specific evidence of stress in the cremation sample.

The addition of osteobiographies and differential diagnosis at varying scales of preservation may be interesting to pursue with the most well-preserved individual, an individual with average preservation, and poorly preserved individual within the sample. These analyses will further contribute to our understandings of preservation of pathologies in cremations and what they can tell us about health and disease in ancient Athens and Attica.

References

Adserias-Garriga

2023 Skeletal Alteration of Burnt Remains through Fire Exposure. In *Burnt Remains: Recovery, Analysis, and Interpretation (First Edition)*, edited by Sarah Ellingham, Joe Adserias-Garriga, Sara C. Zapico, and Douglas H. Ubelaker, pp.113-132. John Wiley & Sons Ltd, Chichester, West Sussex, England.

Agarwal, Sabrina C.

2012 The Past of Sex, Gender, and Health: Bioarchaeology of the Aging Skeleton. *American Anthropologist* 114(2):322–335. DOI:10.1111/j.1548-1433.2012.01428.x.

2016 Bone Morphologies and Histories: Life Course Approaches in Bioarchaeology. *American Journal of Biological Anthropology* 159(S61): 130-149.

Agarwal, Sabrina C. and Patrick Beauchesne

2011 It is Not Carved in Bone. In *Social Bioarchaeology,* edited by Sabrina C. Agarwal and Bonnie Glencross, pp. 312-332. Wiley-Blackwell, Oxford.

Angel, J. Lawrence

1981 History and Development of Paleopathology. *American Journal of Physical Anthropology* 56(4):509–515. DOI:10.1002/ajpa.1330560425.

Arizona State Museum, University of Arizona

2018 ASM Osteology Recording Packet. Cultural Resource Services Forms & Guidelines. vol. 2018. Arizona State Museum, University of Arizona, Tucson, Arizona.

Armelagos, George J. and Dennis P. Van Gerven

2003 A Century of Skeletal Biology and Paleopathology: Contrasts, Contradiction, and Conflicts. *Genetics, Biology, and Race: Understanding Human Differences* 105(1):53-64. DOI:10.1525/aa.2003.105.1.53.

Aufderheide, Arthur C.

2003 *The Scientific Study of Mummies*. Cambridge University Press, Cambridge.

Baby, Raymond S.

1954 *Hopewell Cremation Practices (no. 1)*. Columbus: Ohio Historical Society.

Baker, Ronald K.
1984 The Relationship of Cranial Suture Closure and Age Analyzed in a Modern Multi-Racial Sample of Males and Females. Unpublished M.A., California State University, Fullerton, California.

Bass, William M.
1984 Is it Possible to Consume a Body Completely in a Fire?. In *Human Identification: Case Studies in Forensic Anthropology*, edited by Ted A. Rathburn and Jane E. Buikstra, pp. 159-167. Charles C. Thomas Publisher, Springfield, Illinois.

Bass, William M. and Richard L. Jantz
2004 Cremation Weights in East Tennessee. *Journal of Forensic Science*s 49(5):901-904. DOI: 10.1520/JFS2004002.

Bengtson, J., and J. O'Gorman
2017 Women's Participation in Prehistoric Warfare: A Central Illinois River Valley Case Study. *International Journal of Osteoarchaeology* 27(2):230–244. DOI:10.1002/oa.2532.

Binford, Lewis R.
1963 An Analysis of Cremations from Three Michigan Sites. *Wisconsin Archaeologist* 44(2):98–110.

Blakey, Michael L.
1987 Intrinsic Social and Political Bias in the History of American Physical Anthropology: With Special Reference to the Work of Aleš Hrdlička. *Critique of Anthropology* 7(2):7–35. DOI:10.1177/0308275X8700700203.

Bohnert, Michael, Thomas Rost, and Stefan Pollak
1998 The Degree of Destruction of Human Bodies in Relation to the Duration of the Fire. *Forensic Science International* 95(1):11–21. DOI:10.1016/S0379-0738(98)00076-0.

Boldsen, Jesper L., George R. Milner, Lyle W. Konigsberg, and James W. Wood
2002 Transition Analysis: A New Method for Estimating Age from Skeletons. *Paleodemography* 73–106. DOI:10.1017/cbo9780511542428.005.

Bonucci, Ermanno, and Giorgio Graziani
1975 Comparative Thermogravimetric, X-Ray Diffraction and Electron Microscope Investigations of Burnt Bones from Recent, Ancient and Prehistoric Age. *Atti della*

Accademia Nazionale dei Lincei. Classe di Scienze Fisiche, Matematiche e Naturali. Rendiconti 59:517–532.

Bousson, Valérie, Damien Bisseret, and Rachid Kaci
2023 Overview of Periosteal Reaction by Imaging. *Seminars in Musculoskeletal Radiology* 27(4):421–431. DOI:10.1055/s-0043-1770354.

Bradtmiller, B. and Jane E. Buikstra
1984 Effects of Burning on Human Bone Microstructure: A Preliminary Study. *Journal of Forensic Sciences* 29(2):535–540. DOI:10.1520/JFS11701J.

Brinkley, Megan
2018 *Cribra orbitalia* and Porotic Hyperostosis: A Biological Approach to Diagnosis. *American Journal of Biological Anthropology* 167(4):896-902.

Brinkley, Megan, Rachel Ives, and Simon Mays
2020 *The Bioarchaeology of Metaboloic Bone Disease*. 2nd ed. Academic Press, London.

Brooks, S. T. and Judy Myers Suchey
1990 Skeletal Age Determination Based on the Os Pubis: A Comparison of the Acsádi-Nemeskeri and Suchey-Brooks Methods. *Human Evolution* 5:227-238.

Buikstra, Jane E.
1977 Biocultural Dimensions of Archaeological Study: A Regional Perspective. *Biocultural Adaptation in Prehistoric America*:67–84.

2010 Paleopathology: A Contemporary Perspective. In *A Companion to Biological Anthropology*, pp. 395–411. John Wiley & Sons, Ltd, Chichester, West Sussex, England.

2019 *Ortner's Identification of Pathological Conditions in Human Skeletal Remains (Third Edition)*. Academic Press, London.

2023 Inferring Ancient Human Activities Through Skeletal Study: An Example from Archaic Greece. In *Biocultural Evolution: An Agenda for Integrative Approaches*, edited by Fotios Alexandros Karakostis and Gerhard Jäger, pp. 25–54. Kerns Verlag, Tübingen, Germany.

Buikstra, Jane E. (editor)

2019 *Ortner's Identification of Pathological Conditions in Human Skeletal Remains*. Academic Press, New York.

Buikstra, Jane E., Della C. Cook, and Katelyn L. Bolhofner
2017 Introduction: Scientific Rigor in Paleopathology. *International Journal of Paleopathology* 19:80–87. DOI:10.1016/j.ijpp.2017.08.005.

Buikstra, Jane E. and Sharon DeWitte
2019 A Brief History and 21st Century Challenges. In *Ortner's Identification of Pathological Conditions in Human Skeletal Remains (Third Edition)*, edited by Jane Buikstra, pp. 11-20. Elsevier, London.

Buikstra, Jane E. and Mark Swegle
1989 Bone Modification Due to Burning: Experimental Evidence. In *Bone Modification*, edited by Robson Bonnichsen and Marcella H. Sorg, pp. 247-258, The Center for the Study of the First Americans Institute of Quaternary Studies. University of Maine, Orono.

Buikstra, Jane E. and Douglas H. Ubelaker
1994 *Standards for Data Collection From Human Skeletal Remains.* Arkansas Archaeological Survey Research Series No. 44. Fayetteville, Arkansas

Büyükkarakaya, Ali Metin, Yasin Gökhan Çakan, Martin Godon, Yılmaz Selim Erdal, and Erhan Bıçakçı
2019 Handling Dead Bodies: Investigating the Formation Process of a Collective Burial from Neolithic Tepecik-Çiftlik, Central Anatolia (Turkey). *Journal of Anthropological Archaeology* 56:101118. DOI:10.1016/j.jaa.2019.101118.

Camp, John M.
2001 *The Archaeology of Athens*. Yale University Press, New Haven.

Cerezo-Roman, Jessica I.
2013 Unpacking personhood and identity in the Hohokam area of southern Arizona. Unpublished Ph.D., The University of Arizona, Tucson.

2015 Unpacking Personhood and Funerary Customs in the Hohokam Area of Southern Arizona. *American Antiquity* 80(2):353–375. DOI:10.7183/0002-7316.80.2.353.

2020 Métodos morfoscópicos para analizar restos humanos quemados y cremaciones. *Noroeste de México*(1):97–122.

Cerezo-Román, Jessica, Anna Wessman, and Howard Williams
2017 *Cremation and the Archaeology of Death*. Oxford University Press, Oxford.

Cerezo-Román, Jessica I. and Howard Williams
2014 Future Directions for the Archaeology of Cremations. In *Transformation by Fire: The Archaeology of Cremation in Cultural Context*, edited by Ian Kuijt, Colin P. Quinn, and Gabriel Cooney, pp. 240-256. The University of Arizona Press, Tucson.

CIAS Research Center for Anthropology and Health
2023 Phaleron Bioarchaeological Project (Duration: 2015-Ongoing). Electronic document, https://cias.uc.pt/projects/phaleron-bioarchaeological-project/, accessed April 8th, 2024.

Chaichun, Amnart, Laphatrada Yurasakpong, Athikhun Suwannakhan, Sitthichai Iamsaard, Supatcharee Arun, and Arada Chaiyamoon
2021 Gross and Radiographic Appearance of Porotic Hyperostosis and Cribra Orbitalia in Thalassemia Affected Skulls. *Anatomy & Cell Biology* 54(2):280–284. DOI:10.5115/acb.20.323.

Chhem, Rethy, George Saab, and Richard N. Bohay
2008 Diagnostic Paleoradiology for Paleopathologists. In *Paleoradiology: Imaging Mummies and Fossils*, edited by Rethy Chhem and Don Brothwell, pp. 73–118. Springer, Heidelberg.

Chryssoulaki, Stella
2017 The Archaic Cemetery at the Phaleron Delta [in Greek], Lecture, Acropolis Museum http://www.blod.gr/lectures/Pages/viewlecture.aspx

Chryssoulaki, Stella, Anna Alexandropoulou, and Theosevious Aggouras
2014 The Excavations of the 26th EPCA (Ephorate of Prehistoric and Classical Antiquities) at the Phaleron Delta, https://www.snfcc.org/construction/ archaeological-findings/

Cohen, Mark Nathan and Sharon Bennet

1993 Skeletal Evidence for Sex Roles and Gender Hierarchies in Prehistory. In *Sex and Gender Hierarchies*, edited by Barbara D. Miller, pp. 273-296. Cambridge University Press, Cambridge.

Cook, Della C. and Mary L. Powell
2006 The Evolution of American Paleopathology. In *Bioarchaeology: The Contextual Analysis of Human Remains*, edited by Jane E. Buikstra and Lane A. Beck, pp. 281-323. Academic Press, New York.

Correia, Mayne P.
1997 Fire modification to Bone: A review of the Literature. In *Forensic taphonomy: the postmortem fate of human remains*, edited by William D. Haglund and Marcella H. Sorg, pp. 275-293, CRC Press, Boca Raton Florida.

Crespo, Fabian
2020 Reconstructing Immune Competence in Skeletal Samples: A Theoretical and Methodological Approach. In *Theoretical Approaches in Bioarchaeology*, edited by Colleen M. Cheverko, Julia R. Prince-Buitenhuys, and Mark Hubbe, pp. 72-96. Routledge, London.

DeHaan, John D
2018 Post-Mortem Repositioning of Human Bodies in Fires. *International Journal Criminal Forensic Science.* 2(3): 3-62.

Devlin, Joanne B., and Nicholas P. Herrmann
2015 Chapter 6 - Bone Colour. In *The Analysis of Burned Human Remains (Second Edition)*, edited by Christopher W. Schmidt and Steven A. Symes, pp. 119–138. Academic Press, San Diego.

Dirkmaat, Dennis C., Gregory O. Olson, Alexandra R. Klales, and Sara Getz
2012 The Role of Forensic Anthropology in the Recovery and Interpretation of the Fatal-Fire Victim. In *A Companion to Forensic Anthropology*, pp. 113–135. John Wiley & Sons, Ltd., Chichester, West Sussex, England.

Dokládal, M.
1971 A Further Contribution to the Morphology of Burned Bones. In *Proceedings of the Anthropological Congress Dedicated to Ales Hrdlicka*, edited by N. Novtny, pp. 561-568. Czechosalavak Academy of Sciences, Prague.

Drancourt, Michel, and Didier Raoult
2005 Palaeomicrobiology: Current Issues and Perspectives. *Nature Reviews Microbiology* 3(1):23–35. DOI:10.1038/nrmicro1063.

Duda, Georg N., Sven Geissler, Sara Checa, Serafeim Tsitsilonis, Ansgar Petersen, and Katharina Schmidt-Bleek
2023 The decisive early phase of bone regeneration. *Nature Reviews Rheumatology* 19(2):78– 95. DOI:10.1038/s41584-022-00887-0.

Duday, Henri
2000 Validation des Paramètres de Quantification, Protocoles et Stratégies dans L'étude Anthropologique des Sépultures Secondaires à Incinération. L'exemple des Nécropoles Protohistoriques du midi de la France. In *Archéologie de La Mort, Archéologie de la Tombe au Premier Âge du -Fer, vol 5.*, edited by Bernard Dedet, Phillippe Gruat, Georges Marchand, M. Py, Martine Schwaller, pp. 5-29. Actes du XXI Colloque International de l'AFEAF, Lattes.

Duday, Henri, Anna Maria Cipriani, and John Pearce
2009 *The Archaeology of the Dead: Lectures in Archaeothanatology*. Oxbow Books, Oxford.

Duday, Henri, and Mark Guillon
2006 Understanding the Circumstances of Decomposition When the Body Is Skeletonized. In *Forensic Anthropology and Medicine: Complementary Sciences From Recovery to Cause of Death*, edited by Aurore Schmitt, Eugénia Cunha, and João Pinheiro, pp. 117–157. Humana Press, Totowa, New Jersey.

Dudar, J. Christopher
2011 Arthritis. In *OsteowareTM Software Manual 2*, edited by Cynthia A. Wilczak and Erica B. Jones, pp. 76-83. Smithsonian Institution Washington, D.C.

Dunlop, J.
1978 Traffic Light Discoloration in Cremated Bones. *Medicine, Science and the Law* 18 (3):163–173.

Efremov, Ivan M.
1940 Taphonomy: A New Branch of Paleontology. *Pan American Geologist*. 74:81-93.

Ellingham, Sarah, Joe Adserias-Garriga, and Peter Ellis

2023 Burnt Human Remains and Forensic Medicine. In *Burnt Remains: Recovery, Analysis, and Interpretation (First Edition)*, edited by Sarah Ellingham, Joe Adserias-Garriga, Sara C. Zapico, and Douglas H. Ubelaker, pp. 99-112. John Wiley & Sons Ltd, Chichester, West Sussex, England.

Ellingham, Sarah and Sara C. Zapico
2023 Biochemical Alterations of Bone Subjected to Fire. In *Burnt Remains: Recovery, Analysis, and Interpretation (First Edition)*, edited by Sarah Ellingham, Joe Adserias-Garriga, Sara C. Zapico, and Douglas H. Ubelaker, pp. 193-212. John Wiley & Sons Ltd, Chichester, West Sussex, England.

Ekşi, Murat Şakir, Veli Umut Turgut, Gürkan Berikol, Berk Barış Özmen, Sibel Emilie Huet, Taha Dinç, Doğu Küçüksüleymanoğlu, Ömer Orhun, and Emel Ece Özcan-Ekşi
2022 Schmorl's Nodes Could be Associated with Intervertebral Disc Degeneration at Upper Lumbar Levels and End-Plate Disease at Lower Lumbar Level in Patients with Low Back Pain. *Journal of Clinical Neuroscience* 100:66–74. DOI:10.1016/j.jocn.2022.04.004.

Faccia, K. J., and R. C. Williams
2008 Schmorl's Nodes: Clinical Significance and Implications for the Bioarchaeological Record. *International Journal of Osteoarchaeology* 18(1):28–44. DOI:10.1002/oa.924.

Fairgrieve, Scott I.
2007 *Forensic Cremation Recovery and Analysis*. CRC Press, Boca Raton.

Garland, Carey J.
2020 Implications of Accumulative Stress Burdens During Critical Periods of Early Postnatal Life for Mortality Risk Among Guale Interred in a Colonial Era Cemetery in Spanish Florida (ca. AD 1605–1680). *American Journal of Physical Anthropology* 172(4):621–637. DOI:10.1002/ajpa.24020.

Galloway, Allison, Elayne Pope, and Chelsey Juarez
2024 Bone Color Changes and Interpretation of the Temperature/Duration of Fire Exposure to Human Remains in the Forensic Context. *WIREs Forensic Science* e1517: 1-19. DOI:10.1002/wfs2.1517.

Garvin, Heather M., Sabrina B. Sholts, and Laurel A. Mosca

2014 Sexual Dimorphism in Human Cranial Trait Scores: Effects of Population, Age, and Body Size. *American Journal of Biological Anthropology* 154(2): 259-269. DOI: 10.1002/ajpa.22502.

Geller, Pamela L.
2009 Bodyscapes, Biology, and Heteronormativity. *American Anthropologist* 111(4):504–516. DOI:10.1111/j.1548-1433.2009.01159.x.

Gligor, Mihai
2014 The Archaeology of Death: Archaeothanatology. An Introduction. *Annales Universitatis Apulensis Series Historica* 18:5–9. DOI:10.29302/AUASH/introduction-3.

Gonçalves, David, Vanessa Campanacho, Tim Thompson, and Rui Mataloto
2015 The Weight of the Matter: Examining The Potential of Skeletal Weight for the Bioarchaeological Analysis of Cremation at the Iron Age Necropolis of Tera (Portugal). In *The Archaeology of Cremation: Burned Human Remains in Funerary Studies*, pp. 63-96. Oxbow Books, Oxford.

Gonçalves, David, and Ana Elisabete Pires
2017 Cremation Under Fire: A Review of Bioarchaeological Approaches from 1995 to 2015. *Archaeological and Anthropological Sciences* 9(8):1677–1688. DOI:10.1007/s12520-016-0333-0.

Gonçalves, David, Tim. J. U. Thompson, and E. Cunha
2011 Implications of Heat-Induced Changes in Bone on the Interpretation of Funerary Behaviour and Practice. *Journal of Archaeological Science* 38(6):1308–1313. DOI:10.1016/j.jas.2011.01.006.

Gowland, Rebecca L.
2015 Entangled Lives: Implications of the Developmental Origins of Health and Disease Hypothesis for Bioarchaeology and the Life Course. *American Journal of Physical Anthropology* 158(4):530–540. DOI:10.1002/ajpa.22820.

Grauer, Anne L.
2018 Paleopathology. In *Biological Anthropology of the Human Skeleton*, edited by M. Anne Katzenberg and Anne L. Grauer, pp. 447–465. John Wiley & Sons, Ltd. Chichester, West Sussex, England.

2018 A century of paleopathology. *American Journal of Physical Anthropology* 165:904–914. DOI:10.1002/ajpa.23366.

2019 Circulatory, Reticuloendothelial, and Hematopoietic Disorders. In *Ortner's Identification of Pathological Conditions in Human Skeletal Remains (Third Edition)*, edited by Jane E. Buikstra, pp. 491-524. Academic Press, London.

Grauer, Anne L. and Patricia Stuart-Macadam
1998 *Sex and Gender in Paleopathological Perspective.* Cambridge University Press, Cambridge.

Grupe, Von G., and B. Herrmann
1983 Über das Schrumpfungsverhalten Experimentell Verbrannter Spongiöser Knochen am Beispiel des Caput Femoris. *Zeitschrift für Morphologie und Anthropologie* 74(2):121–127.

Ham, Allison C., Daniel H. Temple, Haagen D. Klaus, and David R. Hunt
2021 Evaluating Life History Trade-Offs Through the Presence of Linear Enamel Hypoplasia at Pueblo Bonito and Hawikku: A Biocultural Study of Early Life Stress and Survival in the Ancestral Pueblo Southwest. *American Journal of Human Biology* 33(2):e23506. DOI:10.1002/ajhb.23506.

Herrmann, B.
1977 On Histological Investigations of Cremated Human Remains. *Journal of Human Evolution* 6(2):101–103. DOI:10.1016/S0047-2484(77)80112-7.

Hlad, Marta, Barbara Veselka, Dawnie Wolfe Steadman, Baptiste Herregods, Marc Elskens, Rica Annaert, Mathieu Boudin, Giacomo Capuzzo, Sarah Dalle, Guy De Mulder, Charlotte Sabaux, Kevin Salesse, Amanda Sengeløv, Elisavet Stamataki, Martine Vercauteren, Eugène Warmenbol, Dries Tys, and Christophe Snoeck
2021 Revisiting Metric Sex Estimation of Burnt Human Remains via Supervised Learning Using a Reference Collection of Modern Identified Cremated Individuals (Knoxville, USA). *American Journal of Physical Anthropology* 175(4):777–793. DOI:10.1002/ajpa.24270.

Holck, Per
1969 *Cremated Bones: A Medical-Anthropological Study of an Archaeological Material on Cremation Burials*. 3rd ed. Anthropologiske Shrifter nr. 1c Anatomical Institute, University of Oslo.

Hooten, Earnest A.
1930 *The Indians of the Pecos Pueblo, A Study of Their Skeletal Remains.* New Haven, Yale University Press, New Haven.

Ingvarsson, Anne and Yiva Backstrom
2019 Bioarchaeological Field Analysis of Human Remains from the Mass Graves at Phaleron, Greece with an Introduction by Stella Chryssoulaki and an Appendix by Anna Linderholm, Anna Kjellström, Vendela Kempe Lagerholm, and Maja Krzewińska. *Opuscula* (12): pp.7-158 DOI: 10.30549/opathrom-12-02.

Johnson, Eileen
1985 5 - Current Developments in Bone Technology. In *Advances in Archaeological Method and Theory*, edited by MICHAEL B. Schiffer, pp. 157–235. Academic Press, San Diego.

Jungmann, Pia M., and Christoph Schaeffeler
2023 Bone Stress Injuries at the Ankle and Foot. *Seminars in Musculoskeletal Radiology* 27(3):283–292. DOI:10.1055/s-0043-1766098.

Karakostis, Fotios Alexandros, Jane E. Buikstra, Eleanna Prevedorou, Elizabeth M. Hannigan, Jessica Hotaling, Gerhard Hotz, Hannah Liedl, Konstantinos Moraitis, Thomas J. Siek, Lukas Waltenberger, Kerri J. Widrick, and Katerina Harvati
2021 New Insights Into the Manual Activities of Individuals from the Phaleron Cemetery (Archaic Athens, Greece). *Journal of Archaeological Science* 131:105415. DOI:10.1016/j.jas.2021.105415.

Klales, Alexandra R.
2020 Chapter 6 - Sex estimation Using Pelvis Morphology. In *Sex Estimation of the Human Skeleton*, edited by Alexandra R. Klales, pp. 75–93. Academic Press.

Klales, Alexandra R., Allison Nesbitt, Dennis C. Dirkmaat, and Luis L. Cabo
2023 Recovery and Interpretation of Human Remains from Fatal Fire Scenes. In *Burnt Remains: Recovery, Analysis, and Interpretation (First Edition)*, edited by Sarah Ellingham, Joe Adserias-Garriga, Sara C. Zapico, and Douglas H. Ubelaker, pp. 37-58. John Wiley & Sons Ltd, Chichester, West Sussex, England.

Krogman, Wilton M.

1949 The Human Skeleton in Legal Medicine: Medical Aspects. In *Symposium on Medicolegal Problems Ser 2.*, edited by Samuel A. Levinson, pp. 1-92. Lippincott, Philadelphia.

Kuijt, Ian, Colin P. Quinn, and Gabriel Cooney
2014 *Transformation by Fire: The Archaeology of Cremation in Cultural Context*. University of Arizona Press, Tucson.

Langley, Natalie R., Lee Meadows Jantz, Stephen D. Ousley, Richard L. Jantz and George Milner
2016 *Data Collection Procedures for Forensic Skeletal Material 2.0*. Forensic Anthropology Center, Department of Anthropology, The University of Tennessee, Knoxville, Tennessee

Larsen, Clark Spencer
2015 *Bioarchaeology: Interpreting Behavior from the Human Skeleton*. Cambridge University Press, Cambridge.

Lynnerup, Niels
2019 Mummies and Paleopathology. In *Ortner's Identification of Pathological Conditions in Human Skeletal Remains (Third Edition)*, edited by Jane E. Buikstra, pp. 799-807. Academic Press, London.

Mackiewicz, Klementyna, and Jacek Szczurowski
2023 Limitations and Potential of Analyses of Cremation Remains – Anthropological Analysis of Bone Remains from a Lusatian Culture Cremation Cemetery in Paszowice (Lower Silesia, Poland): Anthropologischer Anzeiger. *Anthropologischer Anzeiger* 80(1):69–83. DOI:10.1127/anthranz/2022/1539.

Matczak, Magdalena D., Jane E. Buikstra, Andrzej M. Wyrwa, and Jessica Pearson
2022 The Problem of Assessing Intervertebral Disc Disease as Impairment and Disability in Bioarchaeology. The Case of a Male Individual from the Late Medieval and Early Modern Period in Łekno, Poland. *Forum Kritische Archäologie* 11 (2022):167–194. DOI:10.17169/refubium-37540.

Mann, RW, SA Symes, and WM Bass
1987 Maxillary Suture Obliteration: Aging the Human Skeleton Based on Intact or Fragmentary Maxilla. *Journal of Forensic Sciences* 32(1):148–157. DOI:10.1520/JFS12337J.

Mardini, Mahmoud, Ali Badawi, Tania Zaven, Raffi Gergian, and Efthymia Nikita
2023 Mechanical stress in the urbanized Roman Phoenician coast. *International Journal of Paleopathology* 43:58–67. DOI:10.1016/j.ijpp.2023.09.008.

Martin, Debra L., Ryan P. Harrod, and Misty Fields
2010 Beaten Down and Worked to the Bone: Bioarchaeological Investigations of Women and Violence in the Ancient Southwest. *Landscapes of Violence* 1(1). Berkely Electronic Press, Berkely.

May, Shannon E.
2011 The Effects of Body Mass on Cremation Weight. *Journal of Forensic Sciences* 56(1):3–9. DOI:10.1111/j.1556-4029.2010.01535.x.

Mayne, Pamela M.
1990 The Identification of Precremation Trauma in Cremated Remains. Unpublished Master's thesis, University of Alberta, Edmonton.

McKern, Thomas W. and T.D. Steward
1957 *Skeletal Age Changes in Young American Males, Analyzed from the Standpoint of Identification.* Technical Report EP-45. Headquarters, Quartermaster Research and Development Command, Natick, Massachusetts.

McKinley, Jacqueline I.
1989 Cremations: Expectations, Methodologies and Realities. In Burial Archaeology: Current Research, Methods and Developments, edited by Charlotte A. Roberts, Frances Lee and J. L. Bintliff, pp. 65-79. British Archaeological Reports, Oxford.

1993 Bone Fragment Size and Weights of Bone from Modern British Cremations and the Implications for the Interpretation of Archaeological Cremations. *International Journal of Osteoarchaeology* 3: 283-287.

1994 Bone Fragment Size in British Cremation Burials and its Implications for Pyre Technology and Ritual. *Journal of Archaeological Science* 21:339-342.

2000 The Analysis of Cremated Bone. In *Human Osteology in Archaeology and Forensic Science*, edited by Margaret Cox and Simon Mays, pp. 403-421.Greenwich Medical Media Ltd., London.

2004 Compiling a Skeletal Inventory: Cremated Human Bone. In *Updated Guidelines to Standards for Recording Human Remains*, edited by Piers D. Mitchell and Megan Brickley, pp. 14-20. British Association for Biological Anthropology and Osteoarchaeology Institute of Field Archaeologists.

2015 Chapter 10 - In the Heat of the Pyre. In *The Analysis of Burned Human Remains (Second Edition)*, edited by Christopher W. Schmidt and Steven A. Symes, pp. 181–202. Academic Press, San Diego.

2016 Complexities of the Ancient Mortuary Rite of Cremation: An Osteological Conundrum. In *Isotopic Landscapes in Bioarchaeology*, edited by Gisela Grupe and George C. McGlynn, pp. 17-41, Springer-Verlag. Heidelberg, Germany.

McKinley, Jacqueline I. and Julie M. Bond
2001 Cremated Bone. In *Handbook of Archaeological Sciences*, edited by Don R. Brothwell and A. Mark Pollard, pp. 281-292. John Wiley & Sons, LTD, Chischester.

Meindl, Richard S., and C. Owen Lovejoy
1985 Ectocranial Suture Closure: A Revised Method for the Determination of Skeletal Age at Death Based on the Lateral-Anterior Sutures. *American Journal of Physical Anthropology* 68(1):57–66. DOI:10.1002/ajpa.1330680106.

Milner, George R.
1992 Determination of Age and Sex: A Manual Prepared for the Dixon Reburial Team. Ms. On file, Dickson Mounds Museum, Lewiston, Illinois.

Milner, George R., and Jesper L. Boldsen
2012 Transition analysis: A Validation Study with Known-Age Modern American Skeletons. *American Journal of Physical Anthropology* 148(1):98–110. DOI:10.1002/ajpa.22047.

Milner, George R., Jesper L. Boldsen, and Roar Hylieberg
2016 ADBOU Version 2.1.046. https://www.statsmachine.net/software/ADBOU2/

Milner, George R., Steven D. Ousely, Jesper L. Boldsen, Sara M. Gertz, Svenja Weise, And Peter Tarp
2021 Transition Analysis 3 (TA3): Trait Manual Public Distribution Draft (Version 1.0). https://www.statsmachine.net/software/TA3/docs/TA3_Trait_Scoring_Manual_1.0.pdf

Moodie, Roy L.
1923 *Paleopathology: An Introduction to the Study of Ancient Evidences of Disease*. University of Illinois Press, Champaign.

Morris, Ian
1987 *Burial and Ancient Society: the Rise of the Greek City State.* Cambridge University Press, Cambridge.

Mulhern, Dawn M. and Erica B. Jones
2011 Chapter 7: Pathological Conditions of the Vertebrae. In *OsteowareTM Software Manual 2*, edited by Cynthia A. Wilczak and Erica B. Jones, pp. 61-68. Smithsonian Institute, Washington D.C.

Murray, K. A. and Jerome C. Rose
1993 The Analysis of Cremains: A Case Study Involving the Inappropriate Disposal of Mortuary Remains. *Journal of Forensic Science* 38:98-103. DOI:10.1520/JFS13381J

Nováček, Jan, and Michael Schultz
2021 Palaeopathological Investigations of Cremated Human Remains ? Methodological and Comparative Study on the Example of Traces of Pathological Conditions in the Skull. *Anthropologischer Anzeiger* 78(1–2):59–81. DOI:10.1127/anthranz/2020/1259.

Nystrom, Kenneth C.
2015 The Bioarchaeology of Structural Violence and Dissection in the 19th-Century United States. *American Anthropologist* 116(4): 765-779.

O'Donnell, Lorna
2016 The Power Of The Pyre – A Holistic Study of Cremation Focusing on Charcoal Remains. *Journal of Archaeological Science* 65:161–171. DOI:10.1016/j.jas.2015.11.009.

O'Donnell, Lexi, Ethan C. Hill, Amy S. Anderson Anderson, and Heather J. H. Edgar
2020 Cribra Orbitalia and Porotic Hyperostosis are Associated with Respiratory Infections in a Contemporary Mortality Sample from New Mexico. *American Journal of Physical Anthropology* 173(4):721–733. DOI:10.1002/ajpa.24131.

Ortner, Donald J.
2003 *Identification of Pathological Conditions in Human Skeletal Remains*. 2nd ed. Academic Press, San Diego.

2011 Human Skeletal Paleopathology. *International Journal of Paleopathology* 1(1):4–11. DOI:10.1016/j.ijpp.2011.01.002.

Osborne, Robin
2009 *Greece in the Making 1200-479 BC*. Routledge, London.

2010 Archaic and Classical Greece. In *The Edinburg Companion to Ancient Greece and Rome,* edited by Edward Bispham, Thomas Harrison, and Brian A. Sparkes, pp.92-97. Edinburg University Press.

Owens, Amanda K.
2010 A Re-Examination of Cremated Remains from the Archaeological Record: An Evaluation of the Process and Application of Current Methods. Unpublished Master's thesis, The University of Alabama, Tuscaloosa.

Pelekidis, Stratis
1916 Excavations at Phaleron. *Archaeologikon Deltion* 2:13–64.

Phenice, T. W.
1969 A Newly Developed Visual Method of Sexing the Os Pubis. *American Journal of Physical Anthropology* 30(2):297–301. DOI:10.1002/ajpa.1330300214.

Pilloud, Marin A., and Al W. Schwitalla
2020 Re-evaluating Traditional Markers of Stress in an Archaeological Sample from Central California. *Journal of Archaeological Science* 116:105102. DOI:10.1016/j.jas.2020.105102.

Prevedorou, Eleni-Anna, and Jane E. Buikstra
2019 Bioarchaeological Practice and the Curation of Human Skeletal Remains in a Greek Context: The Phaleron Cemetery. *Advances in Archaeological Practice* 7(1):60–67. DOI:10.1017/aap.2018.42.

Quinn, Colin P., Ian Kujit, and Gabriel Cooney
2014 Introduction: Contextualizing Cremations. In *Transformation by Fire: The*

Archaeology of Cremation in Cultural Context, edited by Ian Kujit, Colin P. Quinn, and Gabriel Cooney, pp. 3-21. University of Arizona Press.

Rakin-Hill, Lesley M.
2016 Identifying the First African Baptist Church: Searching for Historically Invisible People. In *New Directions of Biocultural Anthropology,* edited by Molly K. Zuckerman and Debra L. Martin, pp. 133-156. John Wiley and Sons, New York.

Reinhard, Karl J., and T. Michael Fink
1994 Cremation in Southwestern North America: Aspects of Taphonomy that Affect Pathological Analysis. *Journal of Archaeological Science* 21(5):597–605. DOI:10.1006/jasc.1994.1059.

Resnick, Donald, and Gen Niwayama
1978 Intravertebral Disk Herniations: Cartilaginous (Schmorl's) Nodes. *Radiology* 126(1):57–65. DOI:10.1148/126.1.57.

Richards, N. F.
1977 Fire Investigation—Destruction of Corpses. *Medicine, Science and the Law* 17(2):79–82. DOI:10.1177/002580247701700202.

Robb, John
2002 Time and Biography: Osteobiography of the Italian Neolithic lifespan. In *Thinking through the Body: Archaeologies of Corporeality*, edited by Yannis Hamilakis, Mark Pluciennik, and Sarah Tarlow, pp. 153-172. Kluwer Academic/Plenum Publishers, New York.

Robb, John, Renzo Bigazzi, Luca Lazzarini, Caterina Scarsini, and Fiorenza Sonego
2001 Social "Status" and Biological "Status": A Comparison of Grave Goods and Skeletal Indicators from Pontecagnano. *American Journal of Physical Anthropology* 115(3):213–222. DOI:10.1002/ajpa.1076.

Roberts, Charlotte A.
2019 Infectious Disease: Introduction, Periostosis, Periostitis, Osteomyelitis,, and Septic Arthritis. In *Ortner's Identification of Pathological Conditions in Human Skeletal Remains (Third Edition)*, edited by Jane E. Buikstra, pp. 285-321. Academic Press, London.

Rothschild, Bruce M., Dawid Surmik, and Filippo Bertozzo
2023 Cranial Phenomena. In *Modern Paleopathology, The Study of Diagnostic Approach to Ancient Diseases, their Pathology and Epidemiology : Let there be light, the light of science and critical thinking*, edited by Bruce M. Rothschild, Dawid Surmik, and Filippo Bertozzo, pp. 563–579. Springer International Publishing, Cham.

Rothschild, Bruce M., Lyman Jellema, and Wayne Lambert
2022 Demographics and Significance of Porotic Hyperostosis as Assessed by Surface Microscopy. *The Anatomical Record* 305(9):2158–2165. DOI:10.1002/ar.24881.

Ruffer, Marc Armand
1921 *Studies in the Palaeopathology of Egypt*. University of Chicago Press, Chicago.

Saab, George, Rethy K. Chhem, and Richard N. Bohay
2008 Paleoradiographic Techniques. In *Paleoradiology: Imaging Mummies and Fossils*, edited by Rethy Chhem and Don Brothwell, pp. 15–54. Springer, Heidelberg.

Salo, Kati, Jarkko Saipio, Maddie Hentunen, Kristiina Mannermaa, and Markku Oinonen
2022 Graves, Landmarks, or Sacrificial Monuments? The Human Osteology and Paleopathology of the Bronze Age Burial Cairns in Finland. *International Journal of Osteoarchaeology* 32(5):1073–1081. DOI:10.1002/oa.3133.

Scheelen-Novacek, Kristina, Jan Novacek, Bernd Rasink, Andreas Niemuth, Friedrich-Wilhelm Wulf, and Michael Schultz
2020 Probable Vestiges of Metabolic Diseases in Roman Imperial Cremations from Northern Germany. *Anthropologischer Anzeiger* 78. DOI:10.1127/anthranz/2020/1261.

Schiffer, Michael B.
1983 Toward the Identification of Formation Processes. *American Antiquity* 48(4):675–706. DOI:10.2307/279771.

Shipman, Pat, Giraud Foster and Margaret Schoeninger
1984 Burnt Bones and Teeth: An Experimental Study of Color, Morphology, Crystal Structure and Shrinkage. *Journal of Archaeological Science* 11:307-325.

Soafer Derevenski, Joanna R.

2000 Sex Differences in Activity-Related Osseous Change in the Spine and the Gendered Division of Labor at Ensay and Wharram Percy, UK. *American Journal of Biological Anthropology* 111(3): 333-354. DOI: 10.1002/(SICI)1096-8644(200003).

Soafer, Joanna R.
2006 *The Body as Material Culture: A Theoretical Osteoarchaeology.* Cambridge University Press, Cambridge.

Sonek, A.
1992 The Weight(s) of Cremated Remains. *Proceedings of the 44th Annual Meeting of the American Academy of Forensic Sciences*, pp. 17-22 New Orleans.

Steele, D. Gentry, and Claud A. Bramblett
1988 *The Anatomy and Biology of the Human Skeleton*. Texas A&M University Press, College Station.

Steward, T.D.
1979 *Essentials of Forensic Anthropology: Especially as Developed in the United States*. Charles C. Thomas, Springfield.

Stone, Pamela K. and Adam Netzer Zimmer
2022 Issues of Gender, Identity, and Agency in Paleopathology. In *The Routledge Handbook of Paleopathology*, edited by Anne Grauer, pp. 412-434. Routledge, London.

Stuart-Macadam, Patty
1982 A Correlative Study of a Paleopathology in the Skull. Unpublished PhD. Dissertation, Department of Physical Anthropology, Cambridge University.

1985 Porotic Hyperostosis: Representative of a Childhood Condition. *American Journal of Biological Anthropology* 66: 391-398.

1989 Porotic Hyperostosis: Relationship Between Orbital and Vault Lesions. *American Journal of Biological Anthropology* 80:187-193.

Symes, Steven A., Ericka N. L'abbé, James T. Pokines, Taylor Yuzwa, Diana Messer, Amy Stromquist, And Natalie Keough
2013 Thermal Alteration to Bone. In *Manual of Forensic Taphonomy*, edited by James Pólkines and Steven Symes, pp. 367-403. CRC Press, Boca Raton, Florida

Symes, Steven A., Christopher W. Rainwater, Erin N. Chapman, Desina Rachael Gipson, and Andrea L. Piper
2008 2 - Patterned Thermal Destruction of Human Remains in a Forensic Setting. In *The Analysis of Burned Human Remains*, edited by Christopher W. Schmidt and Steven A. Symes, pp. 15–vi. Academic Press, San Diego.

Thompson, Tim
2004 Recent Advances in the Study of Burned Bone and their Implications for Forensic Anthropology. *Forensic Science International* 114: S203-S205.

2005 Heat-induced Dimensional Changes in Bone and their Consequences for Forensic Anthropology. *Journal of Forensic Sciences* 50(5):JFS2004297-8. DOI:10.1520/JFS2004297.

2015 Fire and the Body: Fire and the People. In *The Archaeology of Cremation: Burned Human Remains in Funerary Studies*, edited by Tim Thompson, pp. 1-19. Oxbow Books, Oxford.

2023 Challenges of Biological Profile Estimations from Burnt Remains. In *Burnt Remains: Recovery, Analysis, and Interpretation (First Edition)*, edited by Sarah Ellingham, Joe Adserias-Garriga, Sara C. Zapico, and Douglas H. Ubelaker, pp. 133-146. John Wiley & Sons Ltd, Chichester, West Sussex, England.

Thompson, Tim J.U., David Gonçalves, Kirsty Squires, and Priscilla Ulguim
2017 Thermal Alteration to the Body. In *Taphonomy of Human Remains: Forensic Analysis of the Dead and the Depositional Environment*, pp. 318–334. John Wiley & Sons, Ltd. Chichester, West Sussex, England.

Thurman, Melburn D. and L. James Willmore
1981 A Replicative Cremation Experiment. *North American Archaeologist* 2(4): 275-283. DOI: 10.2190/29A5-84ED-4MB8-EP3M

Todd, T. Wingate
1920 Age Changes in the Pubic Bone. I. The Male White Pubis. *American Journal of Physical Anthropology* 3(3):285–334. DOI:10.1002/ajpa.1330030301.

Todd, T. Wingate and D. W. Lyon Jr.
1924 Endocranial Suture Closer, Its Progress and Age Relationship. Part I Adult Males of White Stock. *American Journal of Biological Anthropology* 7: 325-384.

1925 Cranial Suture Closer, Its Progress and Age Relationship. Part II. Ectocranial Closure in Adult Males of White Stock. *American Journal of Biological Anthropology* 8-23-45.

Trotter, Mildred and Barbara B. Hixon

1974 Sequential Changes in Weight, Density, and Percentage Ash Weight of Human Skeletons from An Early Fetal Period through Old Age. *Anatomical Record* 179:1-18.

Tung, Tiffany A.

2013 Gender-Based Violence in the Wari and Post-Wari Era of the Andes. In *The Routledge Handbook of the Bioarchaeology of Human Conflict,* edited by Christopher Knüsel and Martin Smith, pp. 333-354. Routledge, New York.

Ubelaker, Douglas H.

1982 The Development of American Paleopathology. In *A History of American Physical Anthropology*, edited by Frank Spencer, pp. 337-356. Academic Press.

1989 *Human Skeletal Remains*. 2nd ed. Taraxacum Press, Washington, D.C.

1999 *Human Skeletal Remains: Excavation, Analysis, Interpretation*. 3rd ed. Manuals on Archeology, vol 2. Taraxacum, Washington D.C.

Ubelaker, Douglas H. and Austin H. Shamlou

2023 History of the Study of Burned Remains. In *Burnt Remains: Recovery, Analysis, and Interpretation (First Edition)*, edited by Sarah Ellingham, Joe Adserias-Garriga, Sara C. Zapico, and Douglas H. Ubelaker, pp. 1-10. John Wiley & Sons Ltd, Chichester, West Sussex, England.

Üstündağ, H.

2009 Schmorl's nodes in a post-medieval skeletal sample from Klostermarienberg, Austria. *International Journal of Osteoarchaeology* 19(6):695–710. DOI:10.1002/oa.993.

Van Vark, G.N.

1970 Some Statistical Procedures for the Investigation of Prehistoric Skeletal Material. Master's thesis, Gröningen, Netherlands.

1974 The Investigation of Human Cremated Skeletal Material by Multivariate Statistical Methods I. Methodology. *International Journal of Skeletal Research* 1:63-95.

1975 The Investigation of Human Cremated Skeletal Material by Multivariate Statistical Methods I. Methodology. *International Journal of Skeletal Research* 2:47-68.

Veselka, Barbara, Giacomo Capuzzo, Rica Annaert, Nadine Mattielli, Mathieu Boudin, Sarah Dalle, Marta Hlad, Charlotte Sabaux, Kevin Salesse, Amanda Sengeløv, Elisavet Stamataki, Dries Tys, Martine Vercauteren, Eugène Warmenbol, Guy De Mulder, and Christopher Snoeck
2021 Divergence, Diet, and Disease: The Identification of Group Identity, Landscape Use, Health, and Mobility in the Fifth- to Sixth Century AD Burial Community of Echt, the Netherlands. *Archaeological and Anthropological Science* 13(97):1-14.

Wagner, Andrew L., F. Reed Murtagh, John A. Arrington, and Dexter Stallworth
2000 Relationship of Schmorl's Nodes to Vertebral Body Endplate Fractures and Acute Endplate Disk Extrusions. *American Journal of Neuroradiology* 21(2):276–281.

Waldron, Tony
2019 Joint Disease. In *Ortner's Identification of Pathological Conditions in Human Skeletal Remains (Third Edition)*, edited by Jane E. Buikstra, pp. 719-745. Academic Press, London.

Walker, Philip L.
2005 Greater Sciatic Notch Morphology: Sex, Age, and Population Differences. *American Journal of Biological Anthropology* 127(4): 385-391. DOI: 10.1002/ajpa.10422.

2008 Sexing Skulls Using Discriminate Function Analysis of Visually Accessed Traits. *American Journal of Biological Anthropology* 136(1): 39-50. DOI: 10.1002/ajpa.20776.

Walker, Phillip L., Kevin W. P. Miller, And Rebecca Richman
2008 7 - Time, Temperature, and Oxygen Availability: An Experimental Study of the Effects of Environmental Conditions on the Color and Organic Content of Cremated Bone. In *The Analysis of Burned Human Remains*, edited by Christopher W. Schmidt and Steven A. Symes, pp. 129–137. Academic Press, San Diego.

Walker, Meg M., Marc F. Oxenham, Thi Mai Huong Nguyen, Hiep Hoang Trinh, Tran Thi Minh, Lan Cuong Nguyen, Hirofumi Matsumura, and Justyna J. Miszkiewicz

2023 Primary Bone Retention in a Young Adult Male with Limb Disuse: a Bioarchaeological Case Study. *Historical Biology* 35(2):235–241. DOI:10.1080/08912963.2022.2032027.

White, Tim D., Michael T. Black, and Pieter A. Folkens
2012 Human Osteology. 3rd ed. Academic Press, San Diego.

Williams, Howard
2008 Towards an Archaeology of Cremation. In *The Analysis of Burned Human Remains*, edited by Christopher W. Schmidt and Steven A. Symes, pp. pp. 239-269. Academic Press, San Diego.

2015 Chapter 15 - Towards an Archaeology of Cremation. In *The Analysis of Burned Human Remains (Second Edition)*, edited by Christopher W. Schmidt and Steven A. Symes, pp. 259–293. Academic Press, San Diego.

Wilczak, Cynthia A.
2011 Chapter 6: Porosity and Channel Formation. In *OsteowareTM Software Manual 2*, edited by Cynthia A. Wilczak and Erica B. Jones, pp. 55-60. Smithsonian Institute, Washington D.C.

Wilczak, Cynthia A. and Marylin R. London
2011 Chapter 8: Vertebral Anomalies. In *OsteowareTM Software Manual 2*, edited by Cynthia A. Wilczak and Erica B. Jones, pp. 69-75. Smithsonian Institute, Washington D.C.

Williams, Amanda N.
2023 Methods for Analyzing Burnt Human Remains. In *Burnt Remains: Recovery, Analysis, and Interpretation (First Edition)*, edited by Sarah Ellingham, Joe Adserias-Garriga, Sara C. Zapico, and Douglas H. Ubelaker, pp. 75-98. John Wiley & Sons Ltd, Chichester, West Sussex, England.

Williams, Howard, Jessica I. Cerezo-Román, Anna Wessman
2017 *Cremation and the Archaeology of Death*. Oxford University Press, Oxford.

Williams, Howard, and Anna Wessman

2017 The Contemporary Archaeology of Urban Cremations. In *Cremation and the Archaeology of Death*, edited by Jessica I. Cerezo-Román, Anna Wessman, and Howard Williams, pp. 266-296. Oxford University Press, Oxford.

Wood, James W., George R. Milner, Henry C. Harpending, Kenneth M. Weiss, Mark N. Cohen, Leslie E. Eisenberg, Dale L. Hutchinson, Rimantas Jankauskas, Gintautas Cesnys, Gintautas Česnys, M. Anne Katzenberg, John R. Lukacs, Janet W. McGrath, Eric Abella Roth, Douglas H. Ubelaker, and Richard G. Wilkinson

1992 The Osteological Paradox: Problems of Inferring Prehistoric Health from Skeletal Samples [and Comments and Reply]. *Current Anthropology* 33(4):343–370.

Appendix A: Skeletal Recording Forms

Form 1

BIOARCHAEOLOGY LABORATORY OU
HUMAN REMAINS DOCUMENTATION PACKET

PROVENIENCE

Site Name:_____ **Site No.:**_____

Designation/ID:_____

_____

Observer(s):_____ **Date:**_____

BIOLOGICAL PROFILE

MNI: _____

Age: _____

Sex: _____

Ancestry:_____

FORM LIST (indicate forms used)

- ☐ **3 Skeletal Inventory**
- ☐ **4 Age and Sex Assessment - Adult**
- ☐ **38 Age Assessment - Juvenile**
- ☐ **7 Permanent Dental Inventory/Pathology**
- ☐ **40 Deciduous Dental Inventory/Pathology**
- ☐ **8 Dental Morphology - Permanent**
- ☐ **41 Dental Morphology - Deciduous**
- ☐ **9 Measurements - Adult**
- ☐ **39 Measurements - Juvenile**
- ☐ **10 Non-Metric Traits**
- ☐ **15 Pathology Checklist**
- ☐ **16 Degenerative Joint Disease**
- ☐ **17 Spinal Osteophytosis**
- ☐ **47 Artificial Cranial Modification**
- ☐ **50 Cremated Remains**
- ☐ **49 Isolated Remains**
- ☐ **Skeletal Visual Recording Forms**
- ☐ **Additional Forms, Notes, Sketches, Photo Log, etc.**

PRESERVATION

- ☐ **Complete skeleton** (>75%)
- ☐ **Partial skeleton** (25-75% present)
- ☐ **Fragmentary skeleton** (<25% present, includes at least one complete element)
- ☐ **Fragments of bone** (small amount of fragmented bone; <<25% is present)
- ☐ **Skull** (only cranial remains present and partially preserved)
- ☐ **Teeth** (only loose teeth are present)
- ☐ **Cremated bone** (burned remains of any quantity; excludes cases of incidental charring of otherwise unburned skeleton)
- ☐ **Soft tissues present**

Describe:_____

_____

_____

_____

CONDITION

Yes	No	Unobservable	
☐	☐	☐	**Cracking**
☐	☐	☐	**Breaks**
☐	☐	☐	**Brittle**
☐	☐	☐	**Exfoliation**
☐	☐	☐	**Warping**
☐	☐	☐	**Cut marks**
☐	☐	☐	**Gnaw marks**
☐	☐	☐	**Root or insect damage**
☐	☐	☐	**Staining**
☐	☐	☐	**Soil adhering**

Describe (include severity & elements affected):

_____

_____

_____

_____

_____

02/2020

Taphonomy Data Provenience _____Numeric/Case I.D. _____ Form _____ Form 2

(Mark X if present and – if unobservable)

Stages of Decomposition
1. Fresh, fully fleshed
1.1.Fresh, no discoloration or insect activity
2. Decomposed
2.1.Early Decomposition
2.1.1.Pink-white appearance with skin slippage and some hair loss
2.1.2.Gray to green discoloration some flesh relatively flesh
2.1.3.Discoloration to brownish shades particularly at fingers, nose, and ears: some flesh still relatively fresh
2.1.4.Bloating with green discoloration
2.1.5.Post bloating following rupture of the abdominal gases with discoloration going from green to dark
2.1.6.Brown to black discoloration of arms and legs, skin has leathery appearance
2.2.Advanced decomposition
2.2.1.Decomposition of tissue producing sagging flesh, caving in of the abdominal cavity, often accompanied by extensive maggot activity
3. **Decomposed with focal skeletonization**
3.1.Moist decomposition in which there is bone exposure
4. Skeletonization with soft tissue mummification
4.1.Mummification with retention of internal structure
4.2. Mummification of outer tissues only with internal organs lost through autolysis or insect activity
5. Skeletonization with articulation/ligamentous attachment
5.1.Mummification with bone exposure of less than one half the skeleton
6. Complete skeletonization with disarticulation
6.1.Skeletonization
6.1.1.Bone with greasy substances and decomposed tissue, sometimes body fluids still present
6.1.2.Bones with desiccated tissue or mummified tissue covering less than one half the skeleton
6.1.3.Bones largely dry but still retaining some grease
6.1.4.Dry bone
7. Complete skeletonization with disarticulation and bone degradation
7.1.Extreme decomposition
7.1.1.Skeletonization with bleaching
7.1.2. Skeletonization with exfoliation
7.1.3.Skeletonization with metaphyseal loss with long bones and cancellous exposure of the vertebrae
8. Other (i.e. burnt, cremains, adipocere, etc)

Bone Color
1. White
2. Grey
3. Natural/Ivory
4. Yellow through brown
5. Yellow to tan (all)
6. Tan to dark brown (all)
7. Black

Adherent Materials
1. Desiccated brain
2. Insect debris/pupa
3. Lichens
4. Roots/rootlets
5. Soil
6. Textile/impression
8. Adipocere
9. Odor

***Postmortem* Cultural Modification**		
1. Cut mark		
2. Intentional fracture		
3. PM drilling/cutting/etc.		
Articulations (A=attached, N=nonattached)		
1. Cranial-atlas		
2. Atlas-axis		
3. Cranium-mandible		
4. Cervical		
5. Thoracic		
6. Lumbars		
7. Sacrum-ilium	L	R
8. Ilium-femur	L	R
9. Scapula grid	L	R
10. Clavicle-sternum	L	R
11. Clavicle-scapula	L	R
12. Ribs end-sternum	L	R
13. Elbow (humerus, radius & ulna)	L	R
14. Wrists (radius, ulna & carpals)	L	R
15. Hand	L	R
16. Knee (femur, patella, tibia & fibula)	L	R
17. Ankle (tibia, fibula & tarsals)		
18. Tarsal		

Staining
1. Green (copper)
2. Green (algae)
3. Red (ocher, cinnabar, vermillion)
4. Iron/ferrous metal
5. Black
6. Soil
7. Roots/plants
8. Mottled pattern
9. Other staining

Surface Damage
1. Sun bleaching
2. Plant root damage
3. Rodent tooth marks
4. Carnivore tooth marks
5. Unidentified animal damage
6. Insect damage
7. Scratches/abrasions
8. Warping due to ground pressure
9. Contact erosion (e.g., coffin wear)
10. Burning
11. With surface exposure
12. Without surface exposure
13. Vulture damage
14. Horizontal cracks

Comments

SKELETAL INVENTORY
RECORDING FORM (3)

Codes:
f = 1-25% present
p = 25-75% present
c = 75-100% present

Provenience: _____

Designation/ID: _____

CRANIAL	left	right
Frontal		
Parietal		
Occipital		
Temporal		
TMJ		
Mandible		
Zygomatic		
Maxilla		
Nasal		
Lacrimal		
I. N. C.		
Palatine		
Sphenoid		
Ethmoid		
Vomer		
Hyoid		
Thyroid/Crycoid		
Ossicles		
Unident. Cranial		

teeth	#	cond
Incisors		
Canines		
Premolars		
Molars		
Unidentified Teeth		

AXIAL	#	cond
1st Cervical		
2nd Cervical		
3-6 Cervical		
7th Cervical		
1-9 Thoracic		
10th Thoracic		
11th Thoracic		
12th Thoracic		
1-4 Lumbar		
5th Lumbar		
Sacrum		
Coccyx		

Manubrium	
Sternal Body	
xiphoid	
Left Ribs	
Right Ribs	
Unidentified Axial	

APPEND.	left	right
Scapula		
glenoid		
Clavicle		
med. epi.		
Ilium		
auricular		
Pubis		
symphysis		
Ischium		
acetabulum		
Patella		
Unidentified Append.		

APPENDICULAR	left					right				
	epi-p	/prox	/mid	/dist	/epi-d	epi-p	/prox	/mid	/dist	/epi-d
Humerus										
Radius										
Ulna										
Femur										
Tibia										
Fibula										

Unidentified Long Bones _____

Notes:

EXTREMITIES	#	cond		#	cond
Scaphoid			Calcaneus		
Lunate			Talus		
Trapezium			Cuboid		
Trapezoid			Navicular		
Capitate			Med. Cuneiform		
Hamate			Inter. Cuneiform		
Triquetral			Lat. Cuneiform		
Pisiform			Metatarsals		
Metacarpals			Prox. Phalanges		
Prox. Phalanges			Mid. Phalanges		
Mid. Phalanges			Dist. Phalanges		
Dist. Phalanges			Sesamoids		
Sesamoids			***Unident. Extremities***		

†This form includes information derived from Arizona State Museum (ASM; Arizona State Museum 2018) and Buikstra and Ubelaker (1994), *Standards for Data Collection from Human Skeletal Remains,* Arkansas Archeological Survey, and is used with permission of the publisher.

Provenience _____ Numeric I.D. _____ Form 4

ADULT AGE/SEX RECORDING FORM

Age Criteria

Pubic Symphysis	Left	Right	**Auricular Surface**	Left	Right
Todd (1-10)	____	____	(1-8)	____	____
Suchey-Brooks (1-6)	____	____			

Suture Closure & Epiphyseal Union: blank = unobservable, 0 = open, 1 = minimal, 2 = significant, 3 = complete

External Cranial Vault	1. Midlambdoid	____	**Palatine**	11. Incisive Suture		____
	2. Lambda	____		12. Anterior Median Palatine		____
	3. Obelion	____		13. Posterior Median Palatine		____
	4. Anterior Sagittal	____		14. Transverse Palatine		____
	5. Bregma	____	**Internal Cranial Vault**	15. Sagittal		____
	6. Midcoronal	____		16. Left Lambdoid		____
	7. Pterion	____		17. Left Coronal		____
	8. Sphenofrontal	____				
	9. Inferior Sphenotemporal	____	**Vertebral Annular Epiphyses**	Cervical	superior	____
	10. Superior Sphenotemporal	____			inferior	____
				Thoracic	superior	____
Clavicle	Sternal epiphysis	____			inferior	____
Sacrum	S1/S2 fusion	____		Lumbar	superior	____
Innominate	Iliac crest	____			inferior	____
Sternal end of 4th rib		____				

Estimated Age: Subadult (12-18 years) ____
Young Adult (18-35 years) ____
Middle Adult (35-50 years) ____
Old Adult (50+ years) ____

Comments:

Sex

Pelvis	Left	Right	**Skull**	
Ventral Arc (1-5)	____	____	Nuchal Crest (1-5)	____
Subpubic Concavity (1-5)	____	____	Mastoid Process (1-5)	____
Ischiopubic Ramus Ridge (1-5)	____	____	Supraorbital Margin (1-5)	____
			Glabella (1-5)	____
Greater Sciatic Notch (1-5)	____	____	Mental Eminence (1-5)	____
Preauricular Sulcus (0-4)	____	____		

Estimated Sex, Pelvis (1-5) _____ = ____ Estimated Sex, Skull (1-5) _____ = ____

Comments:

This form includes information derived from Arizona State Museum (ASM; Arizona State Museum 2018) and Buikstra and Ubelaker (1994), *Standards for Data Collection from Human Skeletal Remains*, Arkansas Archeological Survey, and Bioarchaeology Laboratory, Arizona State Musuem. Klales AR, Ousley SD, and Vollner JM. 2012. A revised method of sexing the human innominate using Phenice's nonmetric traits and statistical methods. American Journal of Physical Anthropology 149:104–114.

Form 5

COLLECTION ID CASE #:_____ **ID NAME:**_____

CURATOR/ADDRESS: _____ **RECORDER:**_____**DATE:**_____

---------- PUBIC SYMPHYSIS ----------

	LEFT	RIGHT
1. SYMPHYSEAL RELIEF	_____	_____
2. DORSAL SYMPHYSEAL TEXTURE	_____	_____
3. SUPERIOR PROTUBERANCE	_____	_____
4. VENTRAL SYMPHYSEAL MARGIN	_____	_____
5. DORSAL SYMPHYSEAL MARGIN	_____	_____

---------- SACROILIAC JOINT ----------

	LEFT	RIGHT
1. SUPERIOR DEMIFACE TOPOGRAPHY	_____	_____
2. INFERIOR DEMIFACE TOPOGRAPHY	_____	_____
3. SUPERIOR SURFACE CHARACTERISTICS	_____	_____
4. MIDDLE SURFACE CHARACTERISTICS	_____	_____
5. INFERIOR SURFACE CHARACTERISTICS	_____	_____
6. INFERIOR SURFACE TEXTURE	_____	_____
7. SUPERIOR POSTERIOR ILIAC EXOSTOSES	_____	_____
8. INFERIOR POSTERIOR ILIAC EXOSTOSES	_____	_____
9. POSTERIOR EXOSTOSES	_____	_____

---------- CRANIAL SUTURES ----------

	LEFT		RIGHT
1. CORONAL PTERICA	_____		_____
2. SAGITTAL OBELICA		_____	
3. LAMBDOIDAL ASTERICA	_____		_____
4. ZYGOMATICOMAXILLARY	_____		_____
5. INTERPALALATINE		_____	

The codes for this forms can be found in:
Langley, Natalie R., Lee Meadows Jantz, Stephen D. Ousley, Richard L. Jantz and George Milner
2016 Data Collection Procedures for Forensic Skeletal Material 2.0. Forensic Anthropology Center, Department of Anthropology, The University of Tennessee, Knoxville, Tennessee. This forms comes from this book.

SKELETAL MEASUREMENT

ADULT - RECORDING FORM (9)

Record all measurements millimeters.

Provenience: _____

Designation/ID: _____

CRANIAL

1. **GOL** Maximum Cranial Length _____
2. **XCB** Maximum Cranial Breadth _____
3. **ZYB** Bizygomatic Breadth _____
4. **BBH** Basion-Bregma Height _____
5. **BNL** Basion-Nasion Length _____
6. **BPL** Basion-Prosthion Length _____
7. **MAB** Maxillo-Alveolar Breadth _____
8. **MAL** Maxillo-Alveolar Length _____
9. **AUB** Biauricular Breadth _____
10. **UFHT** Upper Facial Height _____
11. **WFB** Minimum Frontal Breadth _____
12. **UFBR** Upper Facial Breadth _____
13. **ASB** Biasterionic Breadth _____
14. **ZMB** Zygomaillary Br _____
15. **NLH** Nasal height _____
16. **NLB** Nasal Breadth _____
17. **OBB** Orbital Breadth _____
18. **OBH** Orbital Height _____
19. **EKB** Biorbital Breadth _____
18. **DKB** Interorbital Breadth _____
19. **FRC** Frontal Chord _____
20. **PAC** Parietal Chord _____
21. **OCC** Occipital Chord _____
22. **FOL** Foramen Magnum Length _____
23. **FOB** Foramen Magnum Breadth _____
24. **MDH** Mastoid Length _____
25. **MOW** Midorbital Width _____
26. **GNI** Chin height _____
27. **HMF** Ht at Mental Foramen _____
28. **TMF** Br at Mental Foramen _____
29. **GOG** Bigonial Width _____
30. **CDL** Bicondylar Breadth _____
31. **WRB** Minimum Ramus Breadth _____
32. **MLR** Maximum Ramus Breadth _____
33. **MLN** Mandibular Length _____
34. **XRH** Maximum Ramus Height _____
35. **MAN** Mandibular Angle _____
36. **HML** Mandibular Body Height _____
37. **TML** Mandibular Body Breadth _____

POSTCRANIAL

	left	right
38. **Clavicle**: **CLAXLN** Max. Length		
39. **CLAAPD** A-P Diam. Midshaft		
40. **CLAVRD** Sup.-Inf. Diam. Midshaft		
41. **Scapula**: **SCAPHT** Height		
42. **SCAPBR** Breadth		
43. **Humerus**: **HUMXLN** Max. Length		
44. **HUMEBR** Epicondylar Breadth		
45. **HUMHDD** Vertical Diam. Head		
46. **HUMMXD** Max. Diam. Midshaft		
47. **HUMMWD** Min. Diam. Midshaft		
48. **Radius**: **RADXLN** Max. Length		
49. **RADAPD** Ant.-Post. Diam. Midshaft		
50. **RADTVD** Med.-Lat. Diam. Midshaft		
51. **Ulna**: **ULNXLN** Max. Length		
52. **ULNDVD** A-P Diameter		
53. **ULNTVD** M-L Diameter		
54. **ULNPHIL** Physiological Length		
55. **ULNCIR** Min. Circumference		
56. **Sacrum**: **SACAHT** Anterior Length		
57. **SACABR** Anterior Superior Breadth		
58. **SACS1B** Max. Trans. Diam. Base		
59. **Pelvis**: **INNOHT** Height		
60. **ILIABR** Iliac Breadth		
61. **PUBCLN** Pubis Length		
62. **ISCHLN** Ischium Length		

	left	right
63. **Femur**: **FEMXLN** Max. Length		
64. **FEMBLN** Bicondylar Length		
65. **FEMEBR** Epicondylar Breadth		
66. **FEMHDD** Max. Diam. Head		
67. **FEMSAP** A-P Subtroch. Diam.		
68. **FEMSTV** M-L Subtroch. Diam.		
69. **FEMMAP** A-P Midshaft Diam.		
70. **FEMMTV** M-L Midshaft Diam.		
71. **FEMCIR** Midshaft Circumference		
72. **Tibia**: **TIBXLN** Max. Length		
73. **TIBPEB** Max. Prox. Epiph. Breadth		
74. **TIBDEB** Max. Distal Epiph. Breadth		
75. **TIBNFX** Max. Diam. Nutrient For.		
76. **TIBNFT** M-L Diam. Nutrient For.		
77. **TIBCIR** Circ. Nutrient Foramen		
78. **Fibula**: **FIBXLN** Max. Length		
79. **FIBMDM** Max. Diameter Midshaft		
80. **Calcaneus**: **CALCXL** Max. Length		
81. **CALCBR** Middle Breadth		
82. **Sternum**: Length Mesostern.		
83. Max. Breadth 1st		
84. Radial Head Diameter		

PATHOLOGY

CHECKLIST RECORDING

FORM (15)

Provenience: _____

Designation/ID: _____

CRANIAL	present	absent	unobs.
Porotic hyperostosis	____	____	____
Cribra orbitalia	____	____	____
Premature synostosis	____	____	____
Osteomas	____	____	____
Periosteal reactions	____	____	____
Lytic reactions	____	____	____
Proliferative reactions	____	____	____
Trauma	____	____	____
Cultural modifications	____	____	____

AXIAL	present	absent	unobs.
Ankylosis	____	____	____
Arch defects	____	____	____
Compression fractures	____	____	____
Schmorl's nodes	____	____	____
Periosteal reactions	____	____	____
Lytic reactions	____	____	____
Osteoporosis	____	____	____
Trauma	____	____	____
Reaction on pleural aspect of ribs	____	____	____
Accessory facets	____	____	____

APPENDICULAR	present	absent	unobs.
Periosteal reaction	____	____	____
Lytic reactions	____	____	____
Proliferative reactions	____	____	____
Osteoporosis	____	____	____
Trauma	____	____	____
Cultural modifications	____	____	____
Osteomyelitis	____	____	____
Exostoses	____	____	____
Accessory facets	____	____	____

EXTREMITIES	present	absent	unobs.
Lytic reactions	____	____	____
Proliferative reactions	____	____	____
Periosteal reactions	____	____	____
Trauma	____	____	____
Exostoses	____	____	____
Accessory facets	____	____	____

Observations (describe pathology in detail and use individual element visual recording forms to illustrate morphology and extent):

†This form includes information derived from Buikstra and Ubelaker (1994), *Standards for Data Collection from Human Skeletal Remains,* Arkansas Archeological Survey, and is used with permission of the publisher.

Provenience _____ Numeric I.D. _____ Form 16

DEGENERATIVE JOINT DISEASE

SKULL

element	left	right
TMJ	____	____
Mand. condyles	____	____
Occip. Condyles	____	____

SHOULDER

Scapula		
glenoid	____	____
acromium	____	____
Clavicle		
medial	____	____
lateral	____	____
Prox. Humerus	____	____

PHALANGES

element	prox.	distal
C. proximal	____	____
C. middle	____	____
C. distal	____	____
T. proximal	____	____
T. middle	____	____
T. distal	____	____

KNEES

element	left	right
Dist. Femur	____	____
Prox. Tibia	____	____
Prox. Fibula	____	____
Patella	____	____

ELBOW

element	left	right
Dist. Humerus	____	____
Prox. Radius	____	____
Prox. Ulna	____	____

WRIST

element	left	right
Dist. Radius	____	____
Dist. Ulna	____	____
Carpals	____	____
Metacarpals	____	____

HIP

element	left	right
Acetabulum	____	____
Femoral head	____	____
Greater troch.	____	____
Lesser troch.	____	____

ANKLES

element	left	right
Dist. Tibia	____	____
Dist. Fibula	____	____
Calcaneus	____	____
Other tarsals	____	____
Metatarsals	____	____
Talus	____	____

Stages of DJD from Ubelaker (1999). a = normal articular surface; b= appearance of small deposits of bone on articular margins; c= small pits; d= polishing/eburnation; e= other (describe below)

NOTES

Provenience _____ Numeric I.D. _____ Form 17

SPINAL OSTEOPHYTOSIS RECORDING FORM

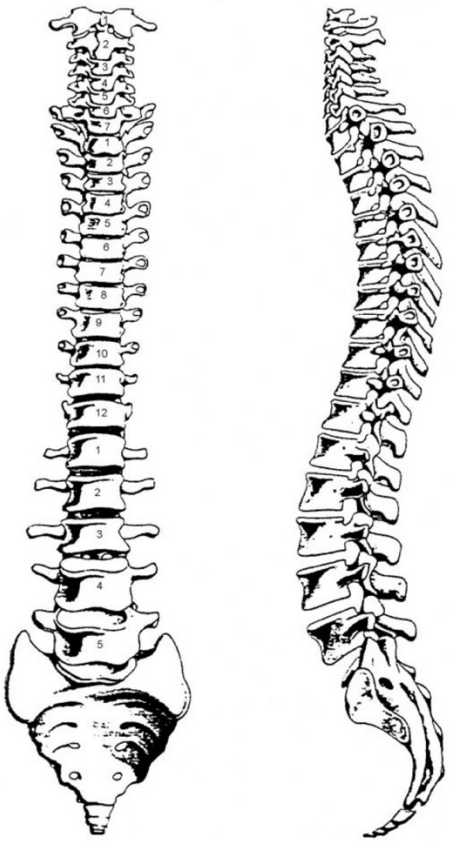

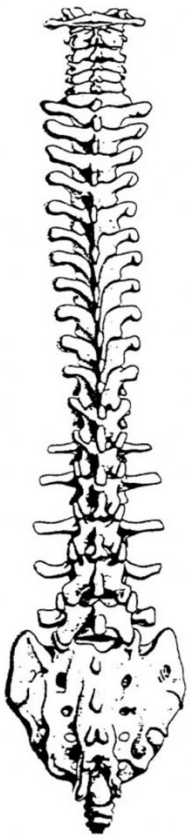

Osteophytosis - stages 0-4 (Ubelaker 1999)

Vertebral Category	Superior Surface	Inferior Surface
Cervical	_____	_____
Thoracic	_____	_____
Lumbar	_____	_____

Extent of Surface Osteophytes - Dudar 2011

Vertebral Category	Superior Surface	Inferior Surface
Cervical	_____	_____
Thoracic	_____	_____
Lumbar	_____	_____

Degenerative Joint Disease (Vertebral Articular Surfaces) – stages a-d (Ubelaker 1999)

Vertebral Category	Superior Surface		Inferior Surface	
	Left	Right	Left	Right
Cervical	____	____	____	____
Thoracic	____	____	____	____
Lumbar	____	____	____	____
Sacral	____	____		

NOTE: If condition varies, bracket & note areas of major differences on graph. Applies to both DJD & osteophytosis.

Form 18

Provenience _____ Numeric I.D. _____

Fill-in skeletal chart when elements can be identified. Label with "U" if unsided, and "A" to denote approximated location. Use key below to shade fragments by color if is a cremation. If not a cremation ignore key and used black for elements present.

Tan (outline fragment)

Black (fill completelty)

Gray-Blue (cross-hatch)

White (hatch)

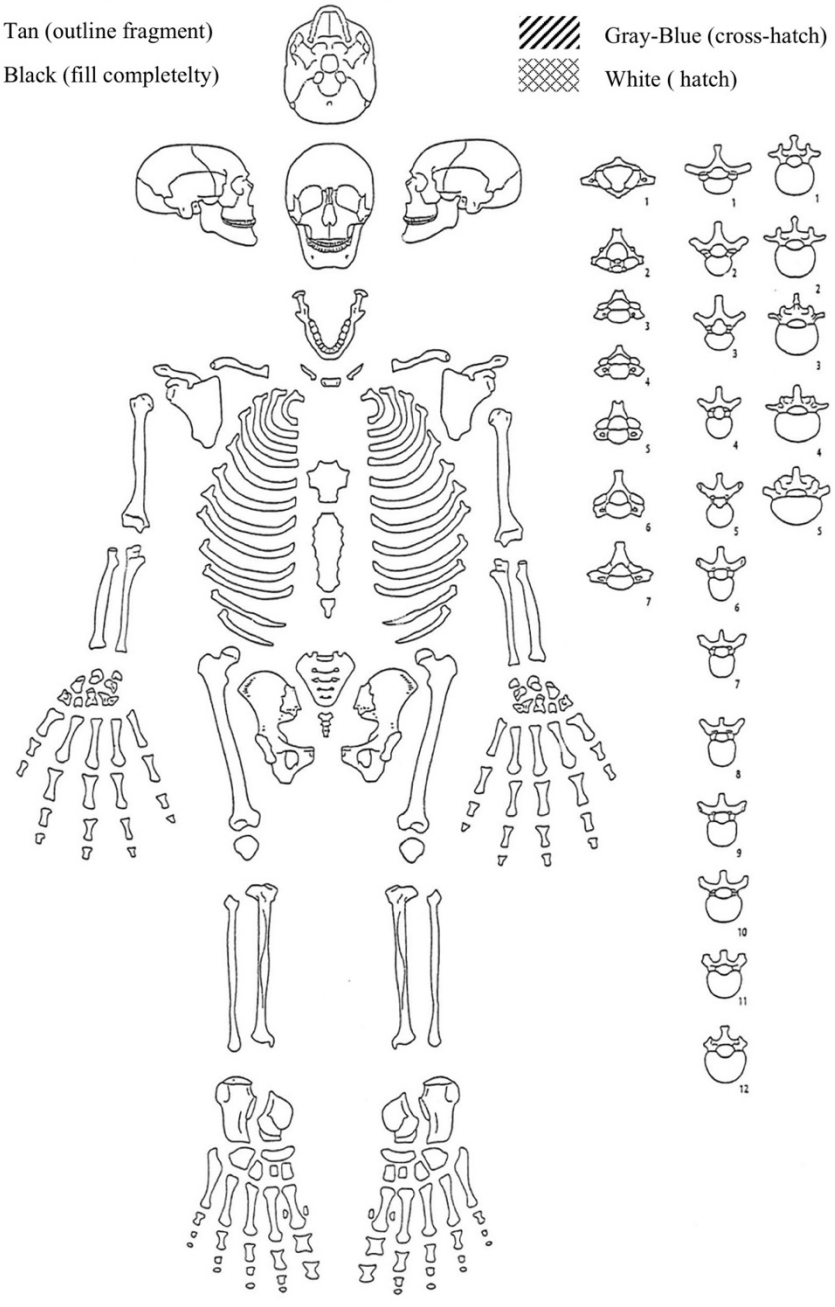

Provenience _____ Numeric I.D. _____ Form 19

ADULT SKELETON

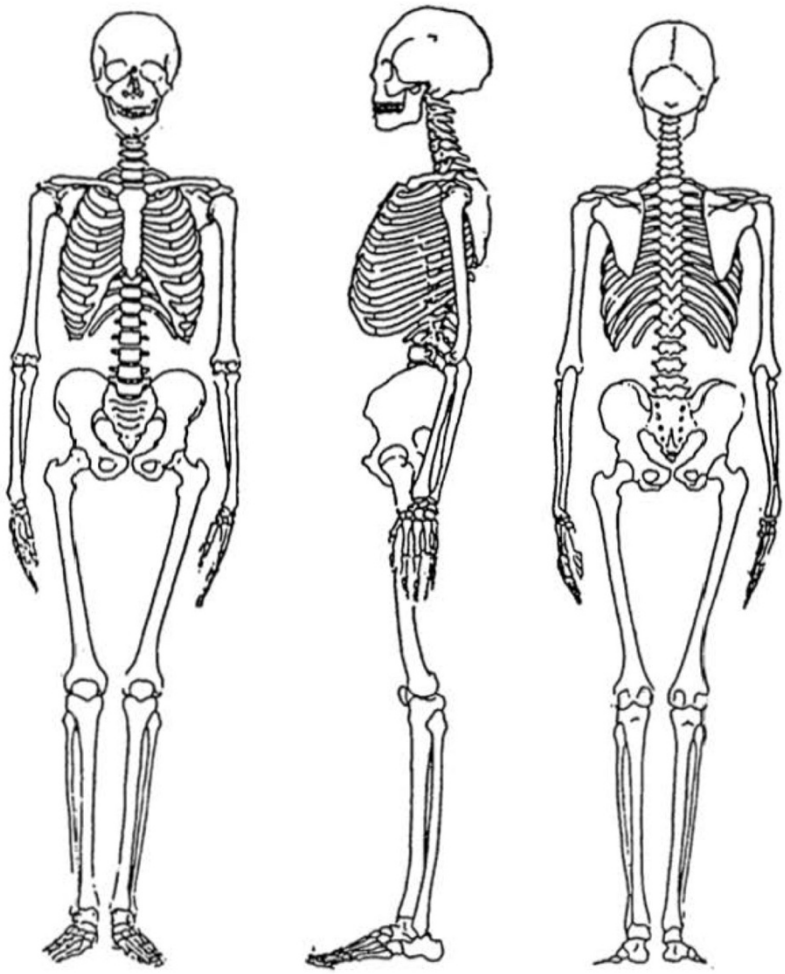

This form includes information derived from Buikstra and Ubelaker (1994), *Standards for Data Collection from Human Skeletal Remains,* Arkansas Archeological Survey, and is used with permission of the publisher.

Provenience _____ Numeric I.D. _____ Form 20

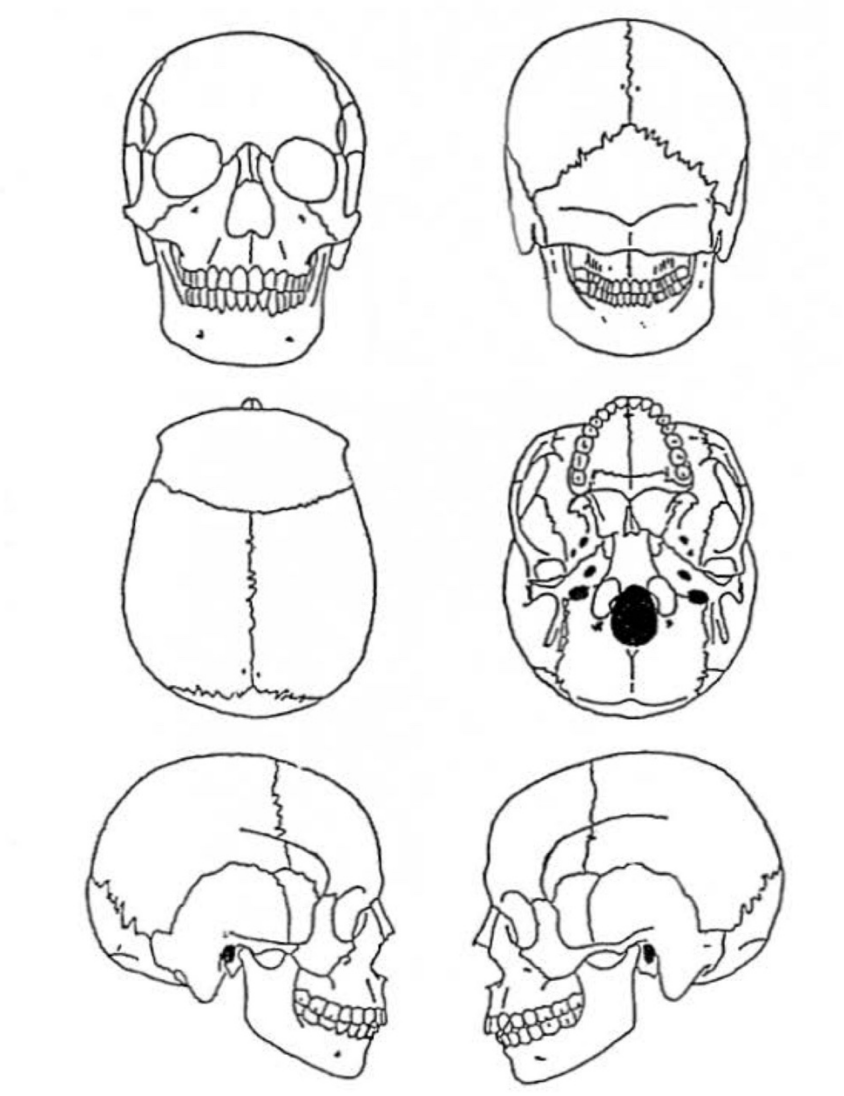

This form includes information derived from Buikstra and Ubelaker (1994), *Standards for Data Collection from Human Skeletal Remains,* Arkansas Archeological Survey, and is used with permission of the publisher.

Provenience _____ Numeric I.D. _____ Form 21

LEFT ILIUM, SCAPULA, CLAVICLE

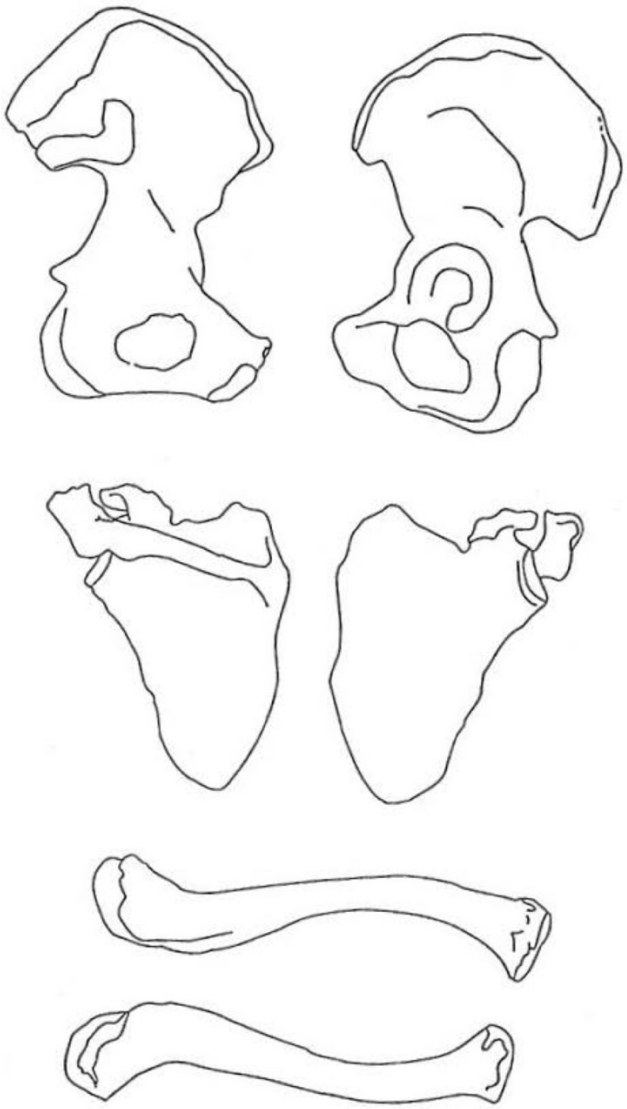

This form includes information derived from Buikstra and Ubelaker (1994), *Standards for Data Collection from Human Skeletal Remains,* Arkansas Archeological Survey, and is used with permission of the publisher.

Provenience _____ Numeric I.D. _____ Form 22

RIGHT ILIUM, SCAPULA, CLAVICLE

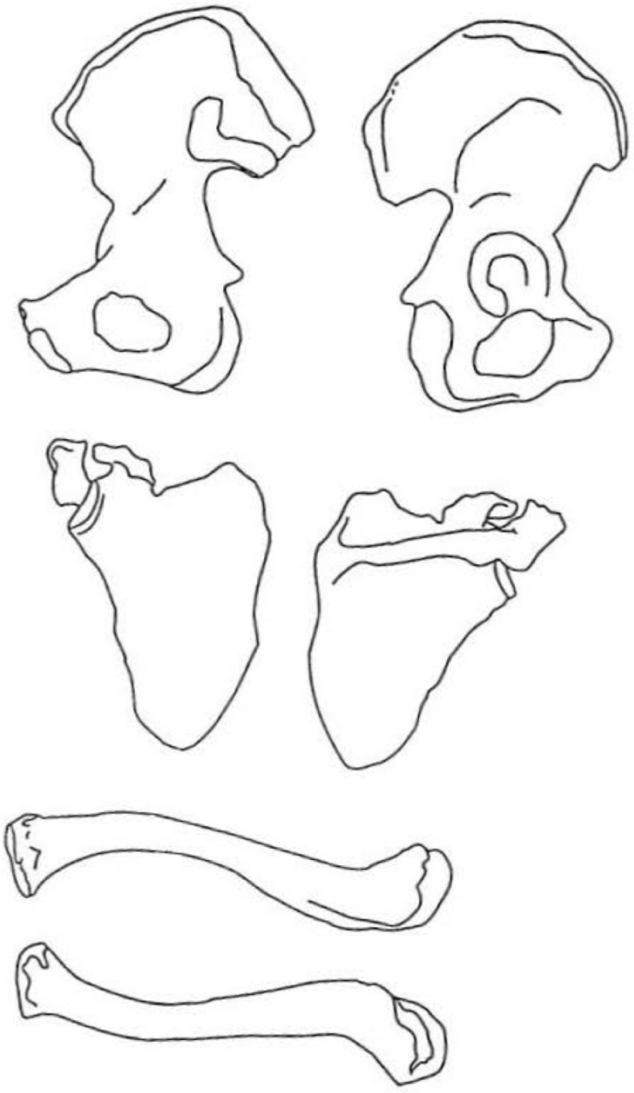

This form includes information derived from Buikstra and Ubelaker (1994), *Standards for Data Collection from Human Skeletal Remains,* Arkansas Archeological Survey, and is used with permission of the publisher.

Provenience _____ Numeric I.D. _____ Form 23

RIGHT HUMERUS

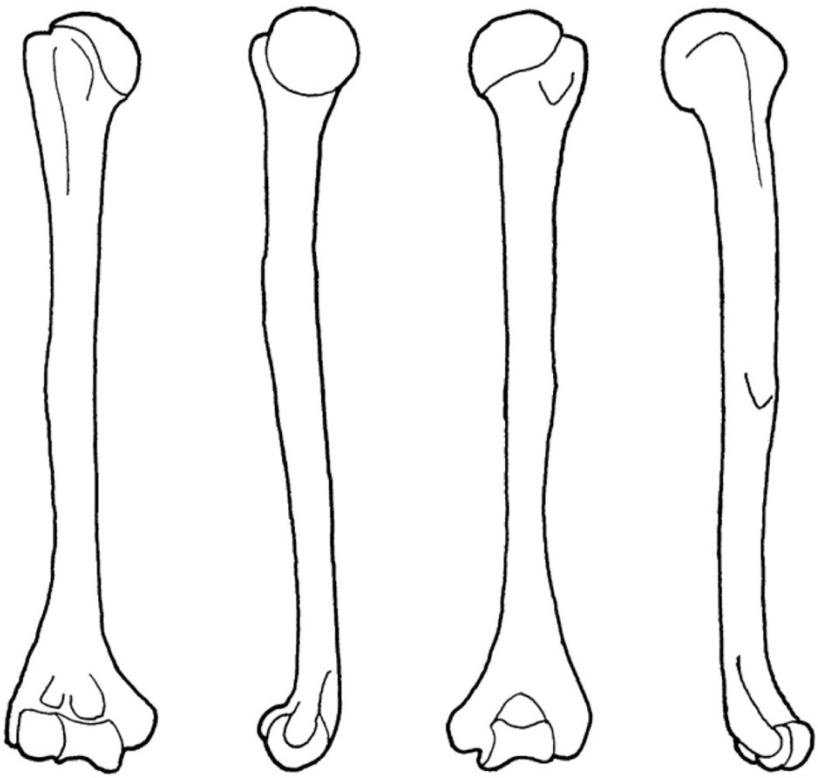

anterior **medial** **posterior** **lateral**

Notes:

Provenience _____ Numeric I.D. _____ Form 24

LEFT HUMERUS

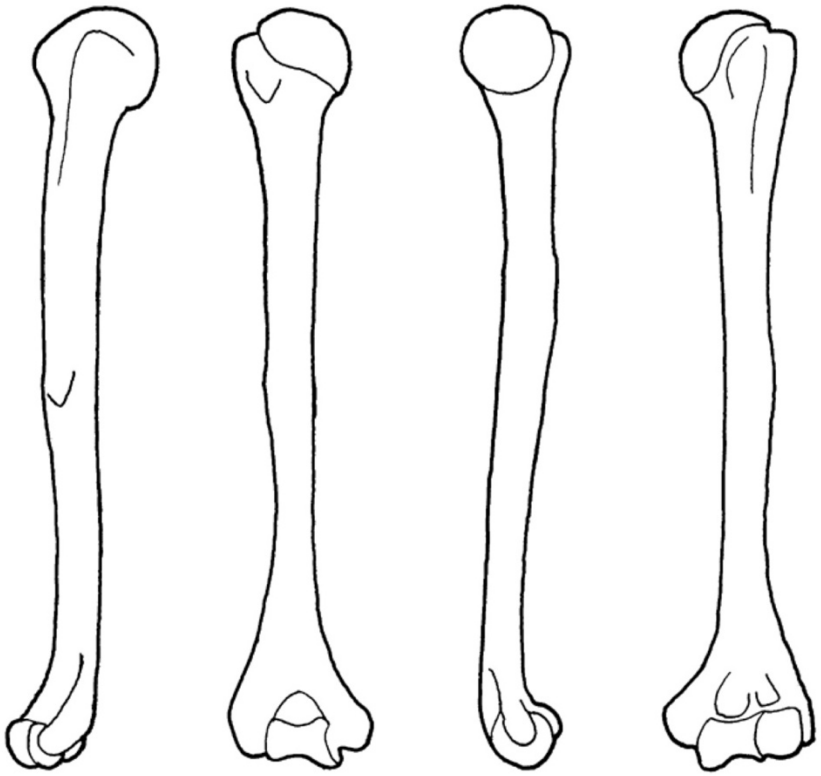

lateral **posterior** **medial** **anterior**

Notes:

Provenience _____ Numeric I.D. _____ Form 25

RIGHT RADIUS

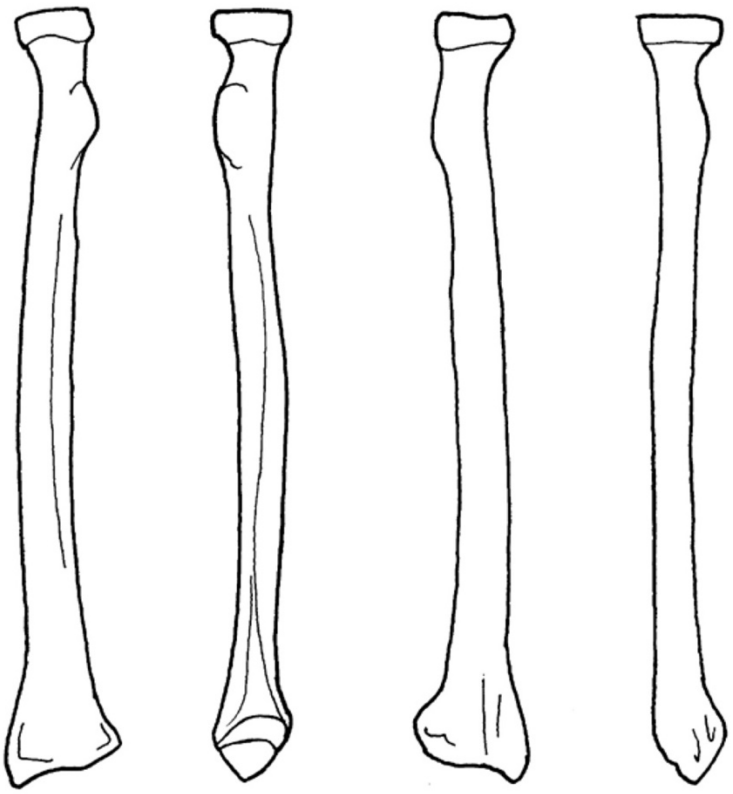

anterior **medial** **posterior** **lateral**

Notes:

Provenience _____ Numeric I.D. _____ Form 26

LEFT RADIUS

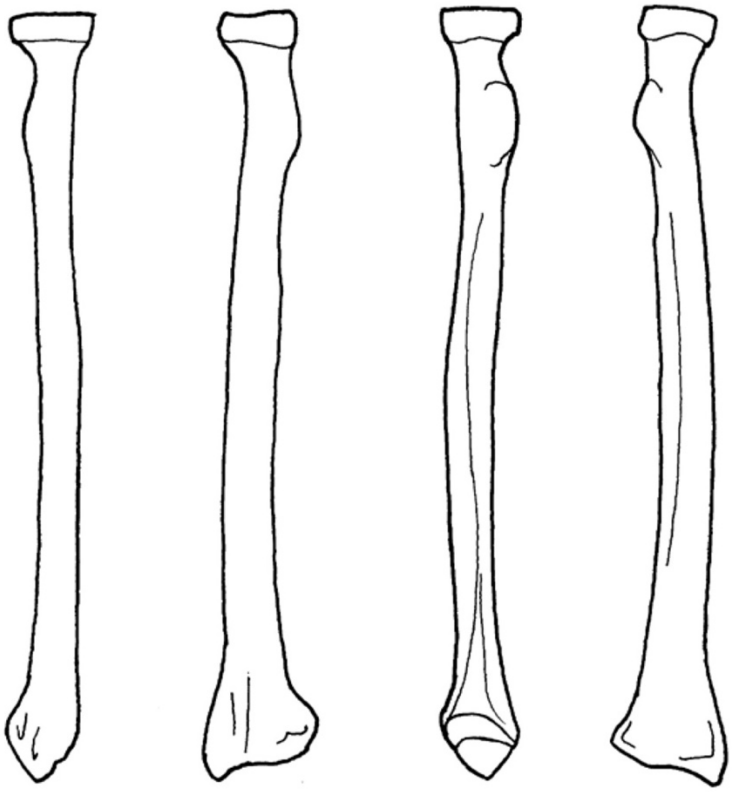

lateral **posterior** **medial** **anterior**

Notes:

Provenience _____ Numeric I.D. _____ Form 27

RIGHT ULNA

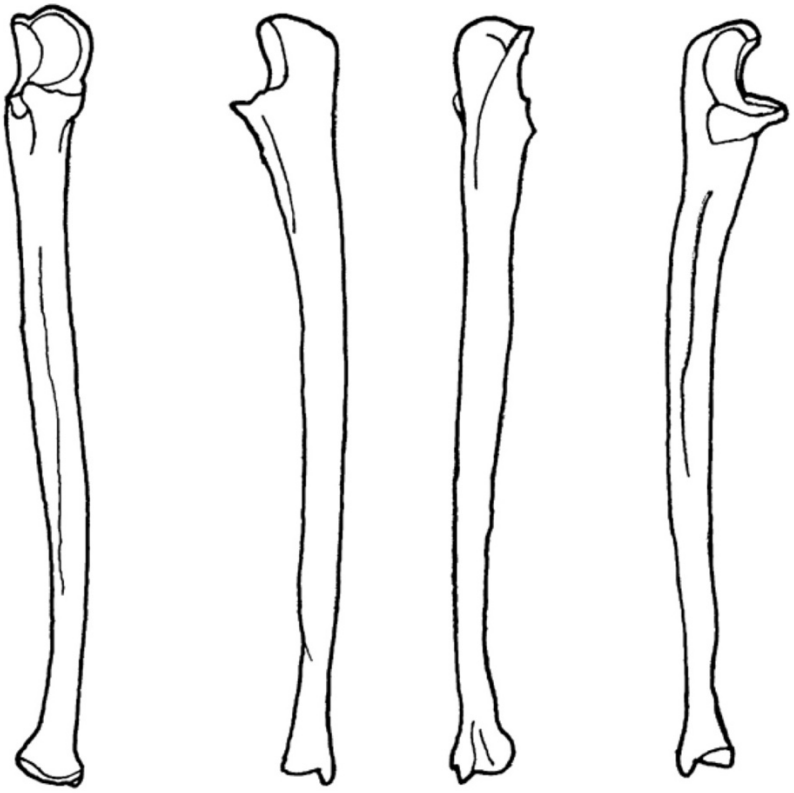

anterior **medial** **posterior** **lateral**

Notes:

Provenience _____ Numeric I.D. _____ Form 28

LEFT ULNA

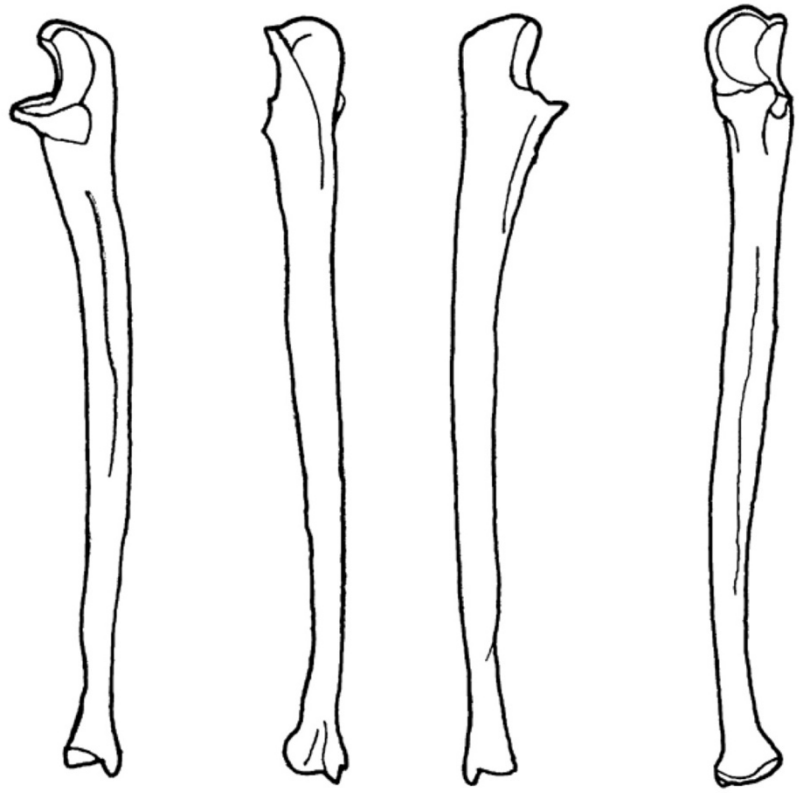

lateral **posterior** **medial** **anterior**

Notes:

Provenience _____ Numeric I.D. _____ Form 29

RIGHT FEMUR

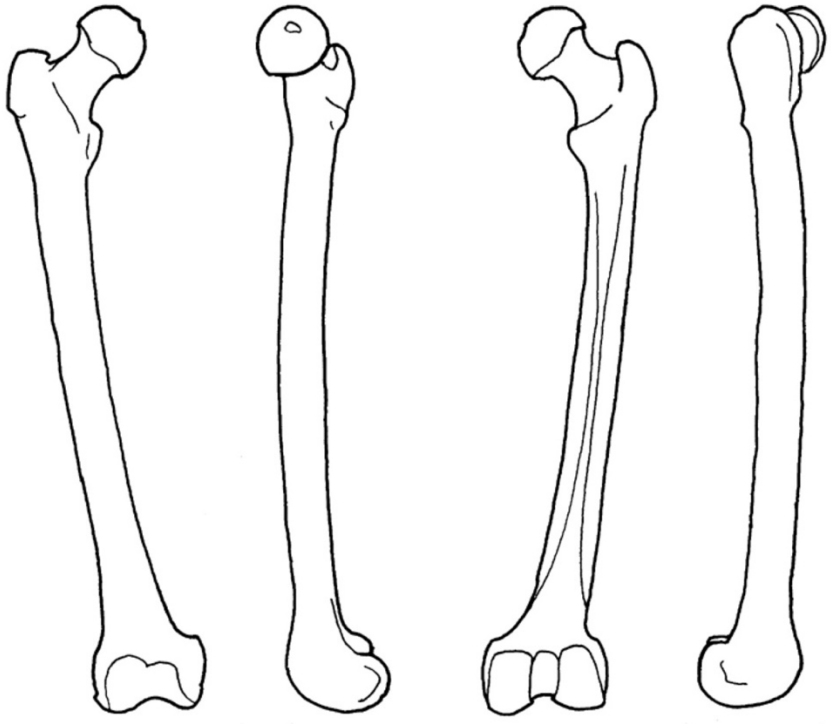

anterior **medial** **posterior** **lateral**

Notes:

Provenience _____ Numeric I.D. _____ Form 30

LEFT FEMUR

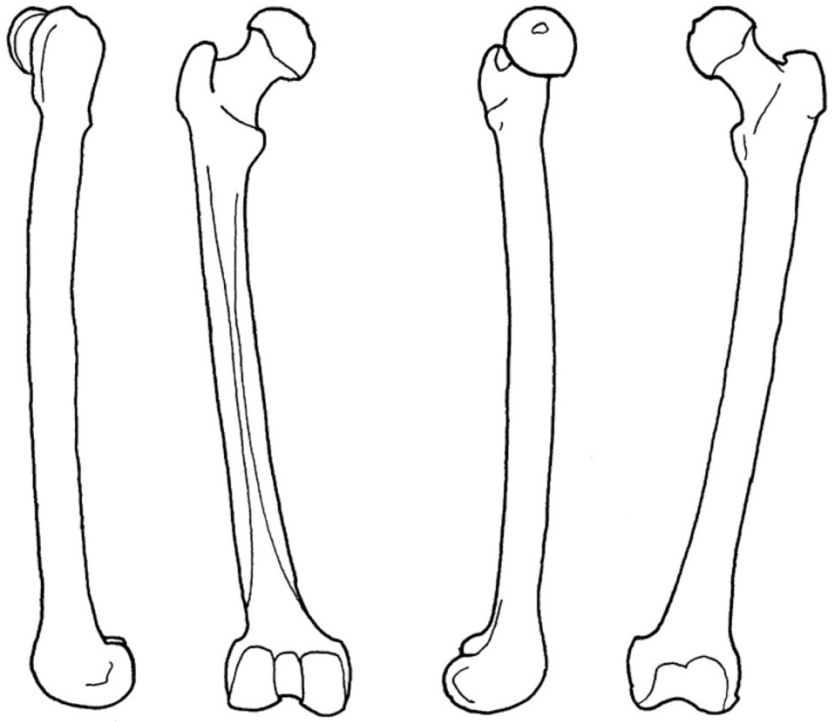

lateral **posterior** **medial** **anterior**

Notes:

Provenience _____ Numeric I.D. _____ Form 31

RIGHT TIBIA

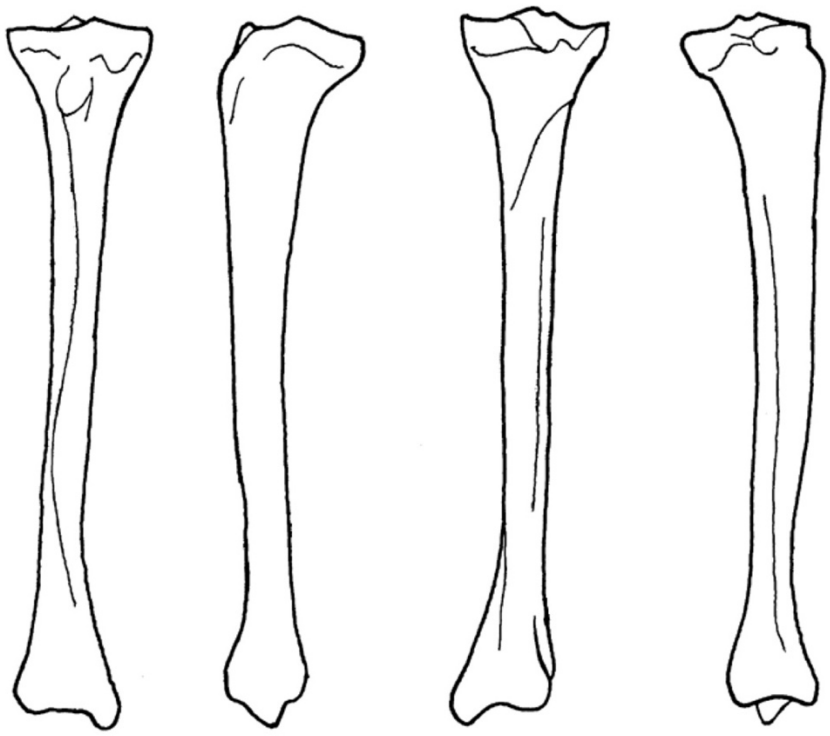

anterior **medial** **posterior** **lateral**

Notes:

Provenience _____ Numeric I.D. _____ Form 32

LEFT TIBIA

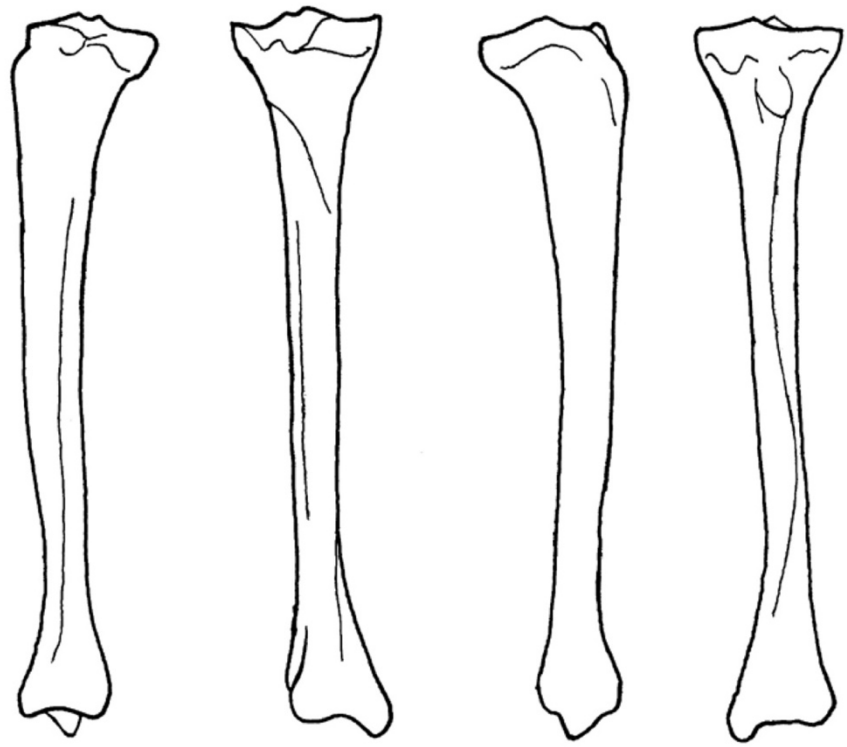

lateral **posterior** **medial** **anterior**

Notes:

Provenience _____ Numeric I.D. _____ Form 33

RIGHT FIBULA

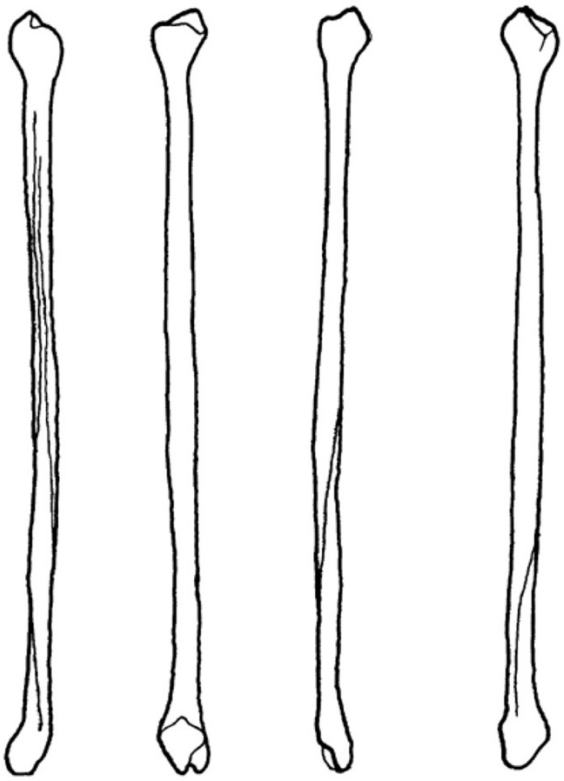

anterior **medial** **posterior** **lateral**

Notes:

Provenience _____ Numeric I.D. _____ Form 34

LEFT FIBULA



lateral **posterior** **medial** **anterior**

Notes:

Provenience _____ Numeric I.D. _____ Form 34

RIGHT HAND

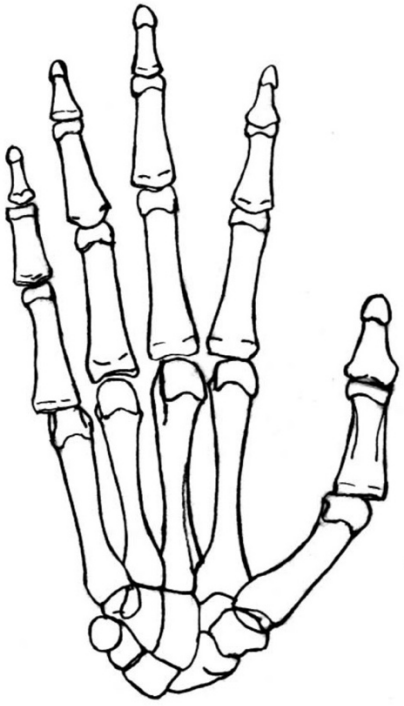

palmar

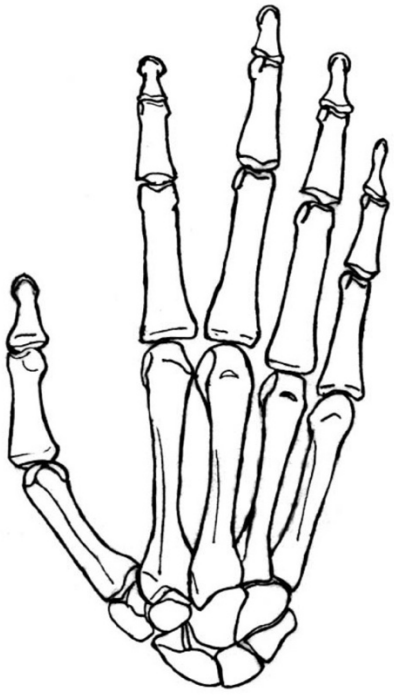

volar

Provenience _____ Numeric I.D. _____ Form 35

LEFT HAND

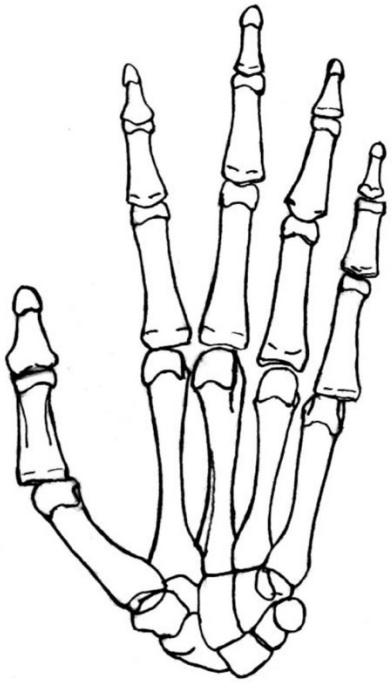

palmar

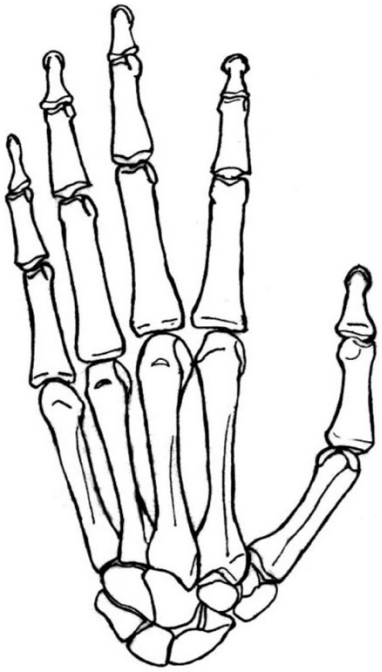

volar

Provenience _____ Numeric I.D. _____ Form 36

RIGHT FOOT

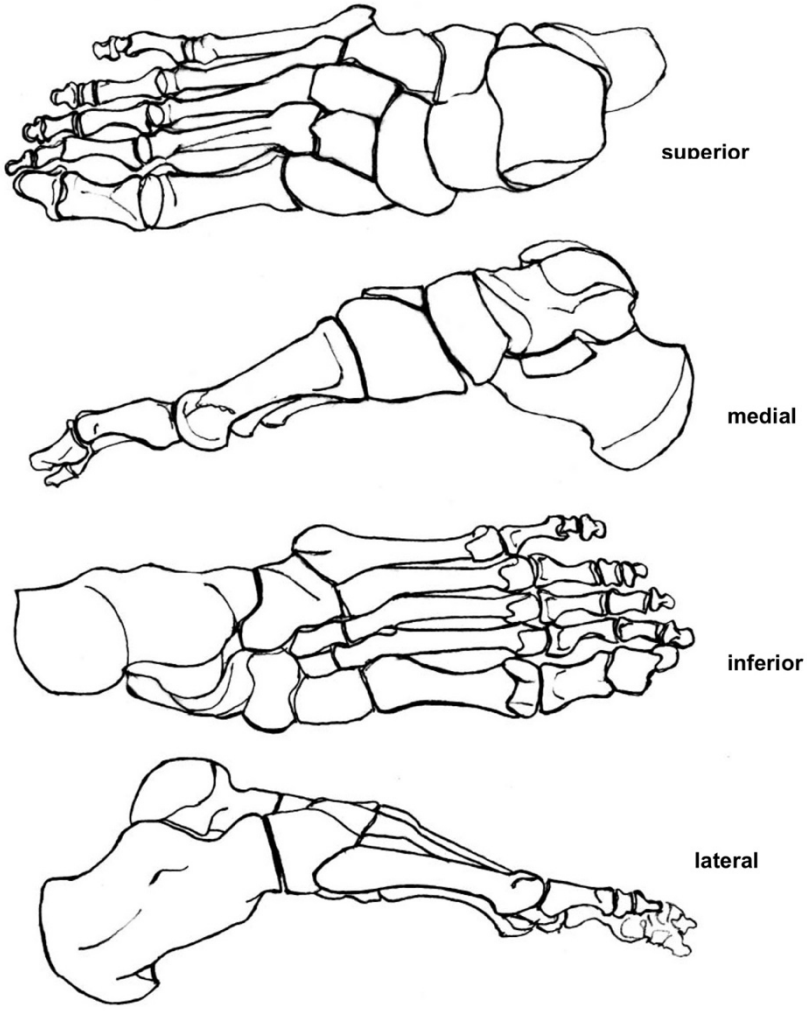

Provenience _____ Numeric I.D. _____ Form 37

LEFT FOOT

superior

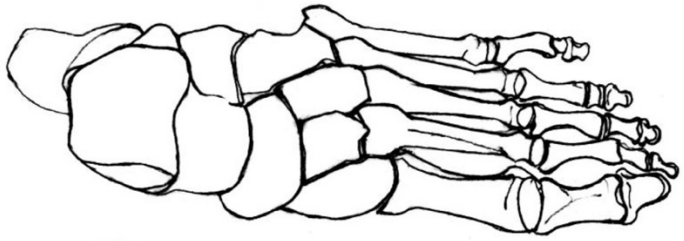

medial

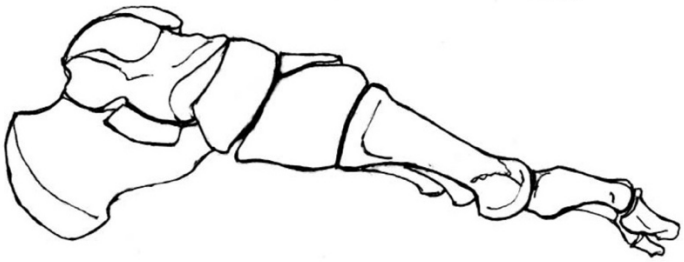

inferior

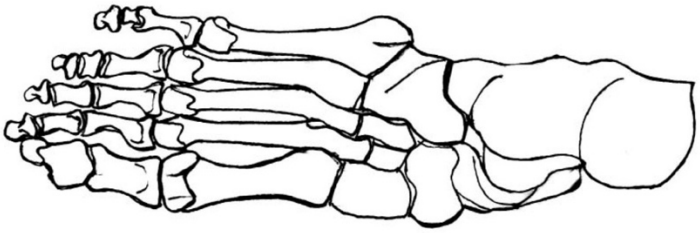

lateral

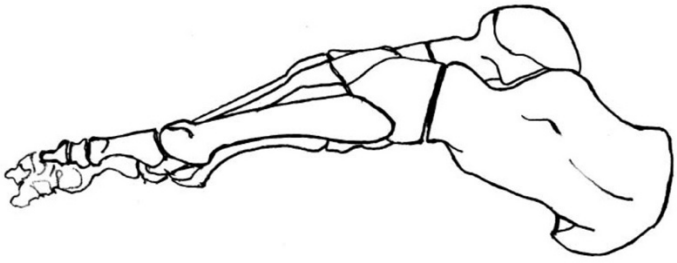

AGE ASSESSMENT

JUVENILE - RECORDING FORM (38)

Stage of Union:
0 = open
1 = minimal
2 = complete

Provenience: _____

Designation/ID: _____

Epiphyseal Union

Element	epiphysis	stage of union left	stage of union right
Scapula	coracoid	____	____
	acromium	____	____
Clavicle	sternal	____	____
Humerus	head	____	____
	distal	____	____
	med. epicondyle	____	____
Radius	proximal	____	____
	distal	____	____
Ulna	proximal	____	____
	distal	____	____
Os Coxa	iliac crest	____	____
	ischial tuberosity	____	____
Femur	head	____	____
	greater trochanter	____	____
	lesser trochanter	____	____
	distal	____	____
Tibia	proximal	____	____
	distal	____	____
Fibula	proximal	____	____
	distal	____	____
Metacarpals	proximal (1st)	____	
	distal (2-5)	____	
Metatarsals	proximal (1st)	____	
	distal (2-5)	____	
C. Phalanges	proximal	____	
T. Phalanges	proximal	____	

Primary Ossification Centers

Element	area of union	stage of union
Innominate	ilium-pubis	____
	ischium-pubis	____
	ischium-ilium	____
Sacrum	1-2	____
	2-3	____
	3-4	____
	4-5	____
Cervical vertebrae		
	neural arches to each other	____
	neural arches to centrum	____
Thoracic vertebrae		
	neural arches to each other	____
	neural arches to centrum	____
Lumbar vertebrae		
	neural arches to each other	____
	neural arches to centrum	____
Cranium		
	basilar suture	____
Occipital		
	lateral – squama	____
	basilar – lateral	____
Mandibular Symphysis		____
Metopic Suture		____

Age Assessment

	Age class	Age range in months or years	
Fetus	____	lunar months	____
Infant (birth – 2 yr)	____	months/years	____
Child (2 – 12 yr)	____	years	____
Subadult (12-20yr)	____	years	____

Comments (criteria used for age assessment):

†This form includes information derived from Arizona State Museum (ASM; Arizona State Museum 2018) and Buikstra and Ubelaker (1994), *Standards for Data Collection from Human Skeletal Remains,* Arkansas Archeological Survey, and is used with permission of the publisher.

Provenience _____ Numeric I.D. _____ Form 42

INFANT SKELETON

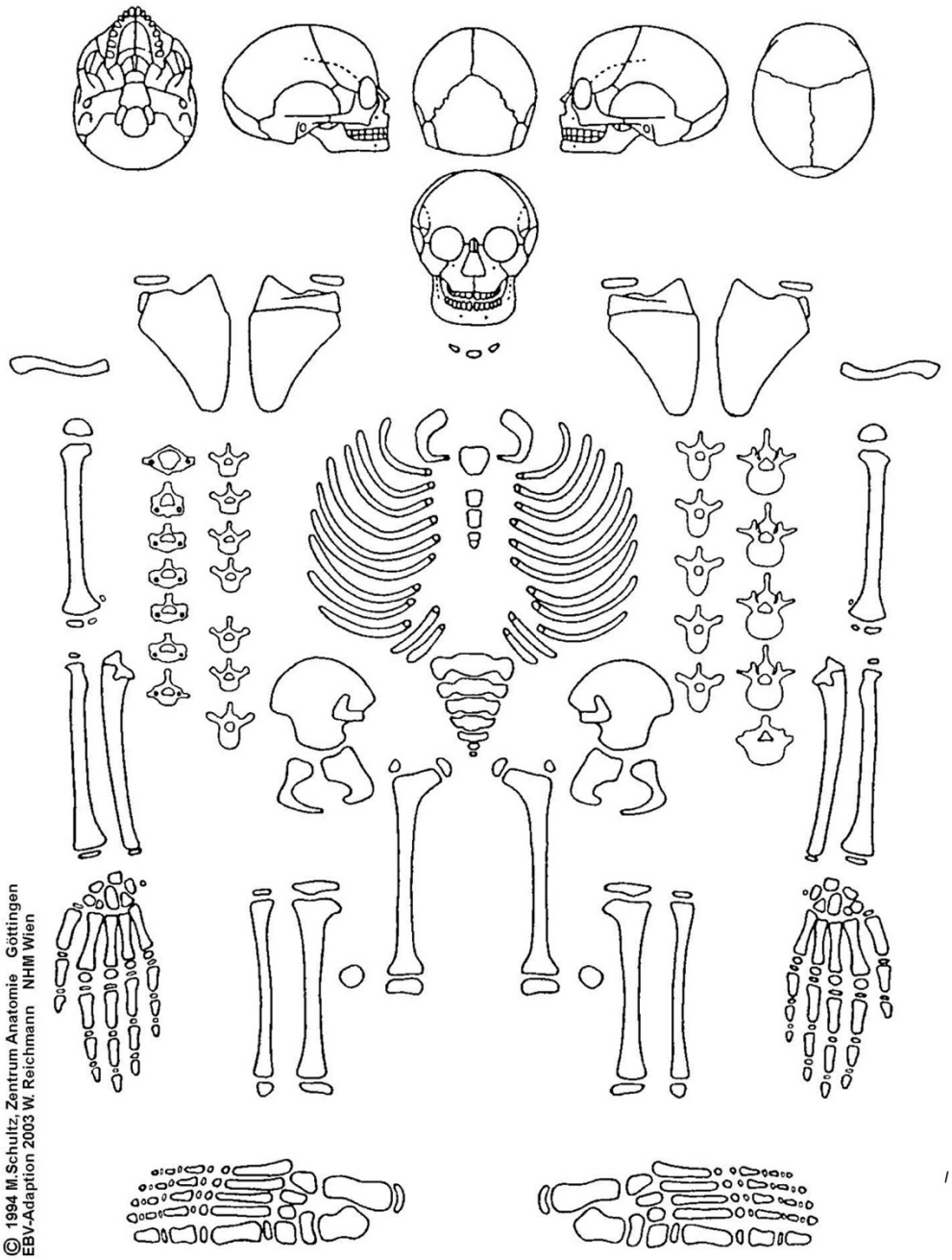

© 1994 M.Schultz, Zentrum Anatomie Göttingen
EBV-Adaption 2003 W. Reichmann NHM Wien

Provenience _____ Numeric I.D. _____ Form 43

CHILD SKELETON

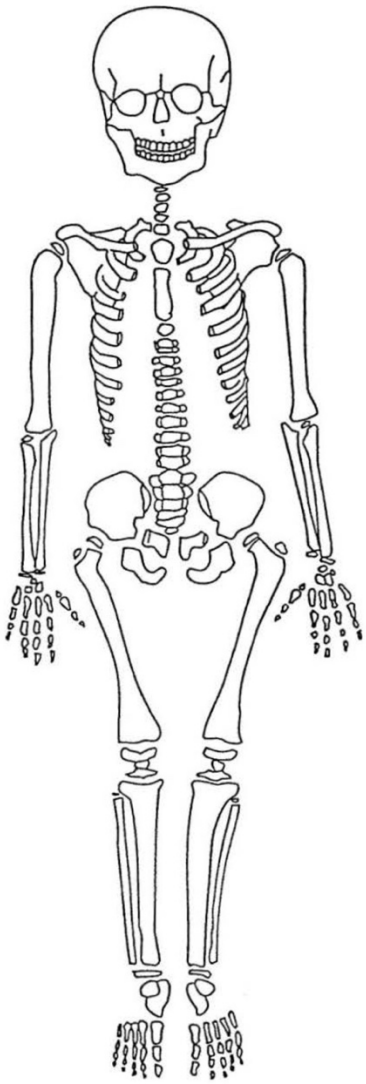

This form includes information derived from Buikstra and Ubelaker (1994), *Standards for Data Collection from Human Skeletal Remains,* Arkansas Archeological Survey, and is used with permission of the publisher.

Form 44

Provenience _____ Numeric I.D. _____

Fill-in skeletal chart when elements can be identified. Label with "U" if unsided, and "A" to denote approximated location. Use key below to shade fragments by color:

Tan (outline fragment)

Gray-Blue (cross-hatch)

Black (fill completelty)

White (hatch)

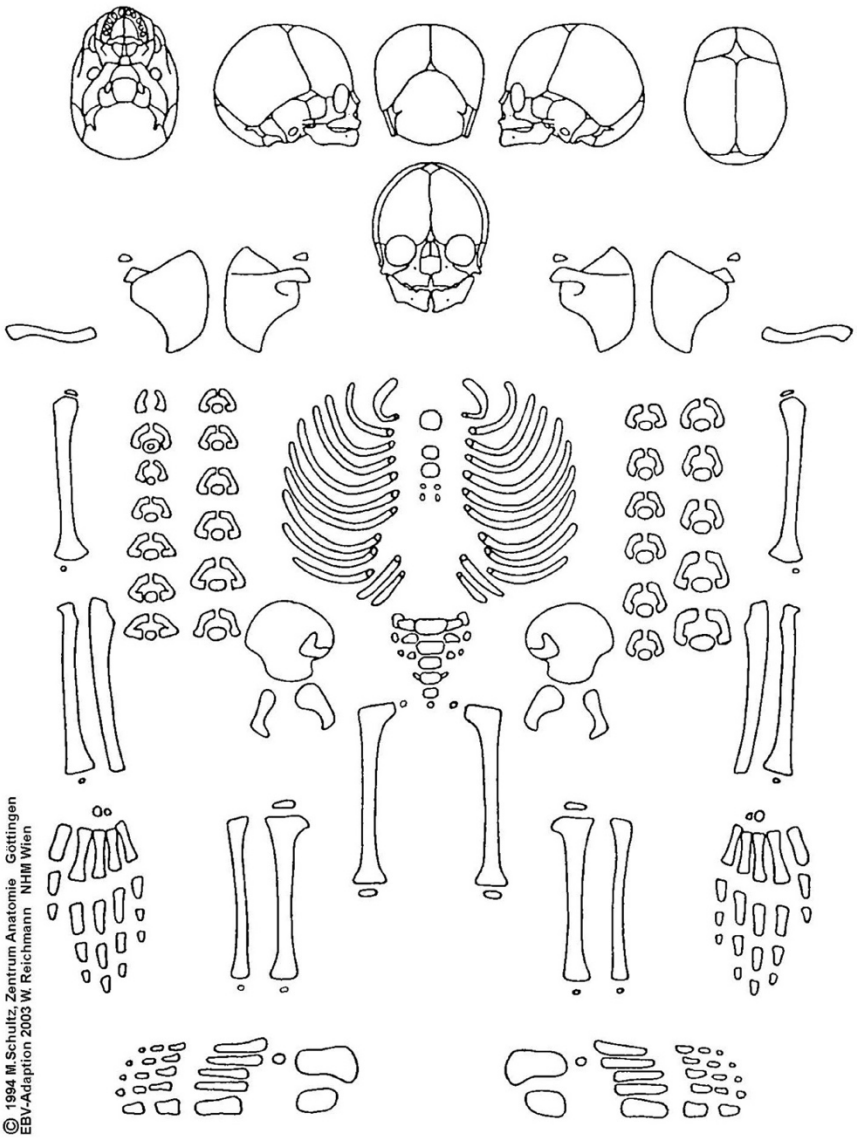

Form 45

Provenience _____ Numeric I.D. _____

Fill-in skeletal chart when elements can be identified. Label with "U" if unsided, and "A" to denote approximated location. Use key below to shade fragments by color:

Tan (outline fragment)

Gray-Blue (cross-hatch)

Black (fill completelty)

White (hatch)

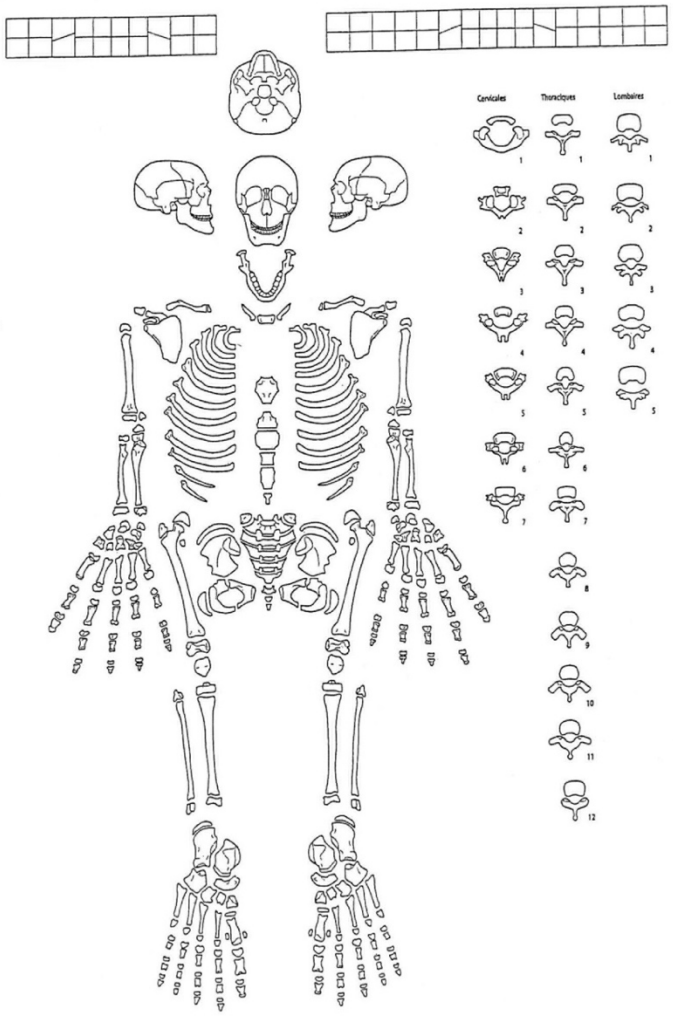

Form 46

Thermal Alterations Cremated Remains

Provenience	Number ID
Deposit Type (Primary or Secondary Deposit):	Primary or Main Color & Munsell Code
Secondary Color & Munsell Code	Calcined (Y/N) & Observations
Chalky (Y/N) & Observation	Warping, Degree & Observations
Cracking Type, Degree & Observations	Bone Weight (grams) & Observation
Total Bone Count & Observation	Maximum Length (mm) & Bone ID
Average Length (mm)	Burning Degree (see Holck 1969)
General Observations	Cranial Weights (grams)
Cranial Count	Cranial Maximum Length (mm) & Bone ID
Cranial Average Length (mm)	Cranial Color
Cranial Cracking , Degree & Type	Cranial Warping , Degree & Observations
Cranial Observation	Dentition Weigh (grams)
Dentition Count	Dentition Color
Dentition Warping, Degree &Observations	Dentition Cracking Degree &Type
Dentition Maximum Length (mm) &Bone ID	Dentition Average Length (mm)
Axial Color	Axial Cracking Degree &Type
Axial Warping, Degree & Observations	Axial Maximum Length (mm) & Bone ID
Axial Average Length (mm)	Axial Observations
Sternum Weights (mm)	Sternum Count
Ribs Weights (grams)	Ribs Count
Vertebrae Weights (grams)	Vertebrae Count
Scapula Weights(grams)	Scapula Count
Pelvis Weights (grams)	Pelvis Count
Humeri, Radii, Ulnae & Clavicles Weight (grams)	Humeri, Radii, Ulnae & Clavicles Count
Humeri, Radii, Ulnae & Clavicles Maximum Length (mm), & Bone ID	Humeri, Radii, Ulnae & Clavicles Average Length (mm)

Form 47

Thermal Alterations Cremated Remains

Provenience	Number ID
Femora, Tibiae, Fibulae & Patellae Weight (grams)	Femora, Tibiae, Fibulae & Patellae Count
Femora, Tibiae, Fibulae & Patellae Maximum Length (mm) & Bone ID	Femora, Tibiae, Fibulae & Patellae Average Length (mm)
Unidentified Long Bone Frag. Weight (grams)	Unidentified Long Bone Frag. Count
Appendicular Color	Appendicular Cracking Degree & Type
Appendicular Warping, Degree & Observations	Appendicular Maximum Length (mm) & Bone ID
Appendicular Average Length (mm)	Extremities Weight (grams)
Extremities Count	Extremities Color
Extremities Cracking Degree & Type	Extremities Warping Degree & Observations
Extremities Maximum Length (mm) & Bone ID	Extremities Average Length (mm)
Unidentified Bone Weight (grams)	Unidentified Bone Count (Fragments Length ≥ Equal 2 mm)
Unidentified Bone Color Unidentified Bone, Cracking Degree & Type	Unidentified Bone Warping Degree & Observations
Unidentified Bone Maximum Length (mm)	Unidentified Bone Average Length (mm)
Total Weight (G.) Sieve 9.5 mm	Maximum Length Sieve 9.5 mm
Total Weight (G.) Sieve 4.75 mm	Maximum Length Sieve 4.75 mm
Total Weight (G.) Sieve 2 mm	Maximum Length Sieve 2 mm
Total Weight (G.) Sieve <2 mm	Maximum Length Sieve< 2 mm
Additional Observations	Fragmentation Observations

Notes: Cracking type: V = Vertical, H = Horizontal and C = Concentric (thumbnail),
Warping and Cracking degree: Minor = < 25% , Moderate = 25%-75%, Heavy = >75%
This form is from Cerezo-Román, Jessica I. 2013 *Unpacking Personhood and Identity in The Hohokam Area of Southern Arizona*, School of Anthropology, The University of Arizona, Tucson, Arizona.
Reference:
Holck, P.1969 *Cremated Bones: A Medical-Anthropological Study of an Archaeological Material on Cremation Burials*. Anthropologiske skrifter Nr, 1 Anatomical Institude. University of Oslo, Oslo.

ISOLATED BONE RECORDING FORM Form 48

Site Name & # _____ **Date** _____
Numeric ID _____ **Observer** _____

MNI ____ MNI Category _____ Collection type _____

List each element. Indicate R or L side. Code completeness as C (75% or more), P (25-75%), or F (< 25%). For long bones, code regions as PE (proximal epiphysis), DE (distal epiphysis), P 1/3 (proximal third of shaft), M 1/3 (middle third), D 1/3 (distal third).

Elements Represented:

Cranial _____

Dental _____

Axial _____

Appendicular _____

Extremities _____

Unknown _____

Age & Sex assessment _____

Comments: (note pathologies, taphonomy, etc.)

ISOLATED CREMATED BONE RECORDING FORM

Form 49

Site Name & # _____ **Date** _____
Numeric ID _____ **Observer** _____
MNI _____
Bone weight (grams) _____ **Maximum length (cm)** _____ **Average length**_____
Color _____
Warping/Surface texture _____
_____

Elements Represented:

Cranial _____
% ____ _____
_____

Dental _____
% ____ _____
_____

Axial _____
% ____ _____
_____

Appendicular_____
% ____ _____
_____

Extremities _____
% ____ _____
_____

Unknown _____
% ____

Age & Sex assessment _____
_____
_____
_____

Comments: (note pathologies, etc.)

CREMATED BONE RECORDING FORM Form 50

Site Name & # _____ **Date** _____
Numeric ID _____ **Observer** _____
MNI _____ **MNI Form** _____ **Collection Type** _____

left	right	CRANIAL REMAINS		DENTAL REMAINS	#	condition	AREA	cond	path
___	___	Parietal	___ Mandible	Incisors	___	___	Cranial	____	____
___	___	Temporal	___ Frontal	Canines	___	___	Dental	____	____
___	___	Zygomatic	___ Sphenoid	Premolars	___	___	Axial	____	____
___	___	Lacrimal	___ Ethmoid	Molars	___	___	Appendicular	____	____
___	___	I. N. C.	___ Vomer	Milk Incisors	___	___	Extremities	____	____
___	___	Nasal	___ Occipital	Milk canines	___	___			
___	___	Maxilla	___ Hyoid	Milk molars	___	___			
___	___	Palatine	___ Thyroid	Peg teeth	___	___	**AGE CLASS**	_____	
____		Ossicles	___ Crycoid	Unident teeth	___	___	**SEX**	_____	

POSTCRANIAL REMAINS

	#	condition		left	right		left	right
Cervical	___	___	Scapula	___	___	Ilium	___	___
Thoracic	___	___	Clavicle	___	___	Ischium	___	___
Lumbar	___	___	Sternum	___		Pubis	___	___
Sacrum	___	___	Humerus	___	___	Femur	___	___
Coccyx	___	___	Radius	___	___	Tibia	___	___
			Ulna	___	___	Fibula	___	___
						Patella	___	___

	#	condition		#	condition		#	condition
Left Ribs	___	___	Carpals	___	___	Tarsals	___	___
Right Ribs	___	___	Metacarpals	___	___	Metatarsals	___	___
			C. Phalanges	___	___	T. Phalanges	___	___

PATHOLOGY:
_____
_____
_____
_____

Sex Criteria _____
_____

Age Criteria _____
_____

Bone weight (grams) _____ Maximum dimension (cm) _____ Average Dimension (cm) _____

Color _____

Warping/Surface texture_____

Inventory Notes:

Appendix B: Expanded Preservation of Elements by Skeletal Region

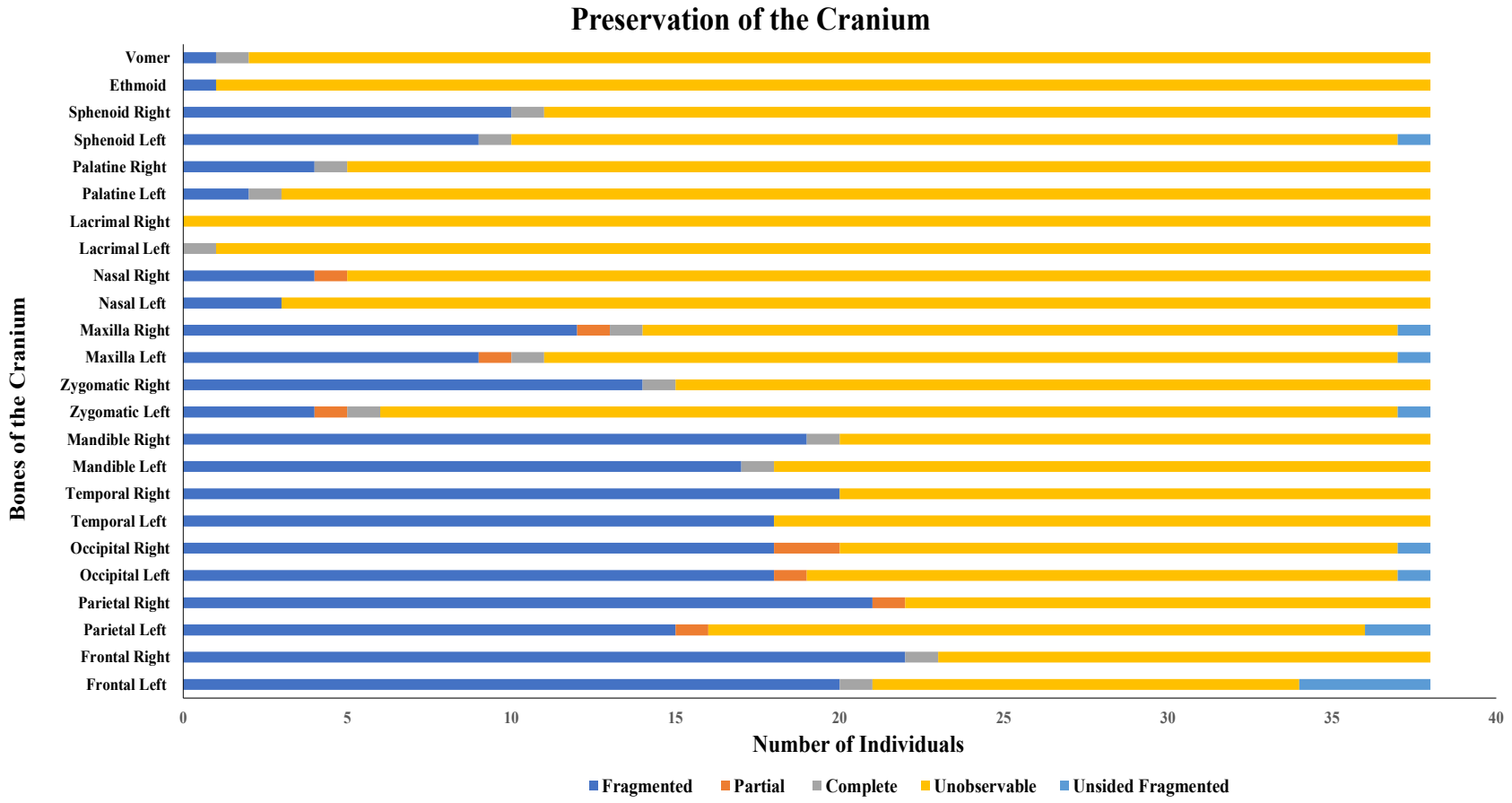

Figure 22 Preservation of the Cranium by Bone and Side

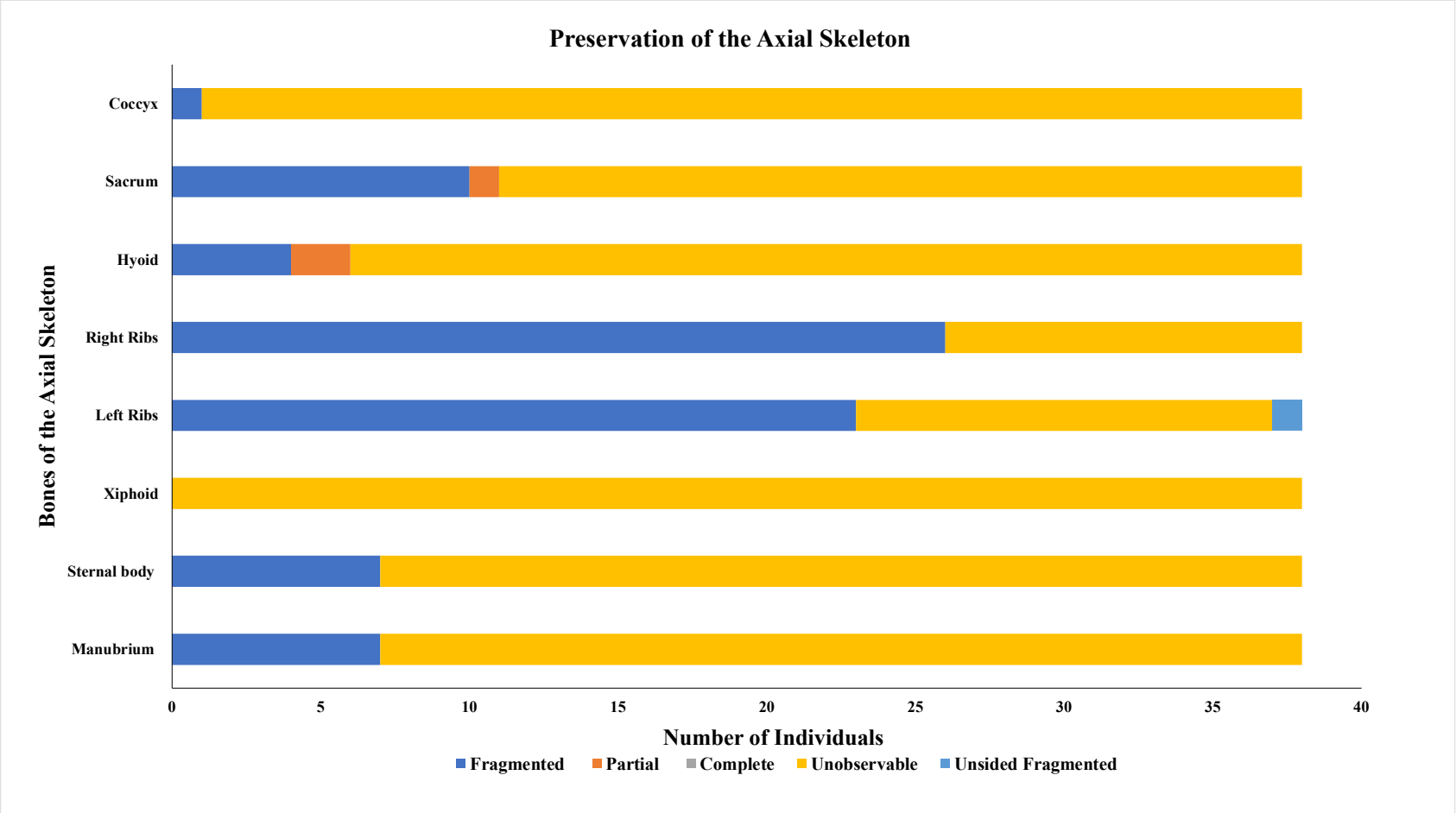

Figure 23 Preservation of the Axial Skeleton by Bone

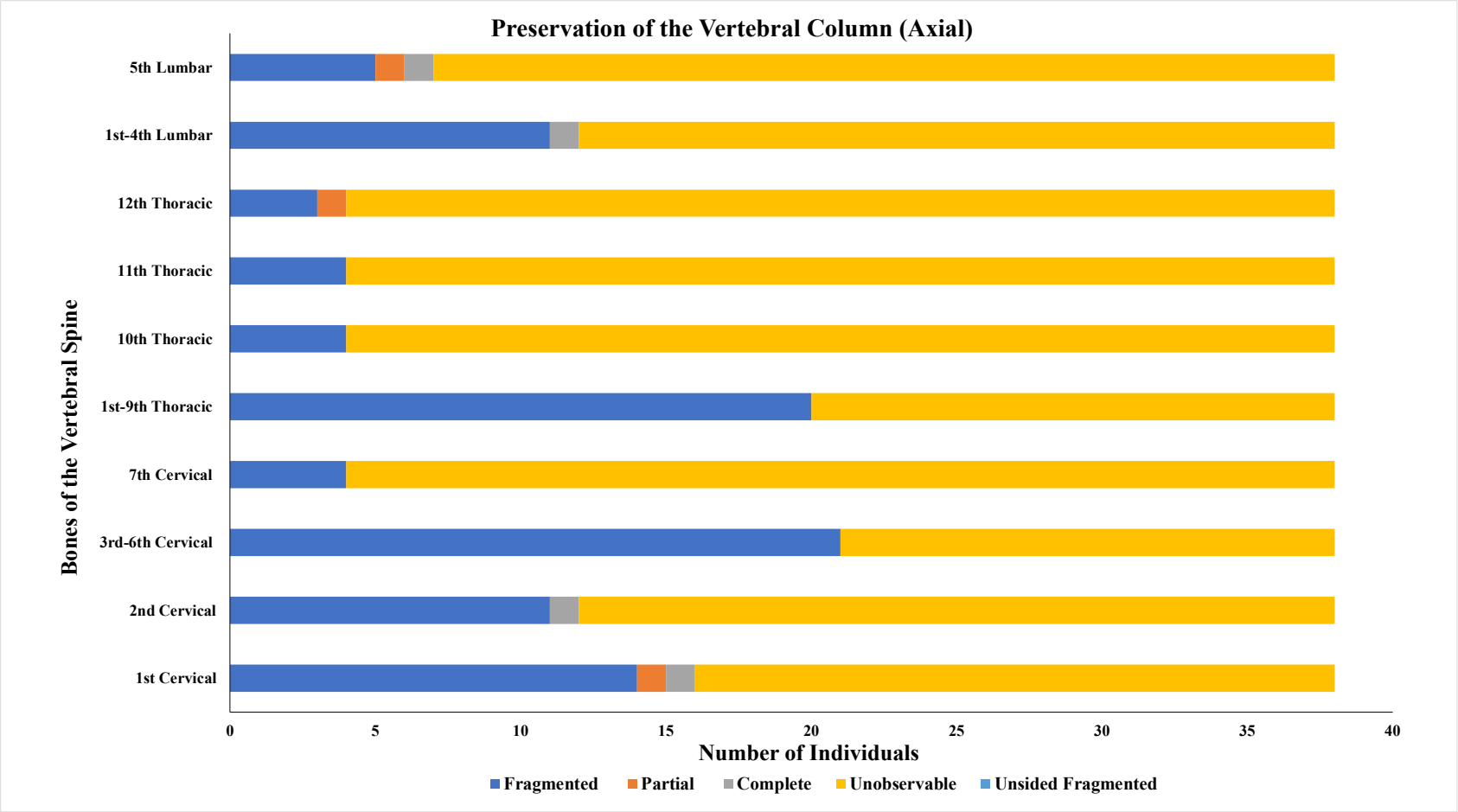

Figure 24 Preservation of the Vertebral Column (Axial) by Bone

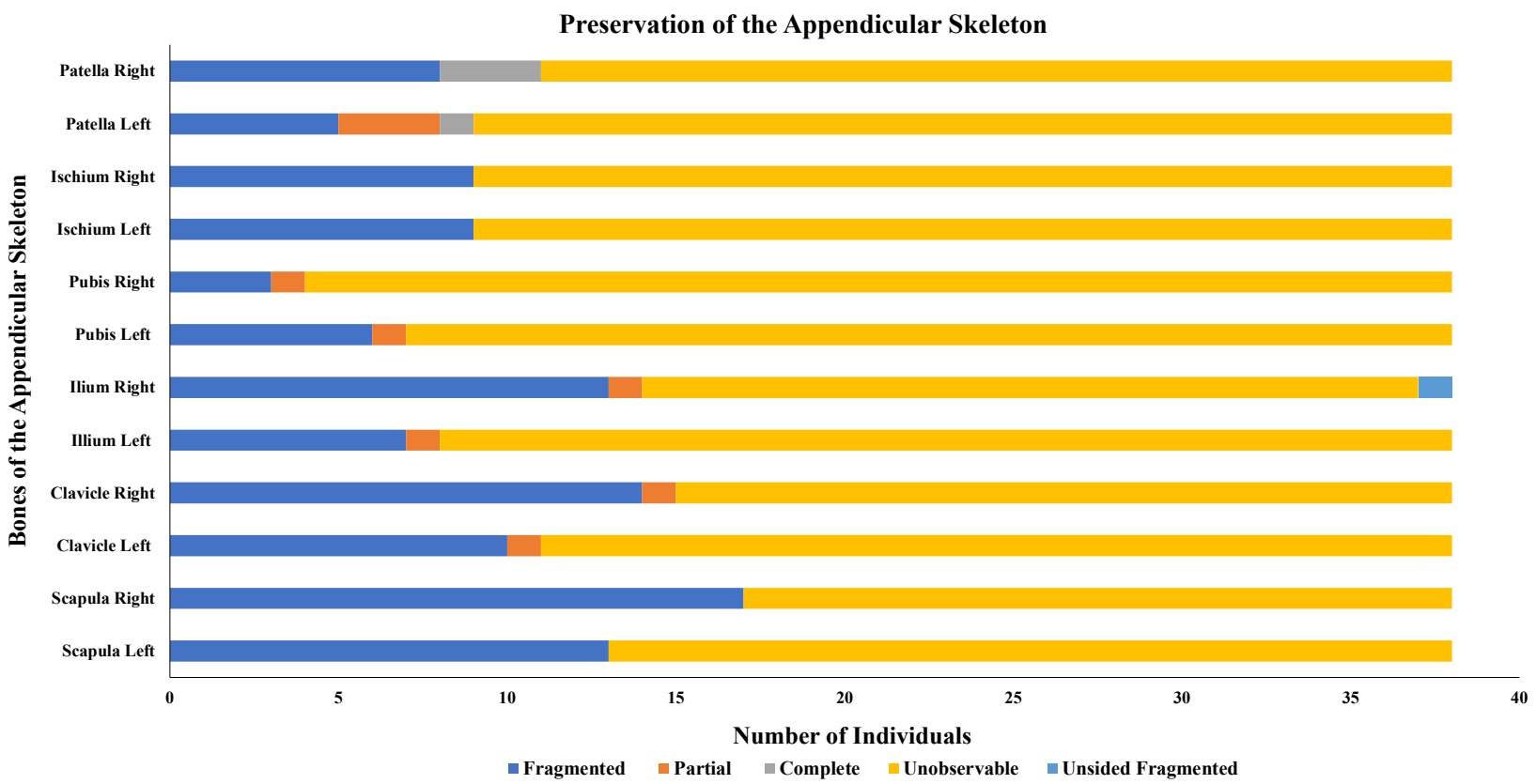

Figure 25 Preservation of the Appendicular Skeleton by Bone

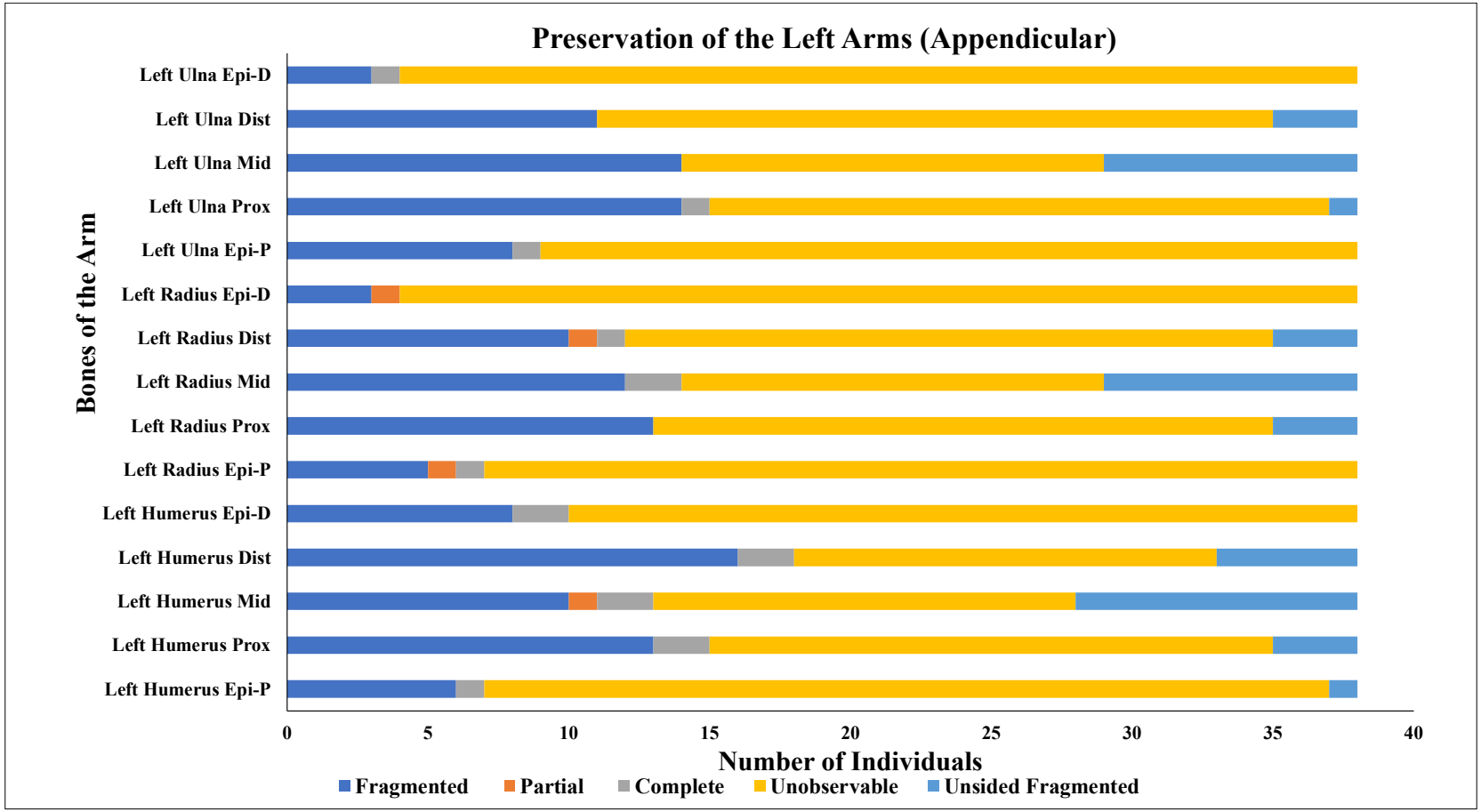

Figure 26 Preservation of the Left Arms (Appendicular) by Bone

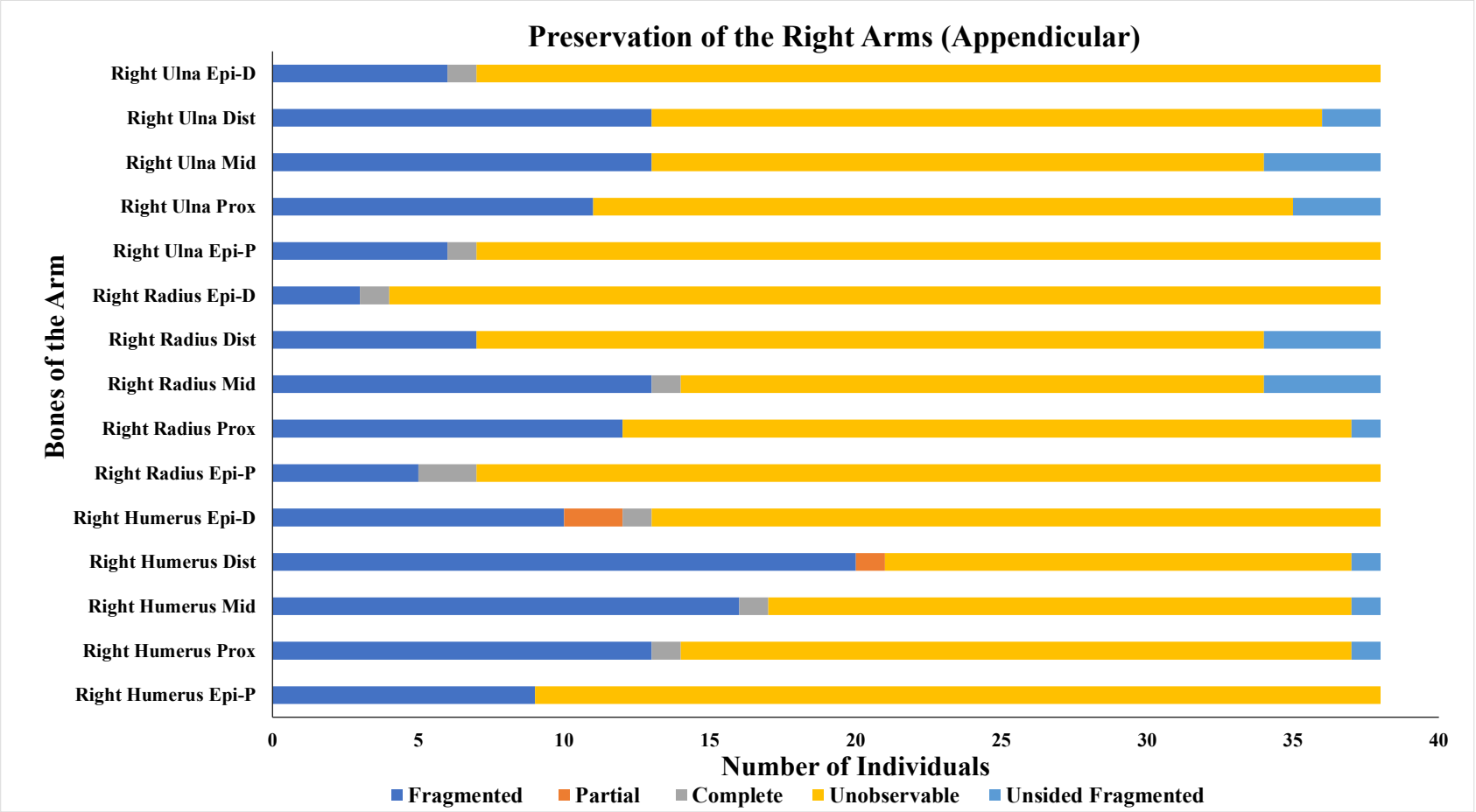

Figure 27 Preservation of the Right Arms (Appendicular) by Bone

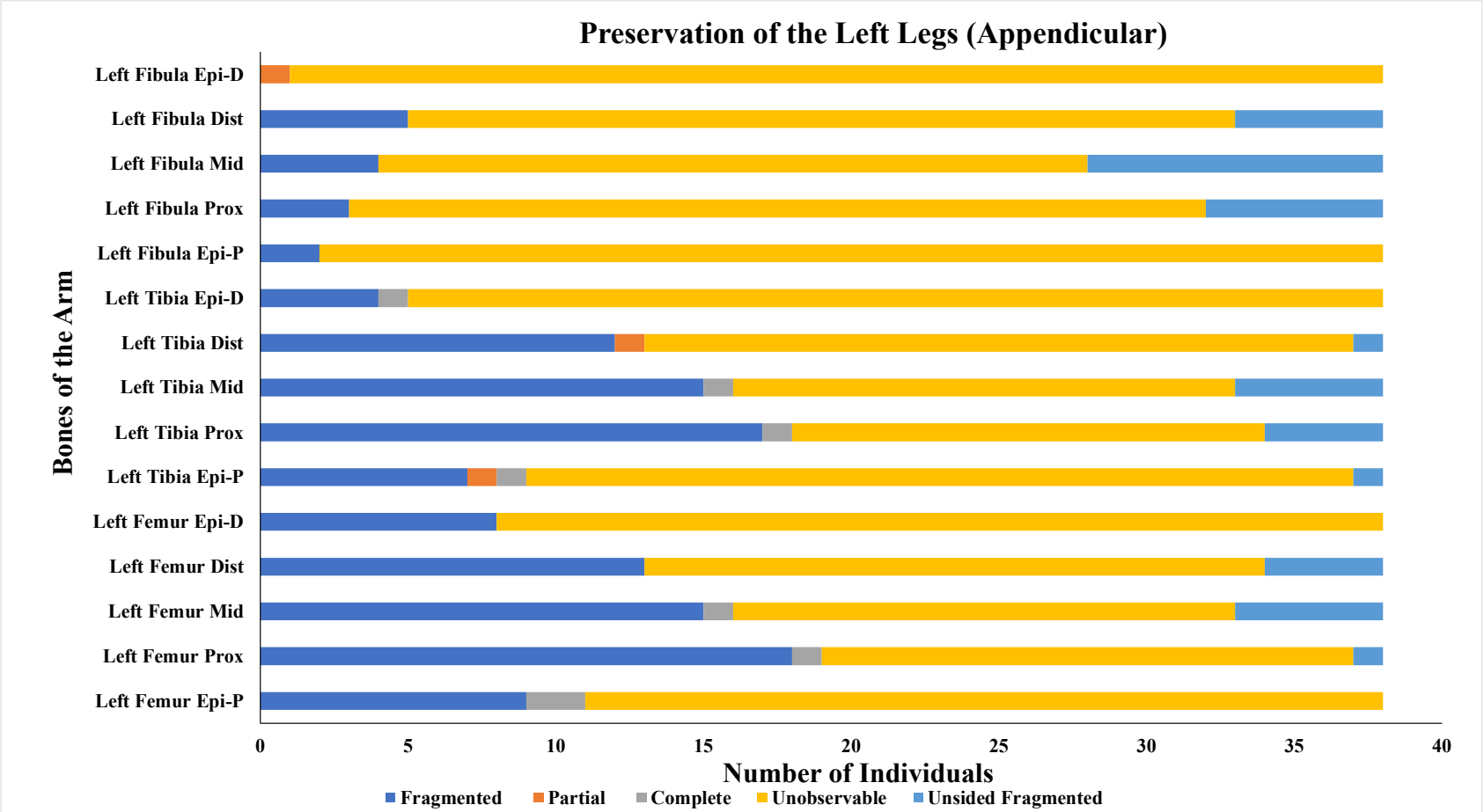

Figure 28 Preservation of the Left Legs (Appendicular) by Bone

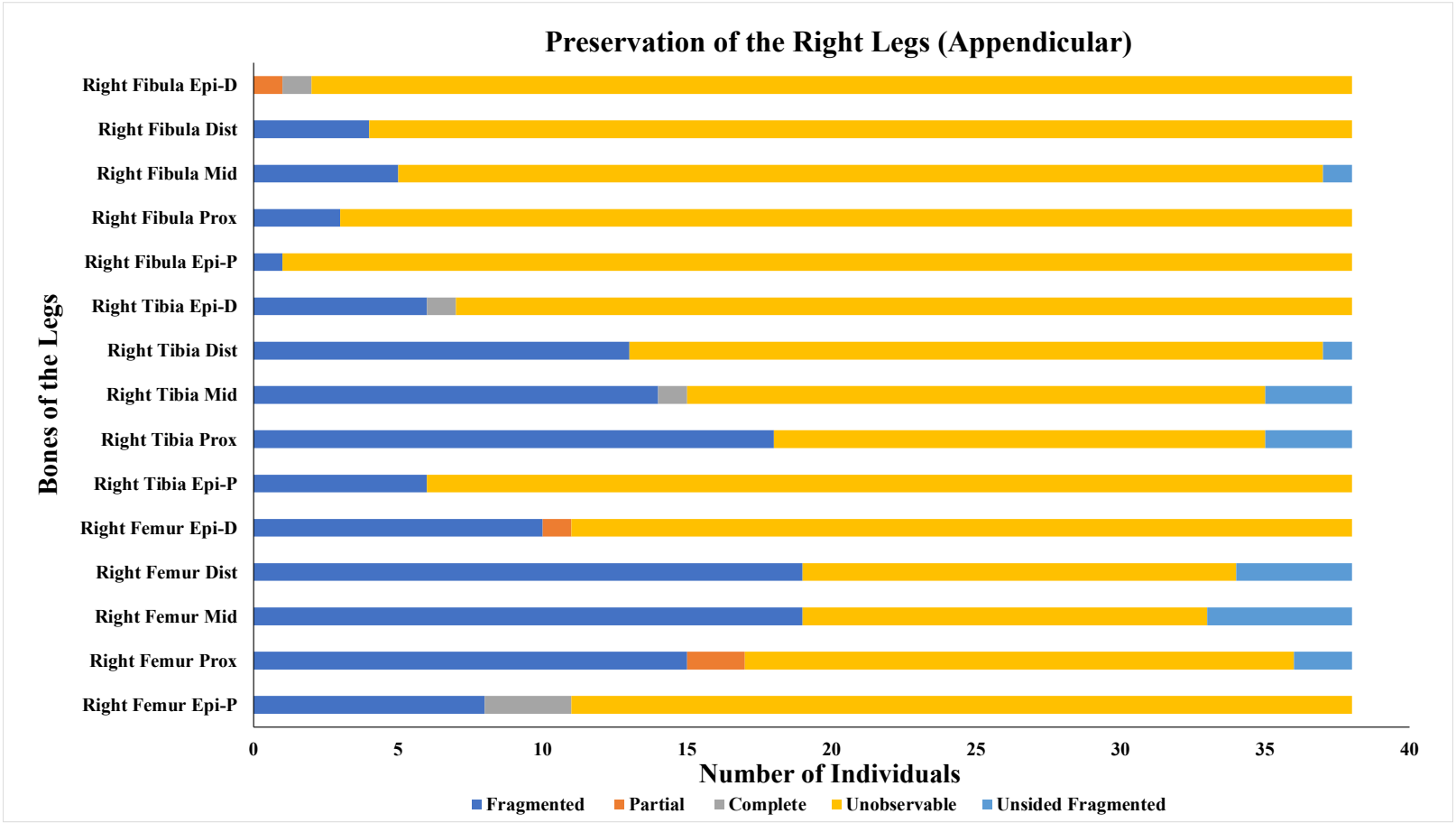

Figure 29 Preservation of the Right Legs (Appendicular) by Bone

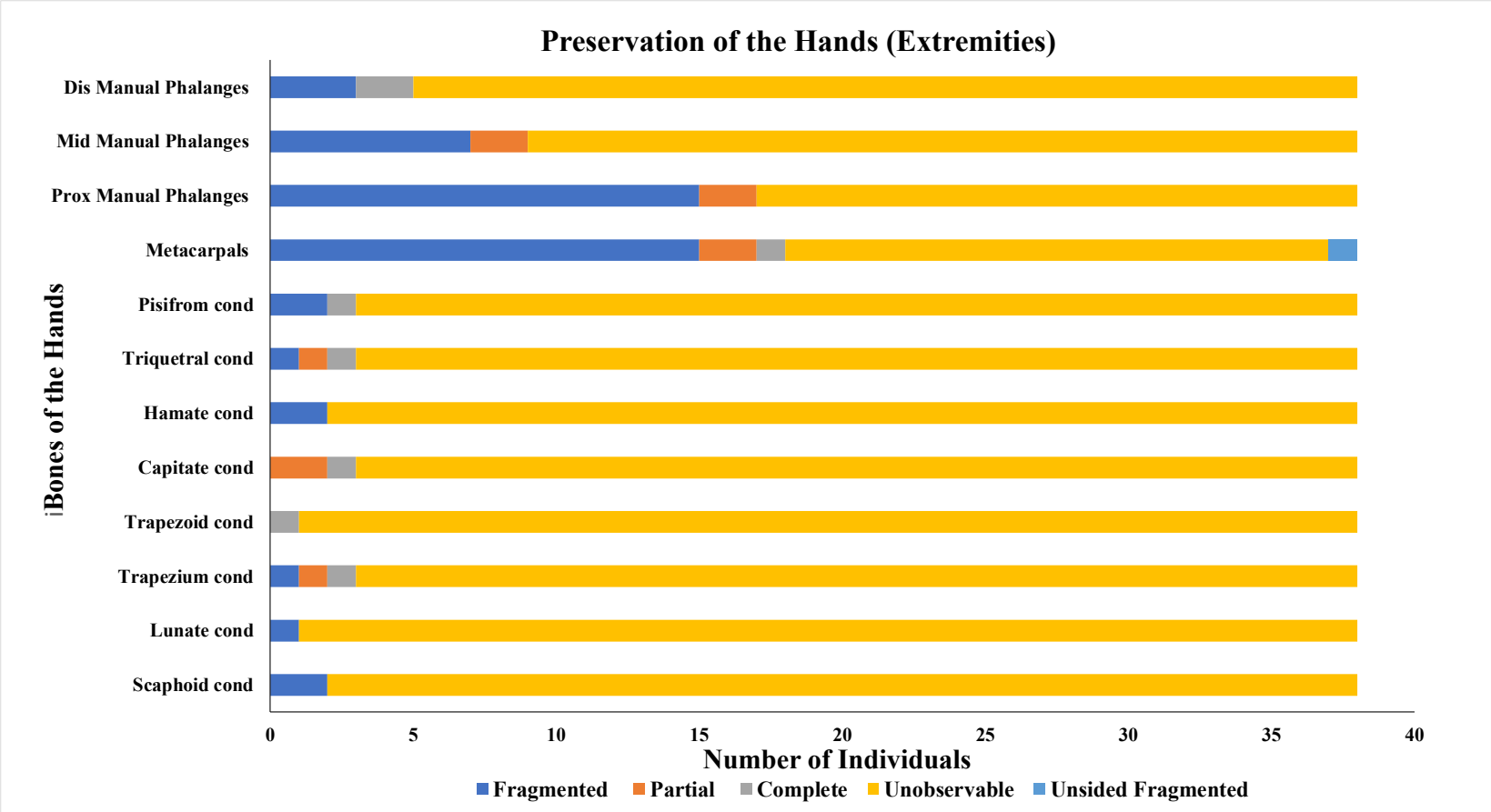

Figure 30 Preservation of the Hands (Extremities) by Bone

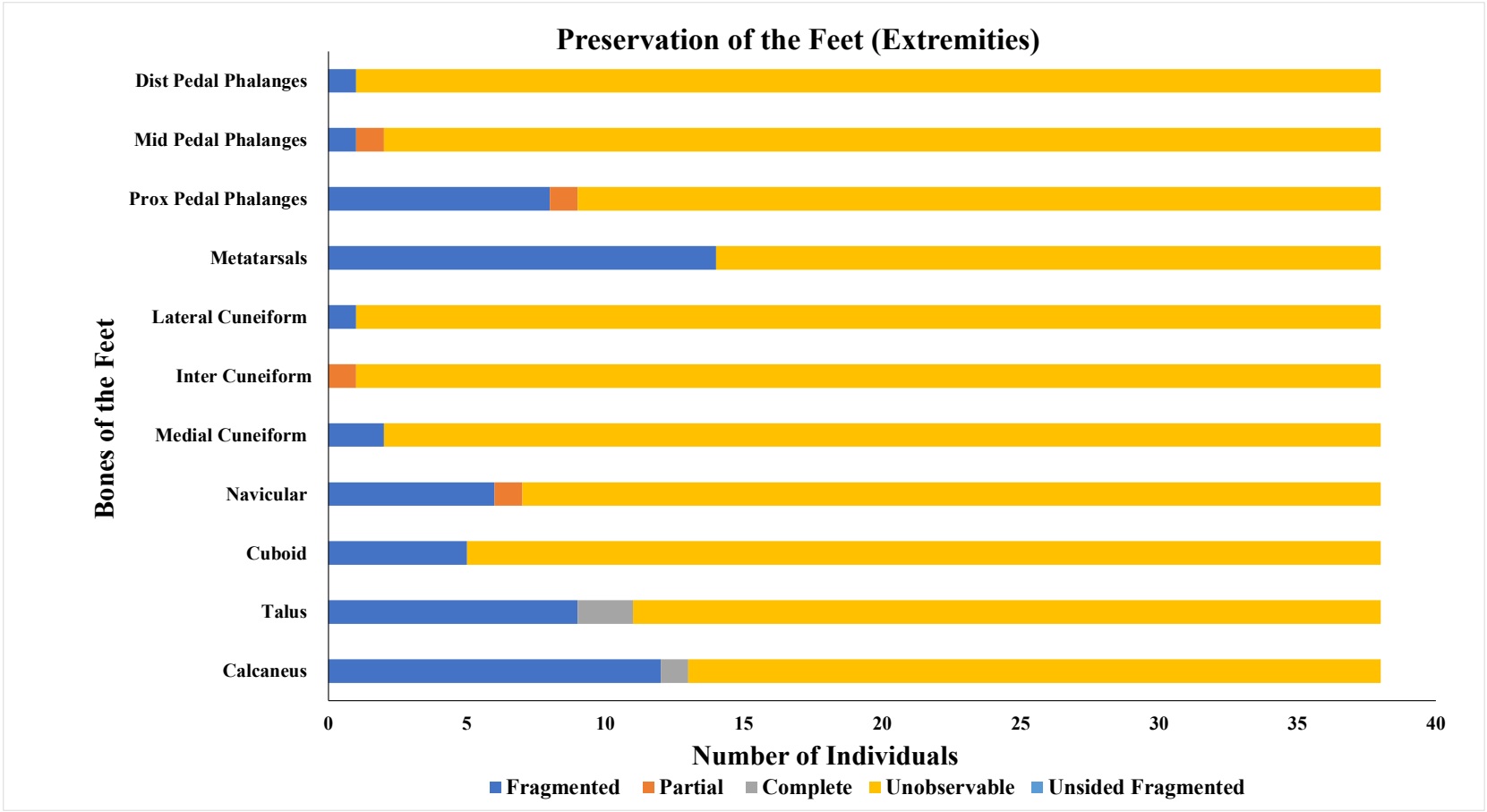

Figure 31 Preservation of the Feet (Extremities) by Bone