INFORMATION TO USERS

This material was produced from a microfilm copy of the original document. While the most advanced technological means to photograph and reproduce this document have been used, the quality is heavily dependent upon the quality of the original submitted.

The following explanation of techniques is provided to help you understand markings or patterns which may appear on this reproduction.

1. The sign or "target" for pages apparently lacking from the document photographed is "Missing Page(s)". If it was possible to obtain the missing page(s) or section, they are spliced into the film along with adjacent pages. This may have necessitated cutting thru an image and duplicating adjacent pages to insure you complete continuity.

2. When an image on the film is obliterated with a large round black mark, it is an indication that the photographer suspected that the copy may have moved during exposure and thus cause a blurred image. You will find a good image of the page in the adjacent frame.

3. When a map, drawing or chart, etc., was part of the material being photographed the photographer followed a definite method in "sectioning" the material. It is customary to begin photoing at the upper left hand corner of a large sheet and to continue photoing from left to right in equal sections with a small overlap. If necessary, sectioning is continued again — beginning below the first row and continuing on until complete.

4. The majority of users indicate that the textual content is of greatest value, however, a somewhat higher quality reproduction could be made from "photographs" if essential to the understanding of the dissertation. Silver prints of "photographs" may be ordered at additional charge by writing the Order Department, giving the catalog number, title, author and specific pages you wish reproduced.

5. PLEASE NOTE: Some pages may have indistinct print. Filmed as received.

Xerox University Microfilms
300 North Zeeb Road
Ann Arbor, Michigan 48106

Downloaded from SHAREOK. Persistent Handle URL: https://hdl.handle.net/11244/3676

74-9864

BOYD, Robert Bruce, 1942-
A COMPARATIVE ANATOMICAL STUDY OF THE RESPIRATORY SYSTEMS OF THE ANTARCTIC WEDDELL AND CRABEATER SEALS.

The University of Oklahoma, Ph.D., 1973
Anatomy

University Microfilms, A XEROX Company, Ann Arbor, Michigan

THIS DISSERTATION HAS BEEN MICROFILMED EXACTLY AS RECEIVED.

THE UNIVERSITY OF OKLAHOMA

GRADUATE COLLEGE

A COMPARATIVE ANATOMICAL STUDY OF THE RESPIRATORY SYSTEMS OF THE ANTARCTIC WEDDELL AND CRABEATER SEALS

A DISSERTATION

SUBMITTED TO THE GRADUATE FACULTY

in partial fulfillment of the requirements for the

degree of

DOCTOR OF PHILOSOPHY

BY

ROBERT B. BOYD

Oklahoma City, Oklahoma

1973

A COMPARATIVE ANATOMICAL STUDY OF THE RESPIRATORY SYSTEMS OF THE ANTARCTIC WEDDELL AND CRABEATER SEALS

APPROVED BY

DISSERTATION COMMITTEE

DEDICATED TO

William M. Bass, Ph.D.

ACKNOWLEDGMENTS

I wish to express my deepest thanks to Dr. W. J. L. Felts, Chairman of the Department of Anatomical Sciences and my major professor. The confidence and faith that he has shown me during my graduate school career gave me the inspiration necessary to finish my dissertation studies.

My sincerest appreciation is extended to Dr. R. E. Coalson of the Department of Anatomical Sciences, whose long hours of guidance, both in the field and in the laboratory, made the completion of this research possible.

Special recognition is extended to Dr. J. T. Eastman of the Division of Biological and Medical Sciences, Brown University, Providence, Rhode Island and to Dr. C. M. Drabek of the Department of Biology, Central State University, Edmond, Oklahoma whose instruction in comparative anatomy and pinniped physiology greatly facilitated my understanding of marine mammals.

I wish to thank Dr. K. K. Faulkner and Dr. J. F. Lhotka, Jr. of the Department of Anatomical Sciences and Dr. A. K. Weiss of the Department of Physiology and Biophysics for the time given so freely during the completion of this dissertation.

I am indebted to Mr. T. M. Sprowl, Senior Laboratory Technician of the Department of Anatomical Sciences for the many hours he spent in preparing the

histological material utilized in this study.

Special appreciation is extended to Dr. Donald Siniff and Mr. Larry Kuechle of the University of Minnesota for their help in finding and capturing the Weddell seals used in this project.

I wish to thank the personnel of N.S.F. (U.S.A.R.P.), the U.S. Navy (Antarctic Support Activities and Air Squadron VXE-6) and Holmes and Narver, Inc. for their logistical support during the field work completed at McMurdo Station, Antarctic.

This research was supported by grant GV-23557 from the National Science Foundation, Office of Polar Programs administered through the United States Antarctic Research Program (U.S.A.R.P.).

Special appreciation is extended to the Department of Anatomical Sciences for the use of the supplies and departmental equipment during my graduate school career.

TABLE OF CONTENTS

Page

LIST OF TABLES vii

Chapter

I. INTRODUCTION 1

II. MATERIALS AND METHODS 11

III. RESULTS 19

IV. DISCUSSION 42

V. SUMMARY AND CONCLUSIONS 58

BIBLIOGRAPHY 60

APPENDIX 70

LIST OF TABLES

Table		Page
1.	Animals Utilized in Study	12
2.	Histological Features of Weddell Seal Tracheo-Bronchial Tree	29
3.	Weddell Seal Lung: Fluid and Tissue Volumes	32

A COMPARATIVE ANATOMICAL STUDY OF THE RESPIRATORY SYSTEMS OF THE ANTARCTIC WEDDELL AND CRABEATER SEALS

CHAPTER I

INTRODUCTION

The first systematic experiments on the respiration of diving vertebrates were conducted on birds (Bert, 1870). By studying the responses of the hen and the duck to forced diving conditions, Bert proved to his satisfaction that the major factor in the duck's ability to remain submerged longer than the hen was its greater blood/body weight ratio. This condition obviously allowed for a greater availability of oxygen during the dive, and Bert felt that this extra supply of oxygen was the factor giving the duck the greater capability.

For over 20 years, Bert's findings were accepted without reservations. Then, in a series of experiments in the last decade of the 1800's, Richet (1894, 1898) and Langlois and Richet (1898a, 1898b), again working with ducks, showed that other factors besides the greater availability of oxygen in the blood permitted the longer diving time of that animal. By measuring the composition of lung and air-sac gases during a dive, they found that the consumption of oxygen

was markedly decreased. Therefore, the set amount of oxygen present during a dive would be available over a longer period of time. Richet (1899) also felt that other physiological adaptations and a decrease in tissue metabolism must surely occur in order to facilitate the longer diving time of the duck. However, he did not speculate further as to precisely what these adaptations might be.

Further pertinent investigations of diving vertebrates did not occur for 14 years. Then, in a series of papers, Huxley (1913a, 1913b, 1913c) showed that the apnea occurring upon submersion was due to a reflex independent of higher central nervous system control. In her experiments both decerebrate and normal ducks displayed apnea when immersed in water. Huxley also showed that a duck placed in its diving posture while still breathing air would exhibit the same physiological responses as those of a submerged animal. She referred to this phenomenon as a postural reflex. Huxley's final observations indicated that diving bradycardia might also be a reflex action since it occurred in both normal and decerebrate ducks.

Many early investigations were undertaken to elucidate the physiological mechanisms involved in the diving of non-mammalian vertebrates. Various studies on the respiratory mechanism of amphibians were carried out during this period (Axenfeld, 1911; Brown, 1909; Willem, 1919; Vincent and Cameron, 1920). However, because the skin of most amphibians functions as an additional respiratory organ (Foxon, 1964), it was difficult to measure accurately their total respiratory activity and related physiological responses. Therefore, studies employing reptiles and birds have been much more meaningful when their results are compared with those of the diving mammalians.

Diving mechanisms of all extant orders of Reptilia except the Rhynchocephalia have been investigated. Andersen (1961) undertook an extensive study of the American alligator, Alligator mississippiensis. The more pertinent studies on turtles were those of Berkson (1966), on the Pacific green turtle, Chelonia mydas agassizii, White and Ross (1966), on the pond turtle, Pseudemys scripta, and Belkin (1968), on the musk turtle, Sternothaerus minor, and Pseudemys scripta. The aquatic snakes investigated have been the common grass snake, Tropidonotus natrix (Johansen, 1959), the water snakes, Natrix sipedon and Natrix cyclopion, (Murdaugh and Jackson, 1962), and the elephant trunk snake, Acrochordus javanicus (Pough, 1973). Finally, Bartholomew and Lasiewski (1965) studied the Galapagos marine iguana, Amblyrhynchus cristatus, and Moberly (1968) investigated the diving responses of the common iguana, Iguana iguana.

As noted in earlier references, the duck has been the most widely studied diving bird. Of the ducks utilized, the domestic duck, Anas boscas, has been the most popular (Dooley and Koppányi, 1929; Johansen and Krog, 1959; Johansen and Aakhus, 1963; Johansen, 1964). Other birds have also been used. Besides the domestic duck Scholander (1940) examined the diving responses of two species of penguins, the macaroni, Eudyptes chrysolphus, and the gentoo, Pygoscelia papua. Also, in a much earlier study Noël Paton (1927) studied the mute swan, Cygnus olor, and the great cormorant, Phalacrocorax carbo.

Studies on maximum diving depths of non-mammalian diving vertebrates

are scarce. Landis (1965), working in a diving chamber, observed a green sea turtle, Chelonia mydas, feeding at a depth of 290 meters. The Galapagos marine iguana usually never descends deeper than 10 meters (Hobson, 1965). Little is known about the diving depths of sea snakes.

Diving birds normally make only shallow, short-duration dives. However, Schorger (1947) reported the common loon, Gavia immer, and the old-squaw, Clangula hyemalis, entangled in fishing nets at a depth of 60 meters. More recently, Kooyman et al. (1971a) recorded emperor penguins, Aptenodytes forsteri, at a depth of 265 meters. The longest duration of a dive for the emperor penguin was 18 minutes.

Most studies on non-mammalian diving vertebrates have emphasized the classic physiological responses to diving. It was shown that all of the animals underwent some form of bradycardia, exhibited extensive peripheral and moderate visceral vasoconstriction and maintained anaerobic glycolysis for extended periods of time.

With possibly one exception (Wolf, 1933), there seems to have been no attempt to correlate any anatomical data, especially at the microscopic level, with the physiological responses to diving in the non-mammalian diving vertebrates. This is the point at which a dichotomy between mammalian and non-mammalian diving studies is most profound. Since the 1920's there has been a definite attempt to correlate mammalian diving responses with anatomical data.

The first studies of any consequence on non-marine mammalian divers utilized the muskrat, Ondatra zibethica (Koppányi and Dooley, 1929; Irving,

1938). Irving (1937) and Irving and Orr (1935) also investigated the diving responses of the beaver, Castor canadensis. As with studies of non-mammalian divers, these investigations emphasized physiological responses and ignored correlative anatomical features.

Most mammals are terrestrial, having evolved to this state from their origins as sea dwelling creatures. Marine mammals are unique among their class in that they are the only mammals to have returned to a marine environment from a terrestrial one (Howell, 1930). In spite of this shift of habitat, they have retained certain basic mammalian physiological characteristics such as the breathing of air and the nursing of young. However, they also became remarkedly adapted for survival in an aquatic environment. Included among these adaptations are the swimming and deep diving prowess of the sperm whale, Physeter catodon (Heezen, 1957), the sonar capabilities of the bottlenose porpoise, Tursiops truncatus (Kellogg, 1961), and the blubber and heat-controlling (counter-current) vessels of pinnipeds and cetaceans in general (Scholander and Schevill, 1955).

The ability of certain marine mammals to dive to great depths and to remain submerged for extended periods of time has long been known to man. The cetaceans are probably the deepest divers among marine mammals. Ommanney (1932) stated that whales probably did not dive to depths much in excess of 130 feet. However, this has become a vast underestimate. Laurie (1933) reported blue whales, Balaenoptera musculus, at depths of 100 meters. More recently it has been reported that sperm whales became entangled in submarine cables at a depth of 1130 meters (Heezen, 1957). Among the smaller

cetaceans, the bottlenose porpoise has been observed to dive to a depth of 170 meters (Ridgeway, 1966).

Compared to cetaceans, pinnipeds are not normally known as deep divers. For instance, a saddleback or harp seal, Pagophilus groenlandicus, was caught in nets off Norway at a depth of 600 feet (Nansen, 1925). However, one pinniped, the Weddell seal, Leptonychotes weddelli, is a definite exception to this statement. DeVries and Wohlschlag (1964) reported that the Weddell seal could dive to a depth of 350 meters. More recently Kooyman (1966), utilizing a self-contained depth-recording device strapped to the back of a Weddell seal, measured the freely diving animal to a depth of 600 meters. Kooyman et al. (1970b) also observed a Weddell seal to remain submerged for as long as 70 minutes.

Since the diving prowess of marine mammals has been known and marveled at for many years, there have been many studies attempting to measure empirically this ability. Joylet (1893) was the first to look systematically at the diving responses of a marine mammal. He measured the lung-ventilation and tidal volume in the bottlenose porpoise.

Following Joylet, there were many studies dealing with various anatomical features of the respiratory systems of different marine mammals. Some of the early studies on odontocetes were those of Barbosa (1914), Fiebiger (1916), Neuville (1921, 1922, 1923) and Lacoste and Baudrimont (1926) on the Mediterranean dolphin, Delphinus delphis. Also, Baudrimont (1929, 1932) and Lacoste and Baudrimont (1933) investigated the lungs of the porpoise,

Phocoena communis. Wislocki (1929) and Huber (1934) studied the lungs of the bottlenose porpoise, while Bonin and Belanger (1939) examined the lungs of the beluga, Delphinapterus leucas.

Early histological studies of mysticetes were undertaken by Laurie (1933) and by Haynes and Laurie (1937) on the blue whale, the humpback whale, Megaptera nodosa and the southern right whale, Balaena australis.

More recent research on cetacean lungs has included the comparative histological study of the lungs of the blue whale, the finback whale, Balaenoptera physalus and the sperm whale as well as the lungs of the smaller odontocetes by Wislocki and Belanger (1940). Wislocki (1942) alone studied the lungs of the harbor porpoise, Phocaena phocoena, and compared them to the lungs of other dolphins and porpoises. Murata (1951) and Engel (1954) compared the respiratory tissues of various odontocetes and mysticetes. Goudappel and Slijper (1958) examined the microscopic structure of the lungs of the bottlenose whale, Hyperoodon ampullatus. Bourdelle and Grassé (1955) presented a very detailed description of various aspects of the anatomy of the cetacean respiratory system.

Very few morphological studies have been conducted on the Sirenia. The first was that of Pick (1907) on the Halicore dugong, Dugong dugon. Hill (1945) dissected two dugongs and commented on the anatomy of their respiratory system. The Florida manatee, Trichechus latirostris, has been investigated by Wislocki (1935), Quiring and Harlan (1953) and by Scholander and Irving (1941). This last study emphasized physiological rather than anatomical parameters.

One marine mammal not heretofore mentioned is the sea otter, Enhydra

lutris, a member of the family, Mustelidae. Its normal environment encompasses the shallow waters off the west coast of North America (Kooyman and Andersen, 1969). Because of their easy accessibility, the sea otter colonies have been reduced to near extinction by groups seeking the animals' pelts for commercial purposes. The sea otter is now an endangered species and for this reason few animals have been made available for studies of its diving ability. Hence, little is known about the anatomy of its respiratory system. Brown (1958) made marco resin casts of its lungs and bronchi. More recently, Tarasoff and Kooyman (1973a, 1973b) have completed an extensive study dealing with the gross and mesoanatomy of the lungs and bronchi of the sea otter, while Denison and Kooyman (1973) have investigated the histology of the lung.

Early studies on the respiratory system of Pinnipedia were much more cursory than those dealing with Cetacea. Most of these were concerned with various gross anatomical features of the respiratory system of different pinnipeds. Owen (1830) and Bronn et al. (1874-1900) made reference to the common harbor seal, Phoca vitulina. Bronn also mentioned the lungs of the harp seal, the bearded seal, Erignathus barbatus, and the grey seal, Halichoerus grypus. Hepburn (1896) also investigated the grey seal. Murie (1871, 1874) studied the gross anatomy of the walrus, Odobenus rosmarus and the stellar sea lion, Eumetopias jubata. Dieuzeide (1927) dissected the Mediterranean monk seal, Monachus monachus and Howell (1929), the ringed seal, Phoca hispida and the California sea lion, Zalophus californianus.

More recently, others have looked at pinniped respiratory systems in

greater detail. Zeek (1951) described the double trachea in the South American sea lion, Otaria byronia. Brown (1954) and Pizey (1954) made casts of the lungs of the harbor seal, and Blessing (1969) studied the microscopic structure of its lung. Slijper (1958) obtained relative lung weights in several species of seals and commented on the left/right symmetry of these organs in each species. King and Harrison (1961) described the lung structure of the Hawaiian monk seal, Monachus schauinslandi. Sokolov et al. (1971) compared the lungs and tracheae of the Bering Sea pinnipeds, while Kuzin (1970) investigated the lobe structure of fur seal embryos. Denison et al. (1971) studied the bronchial tree structure of the California sea lion. Schneider (1962, 1963) conducted an extensive comparative study of the larynxes of several pinnipeds. Probably the most complete histological study on a pinniped lung was that of Belanger (1940) on the harbor seal, done as part of a comparative study of various marine mammals. Denison and Kooyman (1973) have studied the small airway structure of several diving mammals.

The four monotypic species of the Lobodontini tribe of Phocidae, or true seals, inhabit the pack ice, fast ice and waters surrounding the Antarctic continent. In addition to the Weddell seal, these are the crabeater seal, Lobodon carcinophagus, the leopard seal, Hydrurga leptonynx, and the Ross seal, Ommatophoca rossi. Each of these species exhibits unique adaptations to its polar environment. The diving ability of the Weddell seal is one such adaptation.

It is interesting that the four Antarctic seals living in the same general oceanic environment should differ so markedly in diving capabilities. This feature

probably is related to feeding habits. With the exception of the Weddell seal, the Antarctic seals are considered to be shallow divers. Thus, there should be some anatomical characteristics allowing for this proficiency in deep diving in the Weddell seal that probably are not to be found in the other species. At least some of these anatomical characteristics would be exhibited in the respiratory system of this animal.

Most of the studies to date have dealt with only the gross anatomy of the respiratory system (Hepburn, 1912; Murphy, 1913; Nishida and Ameniya, 1962; King, 1968, 1969; Piérard, 1969) or were conducted incidental to studies of diving physiology (Kooyman et al., 1970a). However, a complete anatomical investigation of this system in the Weddell seal, or in any of the other three species, has yet to be undertaken.

In this study the gross and microscopic anatomy of the respiratory systems of the deep diving Weddell seal and the shallow diving crabeater seal will be described and compared. These findings then will be correlated with the known physiological data in an attempt to explain the difference in diving abilities between these two closely related species of Antarctic seals.

CHAPTER II

MATERIALS AND METHODS

Materials

The lungs, tracheae and upper respiratory passages of 11 Weddell seals and two crabeater seals were utilized in this study. The Weddell seals were captured near McMurdo Station, Ross Island, Antarctica, either during the months of October, 1969 and 1971 or during November, 1972. The crabeater seals were captured during the months of January-February, 1973, by personnel based on the USCGC Burton Island operating off the Oates and Pennell Coasts on the Pacific Ocean side of the Antarctic continent. The age, sex, and specimen catalog numbers are listed in Table 1.

Methods

Capture and Anesthetization

Weddell seals. The 1969 animal was provided by the New Zealand Antarctic Research Program. The Weddell seals to be autopsied on the ice were captured using the technique of Stirling (1966). Animals collected during the 1971 season were anesthetized with an intramuscular injection of the experi-

TABLE 1

ANIMALS UTILIZED IN STUDY

Species	Specimen Number	Age	Sex
Weddell seal Leptonychotes weddelli	Z-2	Adult	Male
" "	Z-4	Pup (3 days postnatal)	Male
" "	Z-7	Yearling	Male
" "	Z-8	Adult	Male
" "	Z-12	Adult	Female
" "	Z-13	Fetus (full term)	Female
" "	Z-15	Pup (5 days postnatal)	Male
" "	Z-28	Adult	Female
" "	Z-29	Adult	Female
" "	Z-30	Adult	Male
" "	Z-31	Pup (4 days postnatal)	Female
Crabeater seal Lobodon carcinophagus	Z-34	Adult	Male
" "	Z-35	Adult	Female

mental anesthetic CI-744 (Parke, Davis and Co.). The animals collected during the 1972 season were anesthetized with an intravenous injection (dorsal epidural vein) of 10-15 cc phencyclidine hydrochloride (Sernylan; Parke, Davis and Co.) in combination with 5-10 cc promazine hydrochloride (Sparine; Wyeth Laboratories). Intramuscular or intravenous injections of 30,000-60,000 USP units of heparin (Liquaenin Sodium "10"; Organon, Inc.) were administered during the anesthetization process.

Crabeater seals. The crabeater seals collected for autopsy were captured and anesthetized on the ice using the techniques of Cline et al. (1969), by which the animals were administered with injections of Sernylan and Promazine in dosages comparable to those given to the Weddell seals.

Autopsy

Weddell seals. After complete anesthetization, the animals were exsanguinated through the common carotid arteries. The lungs and tracheae were excised immediately and the several heads bisected para-sagittally to insure fixation of the upper respiratory passages. Tissues for light and electron microscopic study were preserved immediately in the appropriate fixative. Specimens for gross and mesoanatomical study were chilled and returned promptly to the laboratory at McMurdo Station for special processing, e.g., inflation-fixation, vascular injection.

Crabeater seals. After being anesthetized on the ice, the unconscious animals were transferred by helicopter to the ship for autopsy. The autopsy procedure was similar to that described for the Weddell seal.

Embalming

Weddell seals. The Weddell seal pups selected for embalming were transported unanesthetized to the anatomical laboratory at McMurdo Station. The animals were anesthetized with intravenously administered (dorsal epidural vein) sodium thiopental and the common carotid arteries exposed. Each vessel was doubly cannulated with the proximal cannulae directed toward the heart and the distal cannulae directed toward the head. The animals were then perfused through the distal cannulae with heparinized phosphate buffered saline (PBS); the proximal cannulae were opened to effect exsanguination. The PBS perfusion was continued until only blood tinged perfusate flowed from the proximal cannulae. The embalming process was completed by a second perfusion with 20% neutral buffered formalin. All perfusion fluids were administered under a three feet gravity head to insure adequate perfusion pressures.

Crabeater seals. The embalming procedure used for crabeater seals was comparable to that described above.

Packing and Shipping

All embalmed animals and autopsy specimens were doubly packed in heat sealed plastic bags to prevent drying and distortion. The plastic sealed specimens were then packed in plywood crates for shipment to the United States. All shipping crates were insulated with styrofoam to prevent freezing and overheating of the specimens during transport. All critical tissues (e.g., electron microscopic samples, some specially fixed tissues and tissues for surfactant assay) were hand

carried by the field party personnel upon their return to the United States.

Histological Processing

Weddell seals. Tissues for light microscopic study were fixed in 10% neutral buffered formalin, Bouin's, Carnoy's II, Helly's, Zenker's and 4% cacodylate buffered glutaraldehyde, pH 7.4. All tissues were routinely processed in paraffin. Sections were stained with hematoxylin and eosin, orcein, PAS (periodic acid-Schiff's) and the Bodian techniques.

Tissues for electron microscopy (EM) were prepared in duplicate. One series was always preserved in 4% cacodylate buffered glutaraldehyde, pH 7.4 before being post-fixed with Palade's osmium mixture. Duplicate specimens were fixed with Palade's osmium mixture only. All EM specimens were washed and stored in the appropriate buffer until final processing. Subsequent processing for EM examination was performed by other investigators.

Crabeater seals. Tissues for light microscopy were preserved in 10% neutral buffered formalin only. Laboratory facilities aboard the USCGC Burton Island limited severely the variety of histological procedures employed and precluded collection of specimens for electron microscopy.

Special Procedures

Inflation. Weddell seal lungs, which were removed in toto and returned fresh to the laboratory, were weighed and then fixed in the inflated state using standardized conditions. The inflation-fixation procedure was a modification of the technique employed by Heard (1958). Inflation was effected by cannulating

the primary bronchus and infusing 10% neutral buffered formalin. A 25 cm column of formalin was maintained in the cannulation apparatus to insure a constant inflation pressure. The lung and infusion apparatus was allowed to stand for 24 hours to insure complete expansion. All of the laboratory processed Weddell lungs were enclosed in loosely fitting plastic bags to prevent excessive drying.

The carefully standardized inflation procedures used for the Weddell seals at McMurdo Station could not be applied to crabeater specimens processed aboard ship. Therefore, the lungs were only partially inflated with 20% formalin administered through the primary bronchi. The bronchi of these partially inflated lungs were clamped and the organs then were immersed in 20% formalin to complete hardening.

Volume determinations. Following inflation-fixation, the volume of the Weddell seal lungs was determined by two methods. One method utilized was direct measurement of the volume of water displaced by the submerged lung. In the second method, the volume was calculated from the differences in lung weight obtained by weighing in air and during total submersion.

Since crabeater lungs were not inflated under standardized conditions, no attempts were made to determine lung volumes.

Metal casting. Pulmonary segments from Weddell and crabeater lungs were processed separately in the following manner for mesoanatomical study of the bronchial trees. Each segment was dissected free from the lung proper and the bronchus cannulated. The cannula was connected to a pyrex funnel by means of a small piece of rubber tubing. The apparatus was suspended from a ring stand

with the lung segment completely immersed in a water bath. The entire apparatus was placed in a large drying oven maintained at a constant temperature of 74°C. After 10 days at this temperature it was assumed that the lung segment and the ring stand apparatus had stablized temperatures of 74°C. Liquid Wood's metal alloy (Baker Chemical Co.), melting point 64°C, then was poured into the segment via the attached funnel. The entire assembly then remained in the oven at 74°C. At this temperature the Wood's metal remained in the liquid state and slowly displaced the fluid and air in the bronchial tree portion of the segment. After seven days the apparatus was removed from the oven. The final solidification of the Wood's metal and maceration of the soft tissue followed the technique of Peterson (1935).

Surfactant determinations. Lung samples from three Weddell seals (Z-29, Z-30, Z-31) were obtained at autopsy and were frozen immediately without fixation at -79°C. These specimens were packed in dry ice and returned to the United States. Upon receipt in the home laboratory, they were assayed for surfactant activity according to the method of Greenfield (1973).

Injections. The heart-lung complexes, including the thoracic aortas, from two Weddell seals (Z-30, Z-31) were utilized for injection studies.

The bronchial arteries were dissected free of their surrounding connective tissue investments. Each vessel was cannulated near its origin from the thoracic aorta. India ink was injected into the vessels to demonstrate their pattern of distribution. The pulmonary vessels of selected lung lobes were cannulated and then injected with latex solution (Wards' Natural Science Establishment, Inc.).

Photography. All photomicrographs were taken with a Wild M20 microscope fitted with an MKa4 automatic camera attachment.

CHAPTER III

RESULTS

The respiratory system of Phocidae is typically mammalian in its over-all organization. The air conducting portion consists of the nasal cavities, nasopharynx, larynx, trachea and bronchi. The respiratory portion of the system is composed of the lungs. One major variance in its anatomy is the fact that there are no paranasal sinuses present in the skull.

Weddell Seal, Leptonychotes weddelli

Nasal Cavities

Gross anatomy. The two nasal cavities, those chambers rostral to the choanae, are dominated by the highly elaborate, labyrinthine-like turbinates situated on their lateral walls. These structures begin as cylindrical elongations approximately 4 cm caudal to the anterior nares (Fig. 2). The area immediately caudal to the anterior nares and rostral to the turbinates is covered with longitudinal folds of mucosa having the same dark gray to black color as the external skin.

The rostro-caudal length of the nasal cavities relative to its dorso-ventral height is not as great in an adult animal as it is in a pup. The greatest differences in this dimension are seen in the areas rostral and caudal to the turbinate complexes (Fig. 2).

The nasal septum forming the medial walls of the two cavities is characterized by a raised area of multi-folded soft tissue on its rostral, cartilaginous half (Fig. 3). This area is juxtaposed to the anterior elongations of the turbinates on the lateral wall. The most rostral portions of the septum are covered with the same type of darkly pigmented skin as the lateral wall. The caudal half (bony septum) near the choanae appears smooth with numerous small blood vessels visible through its covering epithelium.

Microscopic anatomy. The anterior portion of the lateral wall is covered with the same darkly pigmented, keratinized, stratified squamous epithelium that covers the external nares. Numerous melanocytes are present in the basal cell layer, but other specialized integumentary structures (hair follicles, sebaceous glands, sweat glands) are not present. Gradual changes occur in the mucosa in the region of the longitudinal folds. These are the loss of pigment and a gradual transition to a moist type of stratified squamous epithelium. The turbinates mark the beginning of the respiratory region of the nasal cavities. Therefore, the predominant type of covering is typical respiratory epithelium, i.e., pseudostratified ciliated columnar epithelium with goblet cells. However, the medial, free surface of the turbinates, facing the nasal septum, exhibits areas of metaplasia where the respiratory epithelium is intermixed with a transitional stage of stratified squamous epithelium (Fig. 4). This metaplastic change is not as evident in the posterior turbinate region. The more deeply situated areas of the turbinates are covered with respiratory epithelium. Goblet cells are not as plentiful in these areas as they are in the more exposed regions of the mucosa. The post-turbinate area is

covered by typical respiratory epithelium which continues into the nasopharynx. Goblet cells are not as plentiful in these areas as they are in the more exposed regions of the mucosa.

The lamina propria of the lateral wall is characterized by numerous small blood vessels and is bound to the underlying skeletal structures by collagenous fibers to form a typical muco-perichondrium or muco-periosteum. Elastic fibers are found throughout the lamina propria and continue into the nasopharynx. The lamina propria in the area of the turbinates exhibits additional structures which are not found in the pre- and post-turbinate areas. The structures restricted to this area are large venous spaces and muco-serous glands (Fig. 5).

With the exception of the pigmented, anterior-most portion (rostral half) the entire cartilaginous septum is covered with moist stratified squamous epithelium. The caudal, bony portion of the septum is covered with pseudostratified ciliated columnar epithelium with goblet cells.

The lamina propria contains many small blood vessels and muco-serous glands. The lamina propria in the region of the raised areas of soft tissue contains large, compound, tubulo-acinar glands of the muco-serous variety. These glands extend well into the muco-perichondrium and what appears to be the main excretory ducts of these glands are lined with typical respiratory pseudostratified ciliated columnar epithelium. The multi-folded region also exhibits numerous aggregations of lymphocytes which are not found elsewhere in the medial wall (Fig. 6).

The presence of olfactory mucosa in the epithelium of the nasal cavities was difficult to ascertain, even when utilizing a stain technique specific for ner-

vous tissue. This seems to indicate only a rudimentary development of olfactory receptor cells in the Weddell seal.

Nasopharynx

Gross anatomy. The nasopharynx, extending from the choanae rostrally to the caudal border of the soft palate, is the respiratory portion of the pharynx. The soft palate does not have a uvula. Instead, its caudal, free edge presents a mid-sagittal notch into which the epiglottis will fit. This over-all arrangement gives the nasopharynx a relatively long, narrow lumen, a characteristic found in other pinnipeds and cetaceans.

The walls of this chamber are relatively smooth except in two areas. Located in each lateral wall, at about the level of the junction of the hard and soft palates, is the rather small opening of the Eustachian tube. The other rough area is formed by the exceedingly large pharyngeal tonsils (usually greater than 7.5 cm x 6.25 cm) imbedded within the dorsal wall. These tonsils are easily distinguished from the pale yellow tissue surrounding them.

Microscopic anatomy. Pseudostratified ciliated columnar epithelium with goblet cells covers the walls of the entire nasopharynx.

The lamina propria contains a rather small number of muco-serous glands. Elastic fibers present in this layer extend into the laryngeal region forming a continuous band through this portion of the respiratory passages.

The pharyngeal tonsils exhibit numerous branched crypts and the entire free surface of the tonsils, including the crypts, is covered with pseudostratified

ciliated columnar epithelium. These tonsils contain the typical aggregations of lymphatic nodules seen in other species (Fig. 7).

The submucosal layer deep to the tonsils is predominantly areolar connective tissue containing medium sized blood vessels and isolated groups of fat cells. Mucous glands are also present in the more superficial layer of submucosa. These glands appear to extend into the tonsillar area, but they are separated from the lymphatic tissue by a connective tissue septum (Fig. 7).

Larynx

Gross anatomy. A comprehensive study of the gross anatomy and function of the larynx of the Weddell seal has been completed by Piérard (1969). Therefore, only the histological aspects will be considered here.

Microscopic anatomy. Histologically, the larynx is characterized by two types of epithelium. That area extending from the top of the epiglottis to just caudal to the vocal folds is covered with stratified squamous epithelium. Caudal to the vocal folds the epithelium changes to the pseudostratified ciliated columnar type with goblet cells typical of the remaining portion of the respiratory system.

The lamina propria contains abundant elastic fibers as well as the usual collagenous fibers. Mixed glands, predominantly mucous, but with serous demilunes, are present in the lamina propria immediately rostral to that area corresponding to the ventrical in the human larynx. Elastic cartilage is seen in the epiglottis connected to the lamina propria by a muco-perichondrium.

The laryngeal cartilages are composed of hyaline cartilage while the in-

trinsic laryngeal musculature consists of skeletal muscle.

Trachea

Gross anatomy. The trachea of the Weddell seal is relatively long, averaging 40-45 cm in length in the adult specimens used in this study (Fig. 8). In cross section the trachea appears as a flat, bow-shaped structure. It contains separate, flattened plates of hyaline cartilage, from the caudal border of the larynx through its bifurcation into the two primary bronchi. The ends of the cartilaginous plates diverge in a dorso-lateral direction thus producing a wide dorsal wall composed of soft tissue only (Fig. 9).

Microscopic anatomy. The mucosa of the trachea is characterized by a pseudostratified ciliated columnar epithelium containing goblet cells.

The collagenous and elastic elements of the underlying lamina propria are arranged in a predominantly circular pattern. The deeper layers of the lamina propria are not sharply demarcated from the adjacent submucosal layer.

The submucosa is composed primarily of areolar connective tissue and contains the usual medium sized blood vessels, tracheal glands and unusual gland-like structures which are hereafter referred to in this study as "diverticula" (Fig. 10). These gland-like diverticula do not appear to have been reported previously. In this section of the results, only the basic macro- and microscopic relationships between the diverticula and tracheal glands will be fully described. Serial sections and reconstructions indicate that the majority of the tracheal glands are simple, branched, tubulo-alveolar structures. The epithelium lining the short excretory

ducts is a pseudostratified non-ciliated columnar epithelium with typical goblet cells. The tubulo-alveolar secretory portions are usually composed of mucous secretory cells only, but pure serous and sero-mucous alveoli are present in small numbers. Although most of the diverticula found in the tracheal mucosa are directly associated with the secretory portion of the gland proper, their large size (macroscopically visible) and simple squamous epithelial lining do not suggest a secretory function. Glands and diverticula are usually closely associated with each other throughout the length of the trachea although there is a definite structural relationship in that the truly glandular components predominate in the proximal part of the trachea while the diverticula or non-glandular portions are more in evidence in the distal trachea. A few of the tracheal diverticula are independent of any glandular component and communicate directly with the tracheal lumen via their own ducts. The diverticula are better developed in the more distal regions of the respiratory passages; therefore, their cytology (histochemistry and ultrastructure) will be described with these areas.

The flattened plates of hyaline cartilage are located peripheral to the submucosa. The fibrous layer of perichondrium surrounding each piece of cartilage blends into the adjacent collagenous connective tissue. Elastic fibers are not in evidence in the fibrous perichondrium or in the immediately adjacent connective tissue; however, in that area between cartilaginous plates, there is a distinct layer of elastic fibers extending between adjacent plates. This layer of elastic fibers appears to bifurcate, but it cannot be traced as a discrete layer around the cartilage (Fig. 11).

The soft tissue comprising the dorsal wall of the trachea consists primarily of bundles of smooth muscle fibers having a transverse orientation. Few glands and diverticula are present in the submucosa covering the non-cartilaginous areas.

The trachea of a Weddell seal pup is similar in its histological appearance to that of an adult, with the major exception being that the tracheal glands seem to be much more secretory in nature, and the number of diverticula present is not nearly as great as in an adult.

Bronchial Tree

Gross anatomy. The two primary bronchi of the Weddell seal are formed by the bifurcation of the trachea. These bronchi are characterized by incomplete rings of hyaline cartilage having a more circular shape than the flattened cartilaginous plates found in the trachea (Fig. 12). As in the trachea, the dorsal wall of the primary bronchi is completed by non-cartilaginous tissue extending between the ends of the incomplete cartilaginous rings.

Each primary bronchus divides into secondary, or lobar, bronchi, four such bronchi being found on the right side and two on the left. Each lobar bronchus supplies a distinct lung lobe, and each lobar bronchus subsequently divides into the segmental bronchi supplying the "bronchopulmonary" segments of that lobe. The number of segments, and, consequently, the number of segmental bronchi, vary among lobes. Metal castings have shown that within the lung parenchyma the segmental bronchi continually subdivide until 15-25 generations of bronchi have been formed. The most distal bronchi branch to form numerous bronchioles. Each

bronchiole is that portion of the air conducting system entering a lung lobule, the functional unit of the lung (Ham, 1969).

The cartilaginous support of the lobar and segmental bronchi is seen as irregularly shaped rings completely encircling the lumen of the bronchi (Fig. 12). The more distal bronchi do not contain these complete rings of cartilage, but rather, are characterized by irregularly shaped plaques situated obliquely within their walls.

Microscopic anatomy. Histologically, the primary bronchi are very similar to the trachea and are lined by respiratory epithelium. The relative amount and distribution of elastic fibers in the lamina propria are like those found in the trachea. The submucosa still is quite vascular, but is devoid of smooth muscle. The soft tissues filling the dorsal gap between the free ends of the cartilaginous rings retain their predominance of smooth muscle.

The major difference is seen in the organization of the gland-diverticula complex. In this region the non-secretory diverticular component of the complex is much more pronounced. The diverticular complexes are scattered throughout the submucosa. Their epithelium remains low cuobidal or simple squamous.

Beginning in the lobar and segmental bronchi, and continuing through the bronchial tree, distinct changes are seen in the histological organization. These changes are condensed and presented here in tabular form.

(1) The epithelium remains pseudostratified ciliated columnar through the terminal bronchioles, where the epithelium changes to a high cuboidal without cilia. The number of goblet cells present in the epithelium steadily decreases as the more distal bronchi are approached.

(2) The regularly shaped rings of cartilage are replaced by plaques having very irregular shapes. When seen in cross section, it appears that several pieces of cartilage encircle the lumen of a bronchus (Fig. 13). However, this is due to the extension of the cartilaginous plaques some distance along the bronchus.

(3) The diverticula become much larger and more numerous. The cuboidal or squamous cells lining their lumina exhibit little, if any, secretory function. Most of the secretory activity is found in the cuboidal cells lining the ducts of the diverticula which open into the lumina of the bronchi.

(4) The distribution of elastic fibers is more extensive. A thick, longitudinally oriented layer is still seen in the lamina propria. In addition, the distinct, but discontinuous, elastic layer between adjacent cartilages in the primary bronchi becomes continuous and can be traced around successive cartilages. The elastic fibers, therefore, form a lattice-like network throughout the bronchial tree (Fig. 14).

(5) The smooth muscle present in the dorsal portion of the trachea and primary bronchi forms a layer completely encircling the lumen in the rest of the bronchial tree. This smooth muscle layer lies between the mucosa and the more peripherally situated diverticular complexes and cartilages (Fig. 15).

These data are summarized in Table 2.

Pleura

Gross anatomy. The pleura completely lines the pleural cavity. Its visceral portion covers the entire lung surface and is continuous with the parietal pleura at the root of the lung.

TABLE 2

HISTOLOGICAL FEATURES OF WEDDELL SEAL TRACHEO-BRONCHIAL TREE

Organ	Epithelium	Goblet Cells	Cartilage	Diverticula	Elastic Fibers	Smooth Muscle
Trachea	Respiratory	++++	++++	++	++	-
Bronchi	"					
primary	"	++++	++++	++	++	-
lobar	"	++++	++++	+++	+++	++
segmental	"	++++	++++	+++	+++	++
distal	"	+++	+++	++++	+++	+++
Bronchiole	"	++	++	+++	++	++++
Terminal Bronchiole	"	+	++	+++	++	++++
Respiratory Bronchiole	Tall Cuboidal (no cilia)	-	-	-	+	++++

Respiratory Epithelium = Pseudostratified Ciliated Columnar
Plus (+) = Relative amounts of components present

Microscopic anatomy. The stroma of the visceral pleura is characterized by a distinct layer of elastic fibers situated in its superificial margin just beneath the mesothelial lining (Fig. 16). Bundles of smooth muscle are scattered throughout the areolar connective tissue of the pleura. Numerous small blood vessels are also present. The pleural stroma is continuous with the connective tissue septa dividing the lung into lobules (Fig. 16). These septa are composed of areolar connective tissue with smooth muscle cells and blood vessels, but very few elastic fibers are seen.

Lung

Gross anatomy. The lungs of the Weddell seal are flattened dorsoventrally and reflect the dorsoventrally flattened thoracic cavity and the obliquely positioned diaphragm. The larger right lung consists of cranial, middle and caudal lobes separated by an oblique and horizontal fissure (Fig. 17). There is also a small, accessory lobe on the mediastinal surface of the middle lobe (Fig. 18). This accessory lobe, first described by Hepburn (1912), exhibits two distinct segments separated by a pleural band (Fig. 18).

The smaller left lung has only a cranial and a caudal lobe separated by an oblique fissure. In addition, the inferior portion of the cranial lobe is incompletely divided by an intralobar fissure into an indistinct third lobe (Fig. 19). This partial lobe might possibly be homologous to the cardiac lobe sometimes seen in man.

The interlobar fissures of both lungs extend to the hila. The marked separation of the lung parenchyma by connective tissue septa into segments

and lobules is visible at the lung's surface (Fig. 19). Some of the septa forming the different segments have separated along the edge of the lobes, indicating the possible beginnings of accessory fissures (Fig. 19).

Table 3 summarizes the lung weight to lung volume relationships of four specimens. Both lungs were utilized from the first animal, while either the right or left lung only was used from the other three animals. The lungs excluded from the weight-volume studies were utilized for other special procedures.

The specific gravity of the lung tissue was assumed to be 1.0 (based on standards accepted by pulmonary function laboratories). All of the lung tissue volumes calculated by the fluid displacement method were greater than the measured fresh lung weight. The datum for Z-29 showed the greatest variance. Conversely, all of the volumes calculated by the direct weighing method, except one, were less than the measured fresh lung weight. Again, Z-29 was the exception, being the only specimen showing a greater fresh lung weight.

Microscopic anatomy. The nomenclature for the intralobular portions of the mammalian lung varies greatly in different publications. For this reason a uniform nomenclature is to be used when referring to the various types of intralobular bronchioles and ducts described in this study. Figure 1 indicates the terminology adopted for this study.

The functional portion of the lung of the Weddell seal can be described histologically by examining the organization of a typical lung lobule. This structure is the smallest dissectable unit of the lung, having a pyramidal shape (Fig. 1). As first described by Denison and Kooyman (1973), a lobule is approxmately

TABLE 3

WEDDELL SEAL LUNG: FLUID AND TISSUE VOLUMES

Specimen	Fresh Wt.	Infusate Vol.	Total Vol. by Weight	Total Vol. by Displacement	Lung Tissue Vol. (Wt.)	Lung Tissue Volume (Dspl.)	V/W (Wt.)	V/W (Dspl.)
Z-28								
Rt. Lung	2352	3953	6241	6840	2288	2887	0.97	1.22
Lt. Lung	1878	3220	4894	5430	1674	2210	0.89	1.18
Z-29								
Rt. Lung	1521	2535	5093	5440	2548	1905	1.68	1.25
Z-30								
Lt. Lung	1362	2603	3676	4115	1073	1512	0.79	1.11
Z-31								
Rt. Lung	329	538	624	995	86	357	0.26	1.08

All weights in grams
All volumes in milliliters

Lung Tissue Volume = Total Volume - Infusate Volume

Lung Volume to Weight Ratio (V/W) = Lung Tissue Volume/Fresh Weight

1.5 x 2.0 mm in size and is surrounded by a thin, but distinct, layer of loose connective tissue composed mostly of collagenous fibers. Within the primary lobule, its supplying bronchiole branches to form 8-10 terminal bronchioles, each supplying a smaller, secondary lobule. Within a secondary lobule the terminal bronchiole branches into the respiratory bronchioles. Each respiratory bronchiole opens into the alveolar ducts leading into the alveolar sacs (Fig. 20).

The epithelium of the bronchiole entering a lung lobule, like that of the more proximal bronchial tree, is of the respiratory type. Numerous goblet cells are present throughout the epithelium (Fig. 21).

The hyaline cartilage found in the bronchioles consists of irregularly shaped plaques that do not completely encircle the lumen. It is situated peripheral to the submucosa (Fig. 22).

The diverticula are quite large and are extensive in distribution. At this level they are located on both the luminal and adventitial sides of the cartilage (Fig. 22). Their epithelium appears to be primarily simple squamous in nature with no demonstrable secretory function at the light microscopic level. Only the isolated cuboidal cells in the epithelium and the cuboidal cells in the submucosa show any secretory activity.

The terminal bronchioles retain the respiratory epithelium, but the number of goblet cells has greatly decreased (Fig. 23).

The cartilages of the terminal bronchioles are much smaller and less frequent in occurrence than in the more proximal portions of the bronchial tree. However, the irregular plaques still occupy enough of the wall to aid significantly in

the support of the lumen.

The diverticula of the terminal bronchioles are similar to those seen in the bronchioles in their size, distribution and cellular composition.

Within the respiratory bronchioles, the following major histological alterations have occurred:

(1) The lining epithelium has changed to a tall, simple cuboidal pattern (Fig. 24).

(2) No cilia are present along the free surface of the epithelial cells.

(3) Goblet cells are no longer present in the epithelium.

(4) Hyaline cartilage is absent from the walls.

(5) No diverticula or glands can be found in the walls.

These data are summarized in Table 2.

Elastic fibers in the intralobular bronchioles follow the same distribution pattern found in the proximal bronchial tree. The lattice-like network of fibers surrounding the cartilage extends as far as the terminal bronchioles. In the respiratory bronchioles the cartilage has disappeared. However, the elastic fibers have retained their organization first present in the primary bronchi by surrounding the thick layer of smooth muscle (Fig. 25). This network continues into the alveolar ducts.

Smooth muscle has become much more in evidence throughout the intralobular bronchioles. The distinct layer of smooth muscle found between the mucosa and cartilage of the bronchial tree has increased in thickness, and in the respira-

tory bronchioles this layer is quite thick and appears to be partially contracted in some areas (Fig. 26). The myo-elastic sphincters reported in odontocetes have not been observed in the Weddell seals used in this study.

Diverticula are the most striking histological features of the respiratory system of the Weddell seal. They first appear in the submucosa of the trachea, and then occur with increasing frequency throughout the bronchial tree as far as the terminal bronchioles. As previously stated, these structures appear to be modified muco-serous glands which have lost most of their secretory function.

In the trachea the diverticula are intermediate in morphology (Fig. 10). They still retain some of the characteristics of secreting glands, such as cuboidal epithelium containing secretory granules. However, it has been seen that in the various bronchiolar types nearer the alveolar sacs, the diverticula become much more numerous and elaborate in their arrangement. They are found throughout the terminal bronchioles and in many areas they completely encircle the cartilage plaques. Here, their epithelium appears to consist mostly of simple squamous cells having little, if any, secretory function (Fig. 27).

Electron microscopic examination of the diverticula from a limited amount of material will be discussed in Chapter IV.

Respiratory Portion of the Lung

Alveolar ducts. The alveolar ducts extending from the respiratory bronchioles are partitioned into numerous openings, each opening leading into an alveolar sac. These partitions are characterized by thick bundles of smooth muscle surrounded by the previously mentioned elastic fiber network (Fig. 28).

The epithelium of the alveolar ducts is of the simple squamous type.

Alveolar sacs. The alveolar sacs, opening from the alveolar ducts, are partitioned by thin walled septa into several alveoli having diameters between 50-150 micra (Denison and Kooyman, 1973).

A single capillary bed is present in an alveolar septum (Fig. 29). However, its engorgement with red blood cells gives the impression of the presence of a double capillary system similar to that seen in odontocetes and otarids.

Elastic fibers are scattered throughout the alveolar septa. The network of fibers described as present in alveolar ducts and more proximal bronchioles and bronchial tree is not found in the alveolar septa. Occasional smooth muscle fibers are visible in the alveolar septa (Fig. 30).

Cell types. Numerous cell nuclei are present in the septal walls. Electron microscopic studies of these cell types by Coalson (1973) will be discussed in Chapter IV.

Blood Supply of the Lung

The pattern of distribution of the pulmonary blood supply of the Weddell seal corresponds to that of the typical mammalian respiratory system. Dissections indicated that there is only one bronchial artery originating from the ventral surface of the thoracic aorta.

The pulmonary artery and its branches accompany the bronchial tree in its distribution into the respiratory portion of the lung. The pulmonary veins initially are interlobular in position.

India ink injection of the single bronchial artery indicates that this vessel supplies the caudal half of the trachea, the proximal portions of the lung parenchyma and stroma and at least part of the visceral pleura. The remaining lung tissue obtains its oxygenated blood from the pulmonary capillary beds.

Crabeater Seal, Lobodon carcinphagus

Nasal Cavities

Gross anatomy. The general organization of the nasal cavities of the crabeater seal is similar to that of the Weddell seal. The rostral portion of the chamber exhibits the same darkly pigmented stratified squamous epithelium devoid of sebaceous glands and hair.

The most striking difference in the gross anatomy of the nasal cavities of the two species is the distance from the anterior nares to the rostral border of the turbinates. In the crabeater seal this distance is almost 10 cm (Fig. 31). This length is more than twice that observed in the Weddell seal.

Microscopic anatomy. The turbinates have the same tortuous bony pattern (Fig. 31). However, the respiratory epithelium does not show the similar metaplastic areas of stratified squamous cells seen in the Weddell seal. Also, the presence of goblet cells in the mucosa is not evident. Numerous blood vessels, venous spaces and muco-serous glands are present in the lamina propria.

The histology of the nasal septum is comparable to that of the Weddell seal except that the only glands seen in the lamina propria or submucosa are in the region of the soft tissue swellings.

Nasopharynx

The nasopharynx of the crabeater seal is similar to that of the Weddell seal in most features. Its lining epithelium is pseudostratified ciliated columnar. Large, compound mucous secreting glands are found in the submucosa and occasionally extend into the surrounding skeletal muscle of the soft palate. A pharyngeal tonsil, similar in morphology but larger in size than the one found in the Weddell seal, is situated in the dorsal wall.

Larynx

A study of the gross anatomical structure of the larynx of the crabeater seal was not included in this study because a similar study was not completed on the Weddell seal. Histologically, the epiglottis is lined with stratified squamous epithelium. The lamina propria contains elastic and collagenous fibers. The submucosa is dominated by the same type of compound, tubular mucous glands seen in the nasopharynx.

Trachea

Gross anatomy. Like that of the Weddell seal, the trachea of the crabeater seal is also a long structure, being between 30-35 cm in length. In cross section the crabeater trachea is bow-shaped, especially in its proximal portion (Fig. 9). The distal portion of the trachea is more circular in cross section, closely resembling the proximal bronchi of the Weddell seal. The proximal cartilaginous plates are flattened like those in the Weddell seal, but their ends do not

diverge in the same manner. They have a more semi-lunar shape. The dorsal non-cartilaginous area consists of soft tissue like that of the Weddell seal.

Microscopic anatomy. Histologically, the only significant difference between the tracheae of the two species concerns the diverticula. In the crabeater seal these structures are not readily apparent in the submucosa (Fig. 32). Only mixed, muco-serous glands are seen. Also, no glands, whatsoever, were found in the dorsal trachea.

Bronchial Tree

Gross anatomy. The gross anatomy of the bronchial tree of the crabeater seal is representative of that of the Weddell seal. Both the branching of the different bronchi and the distribution of their cartilaginous rings follow the pattern seen in the Weddell seal.

Microscopic anatomy. The crabeater seal bronchial tree shows the same histological changes as were seen in the trachea. Beginning in the primary bronchi the submucosal glands begin to appear as mixed glands and diverticula. However, neither the number nor the size of the diverticular development is as great as in the Weddell seal. This alteration continues through the bronchial tree into the lung lobules. Throughout, the diverticula appear as expanded acinar or tubular shaped cavities (Fig. 33). The remaining histological features of the bronchial tree of the two species are similar.

Pleura

The visceral pleura and interlobular septa of the crabeater seal lung

exhibit the same general histological characteristics seen in the Weddell seal. One slight difference noted is that there are more elastic fibers in the submesothelial connective tissue.

Lungs

Gross anatomy. The lungs of the crabeater seal are dorsoventrally flattened in a manner similar to that of the Weddell seal. The right lung as a cranial and a caudal lobe separated by an oblique fissure extending to the hilus (Fig. 34). An incomplete intralobar fissure divides the inferior segments of the cranial lobe into an indistinct middle lobe (Fig. 34).

The left lung is composed of cranial and caudal lobes with an intervening oblique fissure extending to the hilus.

Incomplete inflation and distortion incurred during shipment prevented the photographing of the medial surface of the right lung and of both the medial and lateral surfaces of the left lung.

As in the Weddell lung, the parenchyma of the crabeater lung is divided by connective tissue septa into grossly visible segments and smaller lobules.

Microscopic anatomy. Histologically, some similarities and some major differences have been found in the lungs of the crabeater seal.

(1) The epithelium lining the different types of bronchioles corresponds to that found in the Weddell seal.

(2) The alveolar ducts, alveolar sacs and alveoli are, of course, lined with simple squamous epithelium. Neither electron microscopic examination nor surfactant assays were done on these cells.

(3) Hyaline cartilage is distributed through the terminal bronchioles.

(4) Diverticula are present, but they are not nearly as well developed as in the Weddell seal lung. They are found as far distal as the terminal bronchioles.

(5) Elastic fibers are more prevalent in the bronchiolar submucosa and especially within the alveolar septal walls (Fig. 35).

(6) Smooth muscle surrounding the different bronchioles and alveolar ducts is much thicker than in the Weddell seal. Smooth muscle fibers are occasionally seen in alveolar septa.

Blood Supply of the Lungs

The pulmonary blood supply is comparable to that of the Weddell seal and is typically mammalian in its architecture. The distribution pattern of the bronchial arteries is not known since fresh material forvascular injection was not available.

CHAPTER IV

DISCUSSION

Climatic Adaptations

The Weddell seal inhabits the fast (annual, semiannual or of indefinite duration) ice of the Antarctic continent and the adjacent subantarctic islands. Being essentially non-pelagic, this animal encounters the extremes of temperature and humidity as it lives through the year in the Antarctic environment. At McMurdo Station, where the animals utilized in this study were captured, the yearly mean temperatures range from a low of -50°C to a high of 0°C. The mean temperature in October and November (springtime), when the pods of animals are colonizing on the ice and the pups are born, averages -30°C. The relative humidity is usually less than 10% of saturation at these temperatures. The water temperature of McMurdo Sound is a relatively constant -1.81°C throughout the year (Littlepage, 1965). The respiratory system of the Weddell seal has adapted anatomically to permit the animal to survive under these harsh conditions.

The upper respiratory passages must initiate the saturation and warming of the inspired air to the inner core temperature of 37.2°C (Kooyman, 1968). According to Proetz (1951), inspired air undergoes turbulent flow during quiet breathing. This turbulence causes more contact between the inspired air and the

walls of the nasal passages. Since heat is transferred to inspired air by means of "turbulent convection" (Walker and Wells, 1961), the more contact that occurs, the more rapid will be the warming of the air. The elaborate folding of the nasal turbinates and the mucosa of the nasal septum of the Weddell seal permit maximum contact between air and respiratory mucosa. The extreme vascularization of the lamina propria and submucosa in this region supplies the heat necessary for this warming to occur.

The heating of the inspired air also facilitates the transfer of water from the mucosa to the air. Since warmer air can hold more water vapor than colder air, there is a continuous loss of water from the mucosa to the inspired air until an equilibrium of vapor pressure is established at the mucosa/inspired air interface. This transfer of water to the inspired air will, therefore, serve two purposes. First, it will saturate the dry, inspired air before it reaches the lung alveoli. Second, the transfer has a cooling effect on the mucosal surface. The latter will aid in the conservation of body water. This is an important consideration since the seals probably do not have an external source of drinking water, their water coming from either metabolism or diet.

During expiration this entire process is reversed. The warm, moist air from the lungs will lose heat to the respiratory mucosa cooled during the previous inspiration. The water vapor in the expired air will condense on the colder walls of the nasal passages.

Therefore, it can be seen that a countercurrent heat exchanger as described by Jackson and Schmidt-Nielsen (1964) is present in the respiratory

passages of the Weddell seal. However, some heat and water are still lost to the atmosphere due to the extremely cold temperatures encountered.

The crabeater seal will also encounter cold, dry air, and, its respiratory passages must function in a manner similar to those of the Weddell seal. Being pelagic, the crabeater seal will not be exposed to the same harsh temperatures the entire year. The temperature of the sea water throughout the pack ice is about $0^{o}C$, and the air temperature in this region ranges from 0° to $\pm 5^{o}C$. The humidity at these temperatures varies between 10 to 15 percent of saturation. This might account for the fact that the areas of stratified squamous cells seen in the nasal mucosa of the Weddell seal were not observed in the crabeater seal. The constant exposure of the Weddell seal to the extreme cold possibly causes enough irritation to initiate these metaplastic changes in the epithelium.

The difference in the distances between the external nares and the rostral edge of the turbinates of the two species cannot be accounted for functionally. The skull of a crabeater seal is larger than that of a Weddell seal when compared to respective body sizes (Bryden and Felts, 1973). A major portion of this difference is caused by the larger hard palate of the crabeater seal (Eastman, 1973). Both the midsagittal length from the rostral end of the hard palate caudal to the level of the fifth post-canine teeth and the width between the fifth post-canines are greater in the crabeater seal. These dimensions of the hard palate could account for the larger, pre-turbinate antrum seen in the nasal cavity of the crabeater seal, since this antrum is immediately dorsal to the hard palate. It is unlikely that this difference can be related to feeding habits since the crabeater

seal is a filter-feeder surviving almost exclusively on small krill (Bryden and Felts, 1973).

Diving Adaptations

In deep diving animals, including the Weddell seal, the two principal effects of pressure encountered at great depths are the deformation of body cavities containing gas and the increased partial pressures of the gases in these cavities (Kooyman, 1973). If the gases in the cavities do not remain in equilibrium with the ambient pressures, tissue damage and destruction will occur due to the increased pressure differentials. As the partial pressures of the gases in the cavities, including the air in the lungs, increase due to compression, nitrogen from the gas can be absorbed by the blood and nervous tissue of the animal. Upon decompression, if too rapid, this dissolved nitrogen can form bubbles in the blood and interstitial spaces. This condition of nitrogen narcosis, also known as the "bends" or Caisson Disease, can cause pain, paralysis and even death.

Except for the anatomy discussed above, most of the anatomical adaptations found in the respiratory system of the Weddell seal are related to its deep-diving ability and the accompanying physiological adjustments necessary to increase its diving time and to prevent nitrogen narcosis.

The most effective way to prevent gas deformation and absorption during a dive would be to eliminate the gas from the body before the dive commences. In phocids, including the Weddell seal, this is accomplished by several anatomical and physiological adjustments. The skulls of these animals do not contain any paranasal sinuses. This, of course, eliminates one major source of stored gas

subject to compression and deformation during a deep dive.

Scholander (1940) observed that the grey seal, Halichoerus gyprus, exhales prior to diving. He also showed that the lungs of marine mammals collapsed during a dive. This mechanism would remove all the alveolar air, including its nitrogen, from the pulmonary capillary beds, thereby preventing the absorption of the nitrogen by the blood as the depth of a dive increases.

How do these mechanisms relate specifically to the Weddell seal? Kooyman (1968) noted that they exhale before diving. By measuring the blood nitrogen tension levels of seals simulating dives ranging in depths from 30 to 272 meters, Kooyman et al. (1972) confirmed that Weddell seal lungs do indeed undergo compression collapse. An earlier study by Kooyman et al. (1971b) indicated that this alveolar collapse is probably completed at a depth of approximately 70 meters, thereby forcing the diving lung volume of air (averaging 11.6 liters) from the capillary beds.

The air forced from the alveoli must be accommodated by the dead air space of the bronchial tree and trachea. That the trachea of the Weddell seal remains patent during a dive to a depth of 306 meters was shown by Kooyman et al. (1970a). This study also indicated that the smaller bronchi and bronchioles remained open at this depth. These bronchioles were defined as being fifth generation branching. According to casts made of Weddell seal lung segments, this generation of branching would still be bronchial. However, since it has been seen that the bronchioles and terminal bronchioles also contain hyaline cartilage in their walls, the over-all effective dead air space volume would still be increased

accordingly to aid in air accommodation during compression collapse.

With a measured physiological dead space averaging 1.6 liters (Kooyman et al., 1971b), the question arises as to whether or not this volume can easily contain all of the air forced from the alveoli. Since Weddell seals dive with more than residual lung volume, attested by the fact that they expire upon surfacing (Kooyman et al., 1971b), it is postulated that some other anatomical feature of the respiratory system might assist in the accommodation of air during compression collapse. The diverticula found in the tracheobronchial tree might be this anatomical feature.

The four species of Antarctic seals evolved from the same Monachinae stock stemming from the Miocene era (Scheffer, 1958). Each species settled into its own ecological niche, the Weddell seal inhabiting the fast and permanent ice surrounding the continent while the crabeater seal remained among the pack ice. Due to several factors, the most likely being feeding habits, the Weddell seal became a deep-diving animal. In search of the fish composing the major portion of its diet (Trematomus borchgrevinki and the deeper-dwelling Dissostichus mawsoni) the Weddell seal developed its diving proficiency. Meanwhile, the crabeater seal, feeding primarily on the krill, Euphausia superba, developed into a shallow diver. This shrimp-like crustacean is found at depths usually not exceeding 30 meters.

Since the Weddell seal lives in such a dry climate, mucous secreting glands are necessary in its tracheobronchial tree to keep the lining epithelium moist. However, with the sea-level atmosphere of the Antarctic continent and

waters being relatively free of air-borne particles, the need for larger quantities of mucus and serous fluid to aid in the removal of minute foreign particles is probably not required. Terrestrial mammals and marine mammals inhabiting waters surrounding land masses that support flora and man would have a greater need for respiratory glands whose secretions would aid in the removal of foreign matter from their trachea and bronchial tree. Therefore, it might be possible that these tracheobronchial glands, especially those deep in the lung emptying into the bronchioles and smaller bronchi, have adapted into accessory air sacs capable of holding a significant portion of the air forced from the alveoli during compression collapse.

Nordquist (1973) examined the diverticula at the electron microscopic level and found some interesting features. The flattened epithelium actually contains two layers of cells. The superficial layer is composed of squamous cells, while the deeper layer consists of myo-epithelial cells. The squamous cells contain a few small mucous and lipid droplets which are detectable only by electron microscopy, and their over-all cytoarchitecture is not compatable with that of the usual secretory cell. Endoplasmic reticulum and Golgi bodies are not readily seen and well developed desmosomes are present between adjacent squamous cells.

Although the cells lining the diverticula do exhibit evidence of secretory activity and are underlain by myo-epithelial cells, they would be able to withstand the pressures encountered as the diverticula filled with air. The presence of well developed desmosomes between adjacent squamous cells suggests that these cells undergo a constant stress such as would be experienced by the continual filling and

emptying of the diverticula during descent and ascent of a dive. This epithelium could also withstand the deformation occurring as the air in the diverticula is compressed to meet the external hydrostatic pressures of the deepest dives.

The fact that the diverticula in a Weddell seal pup exhibit more of a secretory appearance than is seen in the adults corresponds to the known physiological status of the pups. They are not weaned before 6-8 weeks after birth. During this period they are in the water for only a few minutes at a time with very little diving being done. It seems to be an acclimatization process. Therefore, the diverticula might have time to develop into the definitive adult structures prior to the time the animal must undergo the rigors of diving.

The diverticula might possibly serve another function pertinent to a successful dive. As noted in the results, diverticula are found both on the luminal and adventitial sides of the bronchial and bronchiolar cartilage. Figure 36 summarizes how this anatomical relationship might aid in the compression of alveoli within the interior of the lung. As the seal exhales prior to diving, the more superficial alveoli collapse first (Nagaishi, 1972). The air forced from these sacs would fill the dead air space, including the diverticula on the adventitial side of the cartilage. As these diverticula fill, they would press against the more deeply situated alveolar sacs aiding in their collapse. This compressive action of the diverticula, working with the natural elasticity of the lungs, would insure the removal of most of the air from the respiratory portion of the lungs and the adjacent pulmonary capillary beds. This, of course, would eliminate the possibility of significant nitrogen gas absorption into the bloodstream during compression and

the resultant formation of nitrogen gas bubbles in the blood during too rapid decompression. Kooyman et al. (1972) have shown that a small amount of air remaining in the alveoli after compression is completely absorbed by the pulmonary capillaries. However, the volume of nitrogen gas involved is not significant unless several dives in succession are performed without sufficient decompression time following each dive. Studies indicate that following a dive deep enough to require compression collapse, the surface recovery time is adequate to prevent accumulation of nitrogen gas (Kooyman, 1968).

In the shallow diving crabeater seal the size and distribution of the diverticula in the bronchial tree are not as extensive as in the Weddell seal. This would seem to indicate that these structures may not be important functionally in this species. Since the crabeater seal feeds at depths usually shallower than 40 to 70 meters, its lungs are not exposed regularly to the higher hydrostatic pressures causing compression collapse of the alveoli. Therefore, the need for the extra air space afforded by the diverticula is not required. The presence of cartilage in the walls of the bronchial tree and larger bronchioles increases the effective dead air space so that most of the air forced from the alveoli during an infrequent compression collapse would be adequately accommodated. To date, there have been no studies published on the pulmonary function of the crabeater seal, and thus it is impossible to correlate anatomical data with any empirical physiological data.

Microscopic examination (Coalson and Boyd, 1973) has indicated that the lungs of neither adult nor pup harbor seals, Phoca vitulina, contain any di-

verticula. Being a shallow diver, this species would not be expected to possess all of the anatomical adaptations seen in a deep diving seal. Also, the harbor seal is a member of a different Phocidae tribe, Phocini, than are the Antarctic seals. This might indicate some early dichotomies in the phylogenetic evolution of the Phocidae tribes in regards to diving capabilities and adaptation.

It might be argued that a significant amount of air still can be trapped in the respiratory portion of the lungs by the premature collapse of the non-cartilaginous supported respiratory bronchioles. This, of course, would make the seal more susceptible to nitrogen narcosis. The walls of these small diameter airways are supported mainly by obliquely situated smooth muscle fibers. Denison and Kooyman (1973) calculated that the thickness of this muscle layer was sufficient to keep these airways patent during compression collapse. Since the respiratory bronchioles of both the Weddell seal and the crabeater seal exhibit a thick smooth muscle component, it can be assumed that these airways do not collapse while the animals are diving. This factor is of the utmost importance during a deep dive of a Weddell seal.

The smooth muscle in the bronchioles of odontocetes forms a series of myo-elastic sphincters (Wislocki, 1929). Their function is unknown but they may be involved with lung compression (Kooyman, 1972) or with the entrapment of air in the alveoli during a dive thereby making more oxygen available for underwater utilization (Kooyman, 1973).

These myo-elastic sphincters have been reported in the harbor seal (Pizey, 1954), elephant seal, harbor seal, Weddell seal and grey seal (Harrison and

Tomlinson, 1963), and in the Hawaiian monk seal (King and Harrison, 1961). However, they have not been found in any of the histological preparations in this study involving the Weddell seal and the crabeater seal.

It is thought that phocids elicit their diving response during the administration of anesthetics and the subsequent trauma of autopsy. This is evidenced by the pooling of blood in the inferior vena cava and hepatic sinus during autopsy and by the large volume of blood trapped in fresh, deflated lungs, (personal observations). The presence of the blood indicates general smooth muscle contraction in the lung tissue. Unless the lungs are reinflated prior to fixation, the contracted smooth muscle of the respiratory bronchioles would appear as a series of myoelastic sphincters when viewed histologically.

According to Ham (1969), elastic fibers are present during the early stages of fetal development of the human lung. As the lung grows and develops, these fibers are continually stretched. Thus, they are always in a stretched condition, even when the lung is at the end of expiration. This tendency of the elastic fibers to retain a relaxed condition indicates that the lung is in a continual state of attempted collapse.

The distribution of elastic fibers in both species of seals is similar to that seen in humans. However, the relative amounts seem to be greater in the seals. This would correspond with the greater elasticity of these lungs evidenced when they were removed from the thorax during autopsy. This characteristic in the Weddell seal was first noted by Hepburn (1912) who commented on the natural elasticity of the lung tissue and the apparent total lack of trapped air within the

structure. His doubt that this condition was caused by a "practical deflation of the lungs" might be unfounded since the indications are that the Weddell seal probably does initiate the diving response during traumatic conditions while out of water.

With the lungs of these seals containing more elastic fibers, it can be asked how this innate recoil force is overcome during reinflation of the lungs. Scholander (1940) stated that the deflation during a dive is confined to alveolar walls. Since most of the elastic fibers are situated proximal to the alveolar duct portion of the bronchial tree, it is reasoned that the deflation seen in excised lungs is much more complete than that occurring during a dive. This would be due to the greater role played by the elastic fibers during a total lung collapse.

Another factor to be considered during alveolar compression collapse in a dive is the role played by surfactant. Surfactant is a phospholipid produced by the alveolar Type II cells. This chemical substance is responsible for the decreased surface tension between the air/lung interface in the pulmonary alveoli. Harlan and Said (1969) have stated: "All species with alveolar structure have such a lining and in its absence, mammalian lungs are characterized by alveolar collapse and atalectasis." Coalson (1973) observed that the alveolar Type II cell, characterized by its lamellar inclusions, was difficult to find at the EM level. This might indicate a possible reduction (phylogenetic?) in the total number present in the lungs. The other types of cells seen in the alveolar septa were present in normal amounts. These different cells are:

(1) The Type I simple squamous cell through which

almost all gaseous exchange occurs.

(2) Alveolar macrophages.

(3) Endothelial cells lining the septal capiliaries.

(4) Occasional connective tissue cells.

Extraction studies done on lung material freshly frozen in the field and assayed within 10 days, have shown that the amount of surfactant present in the lungs of Weddell seal adults and pups is less than is found in the lungs of either man or common laboratory animals (Greenfield, 1973). It is possible that this decreased surfactant level might enhance alveolar collapse during a dive. The fact that the Weddell seal has few Type II alveolar epithelial cells also indicates a lower surfactant level. However, two other factors relevant to the lower surfactant levels must be considered. One, the tissue samples used in the assay were stored frozen for 10 days. This is the maximum length of time allowable for storage. It is possible that some of the surfactant might have become chemically inactive during storage, thus accounting for a lower quantitative assay. Second, since the lung samples were atalectic (normal condition due to natural elastic properties and smooth muscle contraction), the saline lavage used to extract the surfactant might not have been able to enter all alveoli in order to remove all of the surfactant present. If either or both of these conditions existed, then the lower surfactant levels recorded would not be the true levels actually present in the Weddell seal. However, the fact that there are fewer Type II cells in the Weddell seal lung implies that less surfactant normally is to be found acting at the air/tissue interface in the alveoli. Therefore, the surface tension at this interface would be

greater and the alveoli would be more prone to collapse.

Scholander (1940) felt that the lung collapse in whales was due to structural characteristics rather than any chemical, surface tension phenomenon. The obliquely situated diaphragm and the dorsoventrally shaped lungs in these animals predispose lung collapse in this direction. In this mechanism, "the alveoli simply flatten out like the mesh of a collapsing fish net or sponge". Therefore, the role played by surfactant would not be as critical as in an atalectic human lung.

The gross anatomy of the lungs and diaphragm of both the Weddell seal and the crabeater seal is quite similar to whales. In other words, the collapsing mechanism suggested for whales by Scholander might be just as applicable to phocids.

Another interesting aspect of the gross anatomy of the Weddell seal lungs is concerned with their lobation pattern. Cetaceans have unlobed lungs while most phocids have indistinctly lobed lungs. In contrast, otarid lungs are markedly lobated. The reasoning for these trends is not definitely known. Slijper (1962) thought that it might have to do with the fact that cetaceans, who spend all their life in water, exchange up to 90% of their lung capacity with each ventilation (Irving et al., 1941). Unlobed, uniformly shaped lungs would facilitate this rapid exchange. In otarids, there seems to be a correlation between time spent on land and increased lobation (Tarasoff and Kooyman, 1973a). The interesting observation is that both species of Antarctic seals utilized in this study exhibit lungs that are multi-lobed. This might indicate some specialization during their evolutionary development. Initial observations of the other two species of Antarctic seals, the leopard seal,

Hydrurga leptonyx, and the Ross seal, Ommatophoca rossi, reveal that their lungs are also multi-lobed. Further comparative studies of the other Monachinae seals would seem warranted. On cursory study (Dieuzeide, 1927), indicated that the lungs of the Mediterranean monk seal, Monachus monachus, a member of the tribe, Monachini, did not have the complete lobation pattern of the Antarctic seals, members of the tribe, Lobodontini.

The existence of double capillary beds in the alveoli of odontocetes has been known for some time (Fiebiger, 1916; Wislocki, 1929). It has been assumed that this morphological trait is characteristic of most of the smaller cetaceans. Recently, Simpson and Gardner (1972) reported this same vascular pattern in the stellar sea lion, Eumetopias jubata, a member of the otarid family. These investigators also observed only a single capillary bed per alveolus in another otarid, the California sea lion, Zalophus californianus. In phocids only single capillary beds have been reported in the harbor seal, Phoca vitulina (Belanger, 1940; Blessing, 1969). The presence of a single capillary bed per alveolus in both the Weddell seal and the crabeater seal, as seen in this study, seems to indicate a pattern for this single arrangement in phocids.

The odontocetes, excluding the sperm whale, are not known as deep divers. They spend little time at the surface between dives due to their rapid rate of air exchange with each ventilation. This rapid exchange could be facilitated by the double row of capillaries in each alveolus. This arrangement would permit more surface area contact between air and blood thereby increasing the oxygen and carbon dioxide exchange rates, given the proper gas tensions. Therefore, the animal

would not have to remain surfaced for any great length of time.

Conversely, in the deeper diving phocids, such as the Weddell seal, the need for this rapid exchange is not necessary. These animals remain at the surface for longer periods between dives, often to remove the oxygen debt incurred during their dives (Kooyman, 1968). Since the speed of the gas exchange is not as important, a single capillary bed per alveolus should be able to handle the exchange demands.

The data in Table 3 indicates the lung volumes measured during the inflation procedure. These volumes probably are less than the real lung volumes due to underinflation of the lungs. The 25 cm column of fluid used to inflate the organs is a standard for human and laboratory animals. Since the seal lungs were so collapsed due to the large amounts of smooth muscle present, a higher column of fluid should have been used to overcome this atalectic state. Figure 37 shows the uneven inflation of the lungs. This is indicated macroscopically by the partially collapsed lobules seen periodically through the visceral pleura.

Due to the working conditions in the field, it was not always possible to obtain the various seal body measurements required to calculate total body weight. Therefore, the correlation of an animal's total body weight with its total lung volume could not be undertaken as was originally planned.

CHAPTER V

SUMMARY AND CONCLUSIONS

Four species of Phocidae, or true seals, inhabit the waters surrounding the Antarctic continent. These animals exhibit varying degrees in diving capabilities. The Weddell seal, Leptonychotes weddelli, being a deep diver, is known to be capable of attaining depths up to 600 meters, while the crabeater seal, Lobodon carcinophagus, considered to be a shallow diver, usually is found at depths of less than 50 meters.

The respiratory systems of these two species of seals show the usual adaptations to an aquatic environment characteristic of other marine mammals. These include lungs that undergo compression collapse at depths greater than 70 meters; hyaline cartilage in the tracheo-bronchial tree as far as the terminal bronchioles; and large amounts of smooth muscle surrounding the distal-most bronchioles. The collapsible lungs provide a mechanism by which air is forced from the alveoli and adjacent pulmonary capillary beds thereby preventing the absorption of nitrogen gas into the bloodstream. The presence of hyaline cartilage throughout most of the tracheo-bronchial tree increases the effective dead air space that accommodates most of the air forced from the collapsed lungs. The smooth muscle surrounding the respiratory bronchioles prevents their collapse

while under the pressures of a deep dive. Collapse of the respiratory bronchioles not supported by cartilage would trap air in the lung alveoli during a dive.

In addition to these anatomical adaptations, another structural change has been found in the respiratory systems of these two species of Antarctic seal. Large, sac-like "diverticula" are found in the submucosa throughout the tracheobronchial tree. These diverticula, which open directly into the lumen of the tree, appear to be modified glands whose cells, in most cases, are no longer capable of any secretory function. They are most numerous in the more distal bronchi and terminal bronchioles where they are situated on both the luminal and adventitial sides of the hyaline cartilage supporting the walls of these air passages. Diverticula are not found in the respiratory bronchioles or in the respiratory portion of the lungs (as delineated on page 35).

It is postulated that these diverticula serve a dual purpose during a dive, especially in the deep diving Weddell seal. First they will aid in the accommodation of air forced from the collapsing lungs during a deep dive. Second, as the diverticula expand, they will press against the more deeply situated central alveoli, aiding in their collapse. These mechanisms will insure that most of the air filling the lung alveoli when the animal is at the surface or just below it will be accommodated when it encounters the extreme pressures of a deep dive, with its accompanying compression collapse of the lung alveoli, thereby preventing the absorption of excessive nitrogen gas and therefore, nitrogen narcosis.

BIBLIOGRAPHY

Andersen, H. T. 1961 Physiological adjustments to prolonged diving in the American alligator, Alligator mississippiensis. Acta. Physiol. Scand., 53:23-45.

Axenfeld, D. 1911 Die Bedeutung der Nasenschleimhaut für den Respirationsakt der Amphibien. Zentralb. Physiol., 25:329-331.

Barbosa, J. M. 1914 Sphincters bronchiques chez le Dauphin (Delphinus delphis). C. R. Acad. Sci., Paris, 159:455-458.

Bartholomew, G. A. and Lasiewski, R. C. 1965 Heating and cooling rates, heart rate and simulated diving in the Galapagos marine iguana. Comp. Biochem. Physiol., 16:573-582.

Baudrimont, A. 1929 Existance de fibres musculaires lisses dans la paroi des alveoles pulmonaires de l'homme et des mammiffaires. C. R. Soc. Biol., Paris, 100:1132-1134.

Baudrimont, A. 1932 Sur un Dispositif Vasculaire fonctionnelle de la Paroi des Voies Aérophores chez Phocoena communis (Less.). C. R. L. Assoc. Anat. (Nancy), pp. 380-387.

Belanger, L. F. 1940 A study of the histological structure of the respiratory portion of the lungs of aquatic mammals. Am. J. Anat., 67:437-461.

Belkin, D. A. 1968 Aquatic respiration and underwater survival of two freshwater turtle species. Resp. Physiol., 4:1-14.

Berkson, H. 1966 Physiological adjustments to prolonged diving in the pacific green turtle (Chelonia mydas agassizii). Comp. Biochem. Physiol., 18: 101-119.

Bert, P. 1870 Leçons sur la Physiologie comparee de la Respiration. J. B. Bailliere et Fils, Paris.

Blessing, M. H. 1969 Beitrag zur Physiologie und Anatomie einiger im Wasser lebender Mammaliae. Z. Säugetierk., 34:65-75.

Bonin, P. W. and Belanger, L. F. 1939 Sur la Structure der Poumon de Delphinapterus leucas. Trans. Roy. Soc., Canada, 33:19-22.

Bourdelle, E. and Grassé, P. P. 1955 In: Traité de Zoologie. Anatomie, Systematique, Biologie, (ed.) P. P. Grassé, Tome 17, Fasc. 1. Masson and Cie Éditeurs, Paris, pp. 341-438 and 445-450.

Bronn, H. G., Giebel, C. G. and Leche, W. 1874-1900 In: Klassen und Ordnugen des Thier-Reichs. Band 6, Abt. 5, Pt. 1, C. F. Winter, Leipzig, p. 1124.

Brown, D. 1954 Some observations on the bronchial system of the common seal. J. Anat., London, 88:551-552.

Brown, D. 1958 The bronchial tree in aquatic mammals. J. Anat., London, 92:656.

Brown, T. G. 1909 Die Atembewegungen des Frosches und ihre Beeinflussung durch die nervösen Zentren und durch das Labyrinth. Arch. ges. Physiol., 130:193.

Bryden, M. M. and Felts, W. J. L. 1973 Quantitative anatomical observations on the skeletal and muscular systems of four species of Antarctic seals. (In preparation).

Cline, D. R., Siniff, D. B. and Erickson, A. W. 1969 Immobilizing and collecting blood from Antarctic seals. J. Wildl. Mgmt., 33:138-144.

Coalson, J. J. 1973 Personal communication.

Coalson, R. E. and Boyd, R. B. 1973 Personal observations.

Denison, D. M. and Kooyman, G. L. 1973 The structure and function of the small airways in pinniped and sea otter lungs. Resp. Physiol., 17: 1-10.

Denison, D. M., Warrell, D. A. and West, J. B. 1971 Airway structure and alveolar emptying in the lungs of sea-lions and dogs. Resp. Physiol., 13:253-260.

DeVries, A. L. and Wohlschlag, D. E. 1964 Diving depths of the Weddell seal. Science, 145:292.

Dieuzeide, R. 1927 Sur quelques points d'Anatomie du Phoque-Moine de al Mediterranee (Monachus albiventer, Boddaert). Bull. Stat. d'Aquiculture Pêche de Castiglione, 2:214-249.

Dooley, M. S. and Koppányi, T. 1929 The control of respiration in the domestic duck (Anas boscas). J. Pharm. Exp. Therap., 36:507-518.

Eastman, J. T. 1973 Personal communication.

Engel, S. 1954 Respiratory tissue of the large whales. Nature, 173: 128-129.

Fiebiger, V. J. 1916 Über Eigentümlichkeiten im Aufbau der Delphinlunge und ihre physiologische Bedeutung. Anat. Anz., 48:540-565.

Foxon, G. E. H. 1964 Blood and respiration. In: Physiology of the Amphibia, (ed.,) J. A. Moore. Academic Press, New York, pp. 151-209.

Goudappel, J. R. and Slijper, E. J. 1958 Microscopic structure of the lungs of the bottlenose whale. Nature, 182:479.

Greenfield, L. J. 1973 Personal communication.

Ham, A. W. 1969 The respiratory system. In: Histology. J. B. Lippincott Co., Philadelphia, pp. 740-767.

Harrison, R. J. and Tomlinson, J. D. W. 1963 Anatomical and physiological adaptations in diving mammals. In: Viewpoints in Biology 2, (eds.) J. D. Carthy and C. L. Duddington. Butterworths, London, pp. 115-162.

Haynes, F. and Laurie, A. H. 1937 On the histological structure of cetacean lungs. Discovery Repts., 17:1-6.

Harlan, W. R. and Said, S. I. 1969 Selected aspects of lung metabolism. In: Biological Basis of Medicine, Vol. 6, (ed.) E. E. Bittar. Academic Press, London, pp. 357-384.

Heard, B. E. 1958 A pathological study of emphysema of the lungs with chronic bronchitis. Thorax, 13:136-149.

Heezen, B. C. 1957 Whales entangled in deep sea cables. Deep-Sea Res., 4:105-115.

Hepburn, D. 1896 Halichoerus grypus: the gray seal. J. Anat. and Physiol., 30:488-501.

Hepburn, D. 1912 Observations on the anatomy of the Weddell seal (Leptonychotes weddelli). III. The respiratory system and mechanics of respiration. Trans. Roy. Soc. Edin., 48:321-332.

Hill, W. C. O. 1945 Notes on the dissection of two dugongs. J. Mammal., 26:153-174.

Hobson, E. S. 1965 Observations on diving in the Galapagos marine iguana, Amblyrhynchus cristatus (Bell). Copeia, No. 2, pp. 249-250.

Howell, A. B. 1929 Contribution to the comparative anatomy of the eared and earless seals (genera Zalophus and Phoca). Proc. U. S. Nat. Mus., 73:1-142.

Howell, A. B. 1930 Aquatic Mammals. C. C. Thomas, Springfield, Ill.

Huber, E. 1934 Anatomical notes on Pinnipedia and Cetacea. Bull. Carnegie Inst. Wash., 447:105-135.

Huxley, F. M. 1913a On the reflex nature of apnoea in the duck in diving. I. The reflex nature of submersion apnoea. Quart. J. Expl. Physiol., 6:147-157.

Huxley, F. M. 1913b On the reflex nature of apnoea in the duck in diving. II. Reflex postural apnoea. Quart. J. Expl. Physiol., 6:158-182.

Huxley, F. M. 1913c On the resistance to asphyxia of the duck in diving. Quart. J. Exp. Physiol., 6:183-196.

Irving, L. 1937 The respiration of the beaver. J. Cell Comp. Physiol., 9:437-451.

Irving, L. 1938 Changes in the blood flow through the brain and muscles during the arrest of breathing. Am. J. Physiol., 122:207-214.

Irving, L. and Orr, M. D. 1935 The diving habits of the beaver. Science, 82:569.

Irving, L., Scholander, P. F. and Grinnell, S. W. 1941 The respiration of the porpoise, Tursiops truncatus. J. Cell Comp. Physiol., 17:145-168.

Jackson, D. C. and Schmidt-Nielsen, K. 1964 Countercurrent heat exchange in the respiratory passages. Proc. Natn. Acad. Sci., U.S., 51: 1192-1197.

Johansen, K. 1959 Heart activity during experimental diving of snakes. Am. J. Physiol., 197:604-606.

Johansen, K. 1964 Regional distribution of circulating blood during submersion asphyxia in the duck. Acta. Physiol. Scand., 62:1-9.

Johansen, K. and Aakhus, T. 1963 Central cardiovascular responses to submersion asphyxia in the duck. Am. J. Physiol., 205:1167-1171.

Johansen, K. and Krog, J. 1959 Peripheral circulatory response to submersion asphyxia in the duck. Acta. Physiol. Scand., 46:194-200.

Jolyet, M. F. 1893 Recherches sur la Respiration des Cetaces. Arch. Physiol., 5:610-618.

Kellogg, W. N. 1961 Porpoises and Sonar. The University of Chicago Press, Chicago.

King, J. 1968 The Ross and other Antarctic seals. Aust. Nat. Hist., 16: 29-32.

King, J. E. 1969 Some aspects of the anatomy of the Ross seal, Ommatophoca rossi. Brit. Antarct. Surv., Sci. Repts., No. 63, pp. 1-54.

King, J. E. and Harrison, R. J. 1961 Some notes on the Hawaiian monk seal. Pacif. Sci., 15:282-293.

Kooyman, G. L. 1966 Maximum diving capabilities of the Weddelll seal, Leptonychotes weddelli. Science, 151:1553-1554.

Kooyman, G. L. 1968 An analysis of some behavior and physiological characteristics related to diving in the Weddell seal. In: Antarctic Research Series, II. Biology of Antarctic Seas III, (eds.) W. L. Schmitt and G. A. Llano. American Geophysical Union, Washington, D. C. pp. 227-261.

Kooyman, G. L. 1972 Deep diving behavior and effects of pressure in reptiles, birds and mammals. Sym. Soc. Exp. Biol., No. 26. In: The Effects of Pressure on Organisms, Cambridge, University Press, London, pp. 295-313.

Kooyman, G. L. and Andersen, H. T. 1969 Deep diving. In: The Biology of Marine Mammals, (ed.) H. T. Andersen. Academic Press, New York, pp. 65-94.

Kooyman, G. L., Drabek, C. M., Elsner, R. and Campbell, W. B. 1971a Diving behavior of the emperor penguin, Aptenodytes forsteri. Auk., 88: 775-795.

Kooyman, G. L., Hammond, D. D. and Schroeder, J. P. 1970a Bronchograms and tracheograms of seals under pressure. Science, 169:82-84.

Kooyman, G. L., Kerem, D. H., Campbell, W. B. and Wright, J. J. 1970b Diving behavior and respiration in Weddell seals and emperor penguins. Antarct. J., U.S., 5:132-133.

Kooyman, G. L., Kerem, D. H., Campbell, W. B. and Wright, J. J. 1971b Pulmonary function in freely diving Weddell seals, Leptonychotes weddelli. Resp. Physiol., 12:271-282.

Kooyman, G. L., Schroeder, J. P., Denison, D. M., Hammond, D. D., Wright, J. J. and Bergman, W. P. 1972 Blood nitrogen tensions of seals during simulated deep dives. Am. J. Physiol., 223:1016-1020.

Koppányi, T. and Dooley, M. S. 1929 Submergence and postural apnea in the muskrat. Am. J. Physiol., 88:592-595.

Kuzin, A. E. 1970 On lobe structure and lung symmetry in fur seal embryos. Tik. Nauchno-Issled. Inst. Rybngo Khoz. I. Okeano, 70:238-240.

Lacoste, A. and Baudrimont, A. 1926 Sur Quelques Particularités Histologiques du Poumon due Dauphin et leur Adaptation Fonctionelle a la plongée. Bull. Stat. Biol. d'Arachon, 23:87-140.

Lacoste, A. and Baudrimont, A. 1933 Dispositifs d'adaptation fonctionnelle a la plongée dans l'appareil respiratore du marsuoin (Phocoena communis, Less.). Arch. d'Anat., d'Hist et d'Emb., 17:1-48.

Landis, A. T. 1965 New high pressure research animal? Undersea Tech., 6:21.

Langlois, P. and Richet, C. 1898a Des gas expirés par les canards plonges dans l'eau. Compt. Rend. Soc. Biol., Paris, 5:483-486.

Langlois, P. and Richet, C. 1898b Dosage des gas dans l'asphyxie du canard. Compt. Rend. Soc. Biol., Paris, 5:718-719.

Laurie, A. H. 1933 Some aspects of respiration in blue and fin whales. Discovery Repts., 7:363-406.

Littlepage, J. L. 1965 In: Antarctic Research Series, Vol. 5, Biology of the Antarctic Seas, II, (ed.) G. A. Llano. Amer. Geophys. Union, Washington, D. C., pp. 1-37.

Moberly, W. R. 1968 The metabolic responses of the common iguana, Iguana iguana, to walking and diving. Comp. Biochem. Physiol., 27:21-32.

Murata, T. 1951 Histological studies on the respiratory portions of the lungs of cetacea. Sci. Repts., Whales Res. Inst. Tokyo, 6:35-48.

Murdaugh, H. V. (Jr.) and Jackson, J. E. 1962 Heart rate and blood lactic acid concentration during experimental diving of water snakes. Am. J. Physiol., 202:1163-1165.

Murie, J. 1871 Researches upon the anatomy of the pinnipedia. Part 1. On the walrus (Trichechus rosmarus, Linn). Trans. Zool. Soc., London, 7:411-464.

Murie, J. 1874 Researches upon the anatomy of the pinnipedia. Part III. Descriptive anatomy of the sea-lion (Otaria jubata). Trans. Zool. Soc., London, 8:501-582.

Murphy, R. C. 1913 The trachea of Ogmorhinus with notes on other soft parts. Bull. Amer. Mus. Nat. Hist., 32:505-506.

Nagaishi, C. 1972 Functional Anatomy and Histology of the Lung. University Park Press, Baltimore.

Nansen, F. 1925 Hunting and Adventure in the Arctic. Duffield and Co., New York.

Neuville, H. 1921 Sur l'appariel respiratorie des Cétacés. Bull. Mus. Nat. Hist. Natur., Paris, 27:209-215.

Neuville, H. 1922 Sur l'appareil respiratorie des Cétacés. Bull. Mus. Nat. Hist. Natur., Paris, 28:27-34.

Neuville, H. 1923 Sur l'appareil respiratoire des Cétacés. Bull. Mus. Nat. Hist. Natur., Paris, 29:35-39.

Nishida, S. and Amemiya, J. 1962 Morphological notes of the internal organs of crab-eating seals. Antarct. Rec., No. 14, pp. 97-101.

Noël Paton, D. 1927 Submergence and postural apnoea in the swan. Proc. Roy. Soc., Endinburgh, 47:283-293.

Nordquist, R. E. 1973 Personal communication.

Ommanney, F. D. 1932 The vascular networks (retia mirablia) of the fin whale (Balaenoptera physalus). Discovery Repts., 5:327-362.

Owen, R. 1830-1831 On the anatomy of the seal (Phoca Vitulina). Proc. Zool. Soc., London, Part I:153-154.

Peterson, A. K. 1935 On the preparation of Wood's metal casts of the lungs. Anat. Rec., 61:261-272.

Pick, F. K. 1907 Zur feineren Anatomie der Lunge von Halicore dugong. Arch. Naturgesch., 73:245-271.

Piérard, J. 1969 Le larynx du phoque de Weddell (Leptonychotes weddelli, Lesson, 1826). Can. J. Zool., 47:77-87.

Pizey, N. C. D. 1954 The structure of the pinniped lung. J. Anat., London, 88:552.

Pough, F. H. 1973 Heart rate, breathing and voluntary diving of the elephant trunk snake, Acrochordus javanicus. Comp. Biochem. Physiol., 44A: 183-189.

Proetz, A. W. 1951 Air currents in the upper respiratory tract and their clinical importance. Ann. Otol., Rhin. and Laryng., 60:439-467.

Quiring, D. P. and Harlan, C. F. 1953 On the anatomy of the manatee. J. Mammal., 34:192-203.

Richet, C. 1894 La résistance des canards à l'asphyxie. C.R. Soc. Biol., Paris 1:244-245.

Richet, C. 1898 De la résistance des canards à l'asphyxie. C.R. Soc. Biol., Paris 5:685-686.

Richet, C. 1899 De la résistance des canards à l'asphyxie. J. Physiol. Path. Gen., Paris, 1:641-650.

Ridgeway, S. H. 1966 Studies on diving depth and duration in Tursiops truncatus. Conf. Biol. Sonar and Diving Mammals, Stanford Research Inst., Menlo Park, Calif., pp. 151-158.

Scheffer, V. B. 1958 Seals, Sea Lions and Walruses. Stanford Univ. Press, Stanford, Calif.

Schneider, R. 1962 Vergleichende Untersuchungen am Kehlkopf der Robben (Mammalia, Carnivora, Pinnipedia). Gegenbaur's morphol. Jahrb., 103:177-262.

Schneider, R. 1963 Der Kehlkopf der Klappmütze (Cystophora cristata, Erxleben, 1777). Ein weiterer Beitrag zur vergleichenden Anatomie des Robbenkehlkopfes. Anat. Anz., 112:54-68.

Scholander, P. F. 1940 Experimental investigations on the respiratory function in diving mammals and birds. Hvalrad. Skrift., No. 22, pp. 5-134.

Scholander, P. F. and Irving, L. 1941 Experimental investigations on the respiration and diving of the Florida manatee. J. Cell Comp. Physiol., 17:169-191.

Scholander, P. F. and Schevill, W. E. 1955 Countercurrent vascular heat exchange in the fins of whales. J. Appl. Physiol., 8:279-282.

Schorger, A. W. 1947 The deep diving of the loon and the old-squaw and its mechanism. Wilson Bull., 59:151-159.

Simpson, J. G. and Gardner, M. B. 1972 Comparative microscopic anatomy of selected marine mammals. In: Mammals of the Sea - Biology and Medicine, (ed.) S. H. Ridgeway, C. C. Thomas, Springfield, Ill., pp. 298-418.

Slijper, E. J. 1958 Organ weights and symmetry problems in porpoises and seals. Arch. neerl. Zool., 13:97-113.

Slijper, E. J. 1962 Whales. Basic Books, New York.

Sokolov, A. S., Kosygin, G. M. and Shustov, A. P. 1971 Structure of lungs and trachea of Bering Sea pinnipeds. In: Pinnipeds of the North Pacific, (eds.) V. A. Arsenev and K. I. Panin. Israel Program Sci. Transl. Jerus., pp. 250-262.

Stirling, I. 1966 A technique for handling live seals. J. Mammal., 47:543-544.

Tarasoff, F. J. and Kooyman, G. L. 1973a Observations on the anatomy of the river otter, sea otter, and harp seal. I. The topography, weight and measurements of the lungs. Can. J. Zool., 51:163-170.

Tarasoff, F. J. and Kooyman, G. L. 1973b Observations on the anatomy of the river otter, sea otter, and harp seal. II. The trachea and bronchial tree. Can. J. Zool., 51:171-177.

Vincent, S. and Cameron, A. T. 1920 A note on an inhibitory respiratory reflex in the frog and some other animals. J. Comp. Neurol., 31:283-291.

Walker, J. E. C. and Wells, R. E. 1961 Heat and water exchange in the respiratory tract. Am. J. Med., 30:259-267.

White, F. N. and Ross, G. 1966 Circulatory changes during experimental diving in the turtle. Am. J. Physiol., 211:15-18.

Willem, V. 1919 Les mouvements respiratoires de la grenouille. Arch. néerl. Physiol., 3:315-348.

Wislocki, G. B. 1929 On the structure of the lungs of the porpoise (Tursiops truncatus). Am. J. Anat., 44:47-77.

Wislocki, G. B. 1935 The lungs of the manatee (Trichechus latirostris) compared with those of other aquatic mammals. Biol. Bull., 68:385-396.

Wislocki, G. B. 1942 The lungs of the Cetacea with special reference to the harbor porpoise (Phocaena Phocoena, Linnaeus). Anat. Rec., 84: 117-121.

Wislocki, G. B. and Belanger, L. F. 1940 The lungs of the larger Cetacea compared to those of smaller species. Biol. Bull., 78:289-297.

Wolf, S. 1933 Zur Kenntnis von Bau und Funktion der Reptilienlunge. Zool. Jahrb. Abt. Anat., 57:139-190.

Zeek, P. M. 1951 Double trachea in penguins and sea lions. Anat. Rec., 111:327-339.

APPENDIX

PLATE I

Figure 1. Divisions of the more distal bronchial tree within a typical lobule of the lung.

PLATE I

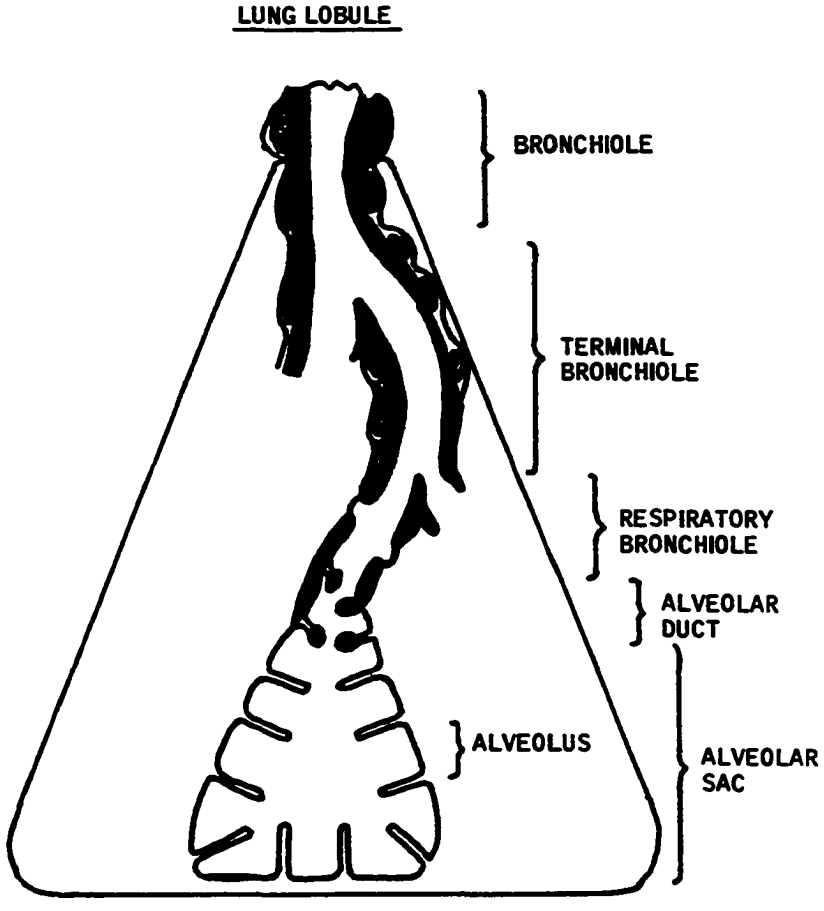
LUNG LOBULE
BRONCHIOLE
TERMINAL BRONCHIOLE
RESPIRATORY BRONCHIOLE
ALVEOLAR DUCT
ALVEOLUS
ALVEOLAR SAC

1

PLATE II

Figure 2. Weddell seal. Lateral wall of nasal cavity. (A) adult seal; (B) seal pup.

PLATE II



2A



2B

PLATE III

Figure 3. Weddell seal. Nasal septum. The anterior cartilaginous portion is characterized by areas of soft tissue swellings (ST). The posterior, bony portion is dominated by the numerous blood vessels (BV) visible through its epithelium.

PLATE III



PLATE IV

Figure 4. Weddell seal. Nasal turbinates. Photomicrograph of areas of stratified squamous cells (SS) that are interspersed throughout the more typical pseudostratified ciliated columnar epithelium (PC). (H & E, X50).

Figure 5. Weddell seal. Nasal turbinates. Photomicrograph of the lamina propria. This region is dominated by large venous spaces (VS) and mucous glands (MG). (H & E, X30).

PLATE IV

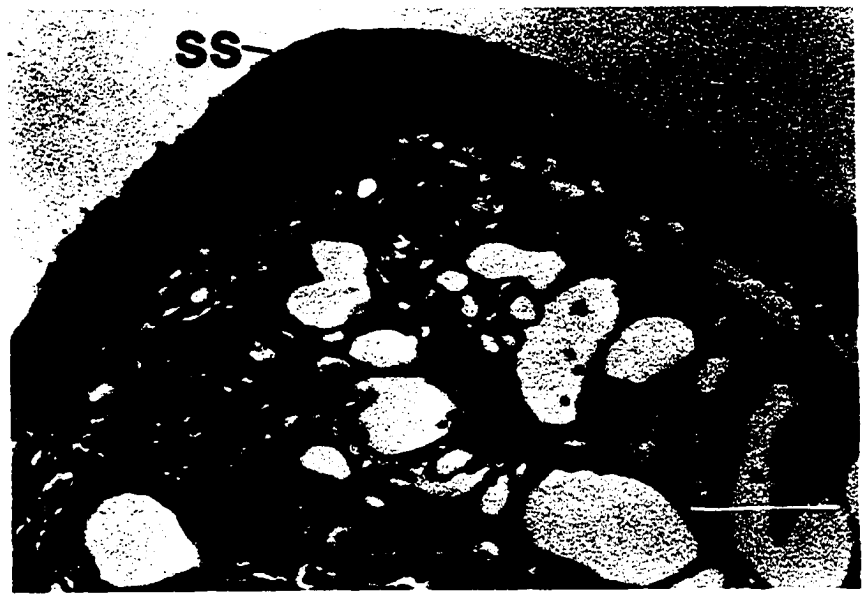

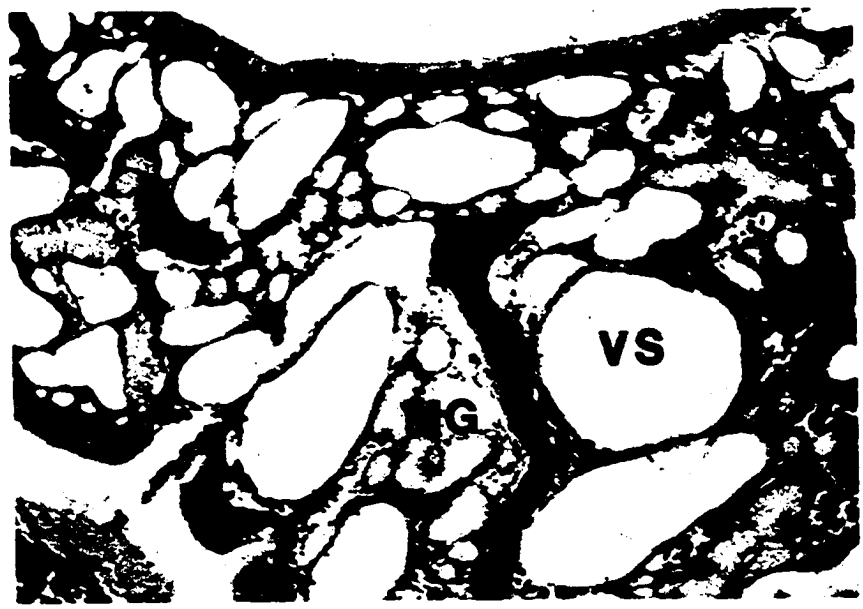

PLATE V

Figure 6. Weddell seal. Nasal septum. Photomicrograph of the soft tissue region. This area exhibits complex mucous glands (MG), the ducts of which are lined with typical respiratory epithelium (PC). Aggregates of lymphocytes (L) are present throughout the area. (H & E, X30).

Figure 7. Weddell seal. Pharyngeal tonsil. Photomicrograph of typical lymphatic nodules (LN) that can be seen in the structure with mucous glands (MG) also present; (S) indicates septum. (H & E, X30).

PLATE V

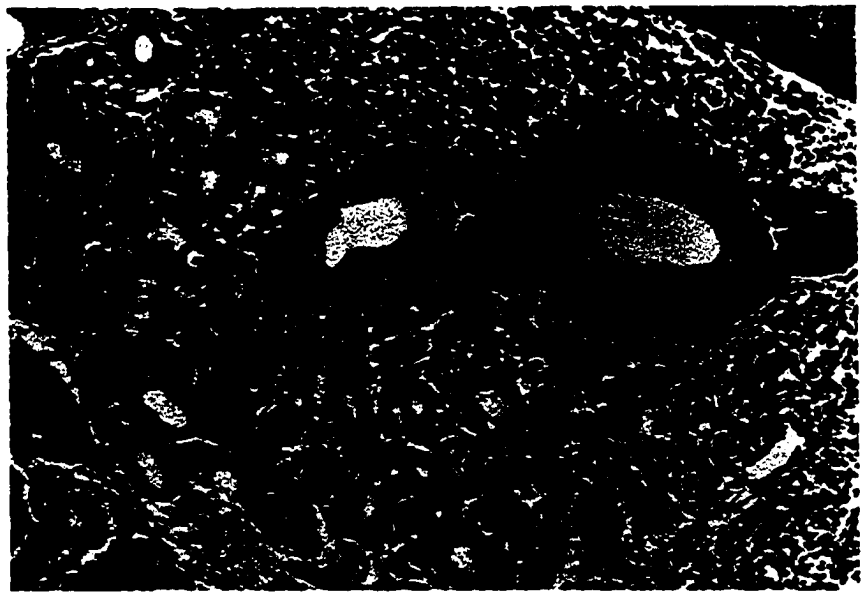



PLATE VI

Figure 8. Weddell seal. Anterior/longitudinal view of trachea.

PLATE VI



PLATE VII

Figure 9. Representative cross section of Weddell and crabeater tracheae. (A) Weddell seal. Note the flaired ends of the flattened cartilaginous plates (C). (B) Crabeater seal. The cartilaginous plate has semilunar shaped ends. Note the lack of cartilage in the dorsal wall of each trachea.

PLATE VII

WEDDELL SEAL



9A

CRABEATER SEAL



9B

PLATE VIII

Figure 10. Weddell seal. Trachea. Photomicrograph of a glandular-diverticular complex. Note the large lumen and apparent simple squamous epithelium of the diverticulum (D), while the glandular portion of the complex (MG) has the typical simple cuboidal epithelium seen in other glands. (H & E, X30).

Figure 11. Weddell seal. Trachea. Photomicrograph of the layer of elastic fibers (E) extending between adjacent cartilaginous plates. (H & E, and Orcein, X15).

PLATE VIII





PLATE IX

Figure 12. Weddell seal. Upper bronchi. Ventral and cross sectional views; note that the cartilaginous rings (C) are open dorsally in the primary bronchi but are completely enclosed in the lobar and segmental bronchi.

PLATE IX

UPPER BRONCHI

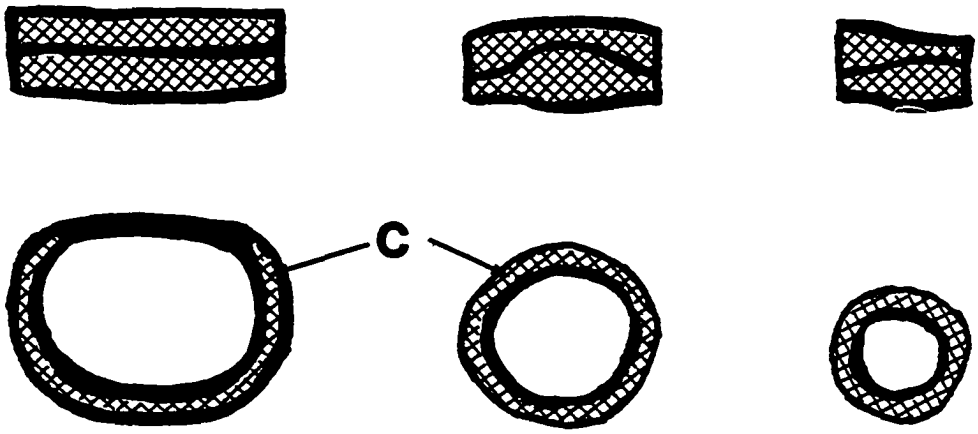

PRIMARY LOBAR SEGMENTAL

12

PLATE X

Figure 13. Weddell seal. Photomicrograph of a medium sized bronchus. Note that the walls of the lumen (L) are supported by irregularly shaped pieces of hyaline cartilage (C). (H & E, X15).

Figure 14. Weddell seal. Bronchus. Photomicrograph of the layer of elastic fibers (E) running between adjacent plaques of cartilage (C). Note how the fibers bifurcate to encircle the cartilage (arrows). (Orcein, X15).

PLATE X





PLATE XI

Figure 15. Weddell seal. Distal bronchus. Photomicrograph of the smooth muscle layer (SM) between the mucosa (M) and cartilage (C). (H & E, X30).

Figure 16. Weddell seal. Visceral pleura. Photomicrograph showing the thick layer of elastic fibers (E) in the periphery of the pleura. The pleura becomes continuous with the connective tissue septum (S) separating adjacent lung lobules (L). (Orcein, X50).

PLATE XI





PLATE XII

Figure 17. Weddell seal. Right lung, lateral view. The lung has cranial (CR), middle (M) and caudal (CU) lobes separated by oblique (OF) and horizontal (HF) fissures.

PLATE XII



17

PLATE XIII

Figure 18. Weddell seal. (A). Right lung, medial view. This surface is characterized by the small, accessory lobe (AS). (B). The accessory lobe consists of two distinct segments (S) separated by a pleural band (P).

PLATE XIII

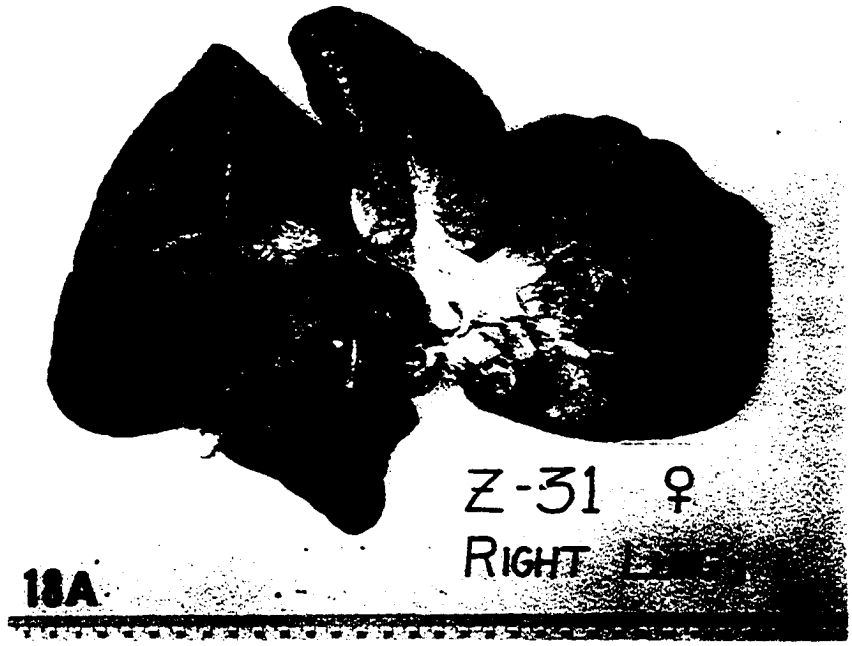

18A



18B

PLATE XIV

Figure 19. Weddell seal. Left lung, lateral view. This lung has complete cranial (CR) and caudal (CU) lobes plus an indistinct middle lobe (M). Segmentation and lobulation of the parenchyma is visible through the visceral pleura (arrows). The beginning of incomplete accessory fissures are seen along the free edge of the lung (F).

PLATE XIV



19

PLATE XV

Figure 20. Weddell seal. Photomicrograph of the distal-most portions of the bronchial tree. (TB) terminal bronchiole; (RB) respiratory bronchiole; (AD) alveolar duct; (AS) alveolar sac. (PAS, X15).

Figure 21. Weddell seal. Photomicrograph of the respiratory epithelium of a typical bronchiole. Note the large number of goblet cells (GB) present. (PAS, X200).

PLATE XV





PLATE XVI

Figure 22. Weddell seal. Photomicrograph of a distal bronchus. Note the irregular cartilaginous plaques (C) supporting the walls of the lumen. The diverticula (D) are situated on both the luminal and adventitial sides of the cartilage. (PAS, X10).

Figure 23. Weddell seal. Photomicrograph of the respiratory epithelium of a terminal bronchiole. Note that there are fewer goblet cells (GB) than are seen in the more proximal portions of the bronchial tree. (PAS, X200).

PLATE XVI





PLATE XVII

Figure 24. Weddell seal. Photomicrograph of the epithelium lining a respiratory bronchiole. Note that the cell type has changed to a tall simple cuboidal epithelium without goblet cells. (PAS, X200).

Figure 25. Weddell seal. Photomicrograph of a respiratory bronchiole. Note elastic fiber network (E) surrounding the bundles of smooth muscle. (Orcein, X100).

PLATE XVII





PLATE XVIII

Figure 26. Weddell seal. Photomicrograph of a respiratory bronchiole. Note the partially contracted bundles of smooth muscle (SM) in the walls of the structure. (H & E, X50).

Figure 27. Weddell seal. Photomicrograph of a diverticulum. Note that the simple squamous epithelium (SS) does not exhibit any secretory characteristics. (PAS, X200).

PLATE XVIII





PLATE XIX

Figure 28. Weddell seal. Photomicrograph of an alveolar duct (AD). Note the thick bundles of smooth muscle (SM) forming the walls of the alveolar duct. The duct is lined with simple squamous epithelium (SS). (PAS, X100).

Figure 29. Weddell seal. Photomicrograph showing the single capillary bed in an alveolar septum (AS). (RBC) red blood cell. (H & E, X500).

Figure 30. Weddell seal. Photomicrograph of an isolated smooth muscle fiber (SM) in an alveolar septum (AS). (H & E, X500).

PLATE XIX



PLATE XX

Figure 31. Crabeater seal. Lateral wall of nasal cavity. Note the complex turbinates and the large antrum immediately rostral to them.

PLATE XX



PLATE XXI

Figure 32. Crabeater seal. Photomicrograph of the tracheal submucosa. Note the absence of diverticula among the muco-serous glands (MG). (PAS, X200).

Figure 33. Crabeater seal. Photomicrograph of a distal bronchus. Note the small, elongated diverticula (D) on the adventitial side of the cartilage (C). (H & E, X15).

PLATE XXI





PLATE XXII

Figure 34. Crabeater seal. Right lung, lateral view. Note the cranial (CR) and caudal (CU) lobes and the indistinct middle lobe (M) of the cranial lobe.

Figure 35. Crabeater seal. Photomicrograph showing the elastic fibers (E) in the alveolar septa (AS) of the lung parenchyma. (Orcein, X30).

PLATE XXII





PLATE XXIII

Figure 36. Weddell seal. Diagram of possible compression collapse mechanism during a dive. (A). Prior to diving. Note that all alveoli are still open. (B). Early part of a dive. The peripheral alveoli have collapsed, aiding in the expansion of the diverticulum. (C). At the deepest part of the dive, all of the alveoli have collapsed. (LS) lung surface; (PA) peripheral alveoli; (CA) central alveoli; (D) diverticulum.

PLATE XXIII

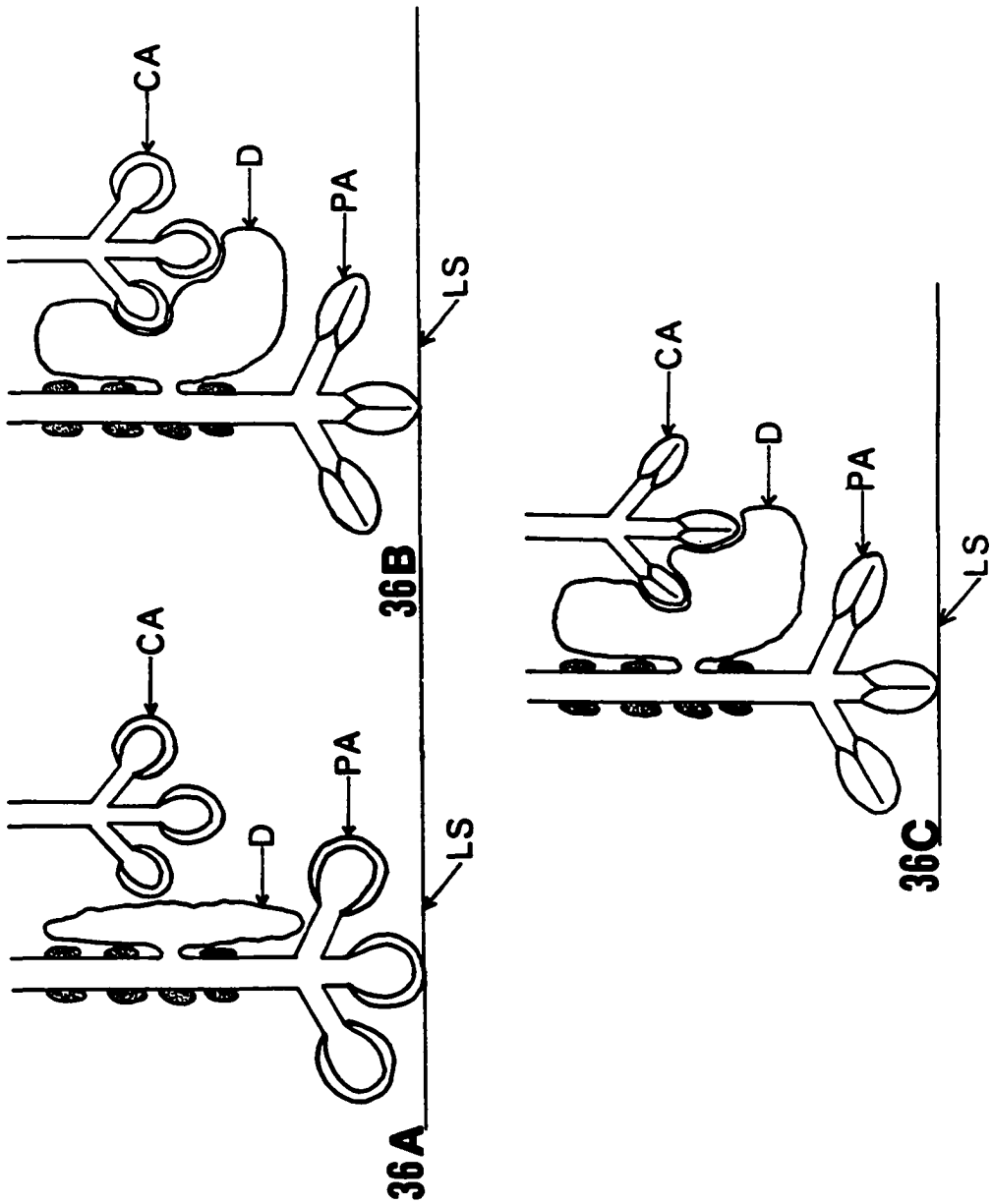

PLATE XXIV

Figure 37. Weddell seal. Photomicrograph of a collapsed lung lobule (L) indicating uneven inflation of the lung. (P) visceral pleura. (PAS, X10).

PLATE XXIV



INFORMATION TO USERS

This material was produced from a microfilm copy of the original document. While the most advanced technological means to photograph and reproduce this document have been used, the quality is heavily dependent upon the quality of the original submitted.

The following explanation of techniques is provided to help you understand markings or patterns which may appear on this reproduction.

1. The sign or "target" for pages apparently lacking from the document photographed is "Missing Page(s)". If it was possible to obtain the missing page(s) or section, they are spliced into the film along with adjacent pages. This may have necessitated cutting thru an image and duplicating adjacent pages to insure you complete continuity.

2. When an image on the film is obliterated with a large round black mark, it is an indication that the photographer suspected that the copy may have moved during exposure and thus cause a blurred image. You will find a good image of the page in the adjacent frame.

3. When a map, drawing or chart, etc., was part of the material being photographed the photographer followed a definite method in "sectioning" the material. It is customary to begin photoing at the upper left hand corner of a large sheet and to continue photoing from left to right in equal sections with a small overlap. If necessary, sectioning is continued again — beginning below the first row and continuing on until complete.

4. The majority of users indicate that the textual content is of greatest value, however, a somewhat higher quality reproduction could be made from "photographs" if essential to the understanding of the dissertation. Silver prints of "photographs" may be ordered at additional charge by writing the Order Department, giving the catalog number, title, author and specific pages you wish reproduced.

5. PLEASE NOTE: Some pages may have indistinct print. Filmed as received.

Xerox University Microfilms
300 North Zeeb Road
Ann Arbor, Michigan 48106