

# Purple Urine Bag Syndrome



Jessica Blalock OMS-2, Michael Blose PGY-3, Taylor Blose PGY-3, Daelor Osen PGY-2, Jennifer Briggs D.O., Anastasia Fisher D.O.

## INTRODUCTION

Purple urine bag syndrome (PUBS) is a complication of urinary tract infections where catheter bags and tubing turn purple.<sup>1</sup> This is usually noted with no significant change in symptoms but accompanied secondary to a UTI. This is generally a benign, but alarming finding in patients. King George III had purple urine during a time of constipation, however, the first formal report of purple urine was not until 1978.<sup>3</sup> First formal report, documented by Barlow and Dixon.<sup>2</sup>

The most common risk factors are advanced age, female gender, constipation, dementia, bedridden situation, institutionalization, end-stage renal disease, dehydration, chronic catheterization, use of polyvinyl chloride urinary catheter or bag, recurrent UTI, high urinary bacterial counts and alkaline urine.<sup>4</sup> With the most important being long-term catheterization, female gender, chronic constipation, elderly, bed-bound, and institutionalized.<sup>4</sup>

## PREVALENCE & MORTALITY

PUBS is a rare phenomenon with poorly described incidence in the general population. However, in patients with the risk factors noted above, the prevalence has been reported to be as high as 42%.<sup>1</sup> Mortality is largely related to patients' comorbidities and not a direct consequence of PUBS.<sup>1</sup> The longer the PVC bag is in use for a patient, the deeper shade of purple the bag becomes, despite changing sterile PVC urine bags from 2 different companies.<sup>3</sup>

## MECHANISM OF ACTION

PUBS is a consequence of UTIs in which bacteria metabolize products of tryptophan into red and blue pigments. Tryptophan is normally metabolized in the GI tract. The flora deaminate tryptophan to indole which is then transported to the liver by circulation. The tryptophan is then conjugated by the liver to produce indoxyl sulfate. From there, it is secreted into urine where sulfates and phosphatases, which are produced by certain bacteria, convert it to indoxyl. In alkaline urine, it is oxidized to indigo and indirubin pigments.<sup>1</sup> The bacteria is primarily gram negative and includes *Providencia stuartii* and *Providencia rettgeri*, *Klebsiella pneumoniae*, *Proteus mirabilis*, *Escherichia coli*, *Enterococcus species*, *Morganella morganii*, *Pseudomonas aeruginosa*, *Citrobacter species*, and group B *Streptococci*, though it is often polymicrobial leading to PUBS.<sup>3</sup> Dehydration leads to an increase of indigo and indirubin, hence purple urine is more likely. Renal failure causes impaired clearance of indoxyl sulfate. Individuals with constipation, intussusception or ileal diversion will likely have more bacterial growth secondary to urinary retention.<sup>4</sup>

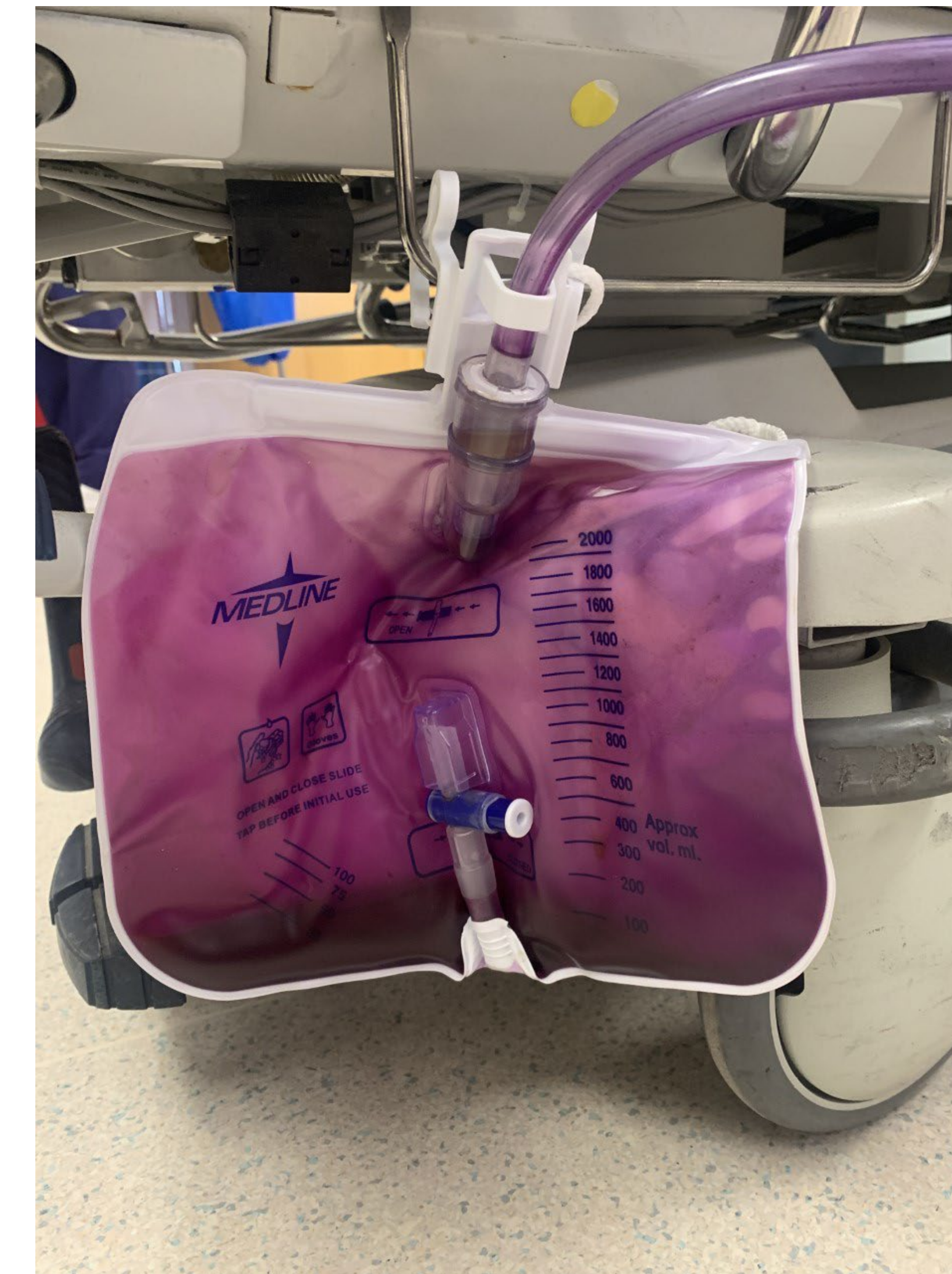## CASE STUDY:

Patient is a 74-year-old female with past medical history of diabetes mellitus type II, hypothyroidism, chronic anemia, essential hypertension, and end stage renal failure requiring hemodialysis. She presented to OSU Medical Center from dialysis per nephrology recommendations due to development of new urinary discoloration. Her nephrologist expressed concern of purple urine bag syndrome (PUBS) due to violaceous urine and numerous associated comorbidities.

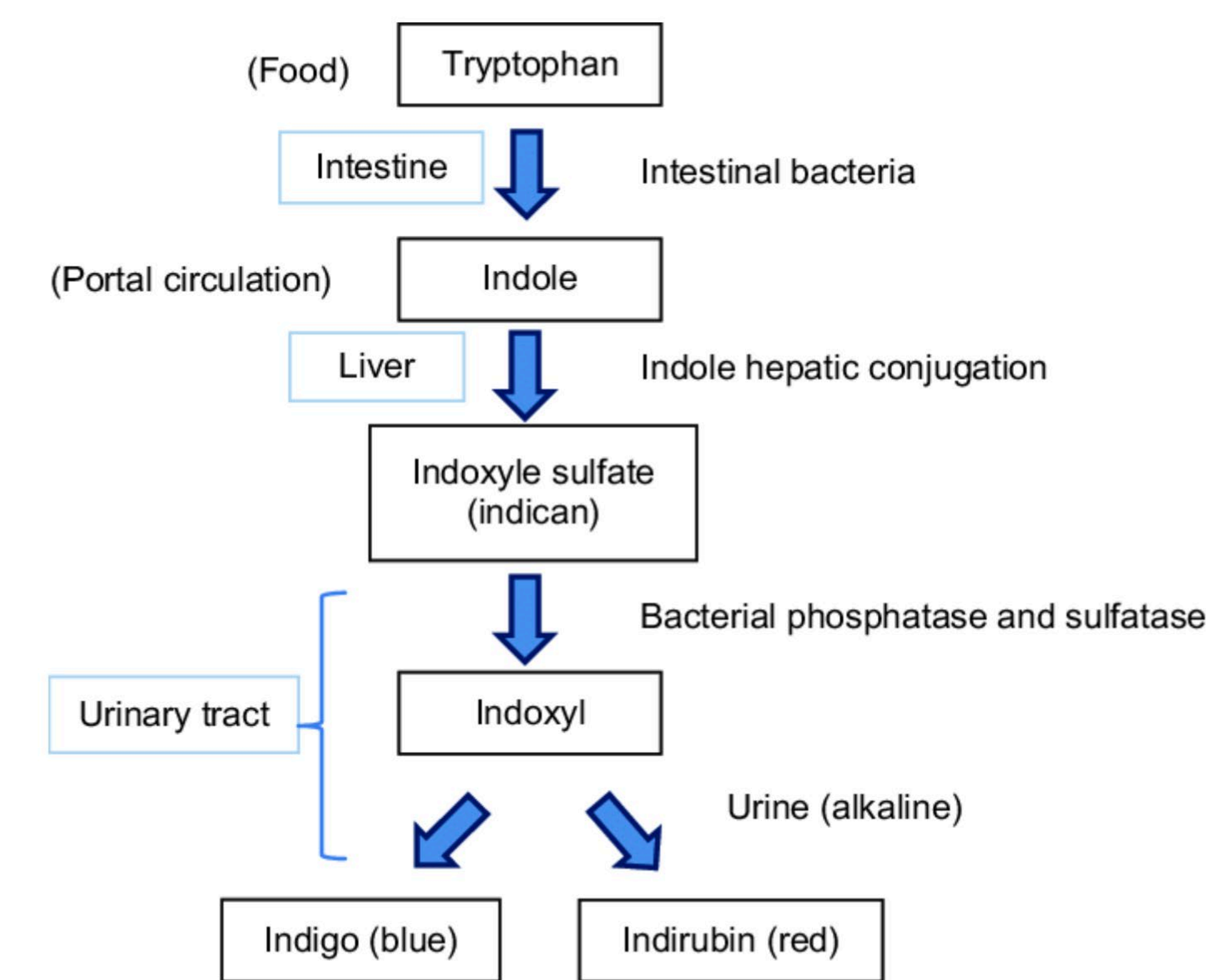
Upon arrival she reported chronic constipation and generalized weakness. She had normal vital signs and normal mentation. CT abdomen/pelvis was performed due to concern for ureterovesicular fistula, incidentally, revealing prominent fecal burden within the rectum. Lab work in the emergency department was significant for white blood cell count of 16. Urinalysis collection was delayed due to anatomical challenges requiring replacement of foley catheter by urology. In the interim, Cefepime was empirically provided per recommendations of clinical pharmacy, and she was ultimately dispositioned to the general medical floor.

While in the hospital, her preliminary urine culture revealed Enterococcus. Patient's antibiotic regimen was transitioned to Vancomycin while awaiting speciation. Sensitivities ultimately revealed Vancomycin Resistant Enterococcus, at which point Infectious Disease was consulted. They recommended antibiotic discontinuation due to suspicion that her cultures were likely secondary to colonization.

Antibiotics were discontinued and patient's urine discoloration resolved. The remainder of her hospital course was unremarkable, and she was eventually discharged back to her nursing home with a bowel regimen and foley catheter in place.



## Mechanism of Action



Pathogenesis of purple urine bag syndrome.

## DISCUSSION

In summary, despite the striking appearance, PUBS is a relatively benign condition with the limitation of no well-established treatment guidelines. Most sources recommend multimodal treatment while addressing and treating the predisposing factors such as constipation, in addition to changing of foley bag materials regularly.

## CLINICAL RELEVANCE

Noting PUBS in a patient can indicate significance of patients predisposing factors. Recognizing the need to have frequent changes in the urinary catheter and changes in equipment is important in this scenario.

## LIMITATIONS

Literature review shows primarily case reports with no high-quality study of treatment or evidence-based recommendations for management of PUBS. Additionally, there is a paucity of research from the United States, limiting generalization to our patient population.

## ACKNOWLEDGMENTS

Thank you to Dr. Kelly Murray for her contributions to this work.

## REFERENCES

1. Kalsi, D. S., Ward, J., Lee, R., & Handa, A. (2017). Purple Urine Bag Syndrome: A Rare Spot Diagnosis. *Disease Markers*, 2017, 9131872.
2. Kumar, R., Devi, K., Kataria, D., Kumar, J., & Ahmad, I. (2021). Purple Urine Bag Syndrome: An Unusual Presentation of Urinary Tract Infection. *Cureus*, 13(7), e16319.
3. Lin, C.-H., Huang, H.-T., Chien, C.-C., Tzeng, D.-S., & Lung, F.-W. (2008). Purple urine bag syndrome in nursing homes: ten elderly case reports and a literature review. *Clinical Interventions in Aging*, 3(4), 729–734.
4. Sabanis, N., Paschou, E., Papanikolaou, P., & Zagkotsis, G. (2019). Purple Urine Bag Syndrome: More Than Eyes Can See. *Current Urology Reports*, 13(3), 125–132.
5. Amoozgar, B., Garala, P., Velmahos, V. N., Rebba, B., & Sen, S. (2019). Unilateral Purple Urine Bag Syndrome in an Elderly Man with Nephrostomy. *Cureus*, 11(8), e5435.
6. Barnes, R. (2020, September 23). *Purple Urine Bag Syndrome: A visual diagnosis and what it means for your patient*. ALiEM; Academic Life in Emergency Medicine. <https://www.aliem.com/purple-urine-bag-syndrome/>
7. Vallejo-Manzur, F., Mireles-Cabodevila, E., & Varon, J. (2005). Purple urine bag syndrome. *The American Journal of Emergency Medicine*, 23(4), 521–524.