

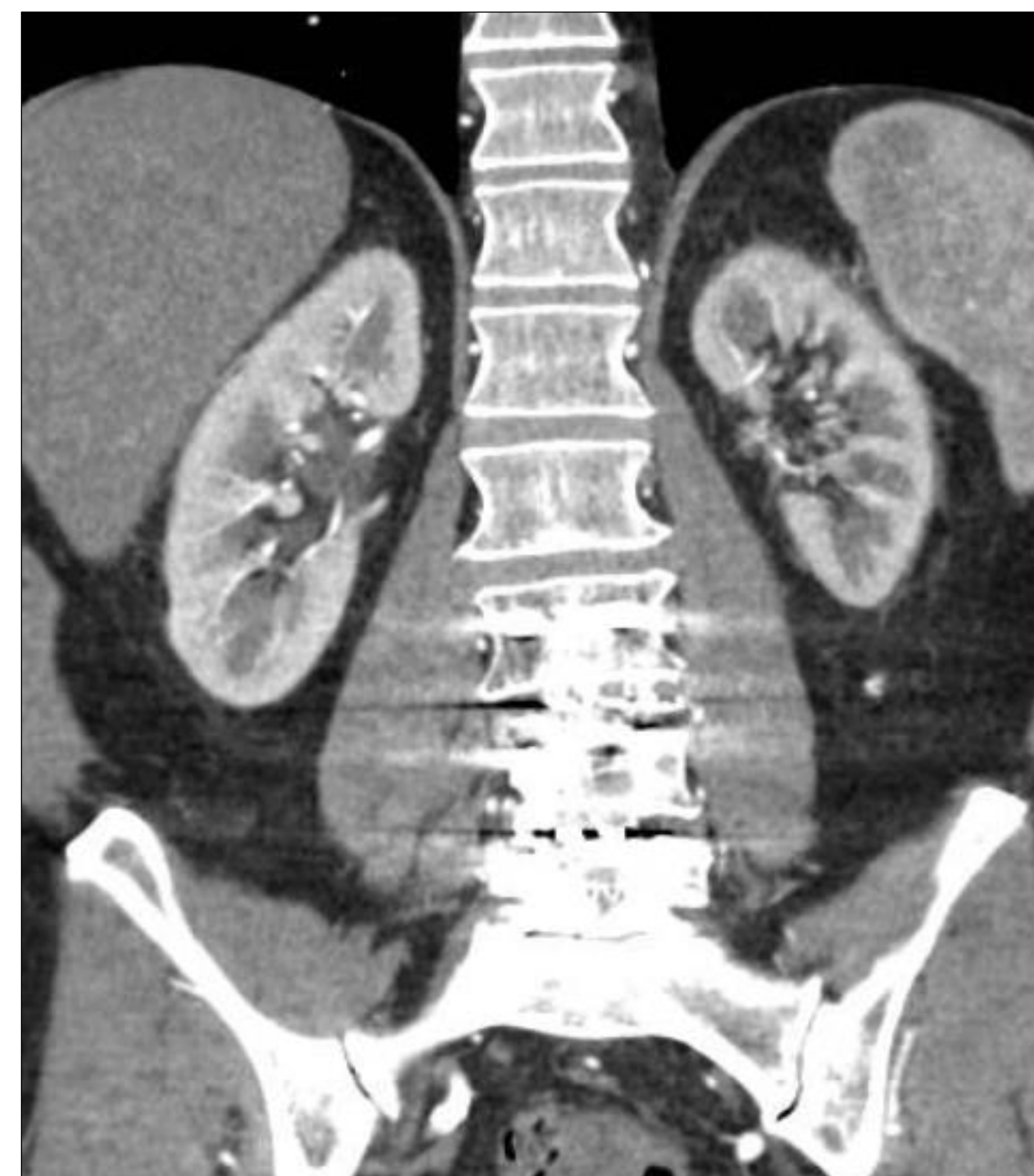## INTRODUCTION

- Renal artery stenosis is one of the many etiologies of hypertension
- Reduced renal perfusion lowers the glomerular filtration rate, causing a response by the renin-angiotensin-aldosterone system resulting in a compensatory increase in blood pressure
- If the stenosis is severe enough, it may also lead to reduced renal function and eventually renal failure
- Hypertension caused by renal artery stenosis can be resistant to medical management
- Treatment options for renal artery stenosis include best medical therapy (BMT) or renal artery stenting (RAS)
- We present a case of patient with poorly controlled blood pressure, despite maximum medical management and renal artery stenosis

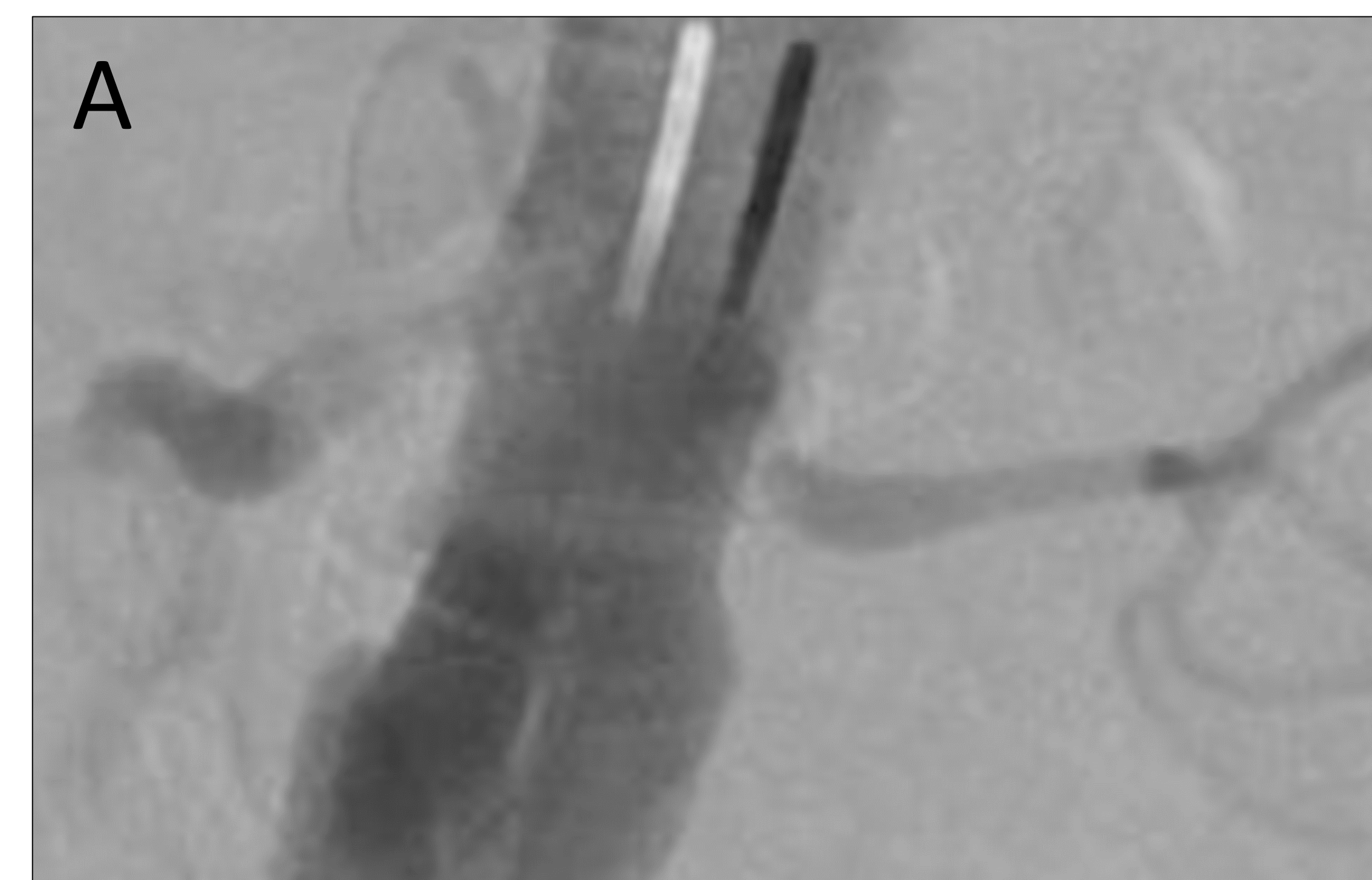
## CASE PRESENTATION

- 66-year-old male with a long-standing history of hypertension refractory to BMT, progressive renal insufficiency, and prostatic obstructive uropathy
- Despite undergoing transurethral prostatectomy, his renal function continued to decline
- **Pelvic magnetic resonance angiogram (MRA):** Bilateral renal artery stenosis
- **Computed tomography angiogram (CTA):** 80% occlusion of left renal artery, 60% occlusion of right renal artery, and left renal atrophy (**Figure 1**)
- **Operative Plan:** Aortogram with bilateral renal angiogram (**Figure 2A**) followed by balloon angioplasty and stenting of both renal arteries (**Figures 2B, C**)
- **Post-Operative:**
  - Immediate post-operative period revealed improvement in blood pressure and renal function
  - One-month follow-up showed no significant change in blood pressure from pre-operative visit

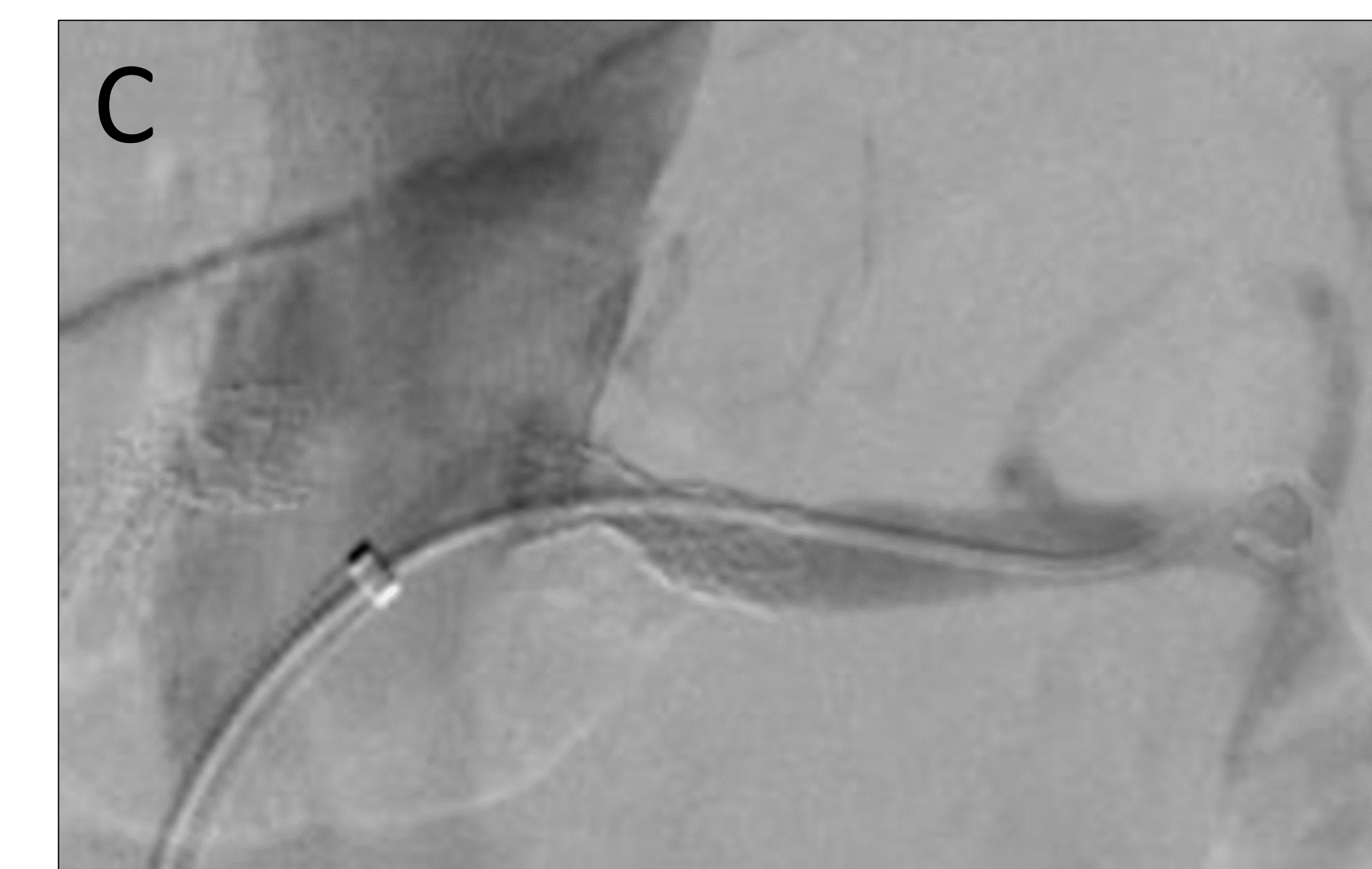
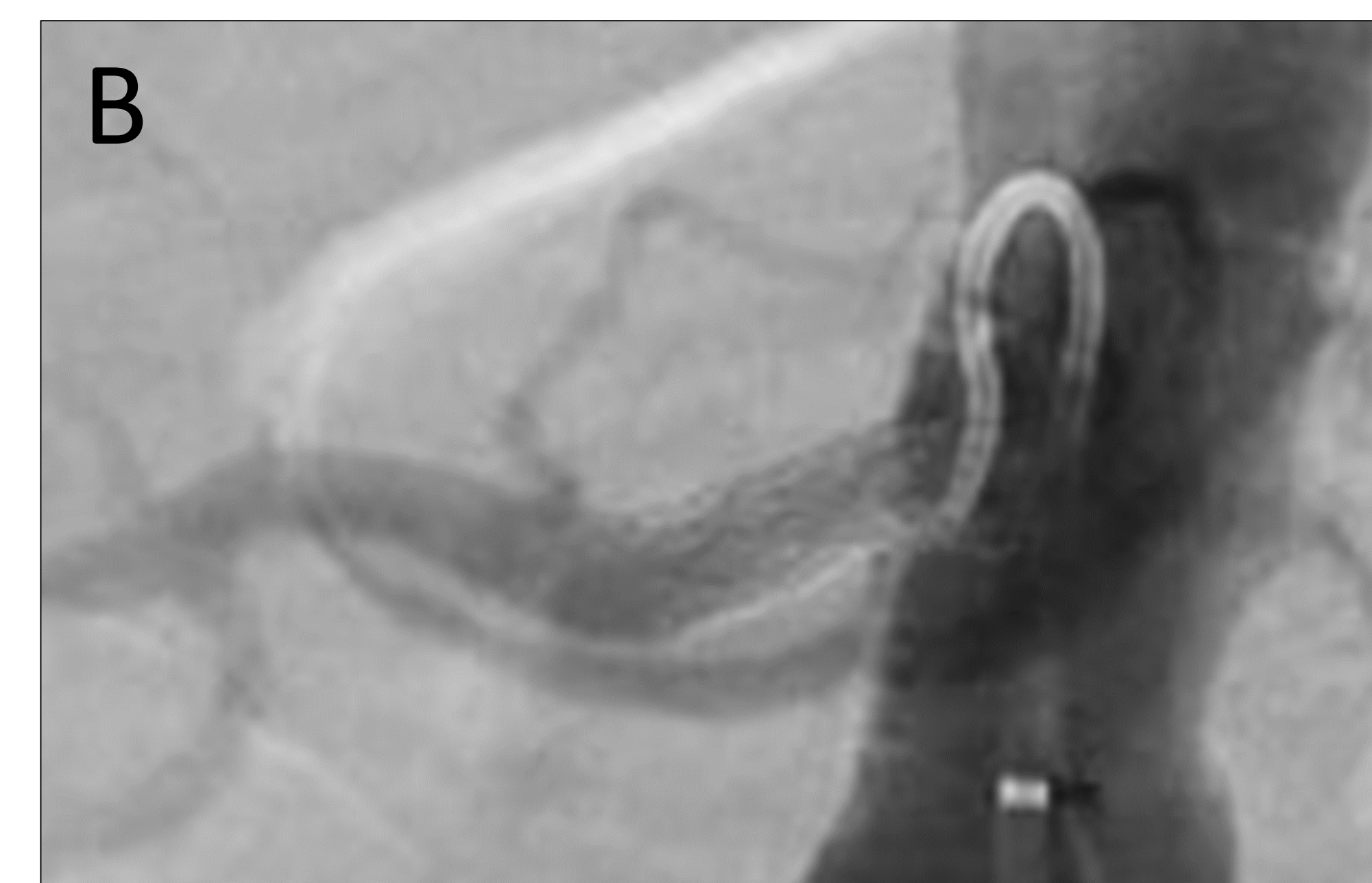
## IMAGES



**Figure 1:** Pre-operative CTA revealing left renal atrophy



**Figure 2:** Intraoperative aortogram confirming bilateral renal artery stenosis (A); RIGHT renal stent (B); LEFT renal stent (C)



## DISCUSSION

- Recent data gathered from renal artery stenting has been disappointing
- Multiple randomized controlled trials have shown conflicting results
- Some patients show improvement with intervention while others have had adverse outcomes due to renal reperfusion
- When deciding to intervene, it is important to consider the extent of renal atrophy
- Kidneys that have atrophied to a length less than 7cm are unlikely to benefit from revascularization
- Intervention was performed on this patient because he showed an inadequate response to BMT, his renal function continued to decline, and he had not yet developed extensive renal atrophy

## CONCLUSION

- Current data demonstrates that renal artery stenting is not be the best initial approach to treating renal artery stenosis
- Intervention is usually reserved for cases in which all other treatment options have been exhausted
- Ultimately, the decision to intervene is made on a case-by-case basis after discussion between the surgeon, nephrologist, and patient