

# FUSOBACTERIUM NUCLEATUM BRAIN ABSCESSSES IN AN IMMUNOCOMPETENT ADOLESCENT WITH DENTAL BRACES

Gavely Toor, DO, PGY-3, Kimberly Martin, DO, MPH

Department of Pediatrics, University of Oklahoma School of Community Medicine, Tulsa, OK

## INTRODUCTION

- *Fusobacterium nucleatum* is an anaerobic, non-spore forming, gram-negative bacilli commonly found in soil, respiratory tracts of animals, and oropharynx of healthy populations.
- Dental plaque infections with *Fusobacterium spp.* are more common in adolescents and may lead to periodontal disease.
- *Fusobacterium spp.* are capable of causing invasive disease commonly associated with otitis media, tonsillitis with Lemierre syndrome, gingivitis, and oropharyngeal trauma.

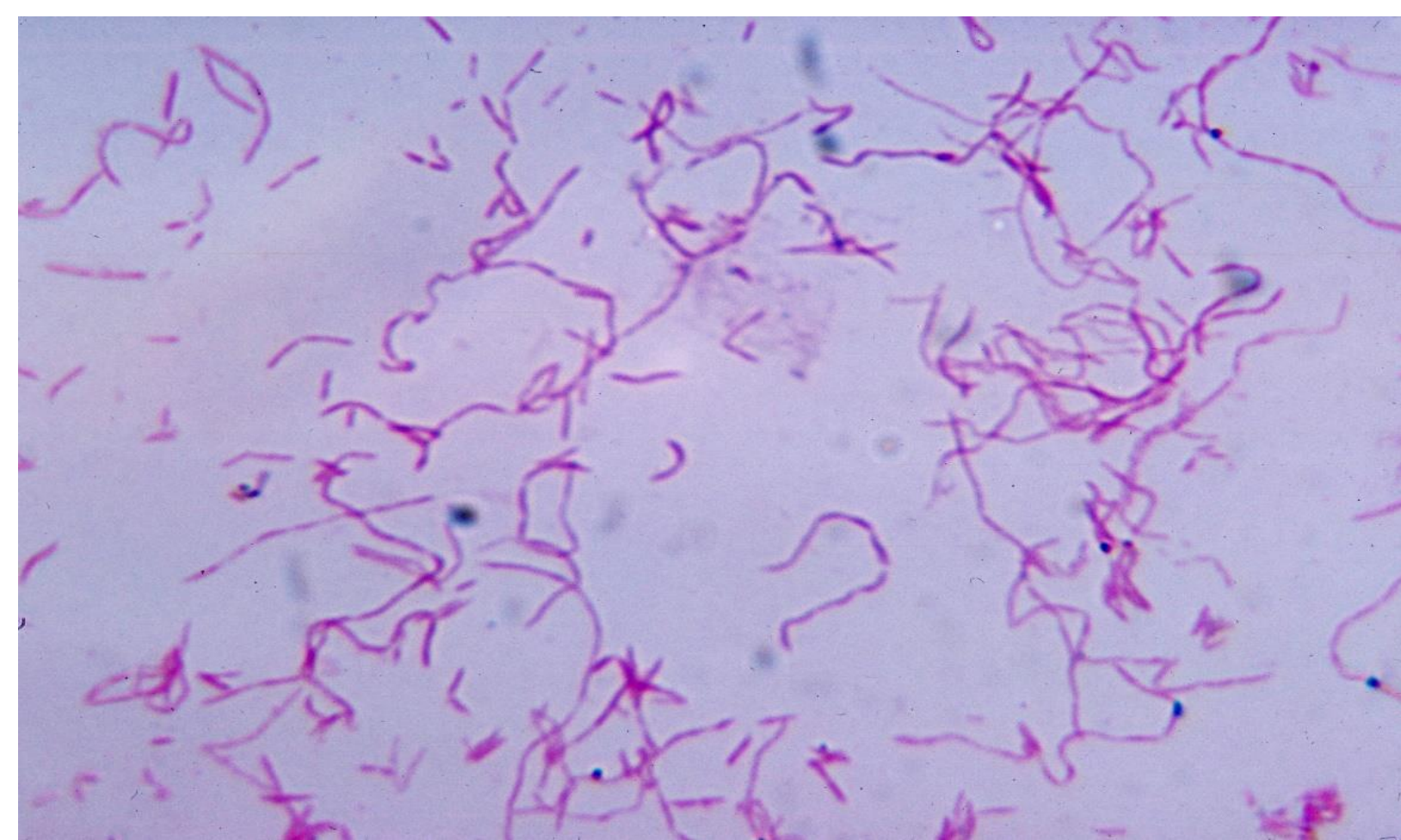


Figure 1: *Fusobacterium nucleatum* after being cultured in liquid thioglycollate medium

## CASE PRESENTATION

- 16-year-old, previously healthy male, with dental braces and poor oral hygiene
- Three day history of non-specific symptoms of fevers, chest pain, and lower back pain.
- Acute development of headache, neck pain, and vomiting.

## CASE DESCRIPTION

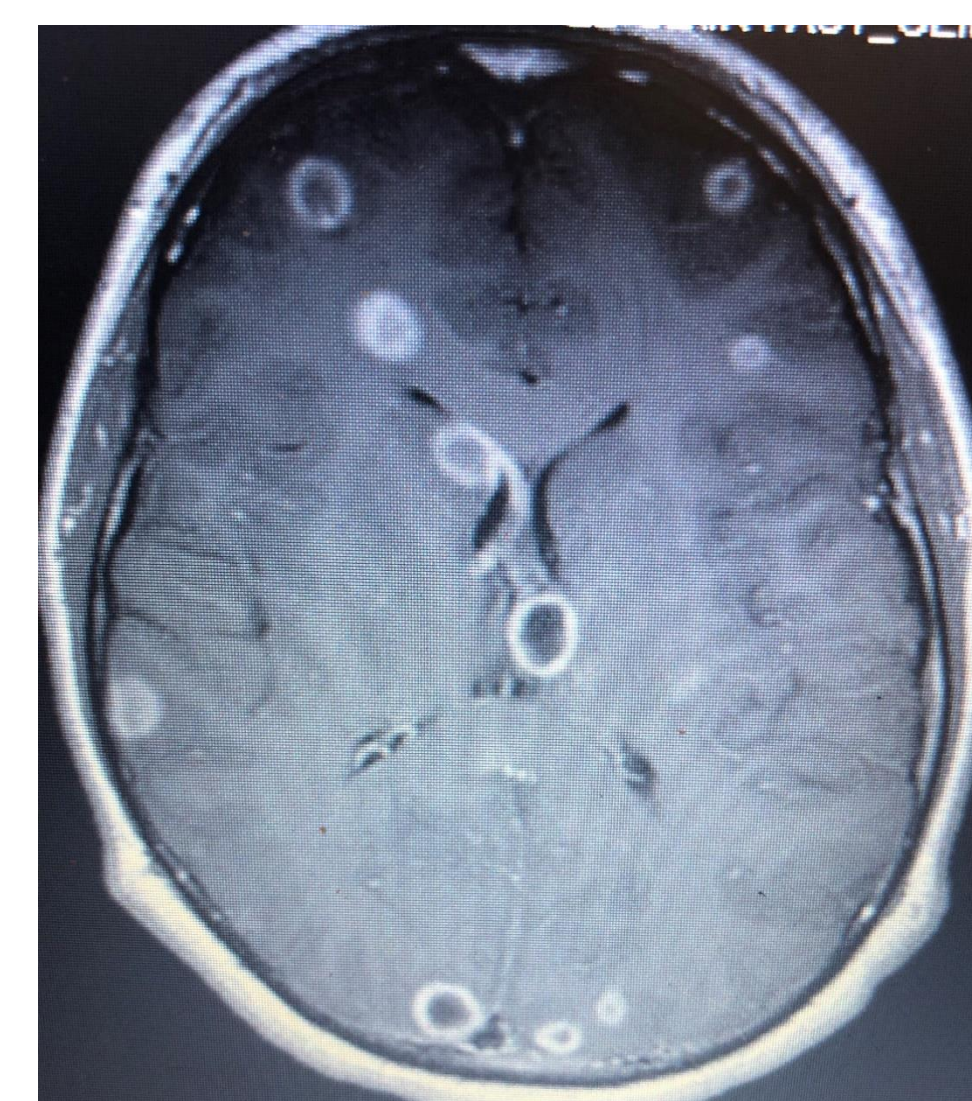
### DIFFERENTIAL DIAGNOSIS

Meningitis caused by bacterial, viral, fungal, or parasitic organisms.

### PERTINENT STUDIES

**CSF:** WBC 18,440 with 91% neutrophils  
RBC 1,260, Glucose 34, Protein 222  
No growth in pre-treated culture.

### MRI Brain:



- Numerous ring-enhancing lesions concerning for multiple cerebral abscesses versus Neurocysticercosis.
- Imaging inconsistent with Neurocysticercosis as reviewed by national experts.

Negative Serum serology for Neurocysticercosis  
Normal Fungal and Immune studies.

**CSF 16s PCR Analysis:** *Fusobacterium nucleatum*

### FINAL DIAGNOSIS

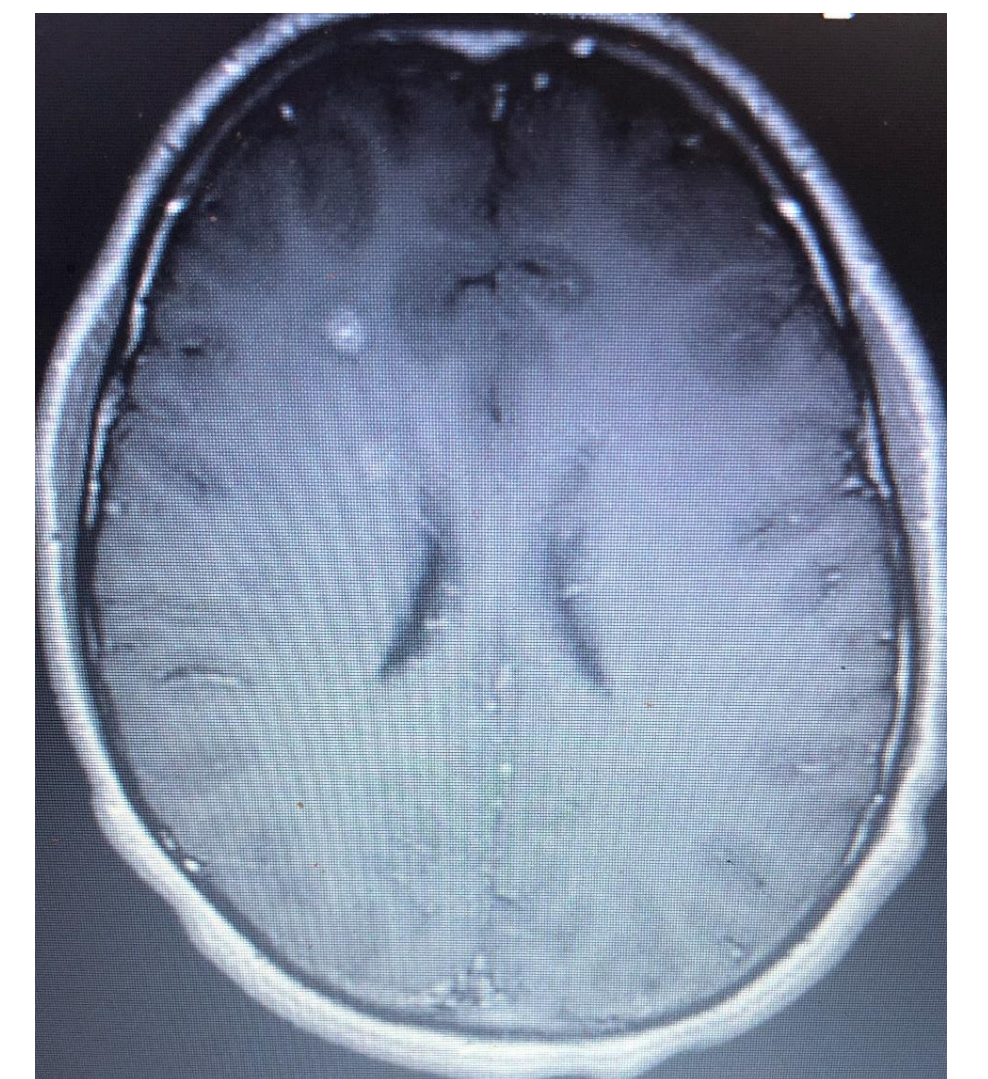
Cerebral abscesses caused by *Fusobacterium nucleatum*.

### TREATMENT

- Triple antibiotic therapy with ceftriaxone, vancomycin, and metronidazole for 8 weeks
- Repeat MRI Brain during and after antibiotic therapy

## DISCUSSION & REVIEW

- Dissemination of the organism to the brain was likely caused by underlying periodontal disease secondary to patient's poor oral hygiene.
- **Repeat CSF analysis:** Significant improvement in pleocytosis (WBC 169)
- **Repeat MRI Brain:** Decreased size of ring-enhancing lesions. No new lesions identified.
- There is very limited data available to identify the role of *Fusobacterium spp.* in dissemination to the brain.



## CONCLUSION

Due to this uncommon cause of brain abscesses, *F. nucleatum's* role in causing disseminated disease in healthy populations should be further investigated.

## REFERENCES

- Han YW. *Fusobacterium nucleatum*: a commensal-turned pathogen. *Curr Opin Microbiol.* 2015;23:141–147. doi:10.1016/j.mib.2014.11.013
- Jacinto RC, Montagner F, Signoretti FG, et al. Frequency, microbial interactions, and antimicrobial susceptibility of *Fusobacterium nucleatum* and *Fusobacterium necrophorum* isolated from primary endodontic infections. *J Endod* 2008; 34(12):1451–1456
- Zhou Z, Chen J, Yao H, Hu H. *Fusobacterium* and Colorectal Cancer. *Front Oncol.* 2018;8. doi:10.3389/fonc.2018.00371