

RIGHT SUPRACLAVICULAR LYMPHADENITIS CAUSED BY KIKUCHI-FUJIMOTO DISEASE

Gavely Toor, DO, PGY-3¹ Keith Mather, MD¹ Ama Karikari, MD¹ Gregory Kirkpatrick, MD²

¹Department of Pediatrics, University of Oklahoma School of Community Medicine, Tulsa, OK

²Department of Pediatric Hematology/Oncology, The Children's Hospital at Saint Francis, Tulsa, OK

INTRODUCTION

- Kikuchi-Fujimoto is a rare and self-limiting condition with unknown etiology that is most commonly seen in young Asian women.
- It usually presents with low grade fever that varies from one week to one month, cervical lymphadenopathy between 2-7cm, and other non-specific symptoms including rash, arthralgias, fatigue, night sweats, and weight loss.
- Histopathology of the involved lymph node typically differentiates it from more serious, life-threatening conditions that mimic similar clinical features, such as Lymphoma.

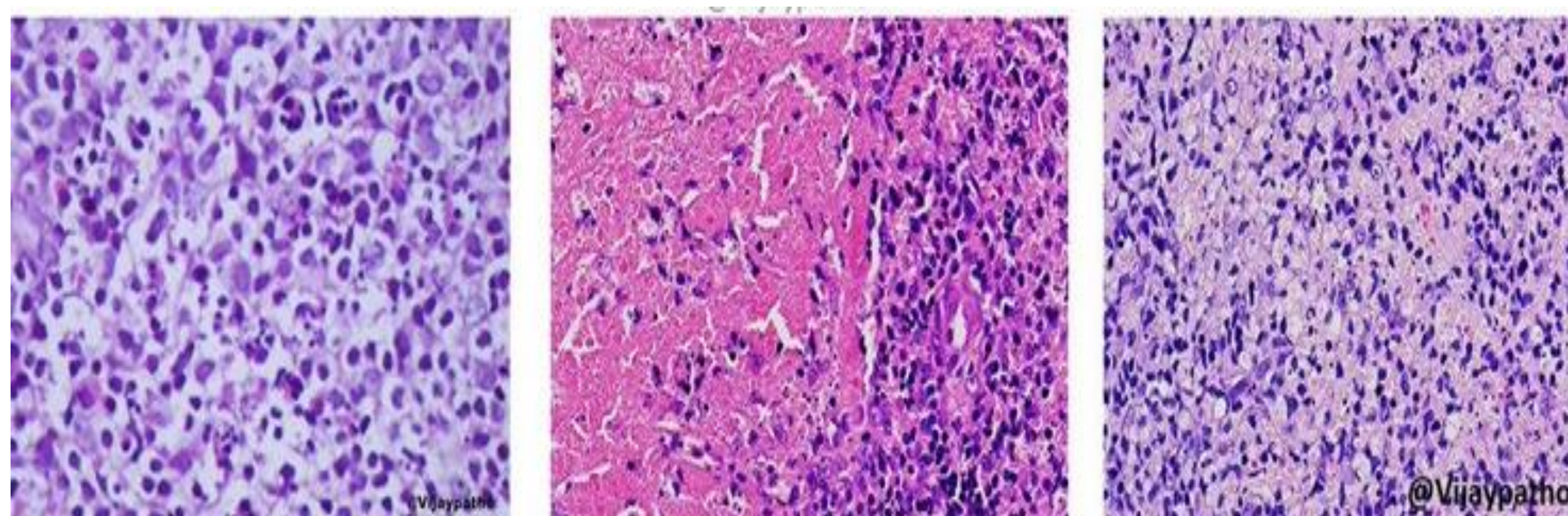


Figure 1: Three phases of histiocytic necrotizing lymphadenitis

A. Proliferative phase: increased histiocytes.

B. Necrotizing Phase: histiocytes with necrosis.

C. Xanthomatous Phase: Foamy histiocytes with necrosis

CASE PRESENTATION

Previously healthy 15-year-old, African-American male, with a two week history of fatigue, low grade fever, and cervical lymphadenopathy with a prominent right supraclavicular lymph node.

CASE DESCRIPTION

DIFFERENTIAL DIAGNOSIS

Lymphoma, Non-tuberculosis Mycobacterium, Cat scratch disease, Toxoplasmosis, Systemic Lupus Erythematosus

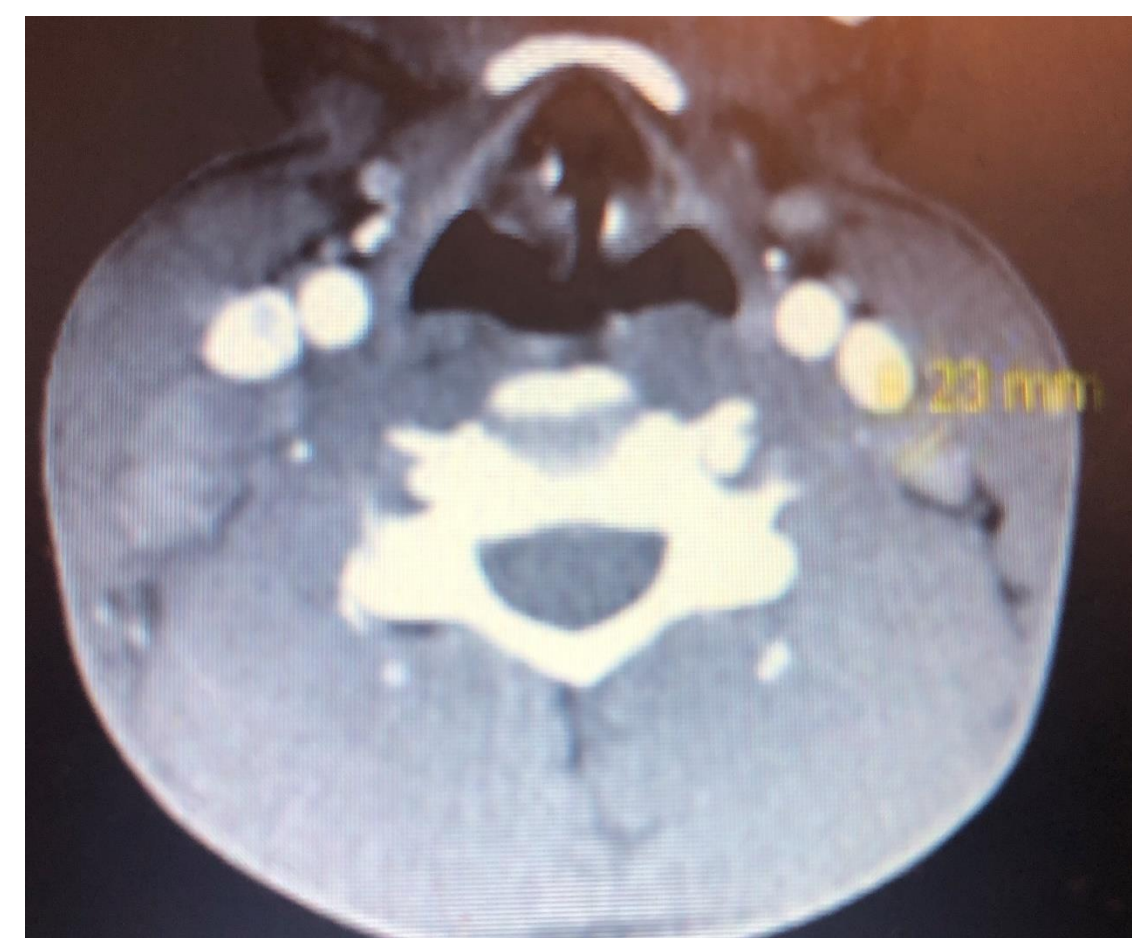PERTINENT STUDIES

WBC 2.7, Hgb: 10.8, EBV titers IgM+ and IgG+

ESR 62, LDH 396, Retic count 0.29

Peripheral smear- microcytic normochromic anemia

CT Neck –bilateral cervical chain lymphadenopathy with a right supraclavicular lymph node measuring 2.5 x 1.6 cm



Excisional biopsy –reactive lymphadenitis with focal areas containing lympho-histiocytic infiltrate and no neutrophilic infiltration

Immuno-chemistry stain with CD68 +histiocytes

FINAL DIAGNOSIS

Right supraclavicular lymphadenitis caused by proliferative phase of Kikuchi-Fujimoto Disease

TREATMENT

- Self-limiting within one to four months
- Routine follow-ups

DISCUSSION & REVIEW

- Here is a very rare case of Kikuchi-Fujimoto disease preceded by EBV in a young African-American male.
- Etiology is unknown but preceding viral etiology has been proposed, such as EBV, HHV-6, HIV, Parvovirus, or Parainfluenza, or even bacterial etiology with *Yersinia enterocolitica* or Toxoplasma.
- Although it is a self-limiting condition, patients should be followed within one to four months for recurrence and increased risk of developing systemic lupus erythematosus.

CONCLUSION

This intriguing case of an uncommon cause of right supraclavicular lymphadenitis prompts investigation and recognition by physicians and pathologists for commonly misdiagnosing as lymphoma and initiating treatment with cytotoxic agents.

REFERENCES

- Asano S, Akaike Y, Jinnouchi H, et al. Necrotizing lymphadenitis: a review of clinicopathological, immunohistochemical and ultrastructural studies. *Hematol Oncol* 1990; 8:251.
- Batton E, Alali M, Hageman JR, et al. Kikuchi-Fujimoto Disease in Children: An Important Diagnostic Consideration for Cervical Lymphadenitis. *Pediatr Ann* 2019; 48:e406.
- Seo JH, Shim HS, Park JJ, et al. A clinical study of histiocytic necrotizing lymphadenitis (Kikuchi's disease) in children. *Int J Pediatr Otorhinolaryngol* 2008; 72:1637.
- Wang TJ, Yang YH, Lin YT, Chiang BL. Kikuchi-Fujimoto disease in children: clinical features and disease course. *J Microbiol Immunol Infect* 2004; 37:219.