CELLS IN CANINE MAMMARY GLAND FLUIDS ASSOCIATED WITH PARTURITION, PSEUDOCYESIS AND TUMOR

By

JEFFIE FISHER ROSZEL

Veterinariae Medicinae Doctoris

University of Pennsylvania

Philadelphia, Pennsylvania

1963

Submitted to the Faculty of the Graduate College
of the Oklahoma State University
in partial fulfillment of the requirements
for the Degree of
DOCTOR OF PHILOSOPHY
May, 1975

CELLS IN CANINE MAMMARY GLAND FLUIDS

ASSOCIATED WITH PARTURITION,

PSEUDOCYESIS AND TUMOR

Thesis Approved:

Thesis Adviser

Dean of the Graduate College

ACKNOWLEDGEMENTS

I appreciate this opportunity to express my thanks to those who have helped me to achieve this goal.

I am grateful for the continued guidance I have received from Dr. A. W. Monlux. Dr. B. L. Glenn has often given encouragement when it was needed. I appreciate the help offered to me by other members of my committee, Dr. R. G. Buckner and Dr. M. L. Frey.

I appreciate the technical assistance given so willingly by Mr. Tom Palmer. The many excellent photographs were taken by Mr. Fred Lawson. The patience and cheerful attitude of Miss Majel Stites while typing the manuscript brought to a conclusion a difficult but enjoyable experience.

TABLE OF CONTENTS

LIST OF TABLES

LIST OF FIGURES

Chapter Page

Figure Page

Figure Page

Figure Page

CHAPTER I

INTRODUCTION

The analysis of body fluids for the purpose of evaluation of the health status of an individual has been used in clinical medicine for many years. Chemical and cellular examination of the blood was one of the earliest and remains one of the most frequently utilized laboratory tests in human and veterinary medicine. Neoplasms arising from cell types that normally occur in the blood have been diagnosed. This is possible by the recognition of morphologic changes in these cells and usually their increased number in the peripheral circulating blood as well as bone marrow.

A new technique for diagnosis of cancer originating in cell types other than blood cells emerged from the work of Papanicolaou and Traut (1). They demonstrated genital cancers in women could be diagnosed by recognition of morphologic changes in cells collected from vaginal fluids. Their conclusions have been reaffirmed by numerous investigators. From these efforts emanated the now famous "Pap" test concerned primarily with detection of uterine cervical cancer in women. The life-sparing effect of the "Pap" test has been due, in part, to the recognition of this progressive lesion at an early stage when it has not yet invaded adjacent connective tissue. At this time in clinical development, the lesion may be more readily eradicated

and a favorable prognosis may follow. Recognition of cellular changes compatible with such epithelial in situ lesions was enhanced by studies of mice with chemically induced vagino-cervical cancer as an experimental model. Comparison of cells in vaginal smears and corresponding histologic preparations from animals killed during sequential phases of developing lesions contributed to the knowledge of the cytologic and histologic stages of tumorgenesis of cervical cancer.

In addition to genital cancer, carcinoma of the breast is a major human health problem due to its high incidence and fatal termination is expected if not treated (2). Various techniques such as palpation, thermography and mammography are currently being evaluated as possible methods to detect early breast cancer (3). Cytologic evaluation of breast fluids has been used to diagnose this neoplasm in a limited number of cases. The absence of breast secretion in many cases has restricted the use of cytology at this site. Animal models offering a spontaneous or induced mammary tumor similar to those in women have been superficially explored.

Cancers arising in mammary glands are as common in bitches as they are in women. A similarity in these tumors in both species also exists in that the malignant neoplasms arise almost exclusively in the epithelial component of the gland (4,5,6). Apparently unlike the majority of glands in women, fluids can be collected from the normal gland of bitches at times other than in association with parturition. This study is directed to the investigation of canine mammary gland fluids to determine if cellular components in those animals with tumor differ from those with no clinical evidence

of tumor and also to determine if the canine mammary carcinoma may offer a model through which may arise a better understanding of human breast cancer.

CHAPTER II

REVIEW OF SELECTED LITERATURE

The purpose of this report is to determine if cytologic differences may be seen in mammary fluids that were expressed from clinically normal glands and also from glands with tumor. The mammary gland is a target tissue for specific hormones and responds to this stimulation by changes that involve the epithelium. Since these epithelial cells line the mammary tubular system through which the fluid passes, information from reports on morphologic changes are presented. There is a sparsity of reports on the cytology of mammary fluids from dogs. Selected references on the cytology of human breast fluids therefore are included.

Early mammary development is seen in the embryo as bilateral linear thickening. There are usually five paired foci in the dog that are located from the axillary to the inguinal region. Each focus gives rise to a separate gland. The epithelial thickenings form the teat and extend as buds into the underlying connective tissue. These buds develop only to the stage of tubules that end blindly until puberty. The immature gland is shown in Figures 1 and 2.

When ovarian activity begins the tubules expand forming the major ducts and branching from the major ducts develop with multiple alveoli at their terminal areas. Each duct forms a separate lobe composed of lobules

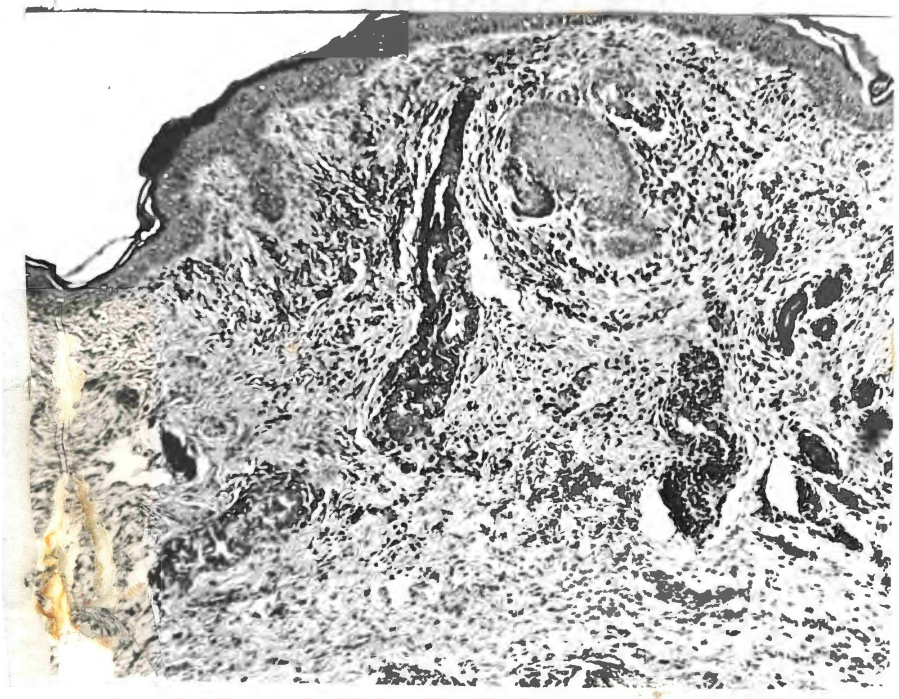

Figure. Teat and the L_4 Rudimentary Gland from Three Week Old Male Dog. (H&E x75)

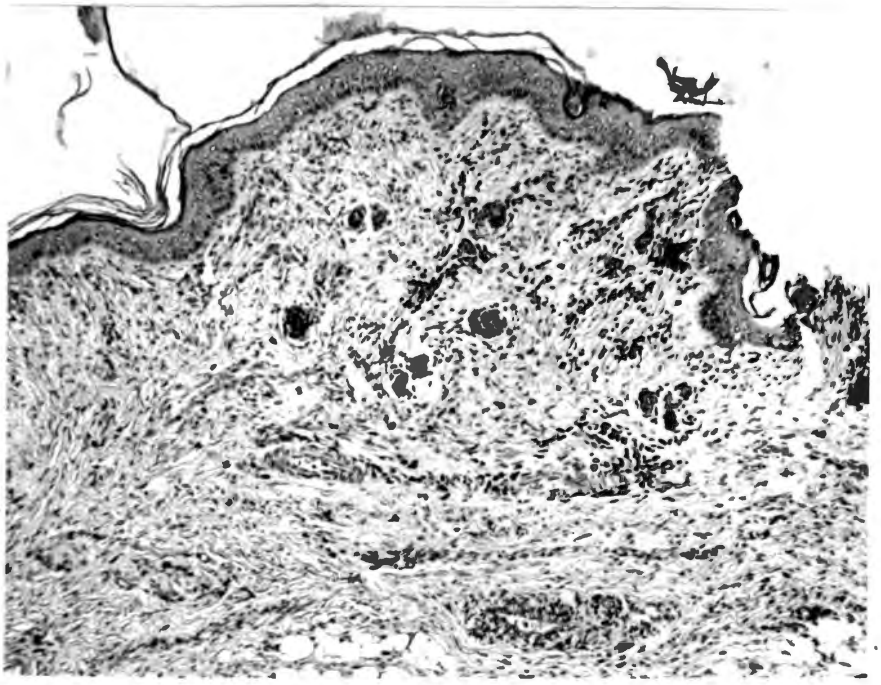

Figure 2. The L_4 Teat and Blindly Ending Mammary Tubules in Same Neonatal Animal Shown in Fig. 1 but at Deeper Level. (H&E x75)

containing terminal tubules and alveoli. The number of major ducts is reported to be from two to twenty. It has been demonstrated that there are more ducts in the tip than the base of the teat suggesting the higher counts may include ducts which end blindly within the teat (7).

There is a rhythmic change in the mammary tissue related to the canine estrous cycle. Evans and Cole (8) described this cycle as containing four phases: 1) Proestrus begins with vaginal bleeding and has an average duration of 9 days. 2) Estrus is the phase during which the bitch will accept the male and spontaneous ovulation occurs. This phase lasts about 9 days. 3) Metestrus is the phase of luteal activity and in the bitch is prolonged (about 3 months) due to the persistence of the corpus luteum independent of pregnancy or coitus. 4) Following metestrus is the period of relative hormonal quiescence called anestrus. This phase lasts about 3 months and is followed by the active phase of the cycle.

Silver (9) and Turner and Gomez (7) compared mammary glands from pregnant and non-pregnant bitches and indicated there was comparable development of the gland up to 30 or 40 days after estrus. During this time there was an increase in the size of the major ducts, increase in number of secondary and tertiary ducts and the appearance and gradual increase in acini. Following this period the increased size of the gland was due primarily to dilatation of the acini with secretions from acinar epithelial cells.

Huggins and Moulder (10) found mammary fluid could be expressed from pregnant bitches a few days prior to parturition. There was marked variation in duration of secretion among animals and among glands in the

same animal. This was true for postparturient bitches and those in pseudocyesis. However, secretions were usually more copious and of longer duration in the inguinal glands. No fluid could be expressed from mammae of 10 dogs from 16 to 55 days after weaning. Secretion associated with pseudocyesis was seen to persist for 4 months in one virgin bitch.

Involution of the glands following parturition and pseudocyesis was gradual with continuing loss of the acinar structures until the gland was a simple duct system but was more extensive than the prepubertal gland (9).

Few publications could be found on the cellular population of canine mammary fluids. The numbers of cells that contained fat droplets stained by Sudan III have been evaluated in specimens collected from normal dogs in the pre-parturient period, during nursing and after weaning (10). These cells considered macrophages were termed "colostrum corpuscles". As many as 100,000 per cu. mm were seen after weaning and in pre-parturient periods but were rarely present during suckling. Between 1,000 and 120,000 per cu. mm of these cells were seen in fluids from 19 glands that contained tumor. Other reports on cells believed to originate from mammary carcinomas briefly described the morphology of such cells (12). Two other reports described mammary carcinoma cells from metastatic foci at other anatomical foci (13,14).

The normal human female breast generally has no recognizable secretion except that associated with parturition. In a study of 917 non-pregnant women without breast complaints, Papanicolaou, et al. (14) reported that breast secretions could be collected in a small percent of women who were premenopausal and had regular cycles. During the late luteal phase

of the cycle the greatest morphological development of the gland occurred and the largest number of secretions were collected. Papanicolaou, et al. (14) reported the cytologic appearance of secretion smears from non-pregnant women contained three basic cell types: 1) Foam cells, so named because of the abundant cytoplasm, were the most frequent cell type seen. With oil red O stains these cells contained abundant cytoplasmic lipid droplets. The nuclei contained one or two small nucleoli. They were usually mononuclear but binucleated and multinucleated forms sometimes were present. The cells appeared singly and in large loose clusters. This cell type was seen in specimens from patients ranging from 14 to 75 years of age and was indistinguishable from those seen in secretions collected during pregnancy, the postparturient period and in neonatal human nipple secretions. The number varied in nondiseased breasts from small to moderate. 2) Macrophages also were a cell type commonly seen. They resembled the foam cell in that the nuclear-cytoplasmic ratio was small and the cytoplasm was finely vacuolated. However, they were often smaller than the foam cells and contained ingested matter. Intermediate types between the foam cell and the macrophages sometimes were seen. Macrophage cells were present in smaller numbers in non-pregnant smears from clinically normal breasts. 3) Ductal epithelial cells were occasionally seen in secretions from healthy nonlactating breasts. When present, they usually appeared in small compact clusters. The cells were small with a round to oval densely stained nucleus. Nucleoli were rarely prominent and there was a small amount of homogenous cytoplasm.

Small numbers of polymorphonuclear leukocytes and lymphocytes were seen in some of the preparations made from normal breast secretions. Squamous epithelial cells also were present in the secretion from some breasts and were believed to originate from the nipple epithelium.

Secretions described by Holmquist and Papanicolaou (15) associated with pregnancy had the same cell types as described above but there was a consistent appearance of macrophages in large numbers. Many neutrophils also were seen immediately before and after parturition. During the latter half of pregnancy and the first postpartum week, ductal epithelial cells were seen in definite clusters and these cells were larger and their nuclei more prominent than in early pregnancy.

The above description of cells was considered normal and was reaffirmed by several investigators (16,17). The nomenclature has been changed however, so that the term histiocyte is now more frequently used than macrophage.

CHAPTER III

ANIMALS, METHODS AND EXPERIMENTAL DESIGN

Animals

The fifteen dogs used in this study were pet animals. Seven lived in the greater Tulsa area and were available through the currently active and National Institute of Health-funded Tumor Registry of Canine and Feline Neoplasms. Eight of the animals lived in or near Stillwater, Oklahoma. Six of these were studied while in the Veterinary Clinic at Oklahoma State University and the remaining two were not hospitalized.

All tumors included in this study occurred naturally.

Methods

Cytology Specimen Collection and Staining

The stain routinely used for cytologic preparations is a trichrome stain. Each specimen collection in this study had at least two slides stained with Pollak trichrome (13). Special stains were used in selected cases to identify some intracellular or extracellular material which was not identified with the Pollak trichrome. The special stains used were Oil Red O (ORO) (18) for neutral fats, Periodic Acid Schiff Hematoxylin (PAS) (19) for

mucopolysaccharides and Turnbull Blue (TB) (19) for hemosiderin.

Mammary fluids were collected by exerting digital pressure near the base of the teat. A drop of the expressed fluid was collected directly onto a slide that had been coated with 2% albumin and prelabeled with the owner's name, date of collection and gland identification. A second similarly marked and coated slide was placed flatly on top of the drop of secretion with the long axis of the slides being parallel. The slides were pulled in opposite directions along the length of the slides to leave a thin, even film of the secretion on each slide. The slides were immersed immediately and while still wet into fixative. Slides to be stained by a modified method of Pollak's trichrome were fixed in 95% ethanol. When additional slides were to be stained with ORO, PAS or TB, they were fixed in 10% acetate buffered formalin.

Smear Examination

Microscopic examination of the slides was done by viewing overlapping vertical fields throughout the length of the slide which contained the specimen. A binocular microscope fitted with a 12.5X eyepiece was used. The smears were examined using a 10X objective and areas of interest were examined with a 40X objective.

The smears were examined for smear pattern which included presence or absence of non-cellular background material and cellularity of the smear. Nomenclature as used with human breast cytology was used when there was a similarity in cellular morphology (16, 17). The various types of cells seen were recorded and their ratios noted. Clusters of cells were recorded along

with approximate number of cells within the cluster and their arrangement. The epithelial cells were examined with consideration of the features associated with malignancy as outlined by Papanicolaou (21).

Histologic Preparations

Tissue specimens from two of the animals (one pregnant bitch and one animal with a malignant mammary tumor) were collected from animals hospitalized at the Veterinary Clinics at Oklahoma State University. The remaining tissues were received through the Tulsa Tumor Registry of Canine and Feline Neoplasms.

All tissues were fixed in 10% acetate buffered formalin. Sections were cut at 6μ thickness and stained with hematoxylin and eosin. In selected cases, special stains were used. These included Prussian Blue (19) for hemosiderin, PAS (19) for mucopolysaccharides and ORO (18) on frozen sections for fat.

Experimental Design

Specimens were collected from animals selected to represent one of four following categories: 1) Animals with normal lactating glands associated with pregnancy. Pregnancy was determined by normal whelping or puppies delivered by cesarean section. The gland was considered normal if no palpable mass was detected following weaning or if no tumor was seen in histologic sections of the gland. 2) Animals with secretions associated with pseudocyesis. An animal with at least one secreting gland and a history

of a heat period two to four months previously during which there had been no known breeding was considered to be in pseudocyesis. The gland was considered tumor free if there was no palpable mass after cessation of secretion or if histologic sections of the gland contained no tumor. 3) Those with fluid in a gland that contained a benign mammary tumor. Excision of the total gland and histologic classification was required for all animals in this group. 4) Animals with fluid in a gland that contained a mammary carcinoma. Excision of the gland and histologic preparations were required for all animals selected for this group.

Multiple glands in the same animal were studied when this was possible to determine if there might be cytologic differences related to gland location. Sequential collections were made from the same gland for as long as the animal was available or until secretion ceased.

The location of the glands were designated as R or L referring to the animal's right or left side. The location within the right or left chain was indicated by an Arabic number with the most anterior gland designated as number 1. Thus, the symbol R_3 would refer to the third most cranial gland in the animal's right chain of mammary glands.

CHAPTER IV

RESULTS

Group 1 - Animals with Lactating Glands Associated with Pregnancy

Clinical Data

The age of the five animals in this group ranged from 1 to 6 years with four of the five being two years old or younger. It was the first whelping for three of the dogs. One of the animals had one previous litter and the six year old animal had whelped three previous litters. This clinical data is included in Table I.

Four of the animals were hospitalized during the collection of specimens. The remaining animal (Dog 2) had been hospitalized during pregnancy but was at home during the period of cytology specimen collection. In one dog (Dog 3) the puppies were delivered by cesarean section on the sixtieth day of gestation. All others whelped normally. The cesarean section delivered puppies were not allowed to nurse. All other bitches nursed their puppies (Table II).

TABLE I

CLINICAL AND CYTOLOGIC DATA ON PREGNANT BITCHES - GROUP 1

Animal Identification	Breed	Age	Number of Previous Whelpings	Identification of Glands Studied	
				Preparturient	Postparturient
Dog 1	Pointer	6 yr	3	0	R_1, R_4
Dog 2	Norwegian Elkhound	2 yr	0	L_1, L_5	L_1, L_5
Dog 3	Cocker Spaniel	1.5 yr	1	R_2, L_2, L_5	R_2, L_2, L_5
Dog 4	Mixed Breed	1.5 yr	0	0	L_5
Dog 5	Miniature Schnauzer	1 yr	0	R_4, R_5	R_4, R_5

TABLE II

CYTOLOGY SPECIMEN COLLECTIONS RELATED TO NURSING AND PARTURITION

Animal Identi-fication	Suckling History	Preparturient Day(s) of Specimen Collection	Postparturient Day(s) of Specimen Collection	Comments
Dog 1	Puppies not nursing at time of specimen collection.	-	6 to 11, 10 to 15	Owner unsure of whelping date. Animal hospitalized for chronic dermatitis.
Dog 2	Puppies weaned 1 week prior to last collection.	2	19, 38	Animal had clinically diagnosed herpetic conjunctivitis and vaginitis during pregnancy.
Dog 3	Puppies not allowed to nurse.	1	4, 8, 12, 16, 18, 25	Puppies delivered by cesarean section due to suspected infection of bitch with Brucella canis.
Dog 4	Puppies nursed for 3 days.	-	5	Animal died suddenly of unknown cause. Owner permitted removal of gland but not complete necropsy examination.
Dog 5	Puppy nursing at last specimen collection date.	1	1, 3, 4	Pregnancy unknown to owner and animal hospitalized due to belief she was in pseudocyesis.

Cytology Specimen Collection

A total of ten glands from five dogs were represented by cytology specimens. Seven of these glands were studied by collections both before and after parturition. Samples from three glands in two animals were taken only after parturition. More than one collection was taken from all glands except for the single gland studied in Dog 4. This animal was hospitalized on the fifth postpartum day with acute onset of central nervous system signs. The animal died approximately six hours after specimen collection.

The earliest preparturient collection was two days before whelping and the longest interval after parturition was 38 days. Both of the collections were from the same animal, Dog 2.

Dog 3 had the most numerous collections. Seven collections were made from her glands. These ranged from one day before to 25 days after cesarean section.

Observation of Smears

All smears from Dogs 2, 3, 4 and 5 were similar and will be described together. An exception to this was R_2 of Dog 3. The cytologic appearance of this gland will be described later.

The smears had a background of finely granular material filled with multiple spheres of various sizes. At the high magnification many of the spheres appeared to be hollow but approximately one fifth of them had a small crescent-shaped nucleus closely pressed against the sphere (Fig. 3)

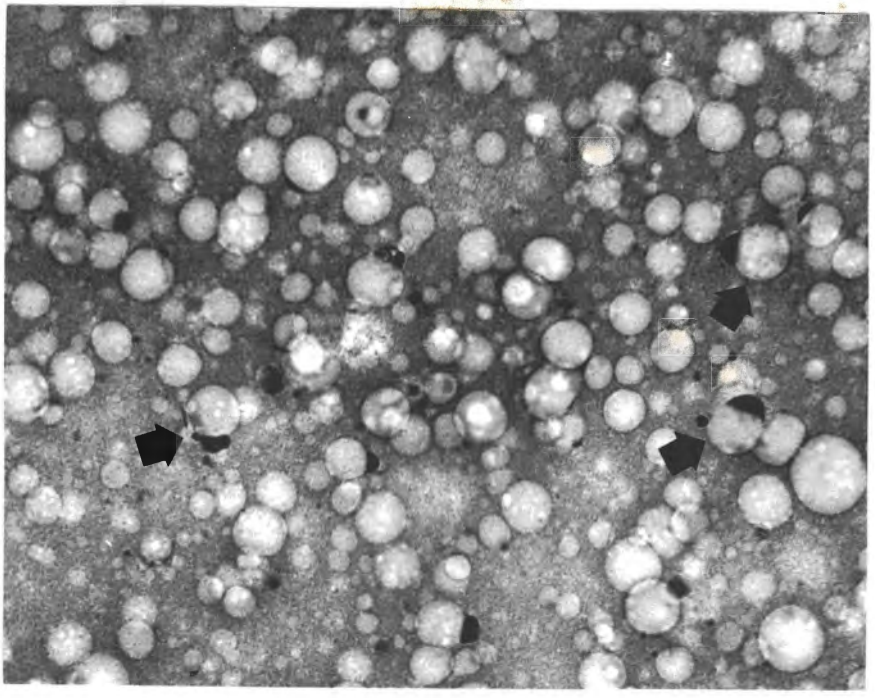

Figure 3. Smear from the L5 Gland in Dog 4. Arrows Indicate Signet Cell. (Pollack Trichrome x480)

and are called signet cells. These cells stained positive with ORO (Fig. 4) and many anucleated spheres of lipid were seen (Fig. 5). PAS positive material was not seen in the signet cells (Fig. 6). Excluding the signet cells, the smears contained only a few cells. Foam cells resembling those seen in human breast smears were occasionally seen (Fig. 7). These were usually single but a few clusters of up to 15 cells were recorded. Cells within the clusters tended to be smaller than when seen alone and it was not always possible to distinguish them from histiocytes. The foam cells contained few to many PAS positive granules that varied in size (Fig. 8). Very few neutrophils or lymphocytes were seen and no smear contained more than very few erythrocytes. Ductal epithelial cells were seen in Dog 4. They were rarely seen and occurred in clusters of three to six cells. The nuclei were often homogenous suggesting degeneration (Fig. 9). Surface squamous epithelial cells and clusters of keratinous material (Fig. 10) were routinely seen in not only this group of animals but all slides examined.

R_2 gland in Dog 3 followed the above described pattern until the last date of collection which was the twenty-fifth day following cesarean section. The smear was filled with histiocytes containing many vacuoles of various sizes and a large number of neutrophils (Fig. 11). The signet cells and the lipid background persisted.

Smears from Dog 1 were markedly different from the other dogs in this group and the two glands differed from one another.

The first set of smears from R_4 were very cellular. In some areas the background material had ORO positive spheres but they were not numerous.



Figure 4. Smear from the L_5 Gland in Dog 4. Lipid Within Signet Cell (arrow) and Smaller Cells that are Neutrophils (ORO x780)

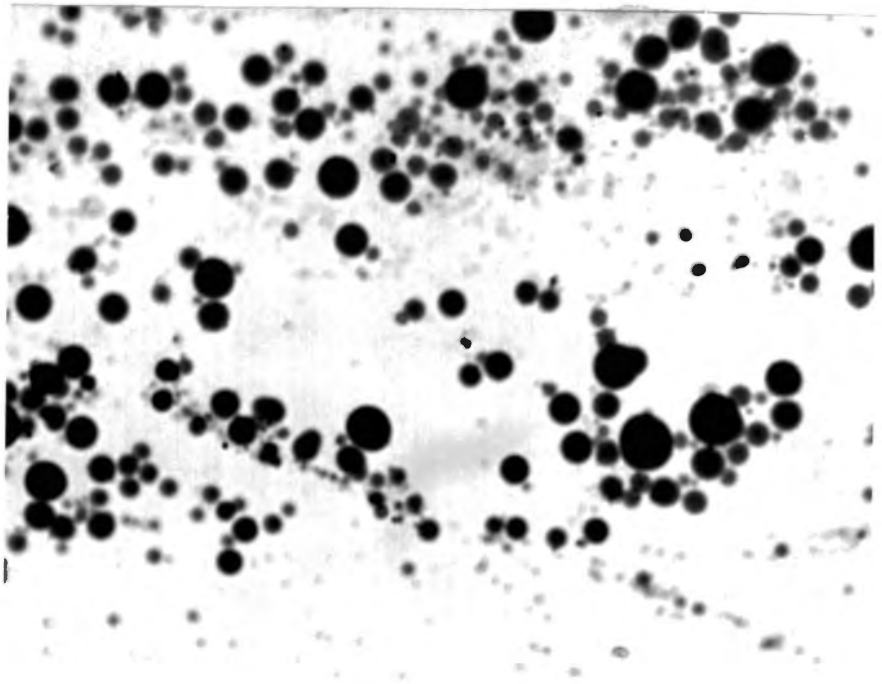

Figure 5. Smear from the L_5 Gland in Dog 4. Multiple Extracellular Fat Droplets are Shown. (ORO x480)

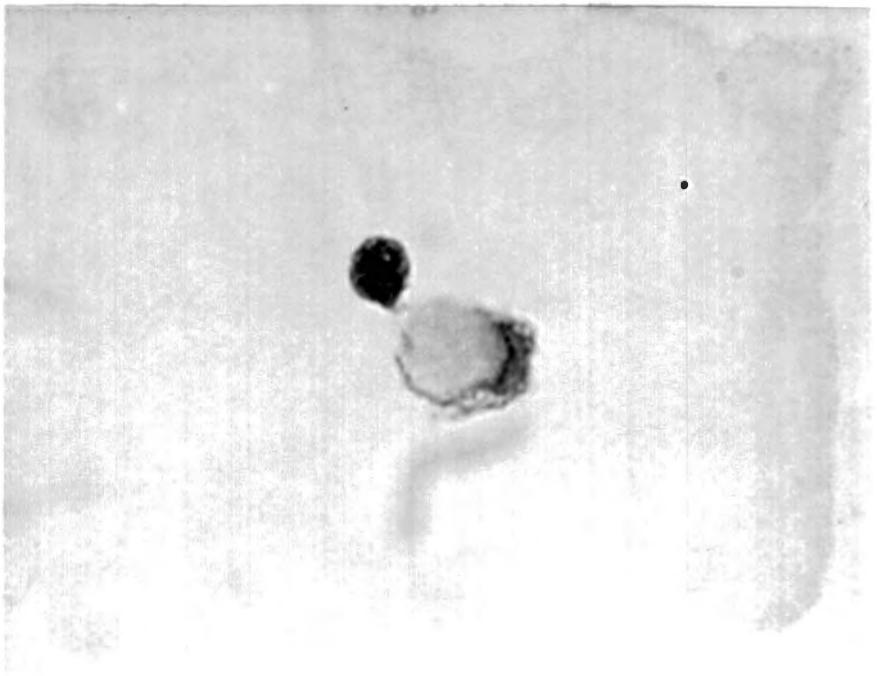

Figure 6. Smear from the L_1 Gland in Dog 2. Signet Cell with No Evidence of Mucopolysaccharide. Small Neutrophil Has PAS Positive Granules. (PAS x780)

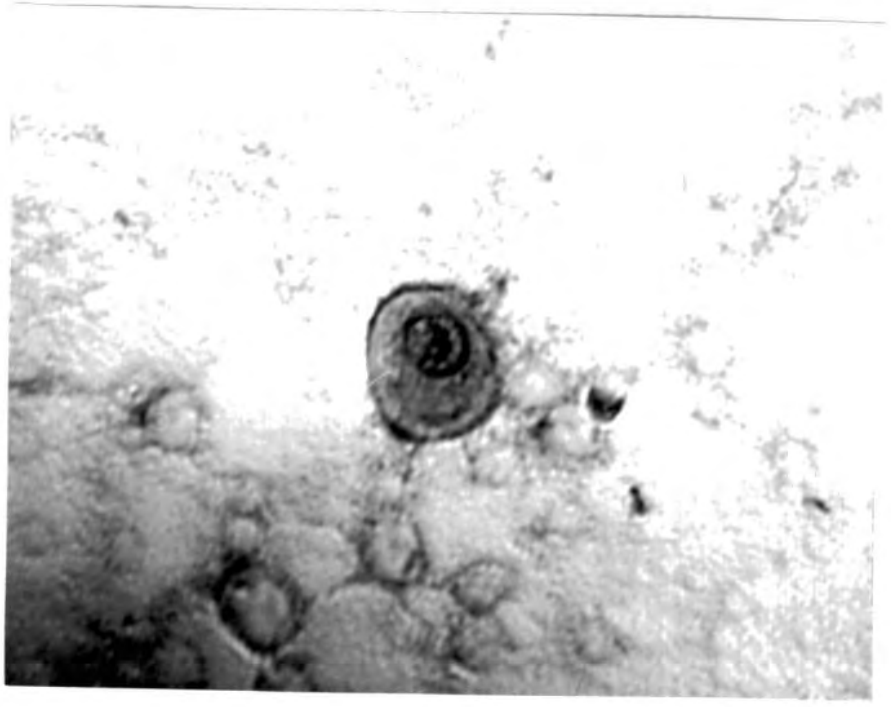

Figure 7. Smear from the R_2 Gland in Dog 3. A Single Foam Cell. (Pollak Trichrome x780)

Figure 8. Smear from the R_4 Gland in Dog 5. Foam Cell with Multiple PAS Positive Granules. The Smaller Cell Has a Few Small PAS Positive Granules. (PAS x780)

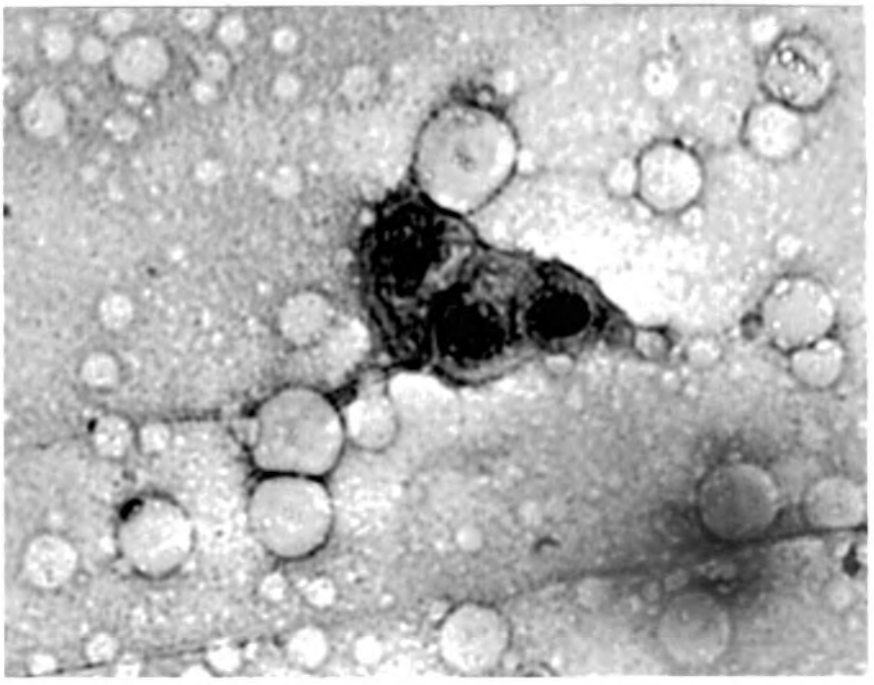

Figure 9. Smear from the L_5 Gland in Dog 4 Showing a Small Cluster of Degenerated Ductal Epithelial Cells. (Pollak Trichrome x780)

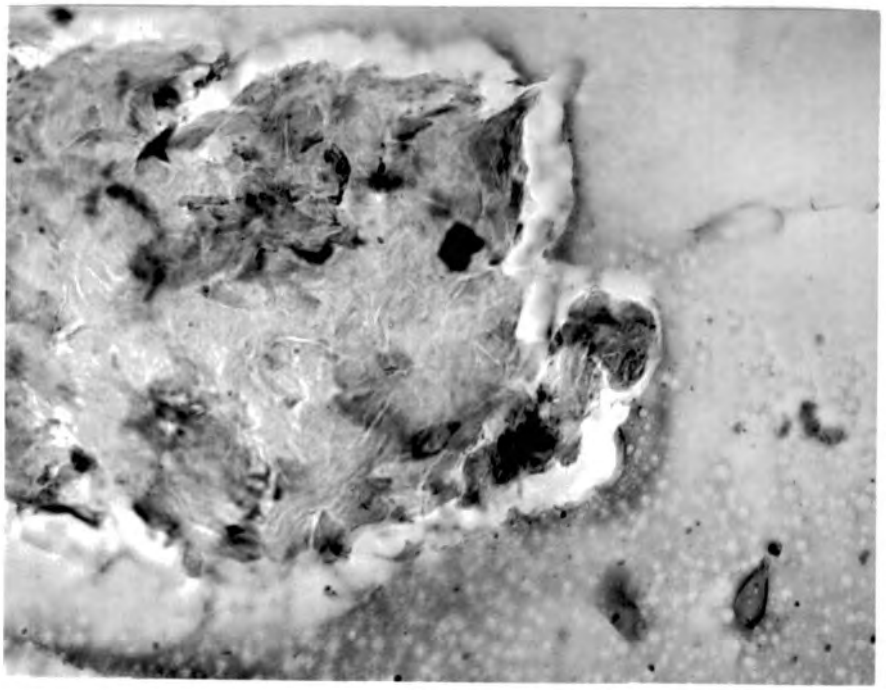

Figure 10. Smear from the L_1 Gland in Dog 2. Large Cluster of Squamous Cells. (Pollak Trichrome x192)

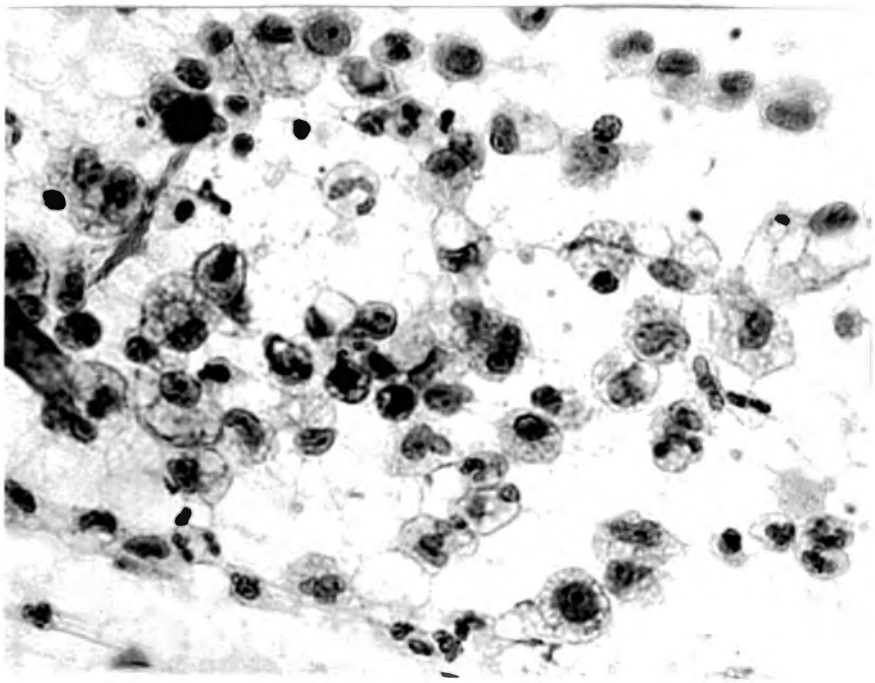

Figure 11. The R_2 Gland from Dog 3 on 25th Day Following Cesarean Section. Many Histiocytes and Some Neutrophils. (Pollak Trichrome x480)

The majority of the smear had a background of long thin bands of finely granular material. Most of the cells were histiocytes and neutrophils with a moderate number of erythrocytes. Many clusters of histiocytes were seen. In several clusters the cells appeared to be radiating from the center of the structure with the nuclei located at the periphery (Fig. 12). Some of the single histiocytes contained multiple large green granules considered to be hemosiderin with the trichrome stain. The TB stained smears confirmed these granules as being hemosiderin (Fig. 13). A few isolated foam cells and some clusters of three to seven of these cells were recorded. There were very few signet cells and no ductal cells seen.

Smears from this gland four days later had the same smear pattern but erythrocytes were more evident. The foam cells increased and two giant clusters containing over one hundred cells were recorded (Fig. 14).

The first collection from R_1 from Dog 1 had a background with a moderate number of ORO droplets. These smears were very cellular due primarily to the large number of erythrocytes. There was a moderate number of histiocytes. Some of these contained hemosiderin and others contained fat droplets (Fig. 15). A few isolated foam cells and neutrophils were seen. No ductal epithelial cells were reported.

The smears from this gland four days later were more cellular due to the large increase in hemosiderocytes (Fig. 16).

Observation of Tissue

Tissue was available from only one animal, Dog 4, in this group. The

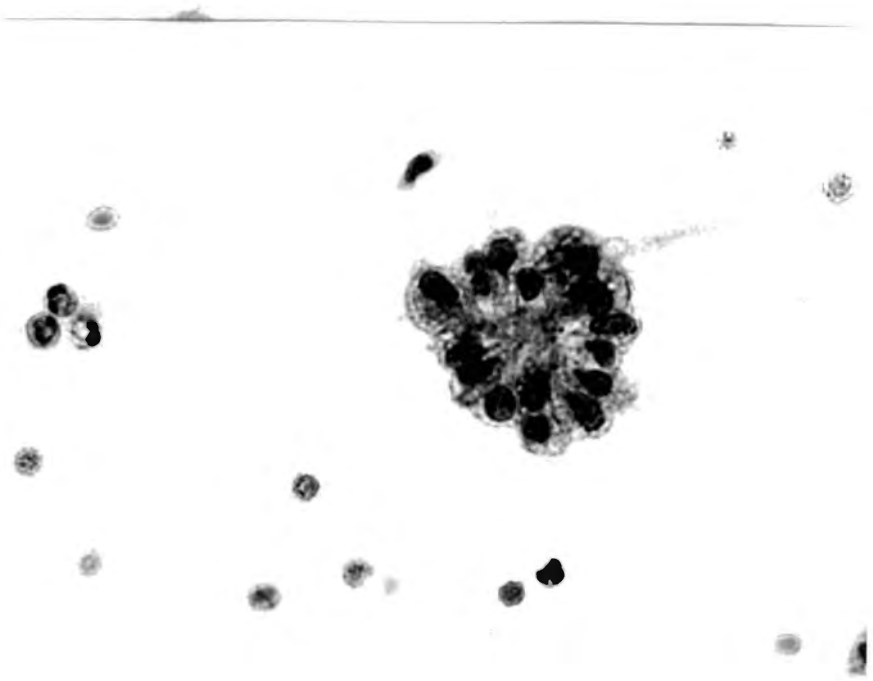

Figure 12. Smear from the R4 Gland in Dog 1. Histiocytes in a Radiating Cluster and Three Neutrophils at the Left. (Pollak Trichrome x480)

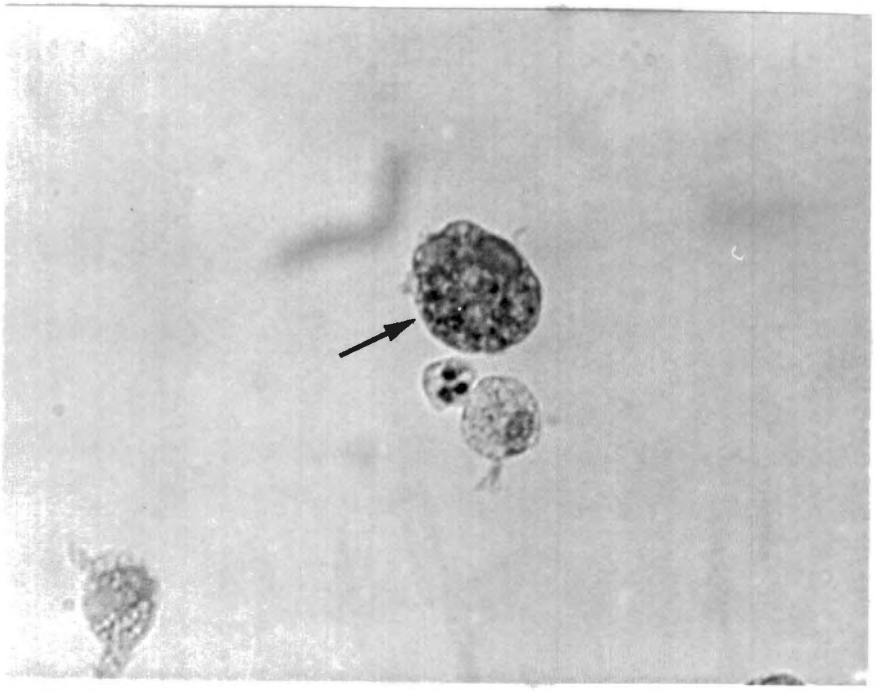

Figure 13. Smear from the R_4 Gland in Dog 1. Histiocytes Containing Hemosiderin (arrow) (TB x780)

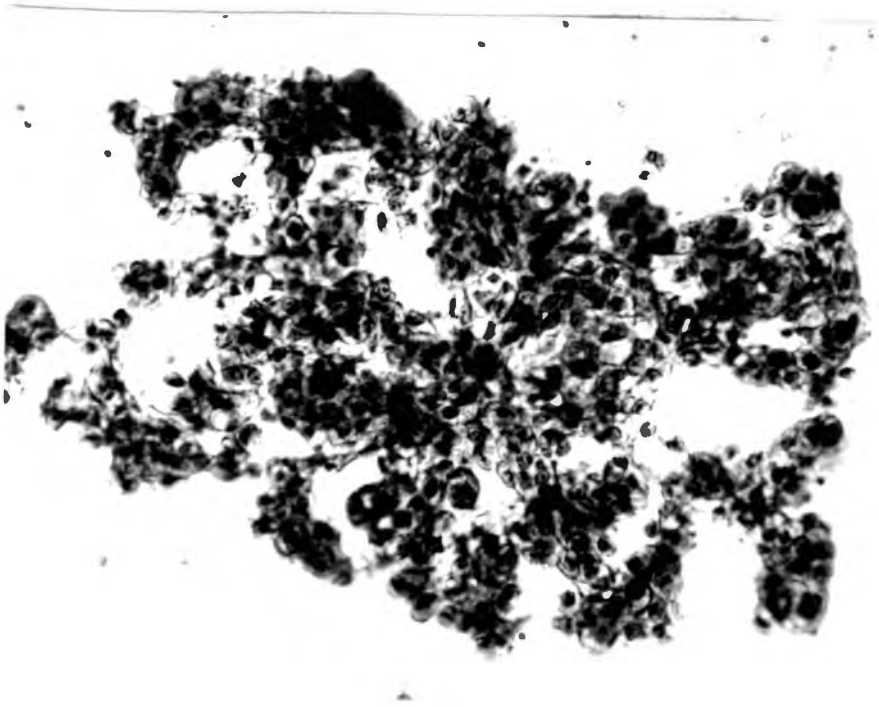

Figure 14. Smear from the R_4 Gland in Dog 1. Giant Cluster of Histiocytes and Foam Cells. (Pollak Trichrome x192)

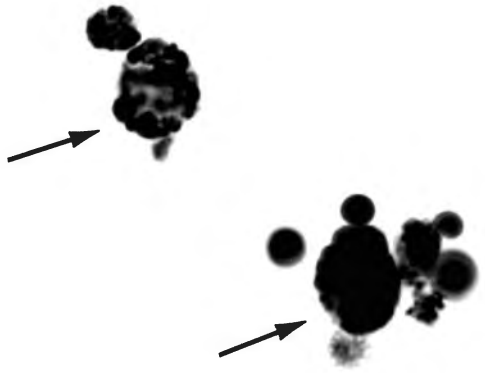

Figure 15. Smear from the R_1 Gland in Dog 1. Histiocytes (arrows) and Neutrophils are Filled with Lipid Droplets. (ORO x780)

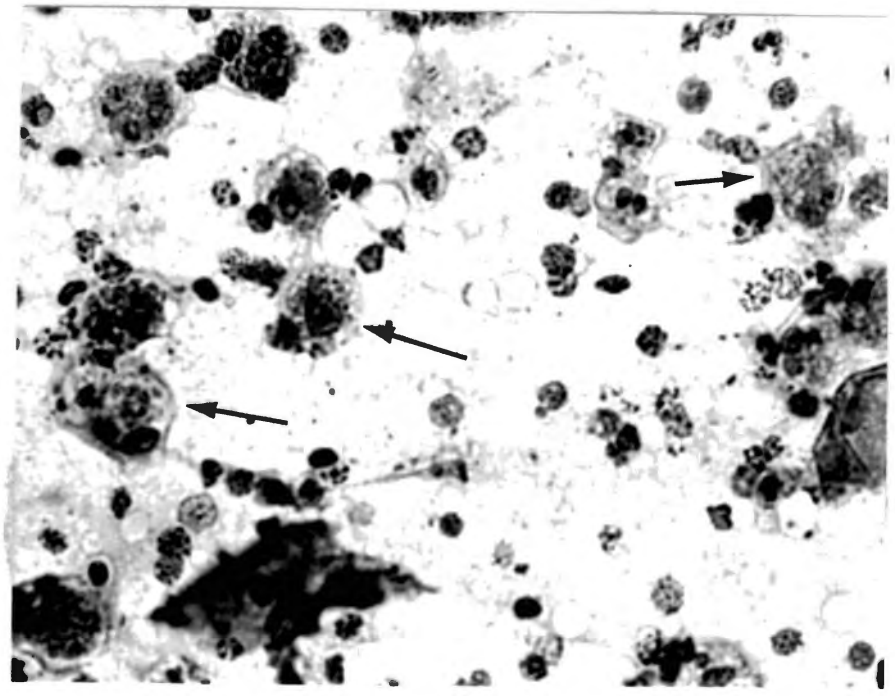

Figure 16. Smear from the R_1 Gland in Dog 1. There are Many Hemosiderocytes (arrows) and Erythrocytes. (Pollak Trichrome x480)

specimen was taken on the fifth postpartum day. The majority of the acini was filled with pink material containing multiple vacuoles that varied in size. Other acini appeared empty. Signet type cells were present in the acinar epithelium (Fig. 17). The epithelium of the major ducts contained signet cells and the lumens were filled with material similar to that in the acini with a few neutrophils and nuclear fragments (Fig. 18).

Group 2 - Animals with Secretions Associated with Pseudocyesis

Clinical Data

A total of seven glands from three dogs was included in this group. The ages ranged from one to four years. The interval between specimen collection and onset of the preceding heat period ranged from eight to twelve weeks (Table III).

Cytology Specimen Collection

Dog 6 had enlargement and various degrees of secretion in all glands, but glands L_1, L_5, R_1 and R_5 were the only ones studied. Two collections were made from these mammae at four day intervals. Attempts to collect fluid on a subsequent fifth day were unsuccessful.

Dog 7 had only one gland secreting. A single collection was made from this gland prior to its surgical removal.

Dog 8 had two enlarged secreting glands on the same side. Following

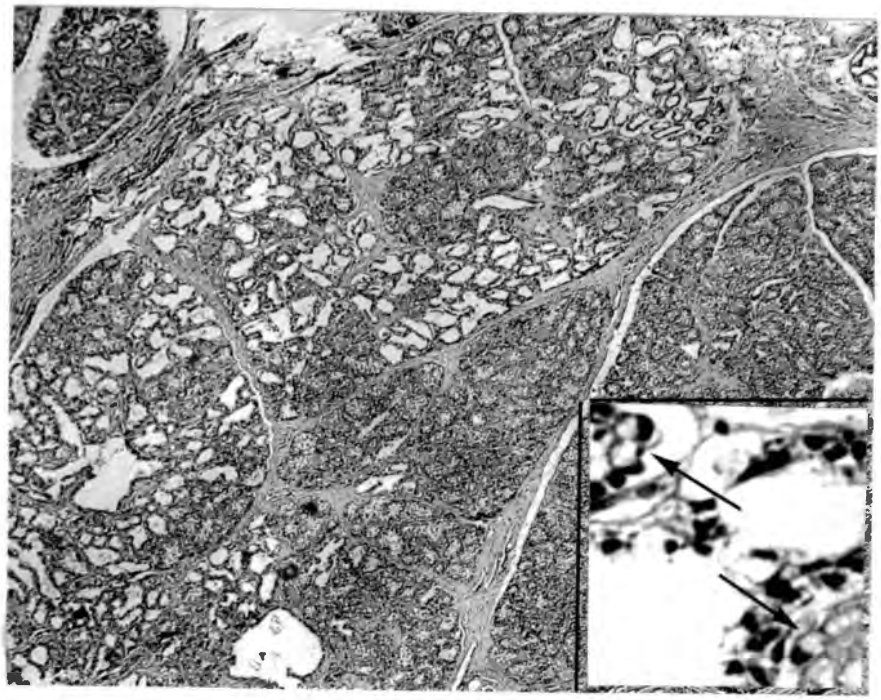

Figure 17. Tissue of a Lactating Mamma from Dog 4 Five Days After Whelping. Some Acini Appear Empty and Others are Filled with Material with Vacuoles. Insert at Lower Right (x380) Shows Some Signet Cells Line Acini (arrows). (H&E x192)

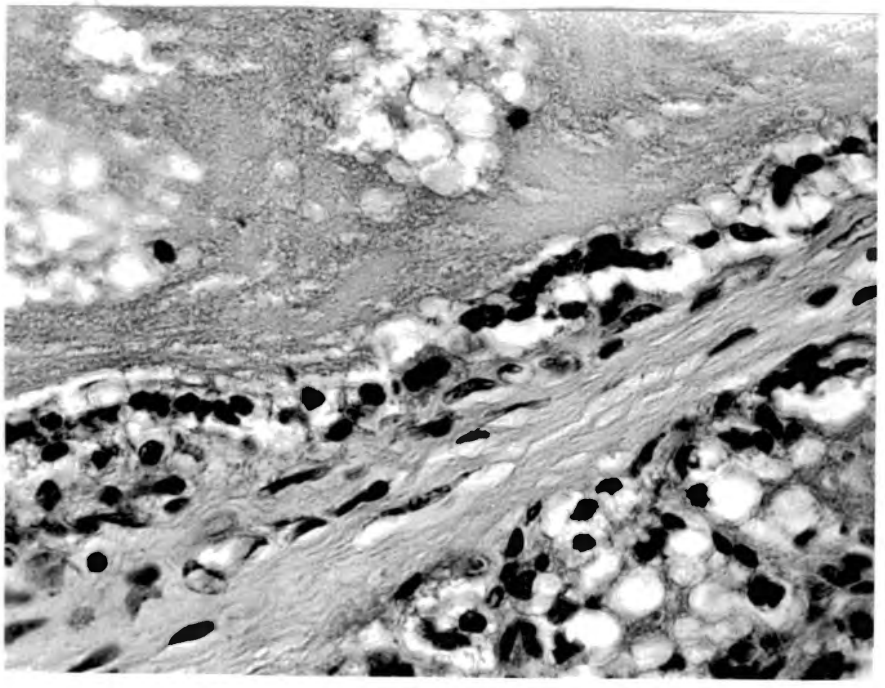

Figure 18. Lactating Mammary Gland Tissue from Dog 4 on Fifth Day Postpartum. The Large Duct Has Many Signet Cells in the Epithelium and the Lumen (at top of photograph) Is Filled with Multi-vacuolated Material (H&E x480)

TABLE III

CLINICAL AND CYTOLOGIC DATA ON BITCHES DURING PSEUDOCYESIS - GROUP 2

Animal Identification	Breed	Age	Identification of Glands Studied	Interval Between Onset of Last Heat Period and Smear Collection
Dog 6	Pointer	1 yr	L_1, L_5, R_1, R_5	12 weeks
Dog 7	Mixed Breed	4 yr	R_5	9 weeks
Dog 8	Great Dane	3 yr	L_2, L_3	approximately 8 weeks

collection, the animal was treated with hormonal injection so subsequent smears were not collected.

Table III outlines clinical and cytology data on these animals.

Observation of Smears

Both sets of smears from Dog 6 were indistinguishable from those seen from pregnant and postparturient Dogs 2, 3, 4, and 5.

The smears from Dog 7 had a thick background of granular material filled with vacuoles and signet cells of various sizes. The smear was moderately cellular. Neutrophils, lymphocytes and erythrocytes appeared at about a 1: 1: 1 ratio. There was a moderate number of single foam cells, some of which contained hemosiderin. There were several clusters of foam cells containing 2 to 25 cells (Fig. 19). The nuclear chromatin pattern was indistinct suggesting early degeneration. Other clusters contained cells that varied markedly in size and contained small and large vacuoles. Several hemosiderocytes were present and there was a moderate amount of cellular debris.

The smears from Dog 8 had a background of finely granular material with many minute vacuoles that varied slightly in size. No signet cells were seen. There were many foam cells. The majority of these had an unusually well preserved nuclear structure and one or two nucleoli. The foam cells appeared singly or in loosely arranged groups (Fig. 20). These cells contained the characteristic small vacuoles and cells with the larger vacuoles seen in Dog 7 were absent. There were several hemosiderocytes and a few erythrocytes.

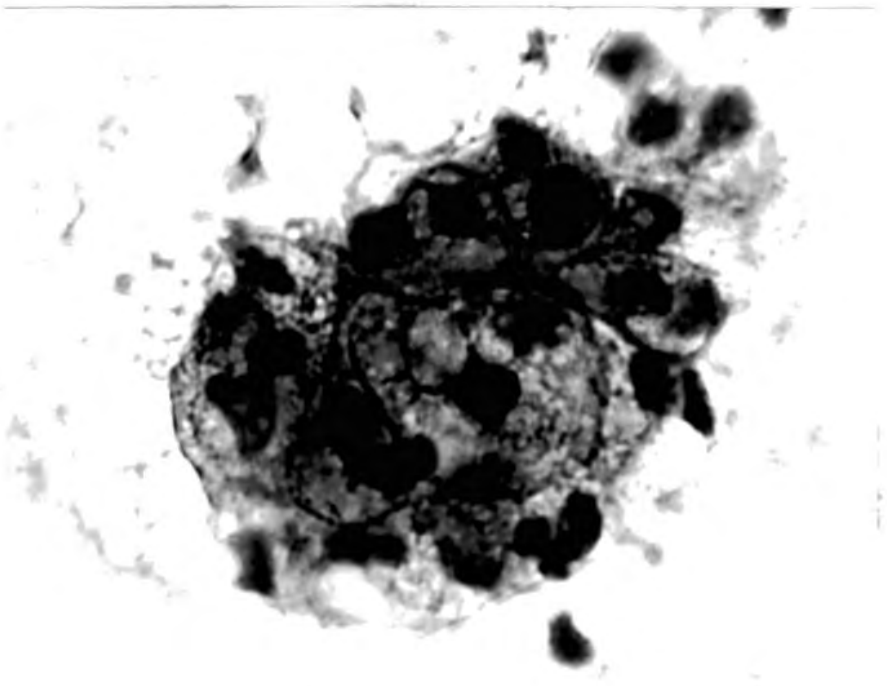

Figure 19. Smear from the R5 Gland in Dog 7 During Pseudocyesis. Cluster of Approximately Twenty Foam Cells. Nuclear Structure Is Indistinct. (Pollak Trichrome x780)

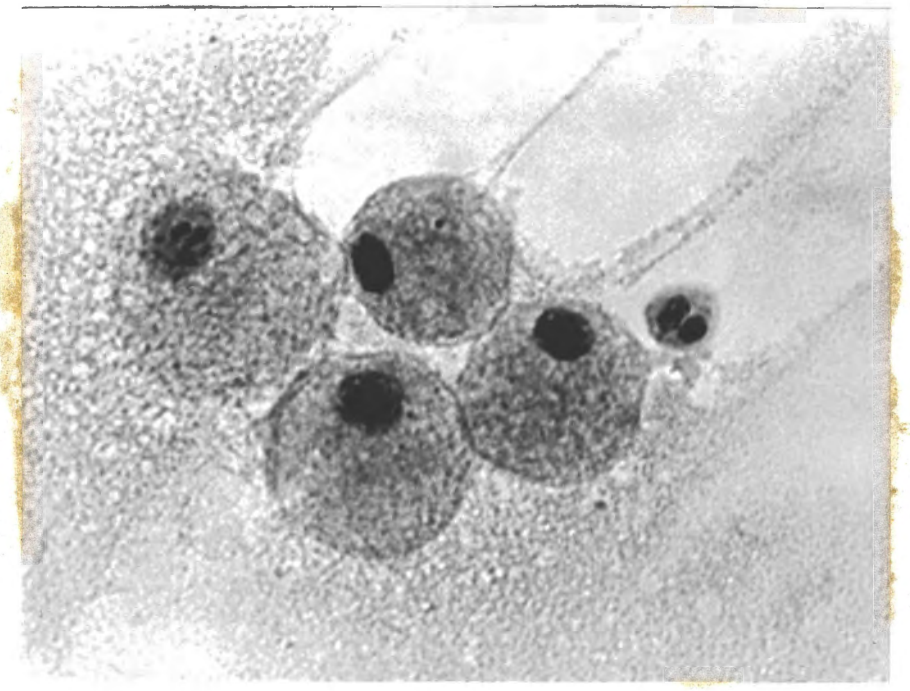

Figure 20. Smear from the L_3 Gland in Dog 8 During Pseudocyesis. Four Foam Cells and One Neutrophil are Shown. Note small Vacuoles in Background. (Pollak Trichrome x780)

Observation of Tissue

Tissue was available from only one animal, Dog 7, in this group. The specimen was surgically excised on the fourth day following the collection of the cytology specimen.

In the histologic preparations there was pink homogeneous material containing many vacuoles within many acinar spaces. Other acini appeared cellular with many signet type cells and large cells with many vacuoles (Fig. 21). The major ducts were lined by signet cells and there were clusters of foam cells free within the lumens and in some areas papillary projections of foam cells appeared to arise from the ductal epithelium (Fig. 22).

Group 3 - Animals with Fluid in a Gland Containing a Benign Mammary Tumor

Clinical Data

The age of the three animals in this group was between eleven and thirteen years. None of the animals had been spayed.

Cytology Specimen Collection

There were six glands with benign mammary tumors in the three dogs. Dog 10 had one benign tumor, Dog 11 had two and Dog 9 had three. Dog 11 and Dog 9 also had malignant mammary tumors that are not included in this study because no fluid could be collected from them. Dog 9 and Dog 11 had a single specimen collected from each gland within a few hours before the

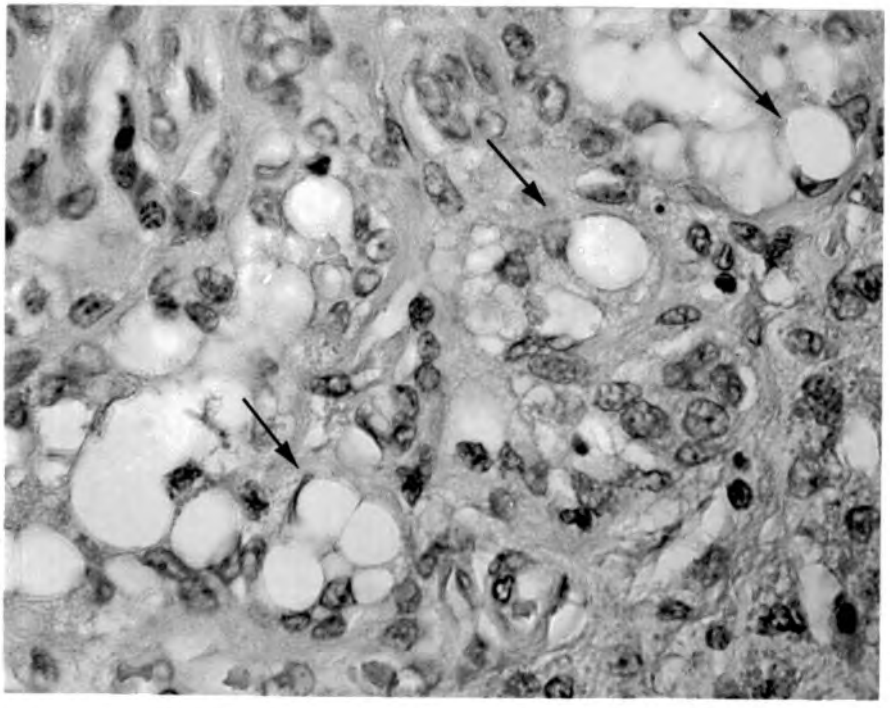

Figure 21. Lobule in Gland from Dog 7 Removed During Pseudocyesis. Signet Cells (arrows) and Other Larger Cells with Multiple Cytoplasmic Vacuoles. (H&E x480)

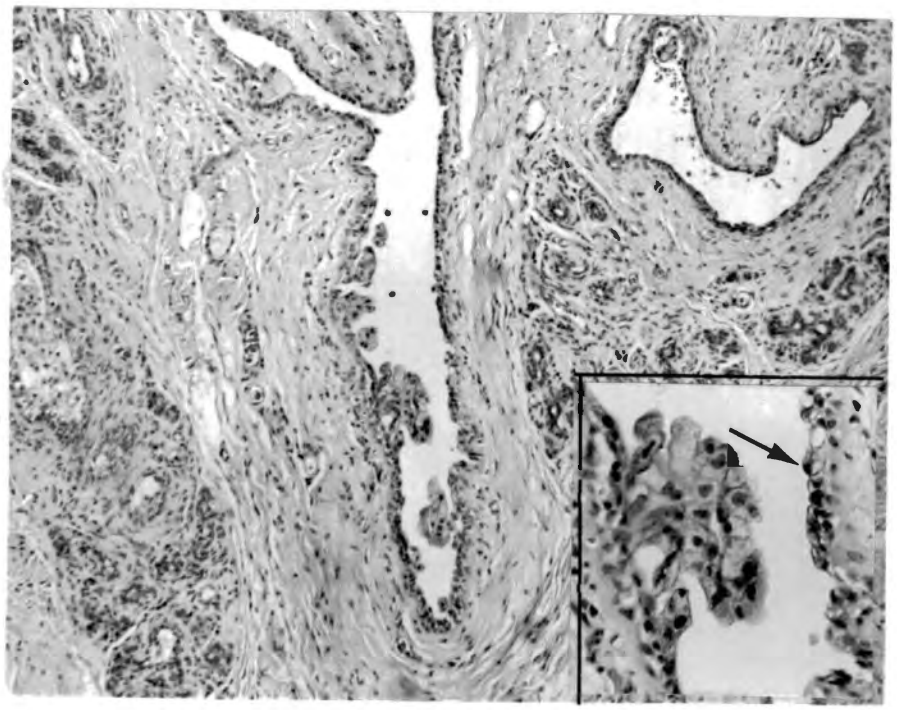

Figure 22. Gland Removed from Dog 7 During Pseudocyesis. Clusters of Foam Cells Are Within the Duct Lumen. In the Insert at Right (x200) the Foam Cells Appear to be Arising from the Duct Epithelium. Signet Cells Line the Duct (arrow). (H&E x75)

tumor tissue was taken during postmortem examination. Dog 10 had seven cytology collections made from her gland over an eleven week period. The last specimen was taken thirteen days prior to euthanasia. Clinical data, location of glands sutdied and histologic classification of the tumors appear in Table IV.

Observation of Smears

Smears from R5 gland in Dog 9 had a background of dense homogeneous material in clumps. The smears were cellular. There were a few neutrophils and many small histiocytes. There were many cell clusters containing from four cells to well over one hundred. Most of the clusters contained about 25 cells. The majority of clusters contained foam cells of various sizes. Other clusters were composed of cells that varied in size and had dense cytoplasm. The nuclear cytoplasmic ratio was high and there were prominent nucleoli. The cells were closely arranged but the cytoplasmic borders were clearly delineated and some had columnar shape. These cells are compatible with the classification of ductal epithelial cells. These two types of cell clusters are shown together in Figure 23. A phenomenon called cell wrapping where one cell appears to be wrapping around another was seen in some ductal cell clusters. Cell wrapping is shown in Figure 24.

Gland L5 from the same animal was similar but less cellular.

Gland L3 from Dog 9 contained approximately the same type of cells and cell clusters as R5 but there were many more foam cells appearing singly and many small vacuoles were seen in the background material.

TABLE IV

CLINICAL AND CYTOLOGIC DATA ON BITCHES WITH BENIGN MAMMARY TUMORS - GROUP 3

Animal Identification	Breed	Age	Spaying History	Glands Studied	Histologic Classification of Tumors	Source of Tissue Collection
Dog 9	Terrier	11 yr.	Intact	L_3, L_5, R_5	Cystic ductal papilloma in L_3, L_5, and R_5	Necropsy specimen
Dog 10	Pointer	13 yr	Intact	R_1	Ductal papilloma of R_1	Necropsy specimen
Dog 11	Scotty	11 yr	Intact	L_2, L_3	Ductal adenomas of L_2 and L_3	Necropsy specimen

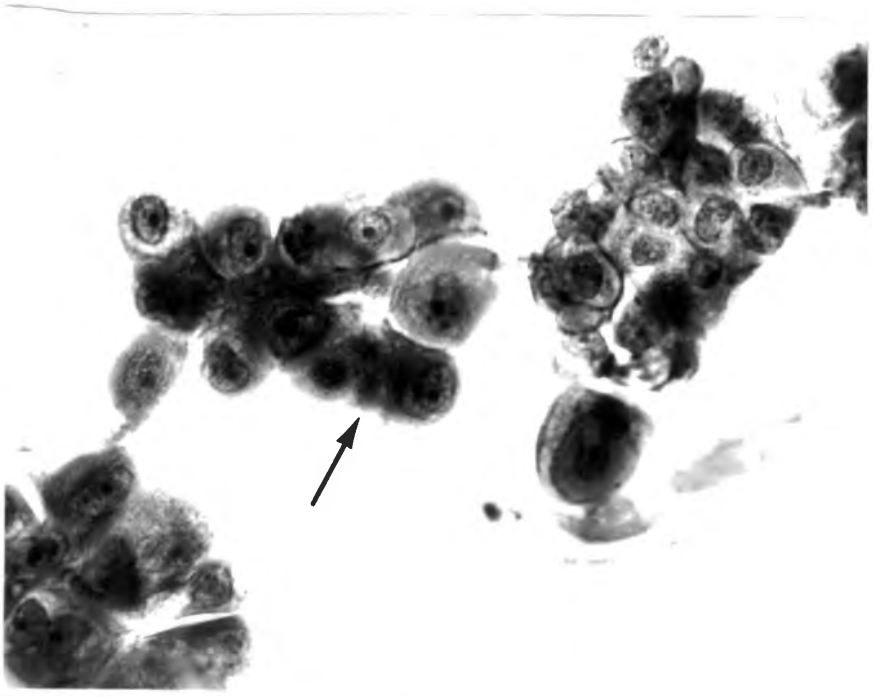

Figure 23. Smear from Dog 9, Gland R_5. A Foam Cell Cluster is at the Right. Ductal Epithelial Cell Clusters at the Left and Bottom Have Cells with Dense Cytoplasm, Large Nucleus and Prominent Nucleolus. Note Columnar Ductal Epithelial Cells (arrow). (Pollak Trichrome x480)

Figure 24. Cluster of Ductal Epithelial Cells in Smear from Dog 9, Gland 5. Cell Wrapping Phenomenon is Shown (arrow). (Pollak Trichrome x480)

The initial collection from R_1 gland in Dog 10 had very little fluid. The smears had a background of granular material with many neutrophils and a few lymphocytes. The secretion was more abundant in the next collection twelve days later. The neutrophils remained the predominant cell type but a few histiocytes were seen. On the third collection, which was 21 days later, and thereafter there was abundant fluid. The smears contained many neutrophils, a moderate number of histiocytes and hemosiderocytes and a few clusters containing from three to 40 cells were present. These cells more closely resembled ductal epithelial cells than foam cells. They were relatively small but occasionally there was a very large cell within the cluster (Fig. 25). This cell pattern remained fairly constant throughout the remainder of the period of collection.

The two glands studied in Dog 11 had dense granular background material with some vacuoles and contained a large number of histiocytes, hemosiderocytes and neutrophils with a few erythrocytes. There were numerous foam cells that appeared singly and in clusters containing up to about 60 cells. There was hemosiderin within some cells in the cluster. L_2 had clusters with more uniformity in size than L_3 (Fig. 26). In addition to giant foam cells, L_3 contained unusual large and small green oval bodies with small ones within cells (Fig. 27).

Observation of Tissue

The tumors removed from glands L_3, L_5 and R_5 in Dog 9 had the classification of cystic ductal papilloma. In histologic preparations

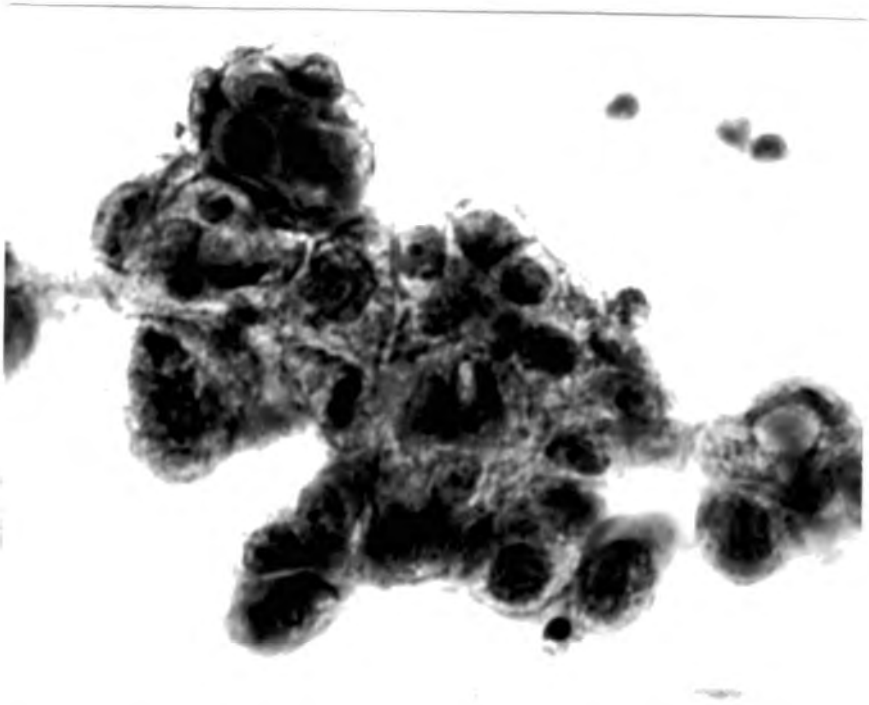

Figure 25. Third Smear in a Series of Collections from R_1 Gland in Dog 10. A Cluster of Compactly Arranged Small Cells. (Pollak Trichrome x780)



Figure 26. Cluster of Uniform Size Foam Cells in Smear from the L_2 Gland in Dog 11. Keratinous Debris Covers Cells at Right (Pollak Trichrome x192)

Figure 27. Smear from the L_3 Gland of Dog 11. A Giant Foam Cell is Shown and a Cluster of Small Foam Cells. Anucleated Green Oval Bodies Are Present Extracellularly and Smaller Ones Appear Intracellular (arrows). (Pollak Trichrome x480)

desquamated cells could be seen in the midst of papillary tumor structures (Fig. 28).

Dog 10 had a small ductal papilloma within a major duct at the base of the teat of R_1. Clusters of small tumor cells and neutrophils were within the duct lumen (Fig. 29).

Glands L_2 and L_3 from Dog 11 were both classified histologically as ductal adenomas. The tissue from L_3 had giant cells in the tumor resembling those seen in the cytology specimen. There were also oval bodies similar to those in the smears. They appeared to be inspissated glandular secretion (Fig. 30). These structures were not seen in the tissue from L_2 (Fig. 31).

Group 4 - Animals with Fluid in a Gland That Contained a Mammary Carcinoma

Clinical Data

There were four animals in this group. They ranged from three to thirteen years in age. Two of the animals were not spayed. One had been spayed two months prior to collection of mammary specimen. The thirteen year old animal had been spayed when her age was three years.

Cytology Specimen Collection

A single specimen was collected from the gland with the carcinoma in each of the dogs. The interval between the collection and necropsy or surgical removal of the gland was nine days (Dog 13), four days (Dog 14),

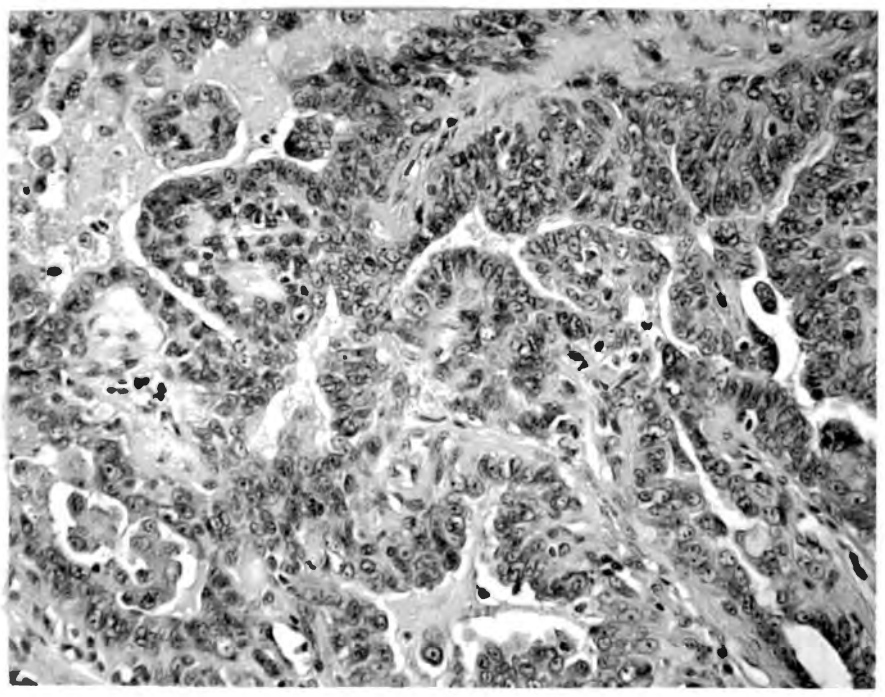

Figure 28. Histologic Section of Ductal Papilloma in the R_5 Gland from Dog 9. Desquamated Cluster of Tumor Cells Is Shown (H&E x192)

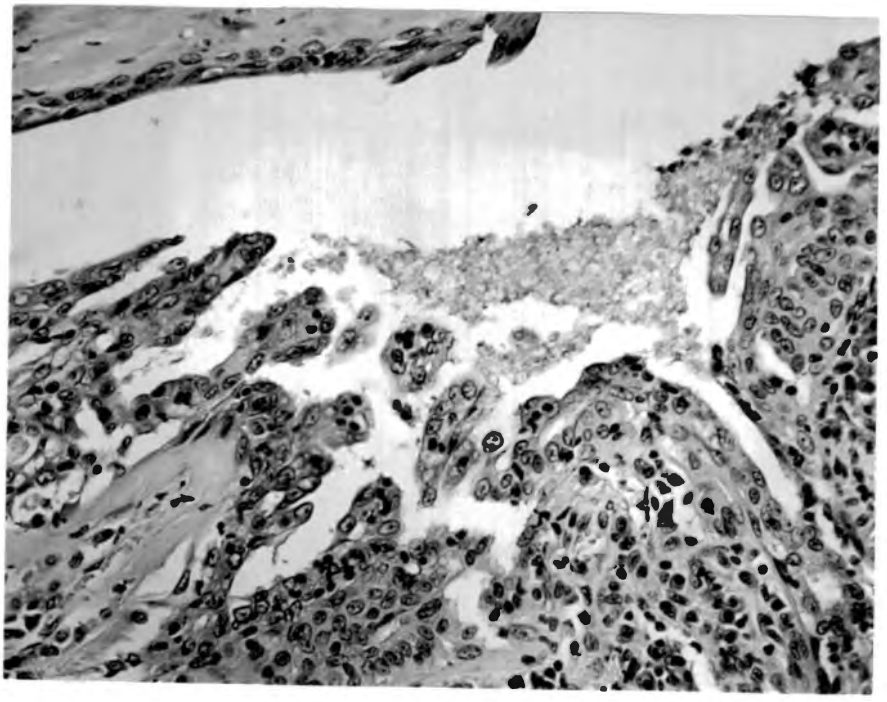

Figure 29. Tissue section of Ductal Papilloma in the L_2 Gland of Dog 10. The Tumor Cells Are Shown Within the Duct Lumen. (H&E x192)

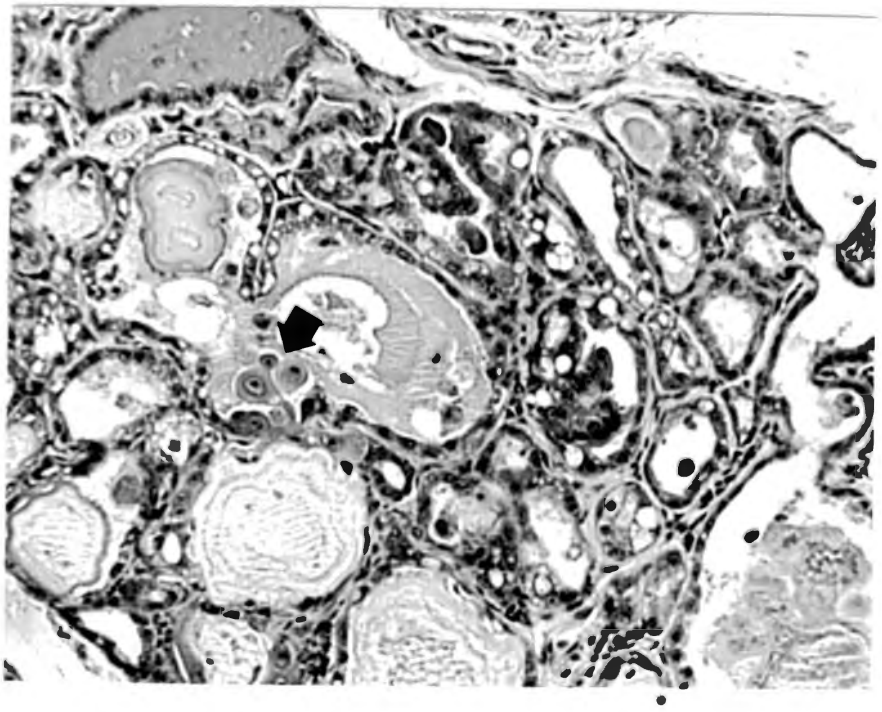

Figure 30. Ductal Adenoma in L3 Gland from Dog 11. Notice Giant Cells (arrow) and Large Intraluminal Oval Bodies. (H&E x150)

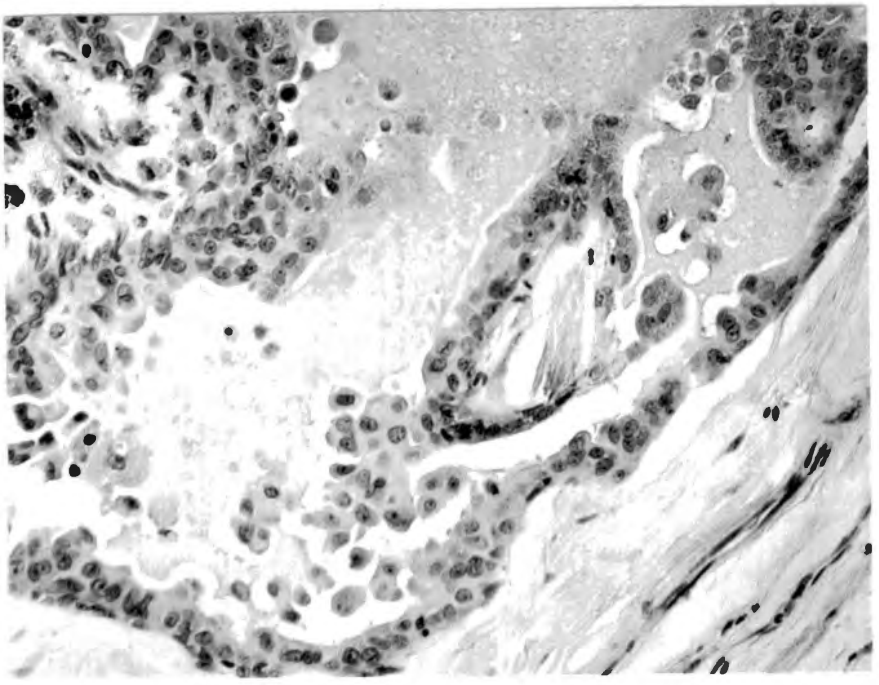

Figure 31. Desquamated Tumor Cells in Cyst of Ductal Adenoma in the L_2 Gland from Dog 11. (H&E x192)

three days (Dog 15) and two days (Dog 12). The mammary carcinomas arose in caudal glands in three dogs. Dog 13 had only four glands in the left mammary chain. Table V outlines data on these animals.

Observations on Smears

Smears from Dog 12 had unevenly spread granular background material. There were very few cells and most of these were erythrocytes and occasionally a neutrophil. Four small clusters of normal appearing ductal cells were noted. There were no more than 25 clusters of cells interpreted to represent the malignant lesion in the four smears examined. Up to 30 cells were present in the clusters. The cancer cells were small when compared with foam cells. There was marked variation in size in the cells within a cluster. The nuclear cytoplasmic ratio was large. The cytoplasm was dense. The nucleoli varied from small to extremely large. The chromatin pattern was fairly evenly dispersed. There were irregular thickened foci in the nuclear membranes. Only five single tumor cells were seen. A cluster of cancer cells is shown in Figure 32.

Smears prepared wtih L4 gland fluid in Dog 13 had unevenly spread and finely granular material. There was a moderate number of neutrophils and a few small histiocytes. Many cells with features compatible with malignancy were present. There were very few clusters seen (Fig. 33). The majority of cells appeared free but in a row formation. Many of the nuclei were eccentric and the cytoplasm was dense. One or more enlarged and usually irregularly shaped nucleoli were seen. Many of the nuclei

TABLE V

CLINICAL AND CYTOLOGIC DATA ON BITCHES WITH MALIGNANT MAMMARY TUMORS - GROUP 4

Animal Identi-fication	Breed	Age	Spaying History	Glands Studied	Histologic Classification of Tumor	Source of Tissue Collection	Histologic Evidence of Metastasis
Dog 12	Doberman	10 yr	Intact	L_1	Ductal carcinoma of L_1	Surgical specimen	Metastasis to regional lymph node
Dog 13	Pointer	3 yr	Spayed 2 months prior to euthanasia	L_4	Ductal carcinoma of L_4	Necropsy specimen	Metastasis to regional lymph nodes and lungs
Dog 14	Poodle	11 yr	Intact	L_5	Early ductal carcinoma of L_5	Surgical specimen	-
Dog 15	Boston Terrier	13 yr	Spayed at 3 yr of age	L_4	Ductal carcinoma of L_3, L_4, L_5	Surgical and necropsy specimens	Metastasis to lungs, lymph nodes, urinary bladder, brain, kidney and vagina

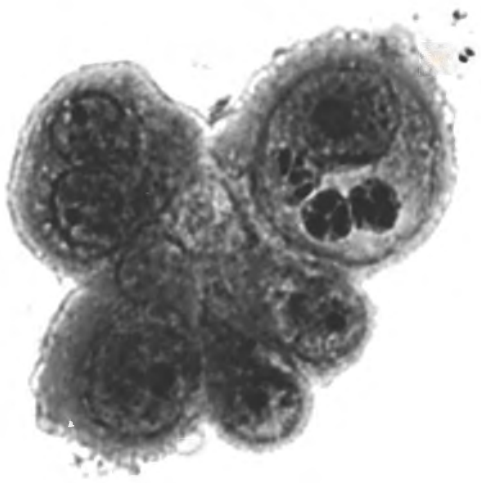

Figure 32. Cluster of Cells Interpreted to be Malignant in Smear from Dog 12. Note Variation in Cell Size, Enlarged Nuclei, and Very Large Nucleoli in the Largest Cell. Three Neutrophils Are On or Within the Cell. (Pollak Trichrome x780)

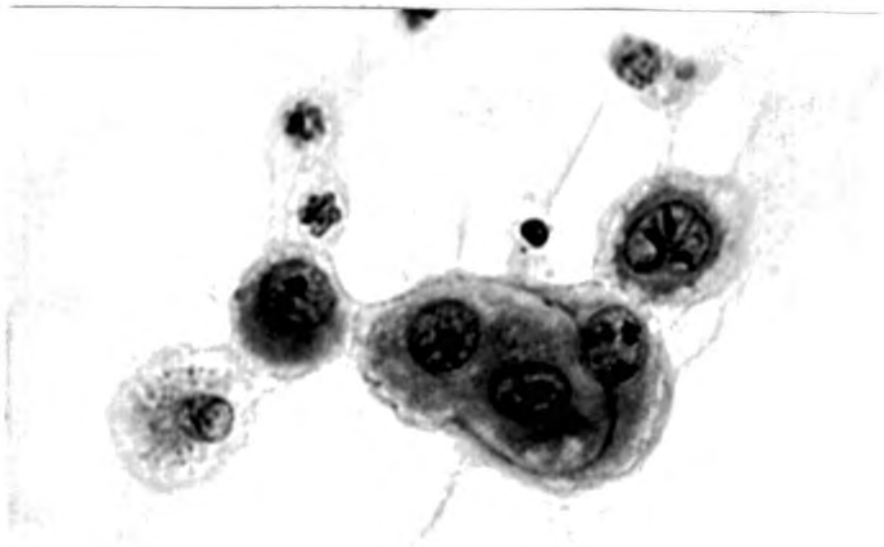

Figure 33. Smear from the L_4 Gland in Dog 13. The Cancer Cells Are in an Epithelial Arrangement. (Pollak Trichrome x780)

were hypochromatic (Fig. 34).

Smears from L_5 gland of Dog 14 were very cellular. The erythrocytes in some areas were so numerous that they covered and hid many of the other cells. A few neutrophils, histiocytes and foam cells were seen. The cells interpreted as cancer cells were pleomorphic. There were many clusters of about 30 cells. The boundaries of these clusters were irregular. There were several large multinucleated cells. Irregularly shaped cells were seen including those with long cytoplasmic projections termed "tadpole" cells. These cells are sometimes seen with squamous cell carcinoma. Other indications of squamous cell carcinoma were epithelial shaped cells with areas of the cytoplasm which were orange-red. This is the color reaction of keratohyaline. Some of the cells seen in the smears are shown in Figure 35.

The smear from L_4 gland in Dog 15 contained few cells. There were a few neutrophils and hemosiderocytes but no erythrocytes were seen. There was a faint granular background. The cells interpreted as malignant were few. They were seen most frequently in clusters. There was marked variation in cell size within the cluster. Nucleoli were not greatly enlarged but the nuclear borders were irregular and very thick. A cytoplasmic vacuole was occasionally seen (Fig. 36).

Observation of Tissue

Tissue was available from all glands included in this group. In two animals, Dog 12 and Dog 14, the glands were removed surgically. In Dog 13 the tissue was taken during necropsy examination. Tissue from Dog 15

Figure 34. Smear from the L_4 Gland in Dog 13. Cancer Cells Are in a Row. Notice the Greatly Enlarged and Irregularly Shaped Nucleoli. (Pollak Trichrome x780)

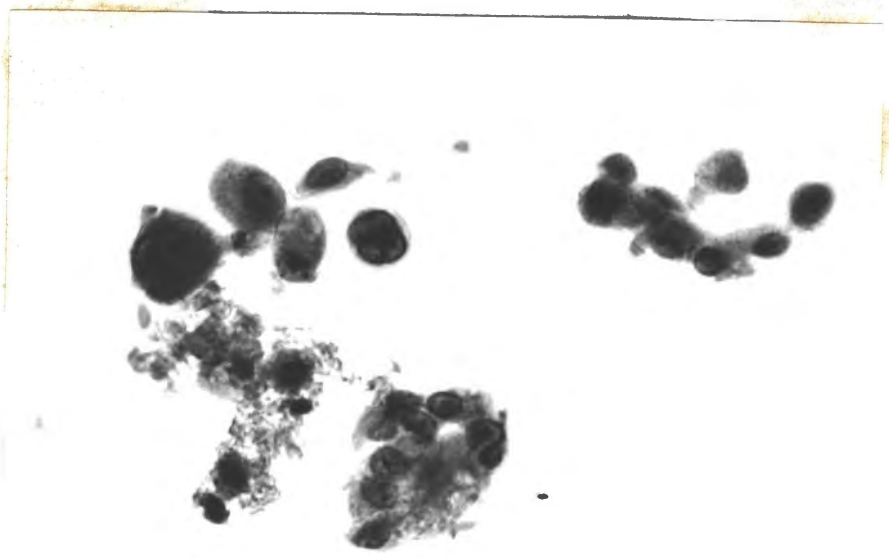

Figure 35. Smear from the L_5 Gland in Dog 14. The Cancer Cells Vary in Size and Shape. Notice the Multinucleated Cells. (Pollak Trichrome x480)

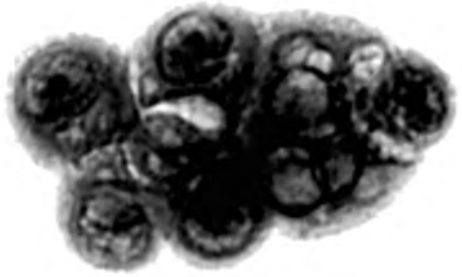

Figure 36. Smear from the L_4 Gland in Dog 15. Some of the Features of Malignancy Shown Are Thickened, Irregular Nuclear Borders and Marked Variation in Cell Size Within the Cluster. (Pollak Trichrome x780)

was initially the gland that had been surgically excised. The animal died less than a month following surgery and the body was examined postmortem.

The histologic diagnosis on the L_1 gland from Dog 12 was ductal carcinoma with metastatic cancer cells in the right axillary lymph nodes. There was a strong similarity between the exfoliated cells and those in the tissue (Fig. 37).

The histologic diagnosis on L_4 gland from Dog 13 was ductal carcinoma with widespread metastasis. This tumor was unusually anaplastic. The feature of noncohesiveness seen in cancer cells in the smears was also present in the tissue preparation (Fig. 38).

The histologic classification on L_5 gland from Dog 14 was early ductal carcinoma. The tumor was located within the teat (Fig. 39). The lymph node which was removed with the gland contained no tumor cells. Squamous metaplasia could be seen within the tumor mass (Fig. 40) and much of the tumor had a papillary arrangement.

The histologic diagnosis on L_4 gland from Dog 15 was ductal carcinoma. The surgical specimen had markedly invasive cancer cells and many lymphatics were dilated and filled with cancer cells (Fig. 41).

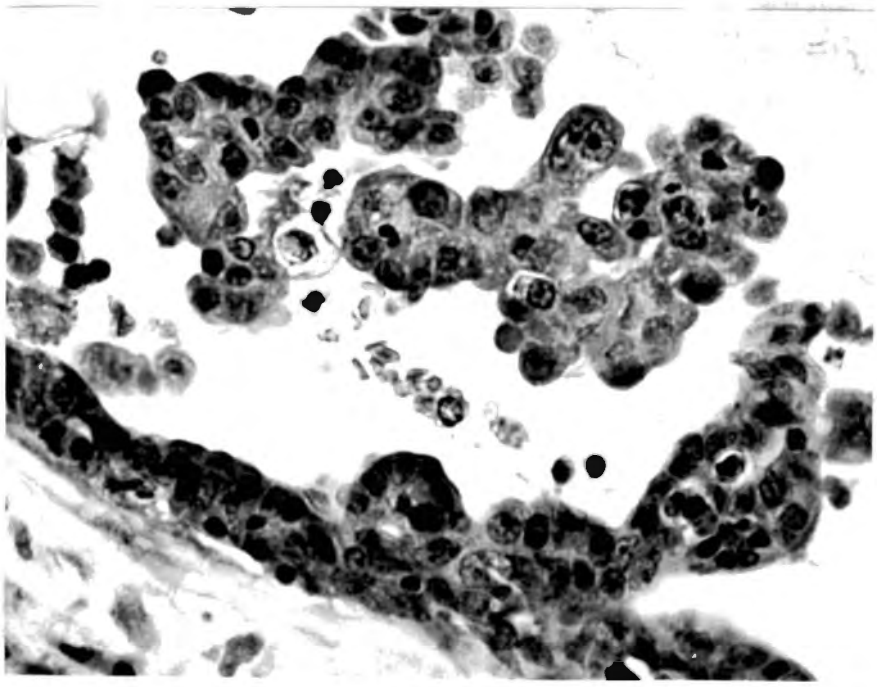

Figure 37. Tissue from the L_1 Gland of Dog 12 with Infiltrating Papillary Ductal Carcinoma. Many Tumor Cell Clusters, Erythrocytes and Neutrophils Are Free Within the Ductal Lumen. (H&E x480)

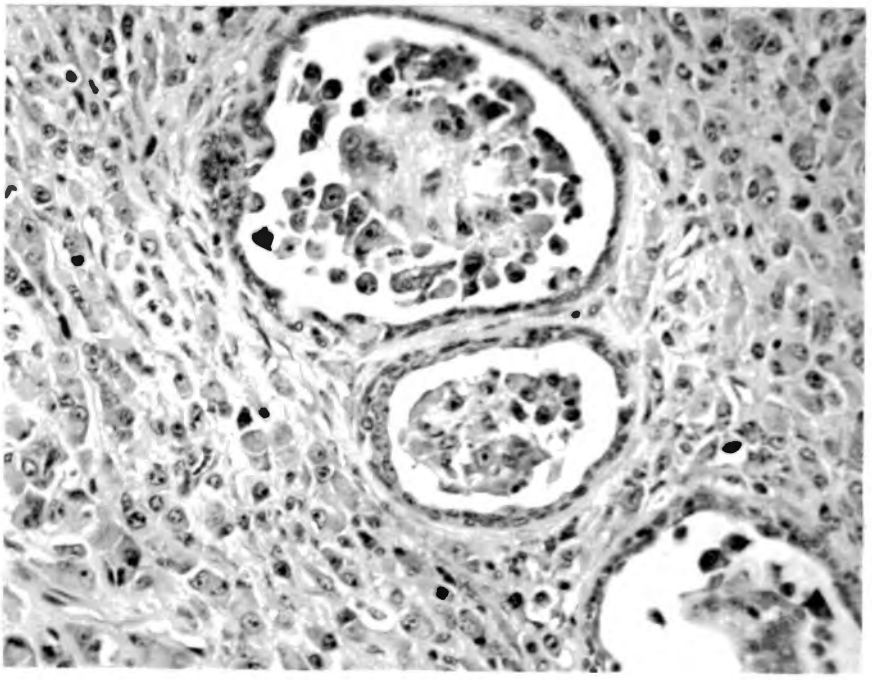

Figure 38. Tissue Preparation from the L_4 Gland from Dog 13. The Cancer Cells Are Anaplastic. Some Cells Can be Seen Within Small Ductal Lumens. (H&E x192)

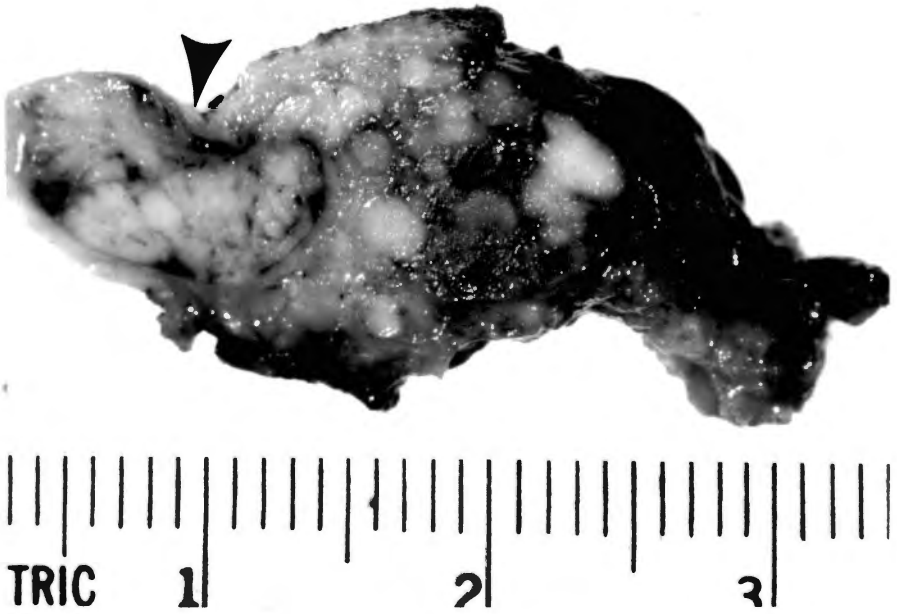

Figure 39. Cut Surface of Formalin-fixed L_5 Gland from Dog 14. The Early Ductal Carcinoma Fills the Teat (arrow) and Appears Encapsulated. (Scale is Metric)

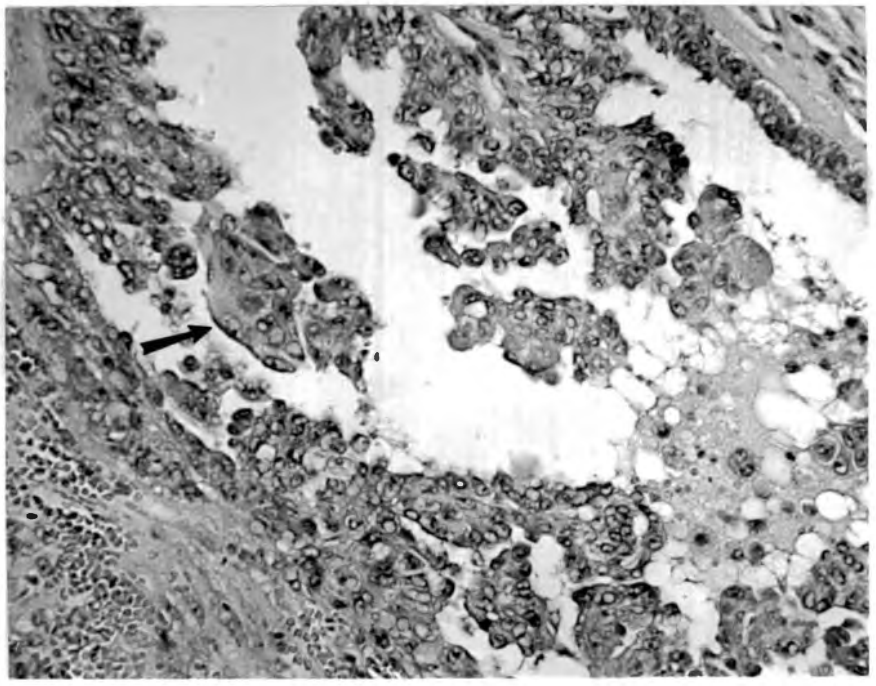

Figure 40. Tissue Prepared from the L_5 Gland Removed from Dog 14. Squamous Metaplastic Cells (arrow) Are Present Wtihin This Early Ductal Carcinoma (H&E x 192)

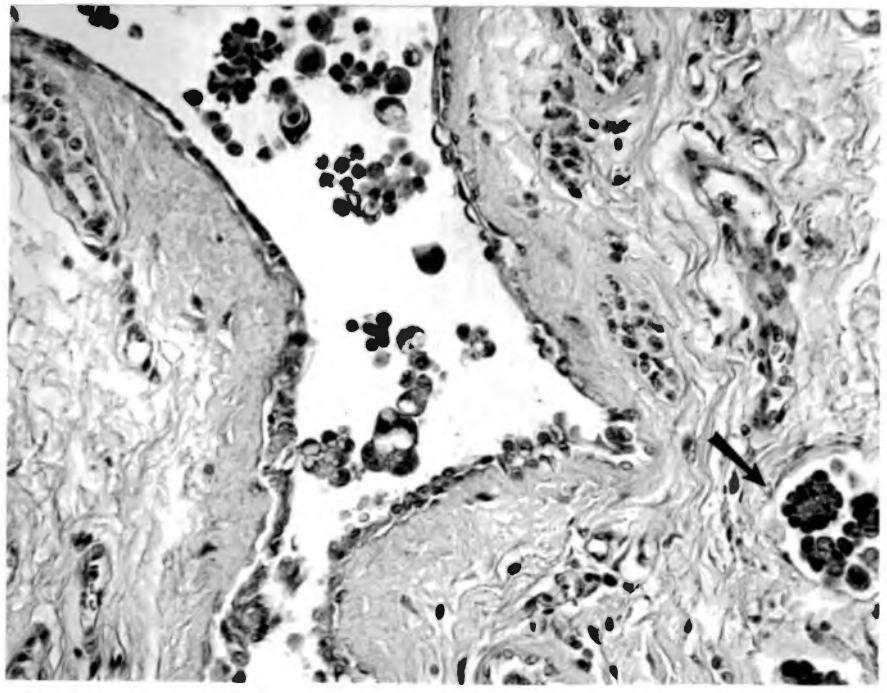

Figure 41. Tissue of Surgical Specimen of the L4 Gland from Dog 15. The Small Clusters of Cancer Cells Are Within Vessels (arrow) and Duct Lumen. (H&E x192)

CHAPTER V

CONCLUSIONS AND DISCUSSION

There was a remarkable similarity in preparturient and postparturient specimens. Excluding Dog 1, there was also a similarity between different glands in the same animals and glands in different animals. No remarkable differences were noted between the smears from nursing and non-nursing bitches except for the last collection from the R_2 gland in Dog 3. It is therefore concluded that the majority of smears in Group 1 represent the smear pattern and cell type that is normal before and after pregnancy regardless of whether or not puppies are nursed. Major features of such smears are the presence of signet cells, extracellular lipid droplets and a few foam cells that may be seen in small clusters. This abundance of lipid is a feature not mentioned in smears from pregnant or parturient women. This is likely due to the differences in the chemical composition of milk in the two species. Chemical analyses of canine and human milk indicate there is almost three times more fat in canine milk (21).

The abrupt change in the last specimen from one gland (R_2) in the non-nursing dog (Dog 3) is interesting. It is well known that nursing is a stimulant for lactation. It is possible that the sudden appearance in the smears of small histiocytes and neutrophils were indicators of initiation of

gland involution. While inflammatory cells are routinely thought of as representing a pathological condition, they often are seen in large numbers related to normal physiological events. Examples of this are the numerous neutrophils that appear in canine vaginal smears following the peak of vaginal epithelial estrogenic effect (12) and the so-called "exodus of histiocytes" seen in vaginal smears from women following menstrual bleeding (20).

No conclusion could be drawn concerning the reason for the notable difference in smears from Dog 1 and other dogs in this group. She was older than the others and had whelped more litters. These may have been contributing factors. The inability of the owner to recall the date of whelping may also be of some importance if it represented poor management.

A consistent cellular pattern was not observed in specimens from animals during pseudocyesis. The youngest animal with pseudocyesis appeared similar to the pregnant ones in that all glands were secreting and the smears were indistinguishable from pregnant bitches.

The smears and tissue from Dog 7 in the pseudocyesis group were interesting for they were similar to those described in women in the early postpartum period (22). Nipple secretion smears from these women contained erythrocytes and clusters of foam cells with some large vacuoles. The similarity of these smears to those from women with intraductal papilloma led to the biopsy of breasts of these postpartum women. Tissue sections contained papillary projections in the duct epithelium that are similar to those seen in Dog 7 (Fig. 22). Studies of serial sections of the human breast biopsy tissue indicated these structures were located at the bifurcation of

the large ducts. It was suggested that trauma to these structures was the origin of postparturient bleeding. No conclusion as to their relation to early ductal papilloma can be made.

Smears from animals in Group 3 were different from the normal lactating smears which did not cytologically appear to be complicated by a disease process. Consistently they all contained more inflammatory cells. Other features by which they differed varied greatly.

The presence of ductal epithelial clusters in the tumors classified as papillomas and their absence in the adenomas may be of some significance. The ductal epithelial cells in the smears from dogs with papilloma differed from those occasionally observed in smears from lactating animals in that the clusters contained many more cells, the nuclear-cytoplasmic ratio was greater and the nuclei contained prominent nucleoli. Other unusual features seen in the animals with benign tumors are listed. They may have value when large groups and possibly those with other diseases are compared. The features were: 1) Large clusters of foam or ductal epithelial cells with the cells varying in size and having an increased nuclear-cytoplasmic ratio. 2) Evidence of abundant bleeding as indicated by many erythrocytes or hemosiderocytes.

It was noted that smears from one gland (L_3) containing a ductal papilloma in Dog 9 contained many hollow spheres in the background material. All smears in all animals with lactation associated with pregnancy or pseudocyesis had similar spheres and these stained positively for lipid with ORO. The hypothesis was made that the dog with the ductal papilloma

was also in pseudocyesis. The ovaries and uterine tissue were taken at necropsy within hours after the other cytology specimens were collected. Microscope examination of these tissues showed large corpora lutea in the ovaries (Fig. 42) and the endometrial cells had foamy cytoplasm (Fig. 43). Both tissues were compatible with the luteal phase of the estrous cycle and pseudocyesis.

The green oval and spherical structures noted in the smears from L_3 gland from Dog 11 are unusual. Morphologic comparison with histologic sections of dogs in this study and many others as well, indicate these structures are inspissated casts formed in the lobular epithelial lined space. Their presence in smears may be of some significance. Abrupt involution of the mammary gland is reported to result in prolonged retention and inspissation of milk in the acini and to promote tumor formation (9).

Smears from the animals with mammary carcinoma were markedly different from both the normal and those with benign tumors. The unusual cellular features considered significant were: 1) nuclear enlargement, 2) heavy irregular nuclear borders, 3) enlarged, multiple, or irregularly shaped nucleoli, 4) small clusters of cells with loss of cytoplasmic membrane outline, 5) nuclear enlargements and nucleoli transformations in single cells as well as these arranged in small clusters, 6) squamous epithelial appearance of cells by size, shape and/or presence of keratohyaline, 7) bizarre shape of cells.

It is concluded that malignant mammary tumor cells in bitches differ in appearance from those seen in normal lactating glands and glands with

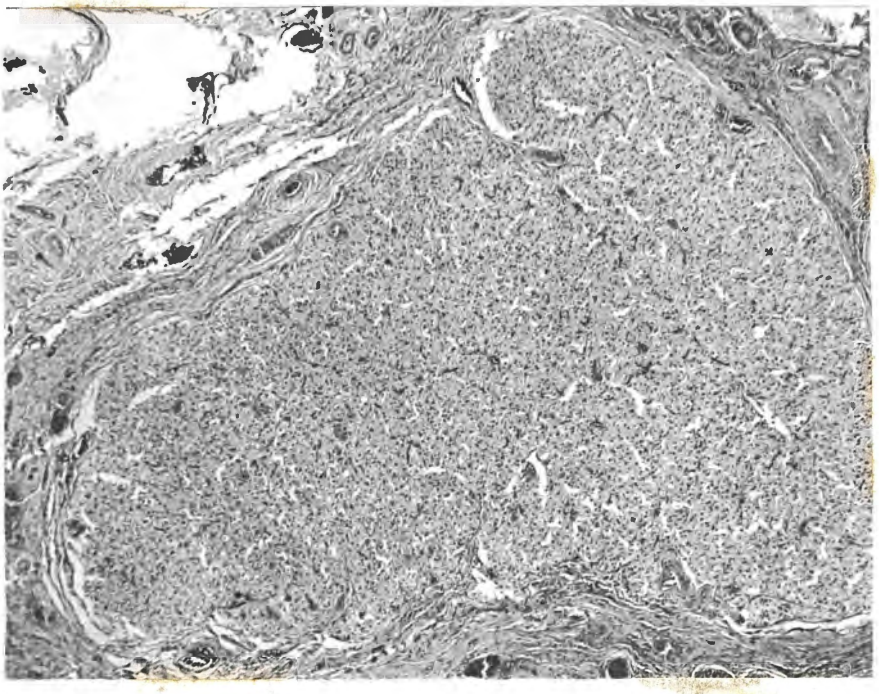

Figure 42. Corpus Luteum in Ovary from Dog 9. (H&E x60)

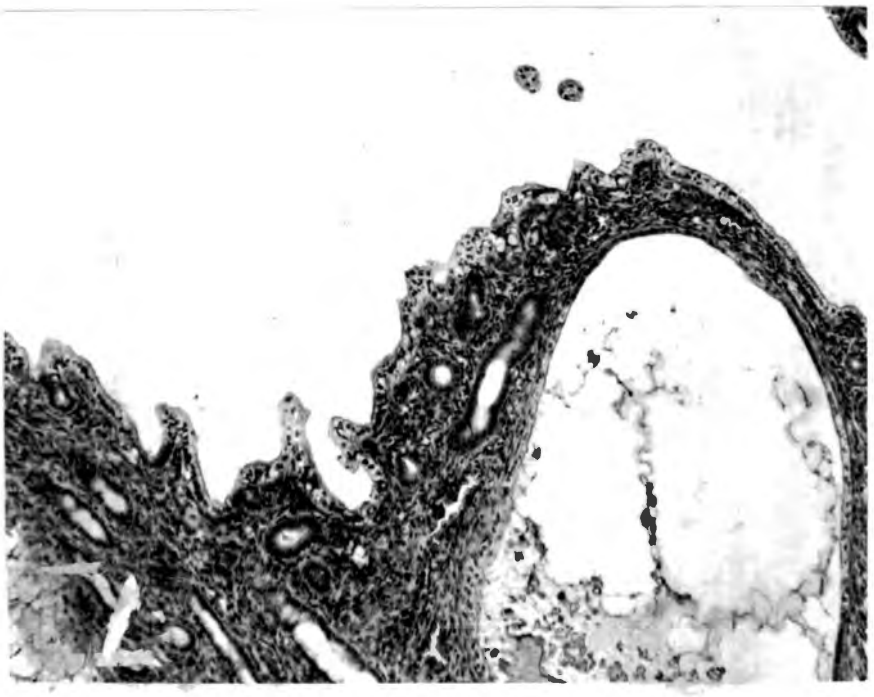

Figure 43. Submucosal Cyst and Endometrial Cells with Foamy Cytoplasm Compatible with Luteal Phase of Estrous Cycle. Uterus from Dog 9. (H&E x75)

benign tumors. Some of the features described in cancer cells from human breast cancer secretions were present. The bitch is believed to be a good cytologic experimental model for advancing knowledge of human breast cancer.

CHAPTER VI

SUMMARY

This study was designed to compare the microscopic appearance of thin film smears of fluids from canine mammary glands before and after parturition, during pseudocyesis, and when histologically confirmed benign and malignant mammary tumors were present.

Smears from lactating glands due to pregnancy or pseudocyesis contained many extracellular fat droplets. When the secretion was related to pregnancy there were also many small signet shaped cells containing lipid. Smears from the prepartum period and postpartum period were indistinguishable.

The fluid from animals with benign tumors differed to the greatest extent from the normal lactating gland most frequently due to bleeding and the presence of large clusters of foam cells or ductal epithelial cells with increased nuclear-cytoplasmic ratios.

The cells in mammary fluids from dogs wtih mammary carcinoma differed from other specimens in that the cells had a greatly increased nuclear-cytoplasmic ratio with enlarged, multiple, or irregularly shaped nucleoli. Squamous epithelial differentiation, bizarre cell shapes and appearance of small clusters of cells with loss of cytoplasmic boundaries were also features

of cancer cells. As would be expected, not all described features were present in specimens from different animals with mammary carcinoma.

SELECTED BIBLIOGRAPHY

(1) Papanicolaou, G. N. and H. F. Traut. "The Diagnostic Value of Vaginal Smears in Carcinoma of the Uterus." Amer. J. Obstet. Gynecol., Vol. 42 (1941), 193-206.

(2) Ross, W. L. "The Magnitude of the Breast Cancer Problem in the U.S.A." Cancer, Vol. 24 (1968), 1106-1108.

(3) Gershon-Cohen, J. "Breast Cancer: Roles of Mammography and Thermography." Indust. Med., Vol. 39 (1970), 19-23.

(4) Norris, H. J. and H. B. Taylor. "Carcinoma of the Breast in Women Less than Thirty Years Old." Cancer, Vol. 26 (1970), 953-959.

(5) Moulton, J. E., D.O.N. Taylor, C. R. Dorn and A. C. Anderson. "Canine Mammary Tumors." Vet. Path., Vol. 7 (1970), 289-320.

(6) Schneider, R. "Comparison of Age, Sex and Incidence Rates in Human and Canine Breast Cancer." Cancer, Vol. 26 (1970), 419-426.

(7) Turner, C. W. and E. T. Gomez. "The Normal and Experimental Development of the Mammary Gland. II. The Male and Female Dog." Missouri Agricultural Experiment Station, Research Bulletin 207. Columbia, Missouri: University of Missouri Press, 1934, 16-35.

(8) Evans, H. M. and H. H. Cole. "An Introduction to the Study of the Oestrous Cycle in the Dog." Memoirs of the University of Calif., Vol. 9 (1931), University of California Press.

(9) Silver, I. A. "The Anatomy of the Mammary Gland of the Dog and Cat." J. Small Anim. Pract., Vol. 7 (1968), 689-696.

(10) Huggins, C. and P. V. Moulder. "Studies on the Mammary Tumors of Dogs. I. Lactation and the Influence of Ovariectomy and Suprarenalectomy Thereon." J. Exp. Med., Vol. 80 (1944), 441-454.

(11) Roszel, J. F. "Exfoliative Cytology in Diagnosis of Malignant Canine Neoplasms." Upjohn Vet. Scope, Vol. 12 (1967), 14-20.

(12) Roszel, J. F. "Genital Cytology of the Bitch." Upjohn Vet. Scope, Vol. 19 (1975), in press.

(13) Roszel, J. F. "Mammary Carcinoma Cells in Canine Genital Smears." Vet. Path., Vol. 11 (1974), 20-28.

(14) Papanicolaou, G. N., D. G. Helmquist, G. M. Bader, and E. A. Talk. "Exfoliative Cytology of the Human Mammary Gland and its Value in the Diagnosis of Cancer and Other Diseases of the Breast." Cancer, Vol. 11 (1958), 377-409.

(15) Holmquist, D. G. and G. N. Papanicolaou. "Exfoliative Cytology of Mammary Gland During Pregnancy and Lactation." Ann. N. Y. Acad. Sci., Vol. 63 (1956), 1422-1435.

(16) Takahashi, M. "Practical Cytology of Organs." Color Atlas of Cancer Cytology. Tokyo: Igaku Shoen Lt.: Philadelphia: J. B. Lippincott Co., 1971, 154-165.

(17) Koss, L. G. "Nipple Secretions in the Nonlactating Breast." Chapter 22 in Diagnostic Cytology and Its Histopathologic Bases. 2nd ed. Philadelphia: J. B. Lippincott, 1968, 568-691.

(18) Luna, L. G. Manual of Histologic Staining Methods of the Armed Forces Institute of Pathology, 3rd ed. New York, N. Y.: McGraw-Hill Book Company, 1968.

(19) Thompson, S. W. and R. D. Hunt. Selected Histochemical and Histopathological Methods. Springfield, Illinois: Charles C. Thomas, 1966.

(20) Papanicolaou, G. N. "Female Genital System." Chapter IV in Atlas of Exfoliative Cytology. Cambridge, Massachusetts: Harvard University Press, 1968, pp. 22-34.

(21) Altman, P. L. Blood and Other Body Fluids. Washington, D. C.: Fed. Amer. Soc. for Exp. Bio., 1961.

(22) Kline, T. S. and S. R. Larsh. "The Bleeding Nipple of Pregnancy and Postpartum Period." Acta Cytol., Vol. 8 (1964), 331-340.

VITA 2

Jeffie Fisher Roszel

Candidate for the Degree of

Doctor of Philosophy

Thesis: CELLS IN CANINE MAMMARY GLAND FLUIDS ASSOCIATED WITH PARTURITION, PSEUDOCYESIS AND TUMOR

Major Field: Veterinary Pathology

Biographical:

Personal Data: Born in Amarillo, Texas, April 5, 1926, the daughter of Rev. & Mrs. V. H. Fisher.

Education: Attended Hunter College (Evening School Division), New York, New York, 1956 to 1959 (no degree); received Veterinariae Medicinae Doctoris degree from the School of Veterinary Medicine, University of Pennsylvania in 1963; completed requirements for Doctor of Philosophy degree at Oklahoma State University in May, 1975.

Professional Experience: Instructor in Pathology (1966 to 1967) and Assistant Professor (1967 to 1970) at The School of Veterinary Medicine, University of Pennsylvania; Lecturer in Pathology (1968-1970) at Philadelphia College of Pharmacy and Science; Visiting Professor (1971 to 1972) and Assistant Professor (1972 to present) in Department of Pathology, College of Veterinary Medicine, Oklahoma State University.

Fellowships and Grants: Hahnemann Medical College and Hospital Institutional Cancer Research Committee Grant in 1963 to 1964; Postdoctoral Research Fellow, National Institute of Health, Cancer Institute, 1964 to 1966; Research Associate, Hahnemann Medical College and Hospital, 1966 to 1967, Institutional Grant of American Cancer Society, University of Pennsylvania, 1967 to 1968; Postdoctoral Trainee in Cancer Research, National Institute of Health, 1967 to 1969, Co-principal Investigator

(Dr. A. W. Monlux, Principal Investigator), National Institutes of Health, Cancer Institute, 1972 to 1978.

Honors: Member Phi Zeta; medical member of American Society of Cytology; full member of Graduate Faculty, University of Pennsylvania, 1969 to 1970; associate member of Graduate Faculty, Oklahoma State University from 1972 to present, named by Women's Veterinary Medical Association as an outstanding woman veterinarian in 1974.