A STEREOTAXIC ATLAS OF THE DIENCEPHALON OF THE SOUTHDOWN SHEEP

By

JOHN MILES ROGERS

Bachelor of Science in Biology

North Texas State University

Denton, Texas

1971

Submitted to the Faculty of the Graduate College
of the Oklahoma State University
in partial fulfillment of the requirements
for the Degree of
MASTER OF SCIENCE
May, 1976

OKLAHOMA
STATE UNIVERSITY
LIBRARY

AUG 26 1976

A STEREOTAXIC ATLAS OF THE DIENCEPHALON

OF THE SOUTHDOWN SHEEP

Thesis Approved:

David Jennings
Thesis Adviser

John H. Venable

Calvin G. Beames, Jr.

N N Durham
Dean of the Graduate College

947637

ACKNOWLEDGEMENTS

Appreciation is expressed to Dr. David P. Jennings for serving as principle adviser to my Master's program and providing the facilities and support required to perform this study. Further appreciation is extended to Dr. John H. Venable and Dr. Calvin C. Beames, Jr., for their guidance and helpful suggestions.

My friends associated with this department have provided a stimulating and enjoyable atmosphere in which to work. Rather than enumerate, I thank them all. Their moral support and technical assistance have been invaluable.

Further thanks are extended to Mrs. Dixie Jennings, the typist, for her valuable suggestions, and to Mrs. Christine Jennings for her understanding and helpfulness.

My parents have provided help and encouragement when needed. For this and much more, I am very grateful.

During the course of this study, financial aid and support were provided by USPHA GRS RR05567, NIH NS11978, and Department of Physiological Sciences.

TABLE OF CONTENTS

Chapter		Page
I.	INTRODUCTION	1
II.	MATERIALS AND METHODS	3
	Definition of the Stereotaxic Coordinate System	3
	Orientation of the Head	4
	Modification of Head-Holder	6
	Positioning the Sheep Head in Head-Holder	10
	Lesioning Procedure	11
	Perfusion	12
	Sectioning	12
	Photography of Unstained Sections	12
	Thionin Staining	13
	Photography of Stained Sections	14
	Determination of Frontal Coordinates	15
	Determination of Vertical Coordinate Axes	16
	Determination of Lateral Coordinate Axes	16
	Determination of Nomenclature	17
III.	RESULTS	19
IV.	DISCUSSION AND CONCLUSION	23
V.	STEREOTAXIC ATLAS	26
SELECTED BIBLIOGRAPHY		72
APPENDIX - FRONTAL COORDINATES OF SELECTED STRUCTURES		74

LIST OF TABLES

Table — Page

I. Frontal Coordinate Means and Standard Deviations of Selected Structures 19

II. Lateral Coordinate Means and Standard Deviations of Selected Structures 20

III. Mean Lateral Error in Lesion Placement. 20

IV. Vertical Coordinate Means and Standard Deviations of Selected Structures 21

LIST OF FIGURES

Figure — Page

1. Alignment of the Brainstem With the Frontal Coordinate Axis. . . 5

2. Modifications of the Head-Holder 7

3. Modification of the Ear Bars 8

4. Placement of Head in the Head-Holder 9

5. Vertical Variation in the Midsagittal Floor of the Cranium . . . 22

LIST OF PLATES

Plate		Page
1.	Section at Frontal 33.6.	30
2.	Section at Frontal 33.1.	31
3.	Section at Frontal 32.5.	32
4.	Section at Frontal 32.0.	33
5.	Section at Frontal 31.5.	34
6.	Section at Frontal 31.0.	35
7.	Section at Frontal 30.4.	36
8.	Section at Frontal 29.9.	37
9.	Section at Frontal 29.3.	38
10.	Section at Frontal 28.8.	39
11.	Section at Frontal 28.3.	40
12.	Section at Frontal 27.7.	41
13.	Section at Frontal 27.2.	42
14.	Section at Frontal 26.7.	43
15.	Section at Frontal 26.1.	44
16.	Section at Frontal 25.6.	45
17.	Section at Frontal 25.1.	46
18.	Section at Frontal 24.5.	47
19.	Section at Frontal 24.0.	48
20.	Section at Frontal 23.5.	49
21.	Section at Frontal 22.9.	50
22.	Section at Frontal 22.4.	51

Plate Page

23. Section at Frontal 21.9. 52

24. Section at Frontal 21.3. 53

25. Section at Frontal 20.8. 54

26. Section at Frontal 20.3. 55

27. Section at Frontal 19.7. 56

28. Section at Frontal 19.2. 57

29. Section at Frontal 18.6. 58

30. Section at Frontal 18.1. 59

31. Section at Frontal 17.6. 60

32. Section at Frontal 17.0. 61

33. Section at Frontal 16.5. 62

34. Section at Frontal 16.0. 63

35. Section at Frontal 15.4. 64

36. Section at Frontal 14.9. 65

37. Section at Frontal 14.4. 66

38. Section at Frontal 13.8. 67

39. Section at Frontal 13.3. 68

40. Section at Frontal 12.8. 69

41. Section at Frontal 12.2. 70

42. Section at Frontal 11.7. 71

CHAPTER I

INTRODUCTION

In 1908 Horsley and Clark introduced a systematic method called stereotaxis for locating structures in the brain. Their method defined a three-dimensional system of coordinates with respect to the brain using external features of the skull as reference points. The development of a useful stereotaxic map has been a consistent and necessary step to the accurate placement of probes into the living brain, such as cannuli for chemical perfusion and electrodes for recording, stimulating, and lesioning.

Sheep are used widely for neuroendocrine research (Traczyk and Przekop, 1963; Radford, 1967; Richard, 1970; Johnson, Zehr, and Moore, 1970; and Haskins, Jennings, and Rogers, 1975). They offer several advantages. Their sleep-waking behavior has been well described and is easily monitored (Ruckenbush, 1972). They are docile and less excitable to experimental manipulation than are monkeys, cats, or dogs, and thus, are easier to restrain. They are large enough to support microelectrode assemblies for recording neuronal activity, and they have a large blood volume, allowing repeated sampling.

Southdown ewes were selected as the breed of choice for microelectrode studies because of their reported skull uniformity, small size, and availability. Their small size made them less expensive to keep than larger breeds and allowed adaptation of an available cat and dog

stereotaxic head-holder to their skull conformation. The Southdown's blocky body and short neck made it relatively easy to restrain during chronic microelectrode studies.

Prior to this study, no stereotaxic atlas has been available for Southdown sheep. Although research on ruminants has created several stereotaxic atlases [goat (Tindal, Knaggs, and Turvey, 1968); water buffalo (Singh, Singh, Soni, and Manchanda, 1972); Préalpes-Du-Sud sheep (Richard, 1967); and Merino sheep (Welento, Szteyn, and Milart, 1964)], skull variation from one species or breed to another is too great to allow their use on the Southdown. The atlas presented herein was constructed for this purpose. It features plates of each section, both unstained and thionin stained, for quick and easy location of nuclear structures in unstained tissue.

CHAPTER II

MATERIALS AND METHODS

Definition of the Stereotaxic Coordinate System

The stereotaxic coordinate system in this atlas is based on the definition of three orthogonal planes: the horizontal, tranverse, and midsagittal reference planes. These three planes intersect at the zero point, a point midway between the tips of the stereotaxic instrument ear bars. The horizontal reference plane lies parallel to the instrument platform. It and the transverse reference plane intersect along the interaural axis (an imaginary line passing through the center of both external auditory meatus). The midsagittal reference plane bisects the interaural axis thus dividing the brain near the midline. The location of any point in this three dimensional system is defined by frontal, lateral, and vertical coordinates (rectilinear measurements of distance from a point to the three reference planes described).

In this atlas, lateral coordinate axes are lines with a vertical coordinate of zero, lying in the horizontal reference plane and orthogonal to the midsagittal plane; vertical coordinate axes are lines with a lateral coordinate of zero, lying in the midsagittal plane, and orthogonal to the horizontal plane; and the single frontal coordinate axis is a line with a lateral and vertical coordinate of zero lying in the horizontal plane and orthogonal to the transverse plane. Lateral, vertical,

and frontal coordinates are distance measurements in millimeters made parallel to these axes from the proper reference plane.

Orientation of the Head

In 1908 Horsley and Clark, using the rhesus monkey, oriented the horizontal reference plane parallel to the interaural-infraorbital plane (a plane passing through the interaural axis and the center of the lower margin of the boney orbit of the eye). This head orientation also has been used for the dog (Lim, Liu, and Moffitt, 1960), the cat (Snider and Niemer, 1961; Bleir, 1961), and many other animals. Because of angular variation between the longitudinal axis of the brainstem and the interaural-infraorbital plane, this orientation could result in the brainstem being other than horizontal in different animals (Oswaldo-Cruz and Rocha-Miranda, 1968).

For the purpose of this atlas the decision was made to tilt the head at an angle making the longitudinal axis of the brainstem parallel with the frontal coordinate axis. In order to determine the brainstem's orientation within the skull, a sheep head was perfused with formalin and refrigerated for one week. Following formalin fixation, the head was cut in the midsagittal plane with a band saw. This demonstrated that the interaural-infraorbital plane intersected the longitudinal axis of the brainstem at approximately a 20° angle. A difference in height of 24 millimeters between the infraorbital hooks and the ear bars approximately aligned the frontal coordinate axis with the brainstem axis (Figure 1).

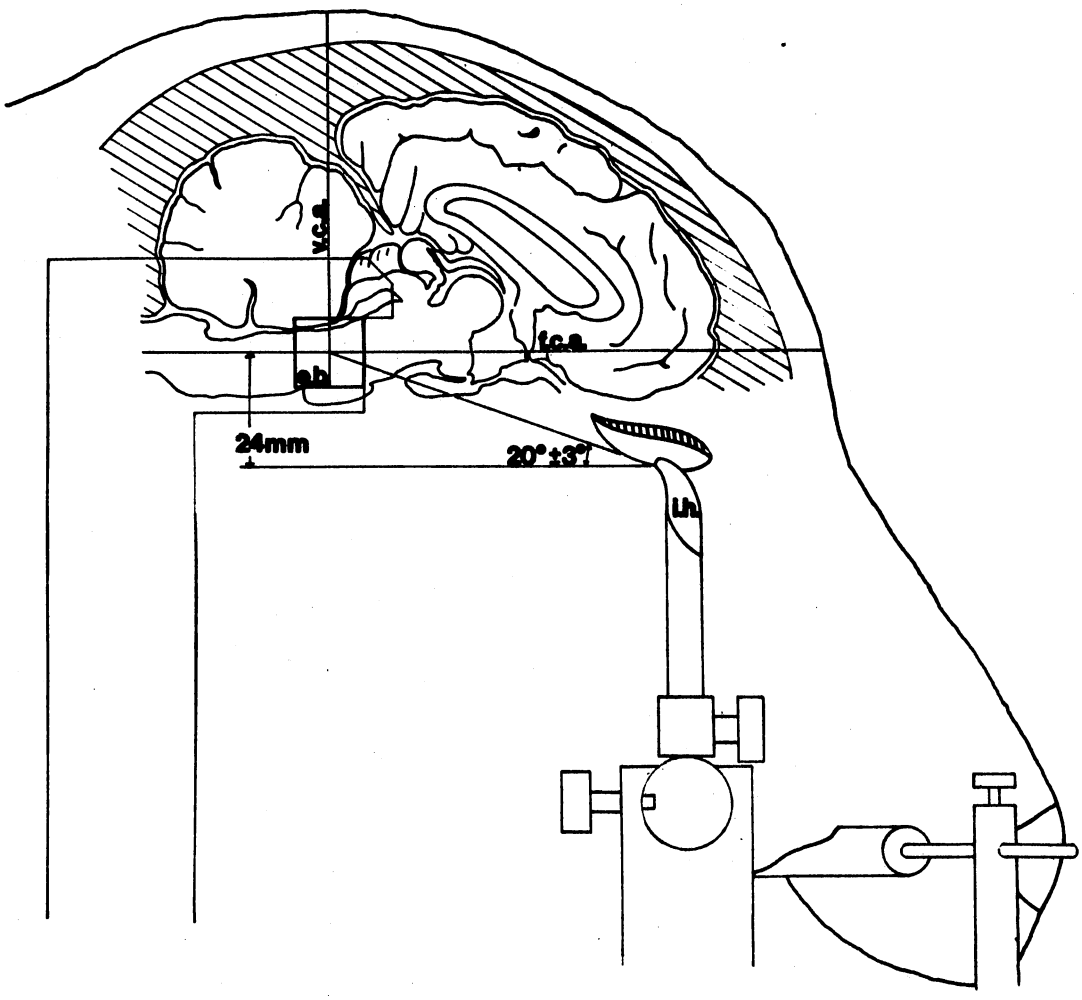

Figure 1. Alignment of the Brainstem With the Frontal Coordinate Axis. e.b.-ear bar; f.c.a.-frontal coordinate axis; i.h.-infraorbital hook; v.c.a.-vertical coordinate axis.

Modification of Head-Holder

Once a desired orientation of the head was determined, modifications of the Baltimore dog and cat head-holder were designed to achieve this orientation and to accommodate the larger sheep head. The distance between ear bar supports was widened from 150 to 216 millimeters and elevated to a position 24 millimeters above the infraorbital hooks (Figures 2A and 2B). The increased height of the ear bar tips above the infraorbital hooks was calculated to position the interaural-infraorbital axis at approximately a 20° angle to the frontal coordinate axis (Figure 1). The ear bar supports were designed with an extension at the top of the vertical support bar to allow a lateral radiographic view of the sella tursica.

The increased distance between ear bar supports necessitated extensions for the ear bars as shown in Figure 3. The extensions are in the form of sleeves that fit snugly over the original tips and add an extra 22 millimeters to each ear bar. The ear bar sleeves maintain a diameter of six millimeters and have blunt tips to prevent perforation of the tympanic membrane.

In addition to the ear bars, the other point of fixation is furnished by the infraorbital hooks; maxillary lifters force the infraorbital arches up into this point of fixation. As illustrated in Figure 2D, both the infraorbital hooks and the maxillary lifters were originally on the same bar extending from one side of the moveable platform to the other. The maxillary lifters were left unchanged; however, because of the large snout of the animal, bilateral supports for the infraorbital hooks were necessary (Figure 2C). The modified head-holder is shown in Figure 4.

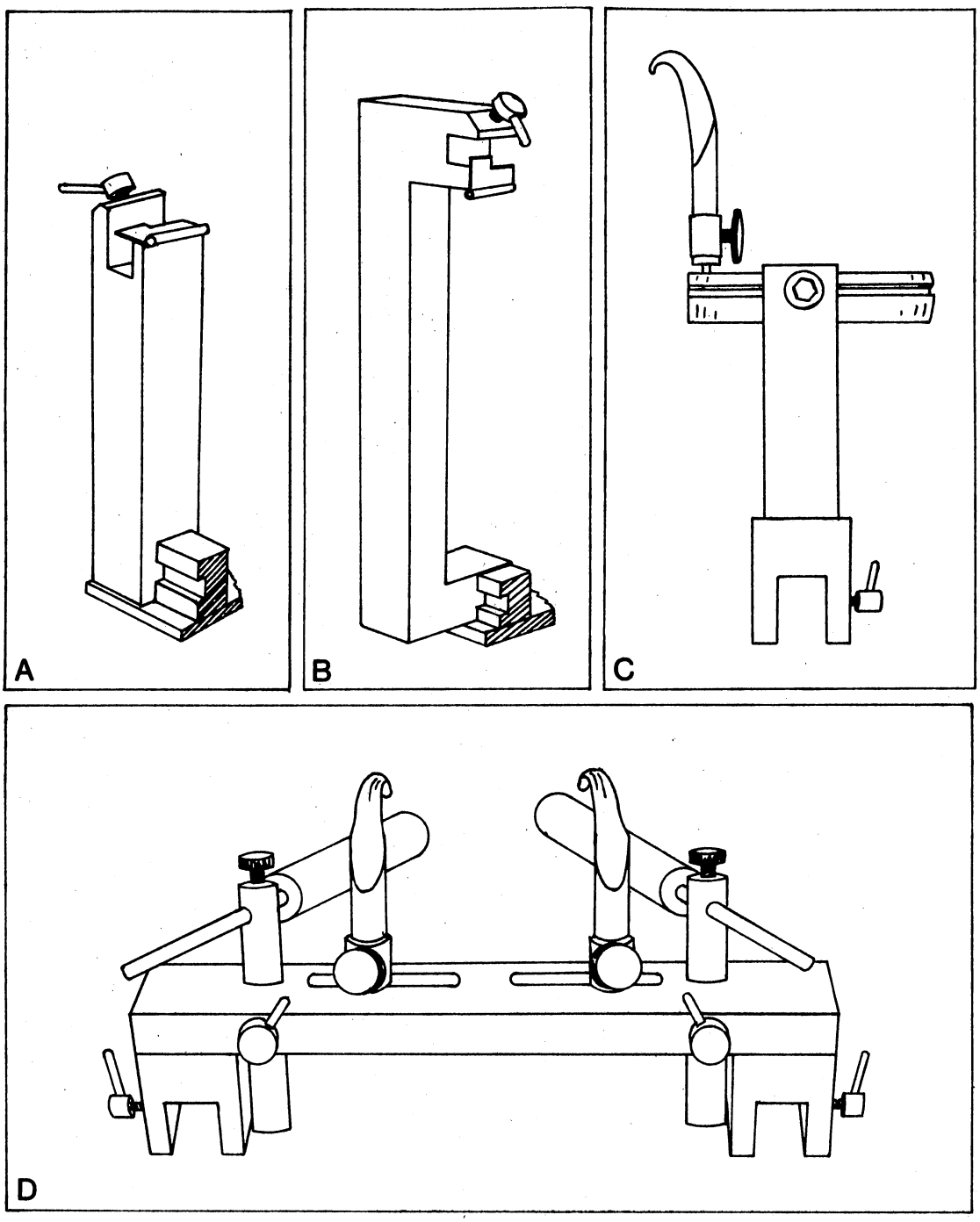

Figure 2. Modifications of the Head-Holder. A. Original ear bar support; B. Modified ear bar support; C. Modified infraorbital hook support; D. Original support for infraorbital hooks and maxillary lifters.

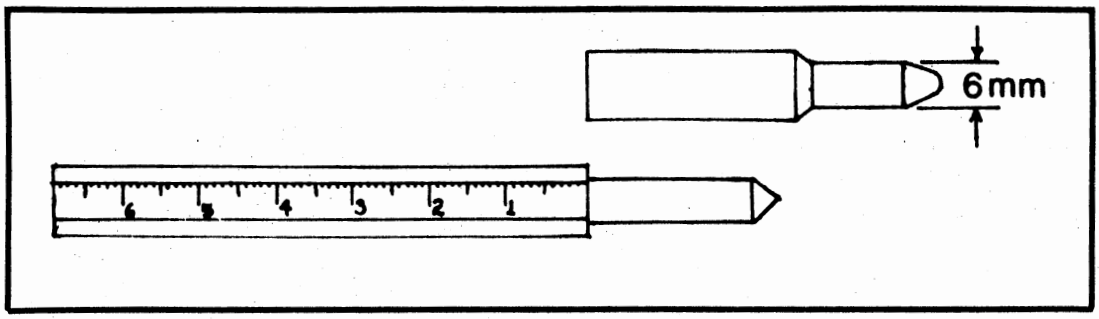

Figure 3. Modification of the Ear Bars. The sleeve (top illustration) fits snugly over the end of the original ear bar.

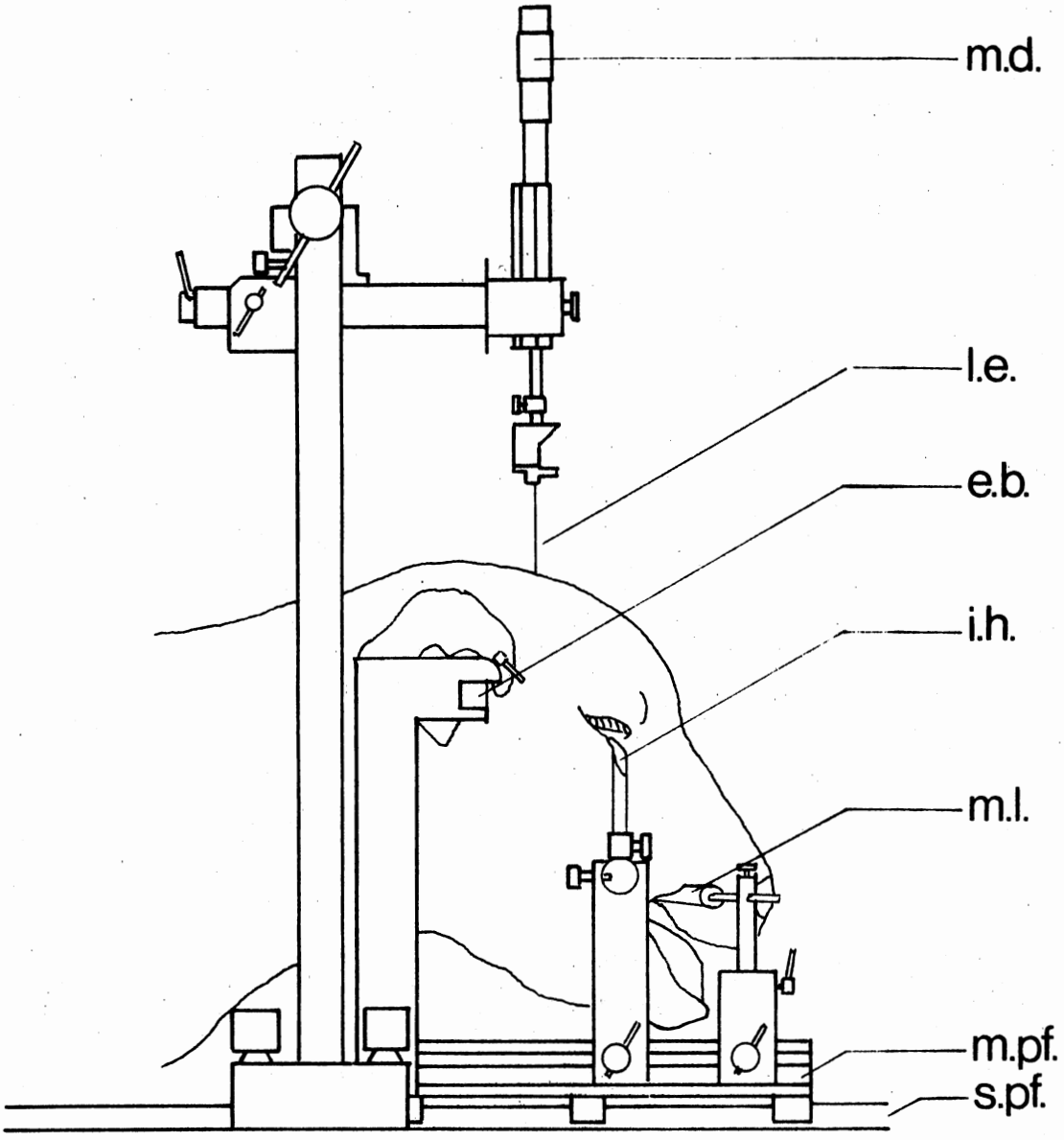

Figure 4. Placement of Head in the Head-Holder. e.b.-ear bar; i.h.-infraorbital hook; l.e.-lesion electrode; m.d.-micro drive; m.l.-maxillary lifter; m.pf.-moveable platform; s.pf.-stationary platform.

Positioning the Sheep Head in Head-Holder

Before positioning each animal in the head-holder, stereotaxic zero coordinates were determined. The moveable platform was fastened to the stationary platform runners and the ear bars were centered. The electrode was fastened to the electrode microdrive and its tip was centered between the ear bars so that frontal, lateral, and vertical "zero coordinates" could be determined. After determining coordinate readings for the electrode tip at zero position, the electrode was moved to one side to allow the sheep head to be placed in the head-holder. General anesthesia was administered to the animal throughout the time it was positioned in the head-holder.

In the experiences of this laboratory, correct placement of both ear bars was the first and most critical step for reasonable stereotaxic accuracy. When sliding the ear bar into an ear canal one must test the tendency of its tip to slip into other cartilagenous depressions; however, care should be taken to avoid damaging the cartilage (Richard, 1967). In agreement with other investigations on the goat, we have found that if damage is sustained, it can be quite difficult to place the ear bars properly (Tindal, et al., 1968). Once the first ear bar is correctly seated, care must be taken to insure it remains seated while fastening it to the ear bar support. The alternate ear bar is then handled in a similar way. Once both ear bars are seated and fastened in the ear bar holders, the head can be centered by sliding the ear bars in the supports. A lapse in pressure at this point has been a prelude to difficult replacement.

With the head centered, a few checks for accurate ear bar placement were routinely made. Movement of the head was attempted with restrained

vigor. The skull was examined to see how level and straight it appeared. The calibration reading on the ear bars was compared with previous readings, our readings being 32 ± 3 millimeters. If the previous checks agreed, the infraorbital hooks were positioned at the lowest point of the infraorbital arch. The head was forced up against the hooks by the maxillary lifters and given its final check. The correct angle between the upper edge of the head-holder and the rostral edge of the nose was approximately 125°. Examining the tilt of the head and the centering of the nose from the front was helpful when an error in placement appeared likely as checked by other methods, but in itself, it could occasionally be misleading.

Lesioning Procedure

A craniotomy was extended with bone rongeurs sufficiently to make a series of paired bilateral lesions at orthogonally determined points five to ten millimeters apart. The lesion points extended from rostral of the diencephalon caudalward to the mamillary bodies. Rostral to the area being studied a set of four lesions was placed for use as reference points when positioning the formalin-fixed diencephalon in the cryostat. Lesions were made by passing a direct current through a glass insulated stainless steel electrode, thus depositing Fe^{++} ions in the tissue at the uninsulated electrode tip. During subsequent perfusion, the Fe^{++} ions were reacted with sodium ferrocyanide producing Prussian blue spots approximately one millimeter in diameter or less.

Perfusion

After lesioning, both carotid arteries were cannulated for perfusion, and the jugular veins or right atrium were lanced to permit adequate drainage of the vascular system. The animal was perfused first with 4000 milliliters of normal saline to clear the vascular system and prevent clotting. This was followed by 2000 milliliters of isotonic saline containing ten per cent formalin and two per cent sodium ferrocyanide. Once perfused, the head was removed and refrigerated. At the end of a week, the partially fixed brain was removed from the skull, and a block of tissue containing the diencephalon was placed in a jar of formalin for ten days.

Sectioning

Following fixation, the brainstem was serially sectioned on an International Equipment Co. Model CTD cryostat at minus six to minus eight degrees Centigrade. The tissue block was mounted with its ventral surface towards the cutting edge of the blade and was tilted until the rostral set of four lesions was being cut in the same section. This positioning of the block insured that sections were cut perpendicular to the frontal coordinate axis. One hundred micron thick sections were cut and mounted directly on slides coated with a solution of 0.5 per cent gelatin and 0.05 per cent chrome alum. Every fifth section was used for the atlas.

Photography of Unstained Sections

While the tissue section was still wet, it was mounted in a photographic enlarger in a manner similar to using a film negative in an

enlarger (Guzmán, Alcarez, and Fernández, 1958). The image was recorded on number four contrast photographic paper. Due to the opaqueness of the myelin relative to the transparency of grey matter, the resulting reversal print gave good definition of myelinated areas. Prints did not have to be made immediately since sections could be kept moist for several minutes by placing them in a covered staining dish containing a small amount of formalin. Besides allowing more time to work with the sections, this procedure facilitated further binding to the gelatin coated slide prior to thionin staining. Air bubbles were a problem that was never completely eliminated, but could be reduced considerably by floating portions of the sections free of the slides and brushing away debris.

Thionin Staining

The tissue sections are allowed to dry prior to thionin staining. Thionin is an acidophilic stain which probably binds the phosphate groups of nucleic acids thus defining nuclear areas. The pH of the stain is approximately 3.2 which gives a negative charge to the primary phosphate groups of nucleic acids having a pK of about 2 (Pearse, 1961). The organic acids with a higher pK than 3.2 will not take up the stain, thus increasing the specificity of the dye. The staining procedure is as follows.

Concentrate Stain:	0.1 Gm. Thionin
	400 ml. Water
	8 drops Acetic Acid
Stain Bath:	80 ml. of Stain Concentrate
	240 ml. of Water
	5 drops of Acetic Acid

1. Dioxane Bath - 15 minutes
2. Distilled Water - 3 fast dips
3. Thionin Stain - 20 minutes
4. Dioxane and Absolute Alcohol (1:1) - 2 minutes
5. Dioxane and Absolute Alcohol (1:1) - 5 minutes
6. Dioxane and Absolute Alcohol (1:1) - Until desired decoloration
7. Dioxane Bath - 15 seconds agitated
8. Dioxane Bath - 15 seconds agitated
9. Xylene - 2 minutes or until milky film removed
10. Xylene - 5 minutes
11. Xylene - 5 minutes

Note: the relatively large thickness of the tissue sections necessitated a long penetration time for the stain; this time could be shortened by removal of the lipid with butanol and chloroform prior to staining.

Photography of Stained Sections

The stained sections were photographed with Leitz Aristophot macrodia equipment and a bellows camera that were well-aligned to eliminate light scatter in the photographic system. A condenser with an 80 millimeter focal length and a Summar 80 millimeter 1:4.5 Ernst Leitz Wetzlar lens were used in this system which utilized transmitted illumination of the slide. Between the light source and the stage, Kodak Wratten gelatin filters 90 and 73 were placed to improve the contrast of stained and unstained areas. The Kodak Wratten 90 filter transmits light between 550 and 640 nanometers with peak transmittance at 580 nanometers, and the Kodak Wratten 73 filter transmits light between 560 and 610 nanometers

with peak transmittance at 570 nanometers. Both filters transmit light at wave lengths that are absorbed by thionin which absorbs the most light between 500 and 625 nanometers with peak absorbance at 596 nanometers (Gurr, 1971). Thus by use of filters, the degree of light absorbance by the stained areas over the unstained areas is increased greatly.

Kodak Contrast Process Pan, a wide spectrum film was used to photograph the slide. The film was selected for its steep "gamma" curve which provided high contrast, and not for its spectral sensitivity which extends below 400 and above 640 nanometers. The film was developed with Kodak D-11 developer at a temperature of 68 degrees Fahrenheit for four minutes. Prints of these negatives were made using a number four filter and Dupont Velour Black four contrast paper.

Determination of Frontal Coordinates

Frontal coordinates for the atlas were determined by the following steps.

1. Percent shrinkage was calculated for each of five brainstems. The lesion frontal coordinates and the number of 100 micron sections between lesions were compared. There should be 40 sections between lesions placed 4 millimeters apart; if there is fewer than 40 sections, then the distance between the lesions has shrunk.

$$\left(1 - \frac{\text{number of sections between lesions}}{\text{distance between lesions in mm X 10}}\right) \text{ X } 100 = \text{per cent shrinkage}$$

2. Actual thickness of fresh tissue per 100 micron section was calculated.

100 + per cent shrinkage = fresh tissue section thickness in microns

3. Frontal positions of the commissura anterior, nucleus supra-opticus, and thalamic adhesion were calculated using frontal lesion coordinates and corrected tissue section thickness.

4. Mean frontal coordinates for the previous named structures were calculated from the five brains.

5. A scalar profile of these mean structural coordinates was matched for best fit with a scalar profile of identical structures displayed in the atlas. The resulting match dictated frontal coordinates used in the atlas.

Determination of Vertical Coordinate Axes

Vertical coordinates were determined by reconstructing the brainstem in acetate overlays. The overlays were traced from the photographs made with the wet tissue sections; the lesions were marked on the overlays as they occurred in the brainstem. Tacks were passed through the stack of overlays so that they passed close to all lesion sites. The overlays were then matched with their respective photograph, and the vertical coordinate axis was determined from the tack holes. To help illustrate the vertical variation expected between sheep, coordinates for the bottom midline of four Southdown sheep skulls were plotted.

Determination of Lateral Coordinate Axes

The lateral coordinate axes were centered about the midline of each section. A scale was determined from bilateral lesions spread 12 millimeters apart.

Determination of Nomenclature

Nomenclature was based on a communication from Dr. James E. Breazile to fellow members of the Subcommittee on Histologic Nomenclature of the International Committee on Veterinary Anatomical Nomenclature (ICVAN), concerning terminology for nervous tissue and for the central nervous system, dated July 22, 1971. This latter group operates under the authority of the World Veterinary Congress. This nomenclature was followed as closely as possible; however, this was a preliminary list and did not appear to be complete. Structures in the atlas not appearing on the list are as follows: the chiasma opticum, the tractus opticus, the area hypothalamica caudalis, the nucleus pretectalis anterior, and the commissura caudalis. The chiasma opticum, the tractus opticus, and the commissura caudalis appear to have been overlooked, but the area hypothalamica caudalis and the nucleus pretectalis anterior may have been present in the list as the area hypothalamica dorsocaudalis and the nucleus pretectalis medialis, respectively. The term area hypothalamica caudalis was based on hypothalamic divisions by Haymaker, Anderson, and Nauta (1969) which was used as the final authority on hypothalamic organization. The term nucleus pretectalis anterior was based on its agreement with Richard (1970) and Rose (1942). Boundaries of the area hypothalamica caudalis, area hypothalamica dorsalis, area hypothalamica lateralis, area septalis, area preoptica, nucleus hypothalamicus dorsomedialis, and nucleus hypothalamicus rostralis were intended to be conservative, positioning the mass of the structures in known locations and leaving off identification of that structure when its nuclear pattern seemed to disappear. Crosby, Humphrey, and Lauer (1962, p. 311) was

often used to clear up conflicts on nomenclature, especially concerning thalamic divisions and the nucleus mamillaris lateralis.

CHAPTER III

RESULTS

Using data obtained from five Southdown ewes, variation in frontal, lateral, and vertical coordinates was examined. The standard deviation for commissura anterior, nucleus supraopticus, and thalamic adhesion frontal coordinates was held to a maximum of 1.30 millimeters as shown in Table I.

TABLE I

FRONTAL COORDINATE MEANS AND STANDARD DEVIATIONS OF SELECTED STRUCTURES

Structure	Mean Frontal Coordinates	Standard Deviation
Commissura Anterior		
Anterior Edge	30.9 mm	0.57 mm
Posterior Edge	30.1	0.68
Nucleus Supraopticus		
Anterior Edge	30.4	1.30
Posterior Edge	28.1	0.58
Thalamic Adhesion		
Anterior Edge	27.9	0.24
Posterior Edge	20.9[1]	0.52[1]

[1]Three sheep were used instead of five.

Stereotaxic accuracy in the lateral axis was examined from two different perspectives. First, lateral coordinate variation for the commissura anterior and the nucleus supraopticus was calculated with reference to each sectional midline (Table II). Second, accuracy in the lateral placement of lesions was measured relative to the midline (Table III).

TABLE II

LATERAL COORDINATE MEANS AND STANDARD DEVIATIONS OF SELECTED STRUCTURES

Structure	Mean Lateral Coordinates	Standard Deviation
Commissura Anterior		
Lateral Edge	2.7 mm	0.35 mm
Nucleus Supraopticus		
Medial Edge	2.8	0.48
Lateral Edge	8.9	0.91

TABLE III

MEAN LATERAL ERROR IN LESION PLACEMENT

Animal Studied	Average Lateral Error for Lesion Sets	Standard Deviation	Number of Lesion Sets
Sheep 3	0.61 mm	0.34 mm	4
Sheep 8	1.50	0.35	2
Sheep 11	0.54	0.25	6

Vertical variation in the midsagittal floor of the cranium is examined in Figure 5. This reflects the result of different tilts for each head, the maximum effect on vertical variation being furthest away from the ear bars, about which the head rotates.

Using the method of transparent overlays described on page 16, positions of lesion sets were projected onto adjacent tissue sections. This method provided examination of the vertical coordinates for the commissura anterior and the nucleus supraopticus (Table IV). With variation in tilt being a factor in the standard deviation, these rostrally located structures should give an indication of the maximum vertical variation to be expected.

The list of structures identified, their abbreviations, and the series of forty-two plates follows on pages 26-71.

TABLE IV

VERTICAL COORDINATE MEANS AND STANDARD DEVIATIONS OF SELECTED STRUCTURES

Structure	Mean Vertical Coordinates	Standard Deviation
Commissura Anterior		
Dorsal Edge	+ 7.7 mm	2.80 mm
Ventral Edge	+ 6.5	2.90
Nucleus Supraopticus		
Dorsal Edge	+ 2.3	3.38
Ventral Edge	+ 0.8	3.64

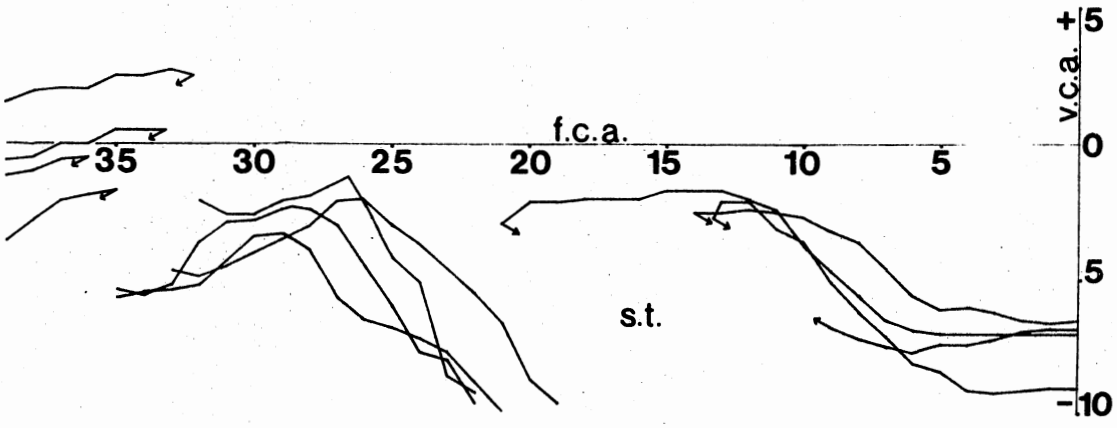

Figure 5. Vertical Variation in the Midsagittal Floor of the Cranium. Measurements in millimeters were taken from four sheep relative to the zero point (center of interaural axis). Lines were discontinued where partial destruction of the cranium or interfering structures made measurements impossible; the direction in which the cranial floor continued was indicated by arrows. f.c.a.-frontal coordinate axis; s.t.-sella tursica; v.c.a.-vertical coordinate axis

CHAPTER IV

DISCUSSION AND CONCLUSION

The realiability of introducing electrodes into the hypothalamus using only a stereotaxic atlas has been questioned by Larsson (1954) and Anderson, Persson, and Ström (1960), who emphasize the necessity of radiological control. Concurrent investigations in this laboratory on Southdown sheep have required radiographic confirmation for critical placement of electrodes. This is understandable since there is variability in skull configuration and consequent variability in the related coordinate systems' alignment with the brain.

However the accuracy of this stereotaxic atlas has proven to be within useful limits. The maximum standard deviations for frontal, lateral, and vertical coordinates are 1.30 millimeters (Table I), 1.50 millimeters (Table III), and 3.64 millimeters (Table IV), respectively.

One reason for the small frontal standard deviation was that in addition to defining frontal and vertical coordinates, the lesions provided a means of checking for shrinkage. For each brain, tissue shrinkage was calculated and used to adjust its frontal coordinates. The atlas' frontal coordinates were then matched with average frontal coordinates for the commissura anterior, the nucleus supraopticus, and the thalamic adhesion.

Lateral variation in nuclear structures appeared to be quite small (Table II). The main source of error was in determining the midline

relative to head orientation in the head-holder. This resulted in a lateral placement error as great as 1.50 millimeters (Table III). Use of the sagittal sinus as a lateral reference would eliminate dependence on skull uniformity, and should improve accuracy.

The zero vertical coordinates for each plate were determined directly from the brain used in the atlas. The method of transparent overlays described on page 16 was used to project lesion positions onto adjacent tissue sections. Vertical coordinates were then determined relative to the lesions. This method was used in determining the mean vertical coordinate and the standard deviation for the commissura anterior and the nucleus supraopticus (Table IV). These standard deviations ranged from 2.80 to 3.64 millimeters, with the atlas' coordinates differing approximately 2.5 millimeters from the mean.

Calculations for these rostrally located structures give an indication of the maximum vertical variation to be expected. Small differences in head tilt from one sheep to the next contribute to this variation. The maximum effect would be furthest away from the ear bars, about which the head rotates. The result of this rotary variation is illustrated in Figure 5 showing vertical variation in the midsagittal floor of the cranium. This should reflect the vertical variation expected in the closely associated brainstem.

The head-holder alone was the source of some uncertainty. Due to a limited budget and nonavailability of a commercial sheep head-holder, an available Baltimore cat and dog stereotaxic head-holder had to be modified for sheep, the cost of modifications being closely scrutinized. Therefore the ear bar supports were made of aluminum, a soft, easily machined metal. A more rigid and heavier metal would have been better.

A slight bending and twisting of the ear bar supports occurred when the ear bars were pushed in and fastened; the twisting was a natural result of the lateral pressure from the ear bars on the frontal extension of the ear bar supports. This extension structurally weakened the head-holder design and should be incorporated only if necessary for radiographic control in future designs.

Stereotaxic accuracy of the atlas is an area of principle concern; however, this atlas also provides comparative plates of unstained and thionin stained sections which can be used for quick location of structures on other animals than Southdown sheep. It is certainly most applicable to sheep and may be easier to obtain than the other two sheep atlases referenced (Richard, 1969; Welento, et al., 1964), one being a publication in French of the Paris Institut National de la Recherche Agronomique and the other in Volume 124 of Anatomischer Anzliger.

In summary, the resulting stereotaxic atlas identifies and locates major diencephalic structures of the Southdown ewe in reference to a three-dimensional coordinate system. The described head-holder modifications, made to accommodate sheep in a Baltimore cat and dog head-holder, were adequate for accurate stereotaxis. However, small improvements in accuracy might be obtained by using a more rigid material than aluminum in constructing these modifications. The photographic comparison of unstained and thionin stained sections can be a useful tool for locating structures in neurological studies.

CHAPTER V

STEREOTAXIC ATLAS

The following structures were identified.

Plates	Abbreviation	Structure
20-26	Ahc	Area hypothalamica caudalis
14-21	Ahd	Area hypothalamica dorsalis
9-16	Ahl	Area hypothalamica lateralis
1- 7	Ap	Area preoptica
1- 7	As	Area septalis
1- 9	Ci	Capsula interna
2-10	Co	Chiasma opticum
38-40	Cso	Colliculus rostralis stratum opticum
38-42	Csz	Colliculus rostralis stratum zonale
1- 7	Ca	Commissura anterior
31-42	Ccd	Commissura caudalis
38-42	Ccr	Commissura colliculorum rostralis
30	Ch	Commissura habenularum
26-29	Csm	Commissura supramamillaris
1-24	Cc	Corpus callosum
32-42	Cs	Corpus subcommissuralis
26-33	Fh	Fasciculus habenulointerpeduncularis

Plates	Abbreviation	Structure
1-27	Fos	Fasciculus occipitoanterior superior
		Fasciculus retroflexus see Fasciculus habenulo-interpeduncularis
		Fasciculus subcallosal see Fasciculus occipito-anterior superior
24-32	FF	Fields of Forel
5-24	F	Fornix
31-38	Pi	Glandula pineale
1- 8	Gp	Globus pallidus
25-42	H	Hippocampus
12-36	Lme	Lamina medullaris thalami externa
12-27	Lmi	Lamina medullaris thalami interna
40-41	No	Nuclei oculomotorii
11-19	Nad	Nucleus anterior dorsalis
15-16	Nam	Nucleus anterior medialis
12-19	Nav	Nucleus anterior ventralis
		Nucleus arcuatus see Nucleus infundibularis
		Nucleus of Cajal see Nucleus interstitialis
1-27	Nc	Nucleus caudatus
18-21	Ncm	Nucleus centralis medialis
16-27	Ndt	Nucleus dorsomedialis thalami
27-36	Ngl	Nucleus geniculatus lateralis
30-41	Ngm	Nucleus geniculatus medialis
24-29	Nhl	Nucleus habenularis lateralis
23-29	Nhm	Nucleus habenularis medialis
16-18	Nhd	Nucleus hypothalamicus dorsomedialis

Plates	Abbreviation	Structure
8-13	Nhr	Nucleus hypothalamicus rostralis
13-17	Nhv	Nucleus hypothalamicus ventromedialis
12-20	Ni	Nucleus infundibularis
35-38	Nit	Nucleus interstitialis
23-33	Nlc	Nucleus lateralis caudalis
17-28	Nld	Nucleus lateralis dorsalis
21-28	Nml	Nucleus mamillaris lateralis
2-29	Nmm	Nucleus mamillaris medialis
6-13	Npv	Nucleus paraventricularis
8-29	Npt	Nucleus paraventricularis thalami
32-38	Npa	Nucleus pretectalis anterior
29-39	Npu	Nucleus pulvinaris
10-27	Nrt	Nucleus reticularis thalami
13-18	Nru	Nucleus reuniens thalami
14-16	Nrh	Nucleus rhomboidieus thalami
33-42	Nr	Nucleus ruber
29-42	Nsn	Nucleus substantia nigra
23-28	Nst	Nucleus subthalamicum
5- 8	Nsc	Nucleus suprachiasmaticus
28-36	Nsg	Nucleus supragenicul atus
22-27	Nsm	Nucleus supramamillaris
6-10	Nso	Nucleus supraopticus
24-29	Nvc	Nucleus ventralis caudalis
19-28	Nvl	Nucleus ventralis lateralis
11-23	Nvr	Nucleus ventralis rostralis
18-42	Pc	Pedunculus cerebri

Plates	Abbreviation	Structure
1-11	P	Putamen
		Stratum periventriculare see Substantia grisea centralis
7-29	Sm	Stria medullaris thalami
5-27	St	Stria terminalis
27-42	Sgc	Substantia grisea centralis
14-25	Tm	Tractus mamillothalamicus
11-22, 38-41	To	Tractus opticus
32-42	Tt	Tractus tegmenti centralis
14-25	Zi	Zona incerta

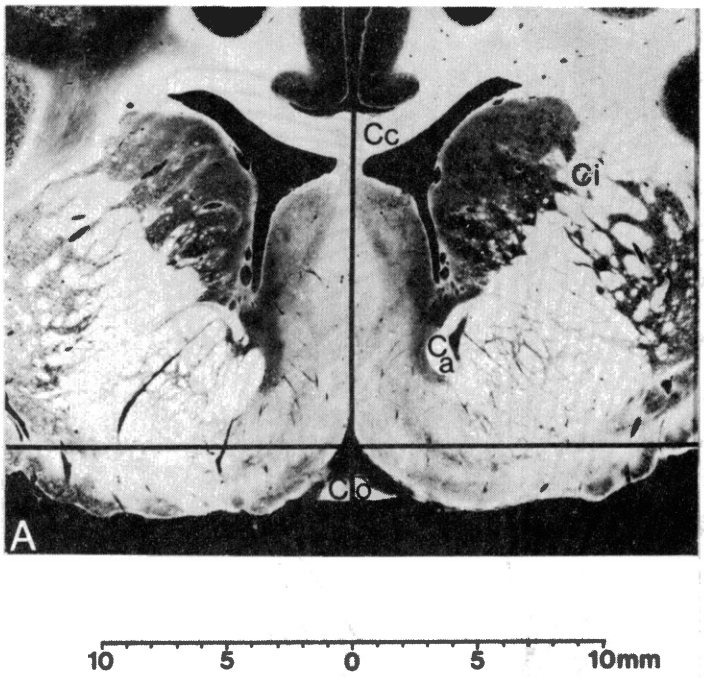

Corpus callosum

Capsula interna

Commissura anterior

Chisasma opticum

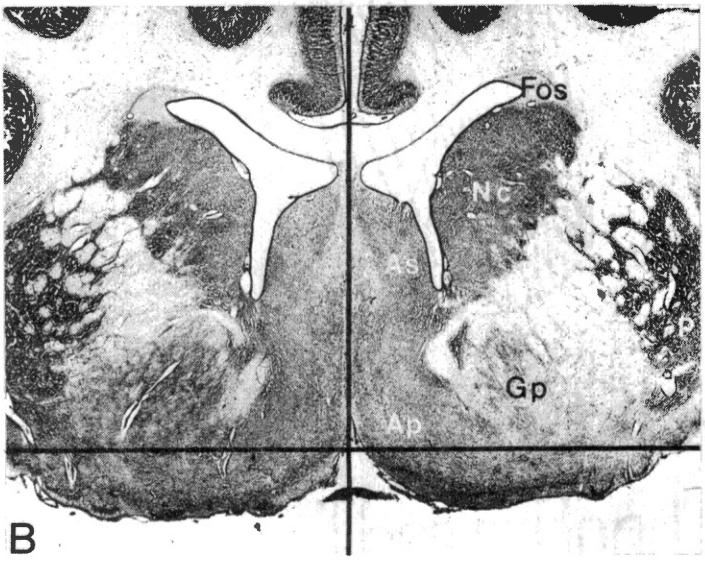

Fasciculus occipitoanterior superior

Nucleus caudatus

Area septalis

Putamen

Globus pallidus

Area preoptica

Plate 1. Section at Frontal 33.6. A. Unstained section; B. Thionin stained section.

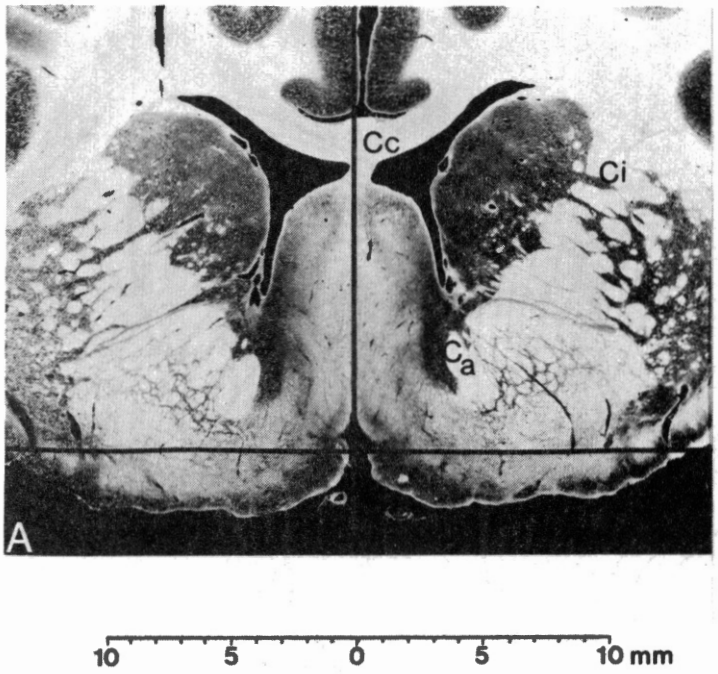

Corpus callosum

Capsula interna

Commissura anterior

Fasciculus occipitoanterior superior

Nucleus caudatus

Area septalis

Putamen

Globus pallidus

Area preoptica

Plate 2. Section at Frontal 33.1. A. Unstained section; B. Thionin stained section.

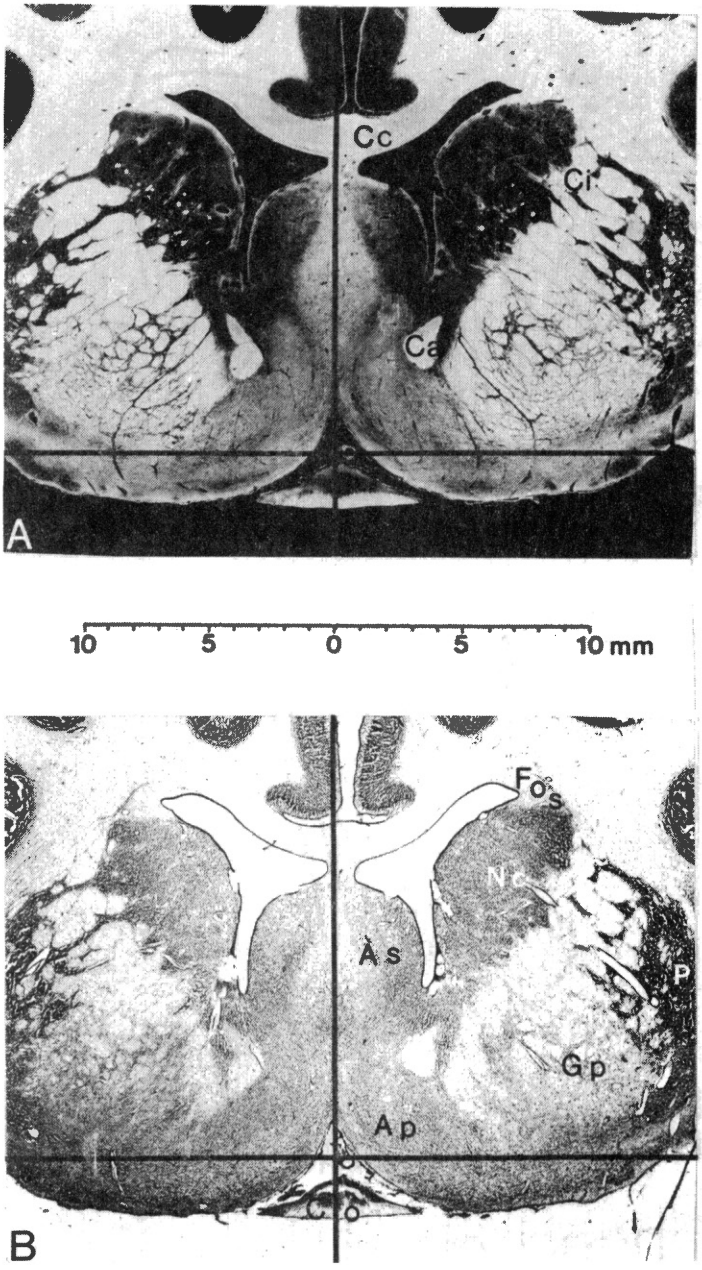

Plate 3. Section at Frontal 32.5. A. Unstained section; B. Thionin stained section.

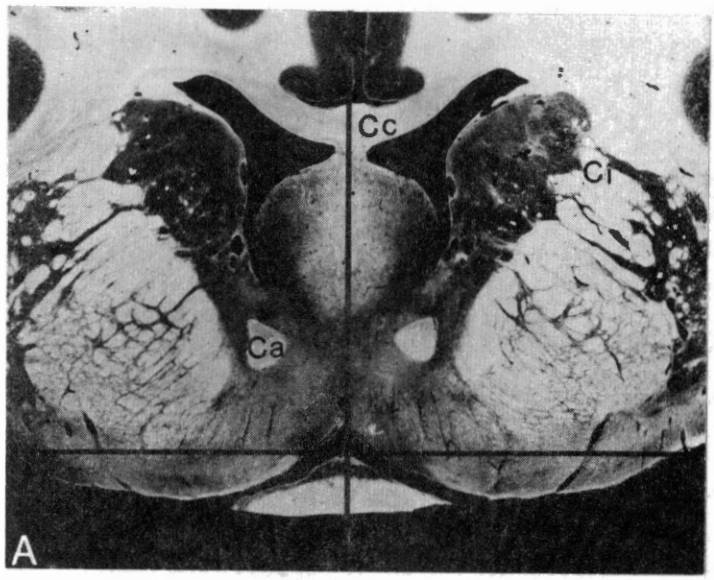

Corpus callosum

Capsula interna

Commissura anterior

10 5 0 5 10 mm

Fasciculus occipitoanterior superior

Nucleus caudatus

Area septalis

Putamen

Globus pallidus

Area preoptica

Chiasma opticum

Plate 4. Section at Frontal 32.0. A. Unstained section; B. Thionin stained section.

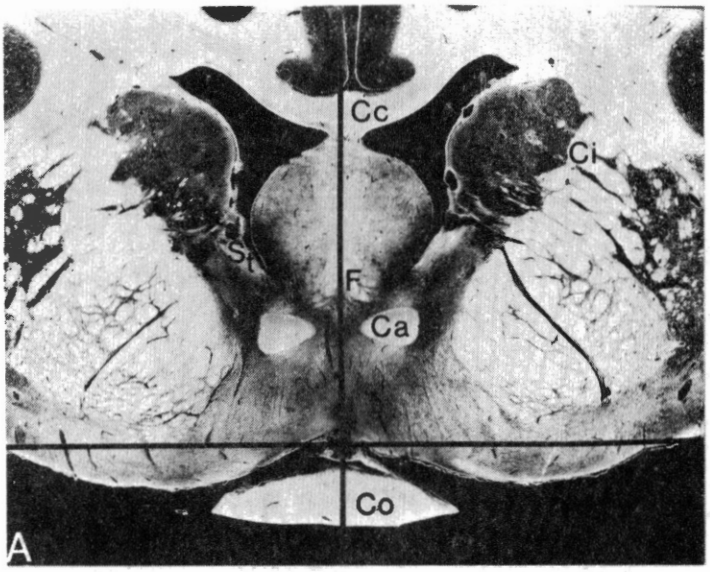

Corpus callosum

Capsula interna

Stria terminalis
Fornix

Commissura anterior

Chiasma opticum

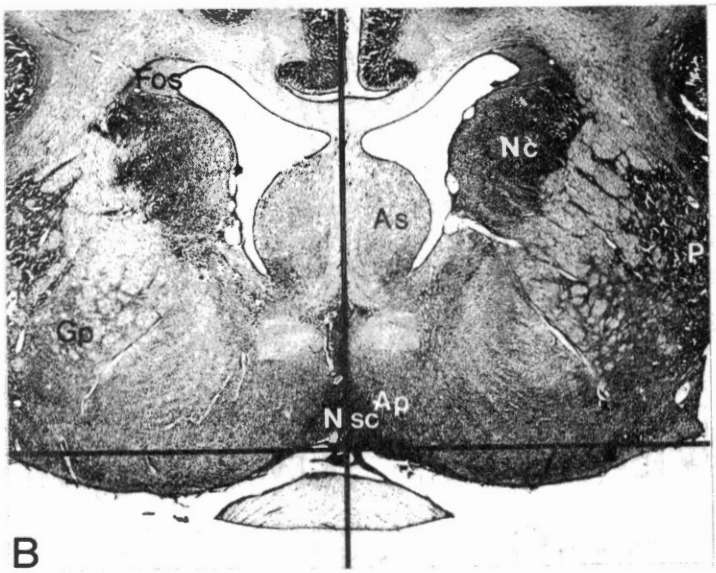

Fasciculus occipitoanterior superior

Nucleus caudatus

Area septalis
Putamen

Globus pallidus

Area preoptica
Nucleus suprachiasmaticus

Plate 5. Section at Frontal 31.5. A. Unstained section; B. Thionin stained section.

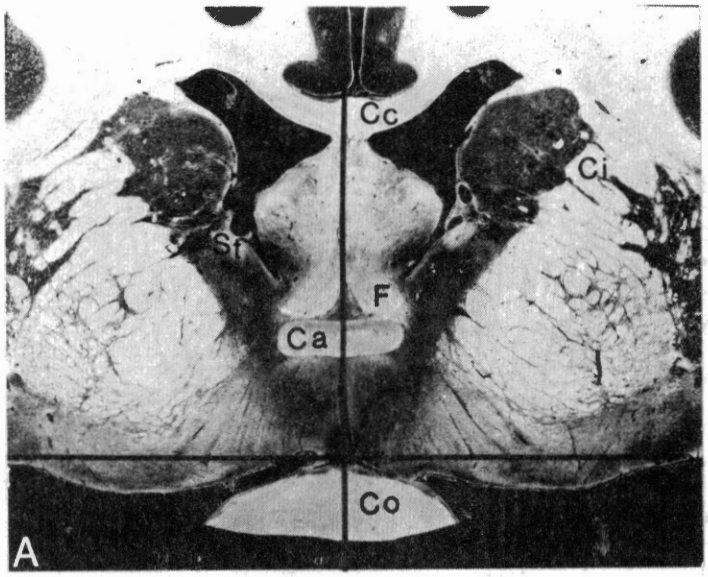

Corpus callosum

Capsula interna

Stria terminalis

Fornix
Commissura anterior

Chiasma opticum

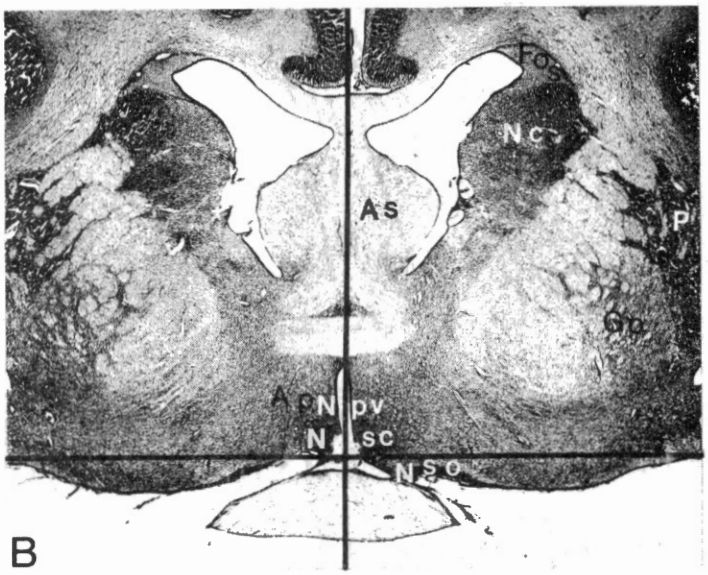

Fasciculus occipitoanterior superior

Nucleus caudatus

Area septalis

Putamen

Globus pallidus

Area preoptica
Nucleus paraventricularis
Nucleus suprachiasmaticus
Nucleus supraopticus

Plate 6. Section at Frontal 31.0. A. Unstained section; B. Thionin stained section.

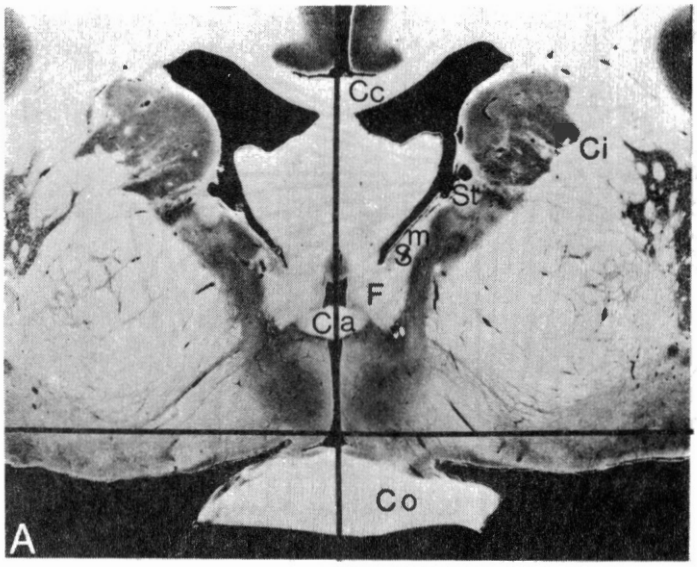

Corpus callosum

Capsula interna

Stria terminalis

Stria medullaris thalami
Fornix

Commissura anterior

Chiasma opticum



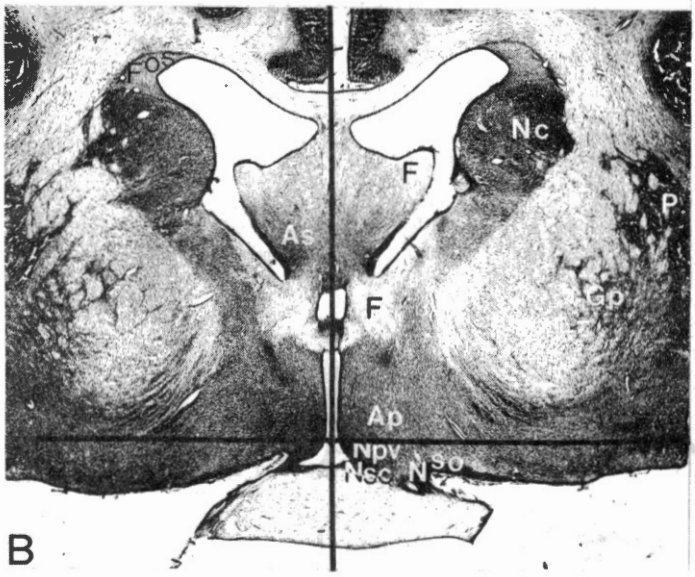

Fasciculus occipitoanterior
superior
Nucleus caudatus

Fornix
Area septalis
Putamen

Globus pallidus
Fornix

Area preoptica

Nucleus paraventricularis
Nucleus suprachiasmaticus
Nucleus supraopticus

Plate 7. Section at Frontal 30.4. A. Unstained section; B. Thionin stained section.

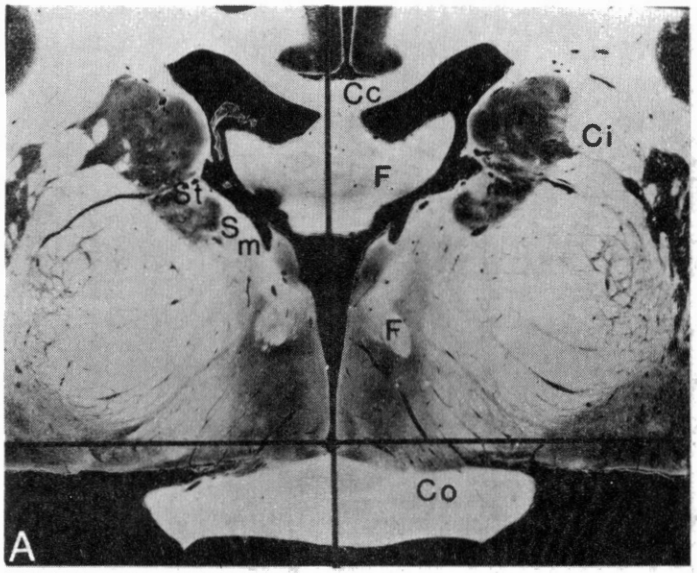

Corpus callosum
Capsula interna
Fornix
Stria Terminalis
Stria medullaris thalami

Fornix

Chiasma opticum

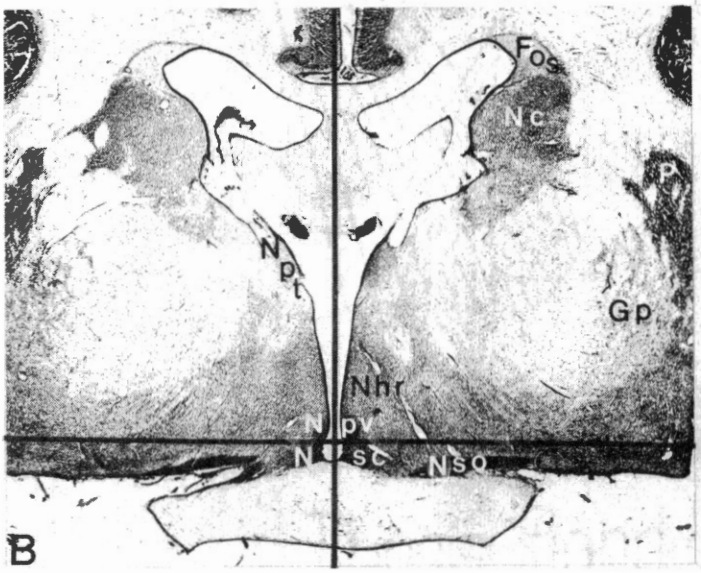

Fasciculus occipitoanterior superior

Nucleus caudatus

Putamen
Nucleus paraventricularis thalami
Globus pallidus

Nucleus paraventricularis
Nucleus hypothalamicus rostralis
Nucleus suprachiasmaticus
Nucleus supraopticus

Plate 8. Section at Frontal 29.9. A. Unstained section; B. Thionin stained section.

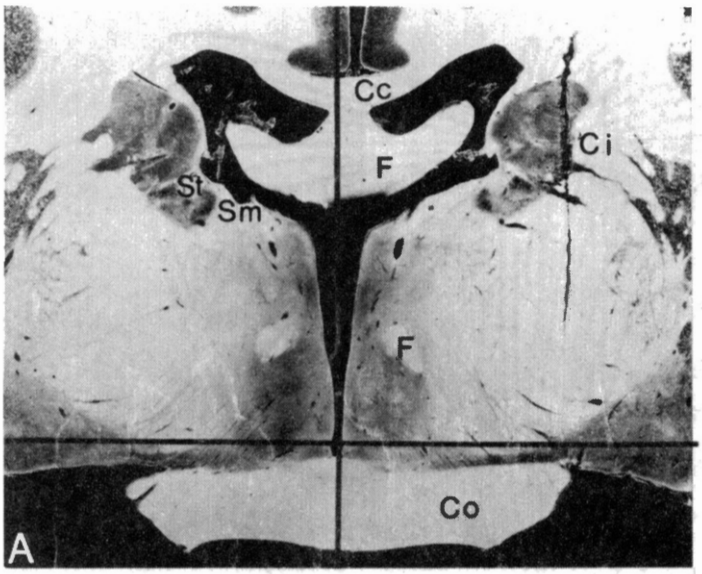

Corpus callosum
Capsula interna
Fornix
Stria terminalis
Stria medullaris thalami

Fornix

Chiasma opticum



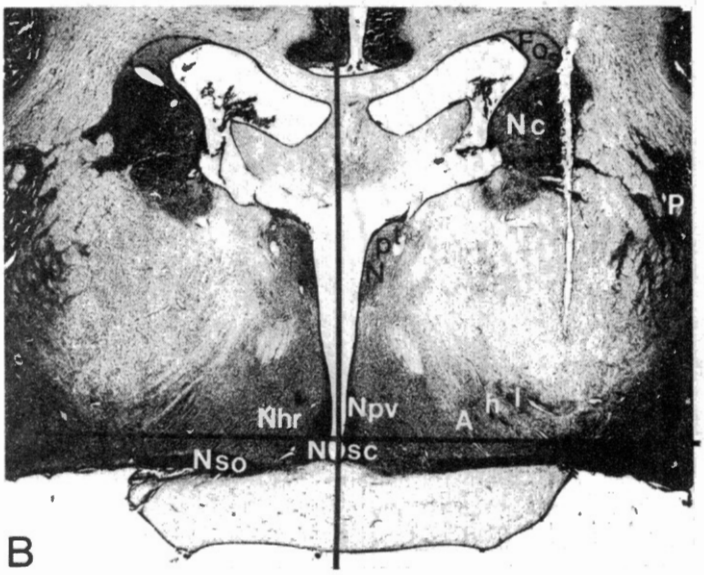

Fasciculus occipitoanterior superior

Nucleus caudatus

Putamen

Nucleus paraventricularis thalami

Nucleus paraventricularis
Nucleus hypothalamicus rostralis
Area hypothalamica lateralis
Nucleus suprachiasmaticus
Nucleus supraopticus

Plate 9. Section at Frontal 29.3. A. Unstained section; B. Thionin stained section.

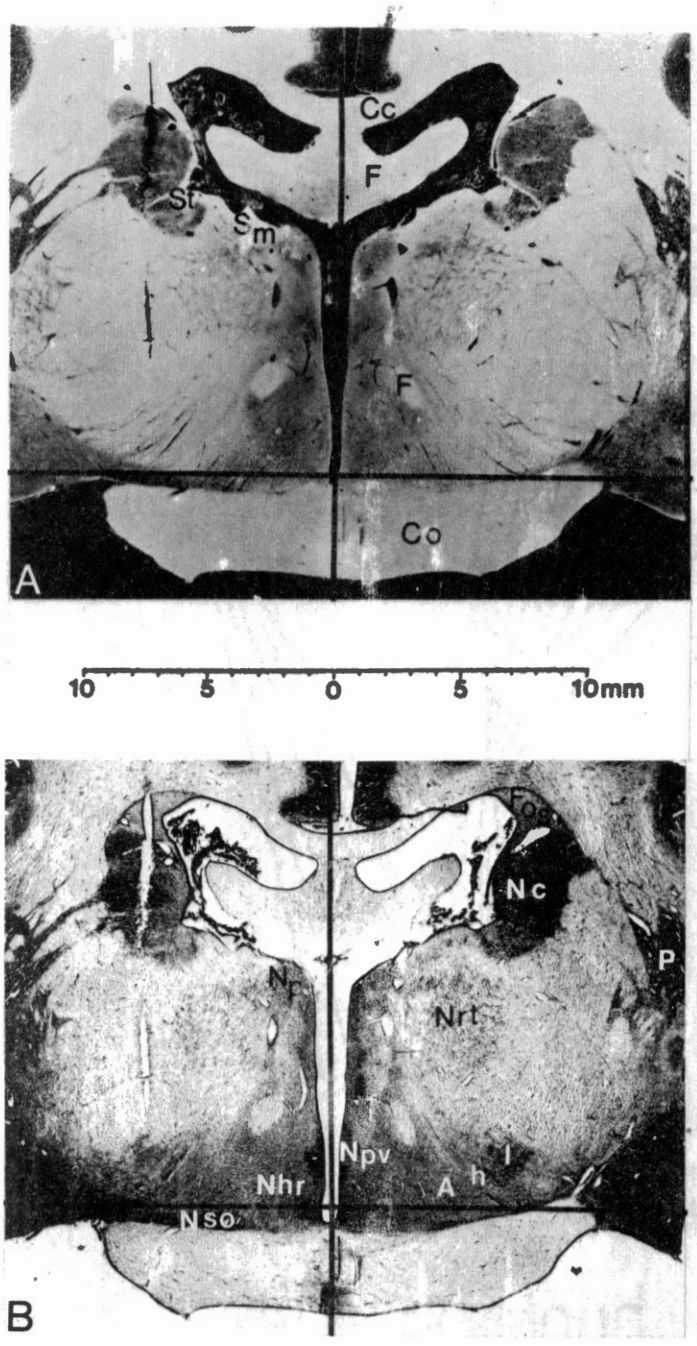

Corpus callosum

Fornix
Stria terminalis
Stria medullaris thalami

Fornix

Chiasma opticum

Fasciculus occipitoanterier superior

Nucleus caudatus

Putamen
Nucleus paraventricularis thalami
Nucleus reticularis thalami

Nucleus paraventricularis
Nucleus hypothalamicus rostralis
Area hypothalamica lateralis
Nucleus supraopticus

Plate 10. Section at Frontal 28.8. A. Unstained section; B. Thionin stained section.

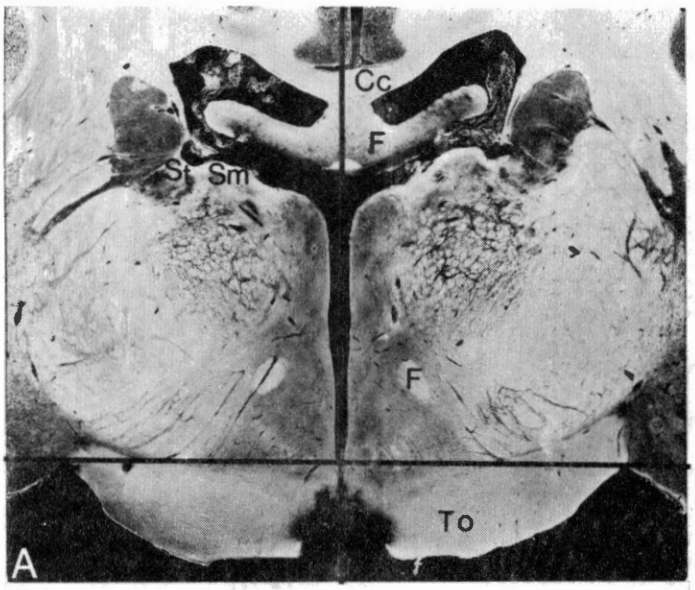

Corpus callosum
Fornix
Stria terminalis
Stria medullaris thalami

Fornix

Tractus opticus

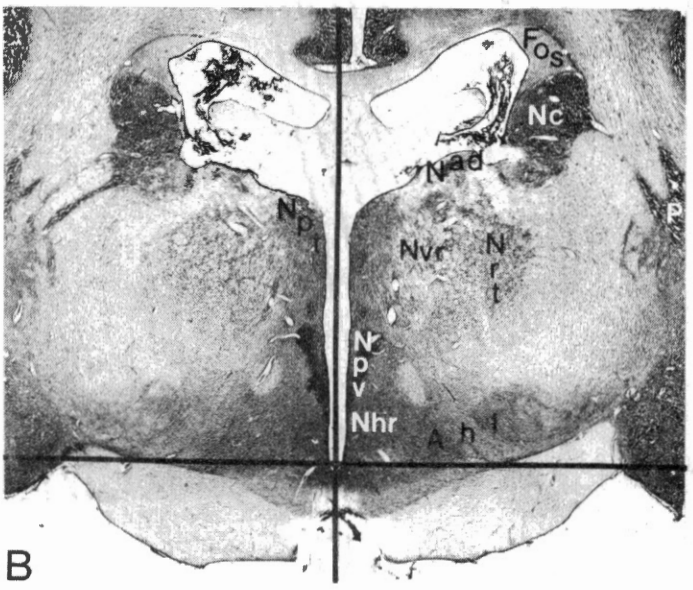

Fasciculus occipitoanterior superior
Nucleus caudatus

Nucleus anterior dorsalis
Putamen
Nucleus paraventricularis thalami
Nucleus ventralis rostralis
Nucleus reticularis thalami

Nucleus paraventricularis

Nucleus hypothalamicus rostralis
Area hypothalamica lateralis

Plate 11. Section at Frontal 28.3. A. Unstained section; B. Thionin stained section.

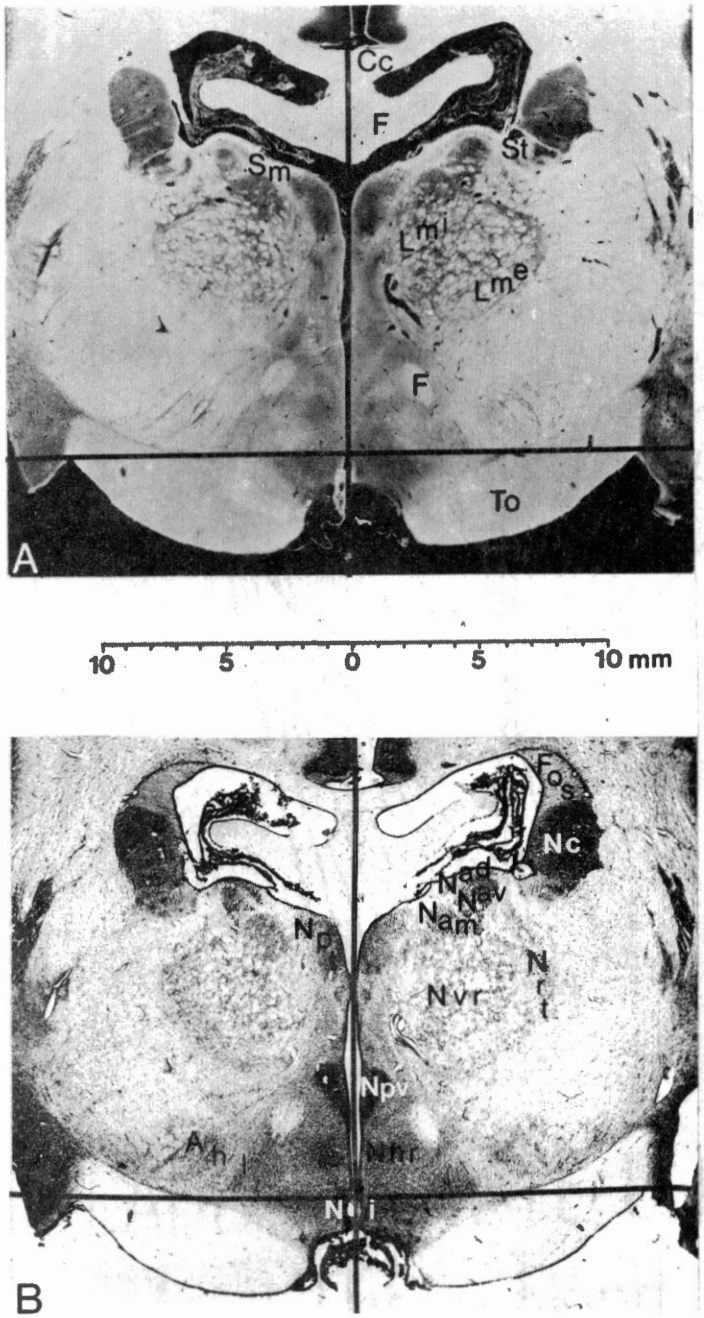

Corpus callosum

Fornix
Stria terminalis
Stria medullaris thalami
Lamina medullaris thalami interna
Lamina medullaris thalami externa

Fornix

Tractus opticus

Fasciculus occipitoanterior superior
Nucleus caudatus
Nucleus anterior dorsalis
Nucleus anterior ventralis
Nucleus anterior medialis
Nucleus paraventricularis thalami
Nucleus ventralis rostralis
Nucleus reticularis thalami

Nucleus paraventricularis

Nucleus hypothalamicus rostralis
Area hypothalamica lateralis
Nucleus infundibularis

Plate 12. Section at Frontal 27.7. A. Unstained section; B. Thionin stained section.

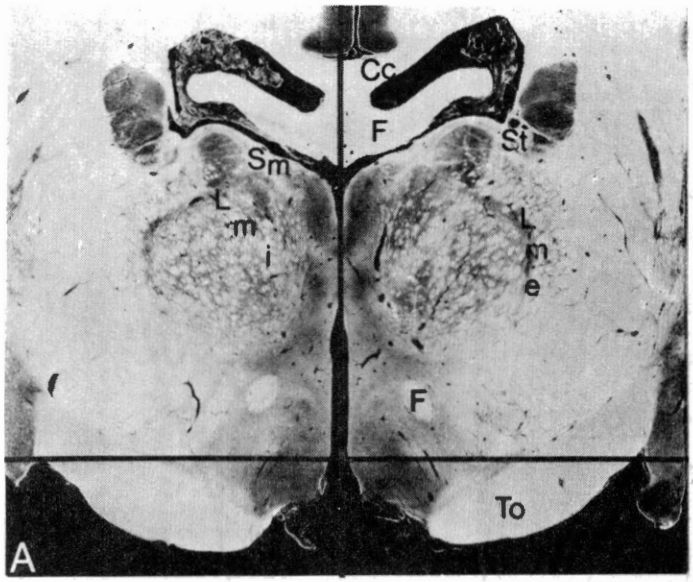

Corpus callosum
Fornix
Stria terminalis
Stria medullaris thalami
Lamina medullaris thalami interna
Lamina medullaris thalami externa

Fornix

Tractus opticus



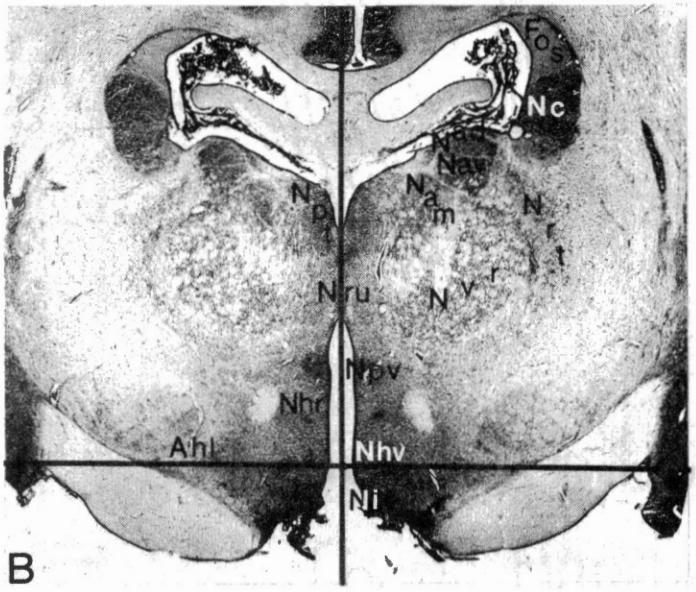

Fasciculus occipitoanterior superior
Nucleus caudatus
Nucleus anterior dorsalis
Nucleus anterior ventralis
Nucleus anterior medialis
Nucleus paraventricularis thalami
Nucleus reticularis thalami
Nucleus ventralis rostralis
Nucleus reuniens thalami

Nucleus paraventricularis
Nucleus hypothalamicus rostralis
Area hypothalamica lateralis
Nucleus hypothalamicus ventromedialis
Nucleus infundibularis

Plate 13. Section at Frontal 27.2. A. Unstained section; B. Thionin stained section.

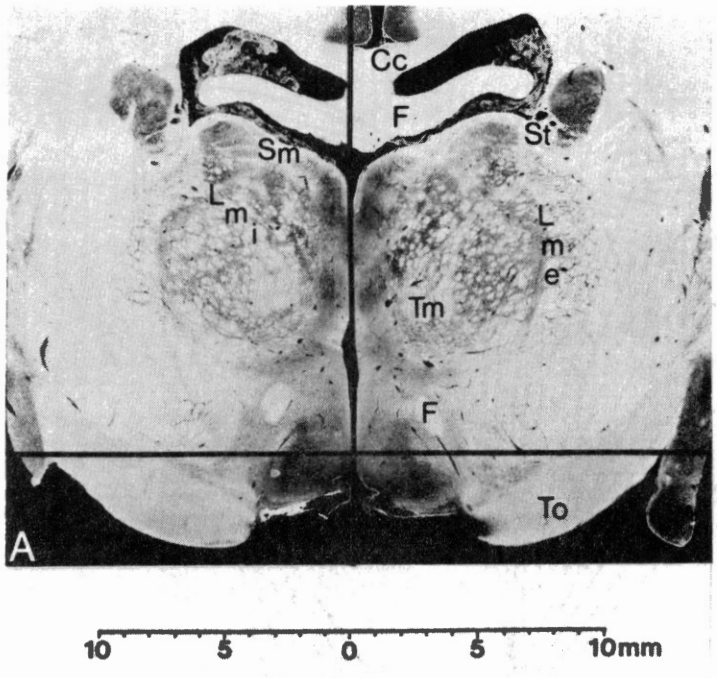

Corpus callosum
Fornix

Stria terminalis
Stria medullaris thalami
Lamina medullaris thalami interna
Lamina medullaris thalami externa
Tractus mamillothalamicus

Fornix

Tractus opticus

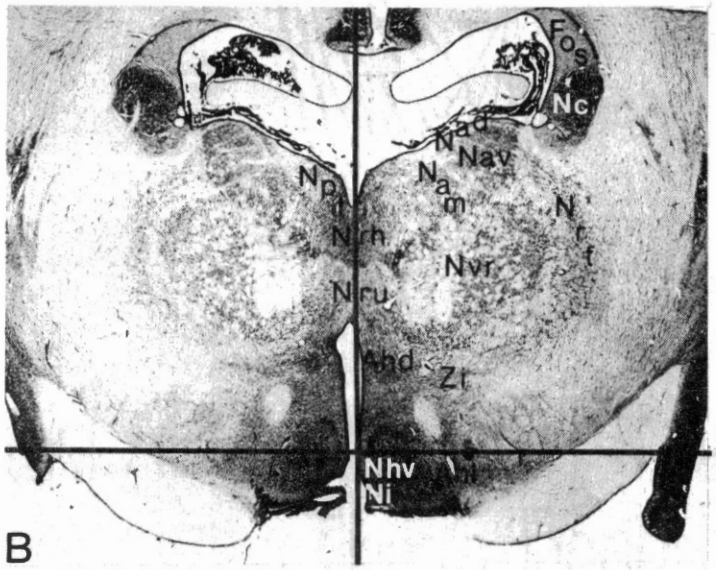

Fasciculus occipitoanterior superior
Nucleus caudatus
Nucleus anterior dorsalis
Nucleus anterior ventralis
Nucleus anterior medialis
Nucleus paraventricularis thalami
Nucleus rhomboideus thalami
Nucleus ventralis rostralis
Nucleus reticularis thalami
Nucleus reuniens thalami
Area hypothalamica dorsalis
Zona incerta
Nucleus hypothalamicus ventromedialis
Area hypothalamica lateralis
Nucleus infundibularis

Plate 14. Section at Frontal 26.7. A. Unstained section; B. Thionin stained section.

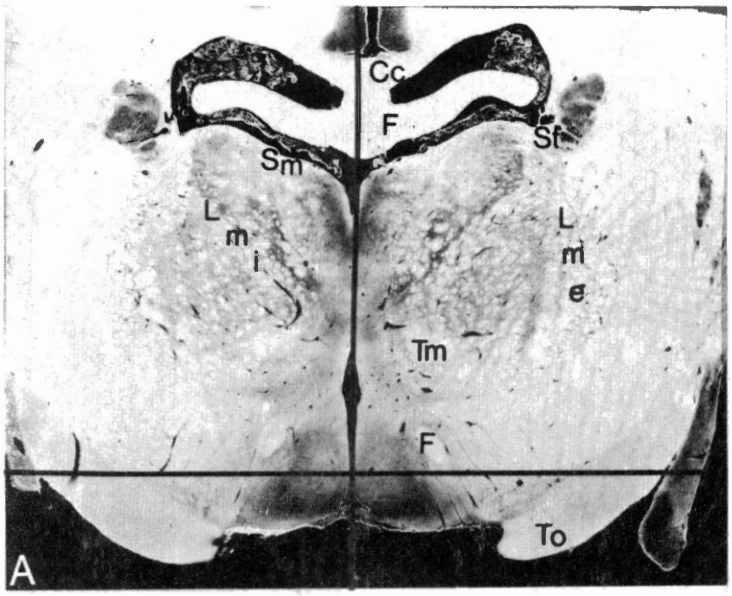

Corpus callosum
Fornix
Stria terminalis
Stria medullaris thalami

Lamina medullaris thalami interna
Lamina medullaris thalami externa

Tractus mamillothalamicus

Fornix

Tractus opticus



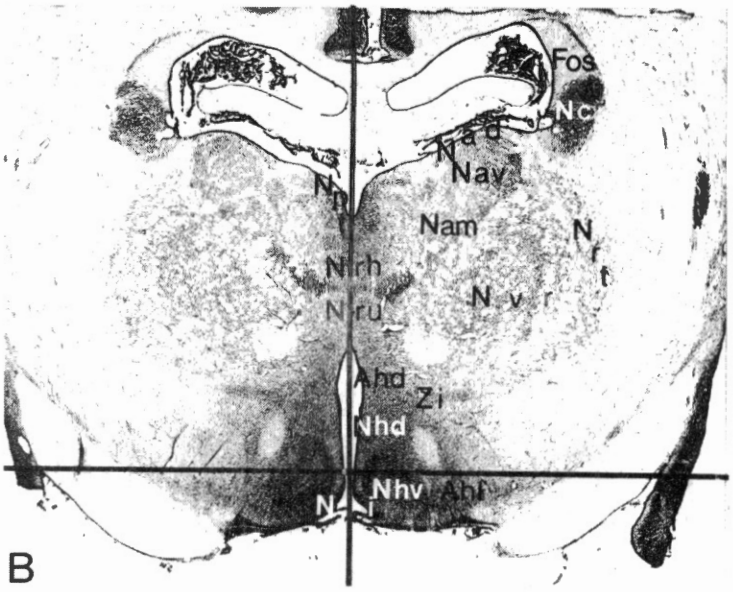

Fasciculus occipitoanterior superior
Nucleus caudatus
Nucleus anterior dorsalis
Nucleus anterior ventralis
Nucleus paraventricularis thalami
Nucleus anterior medialis
Nucleus rhomboideus thalami
Nucleus reticularis thalami
Nucleus ventralis rostralis
Nucleus reuniens thalami
Area hypothalamica dorsalis
Zona incerta
Nucleus hypothalamicus dorsomedialis
Nucleus hypothalamicus ventromedialis
Area hypothalamica lateralis
Nucleus infundibularis

Plate 15. Section at Frontal 26.1. A. Unstained section; B. Thionin stained section.

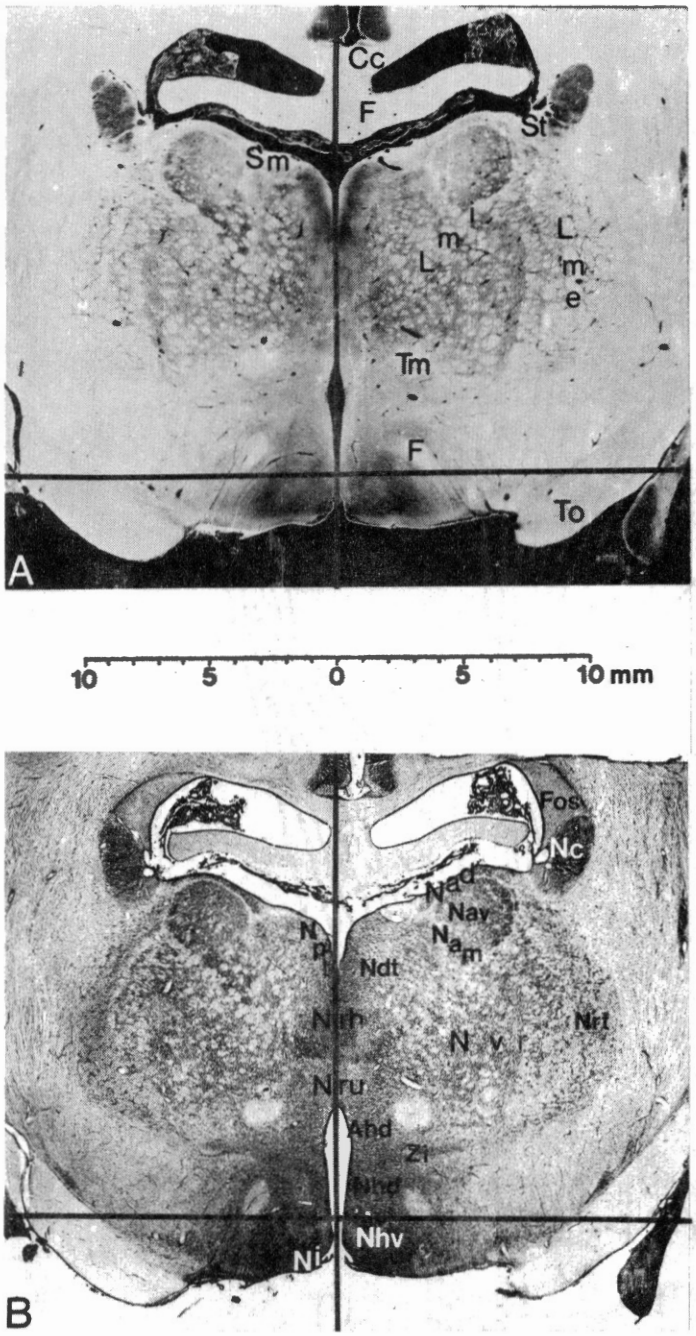

Corpus callosum
Fornix
Stria terminalis
Stria medullaris thalami

Lamina medullaris thalami interna
Lamina medullaris thalami externa

Tractus Mamillothalamicus

Fornix

Tractus opticus

Fasciculus occipitoanterior superior
Nucleus caudatus
Nucleus anterior dorsalis
Nucleus anterior ventralis
Nucleus paraventricularis thalami
Nucleus anterior medialis
Nucleus dorsomedialis thalami
Nucleus rhomboideus thalami
Nucleus reticularis thalami
Nucleus ventralis rostralis
Nucleus reuniens thalami
Area hypothalamica dorsalis
Zona incerta
Nucleus hypothalamicus dorsomedialis
Area hypothalamica lateralis
Nucleus hypothalamicus ventromedialis
Nucleus infundibularis

Plate 16. Section at Frontal 25.6. A. Unstained section; B. Thionin stained section.

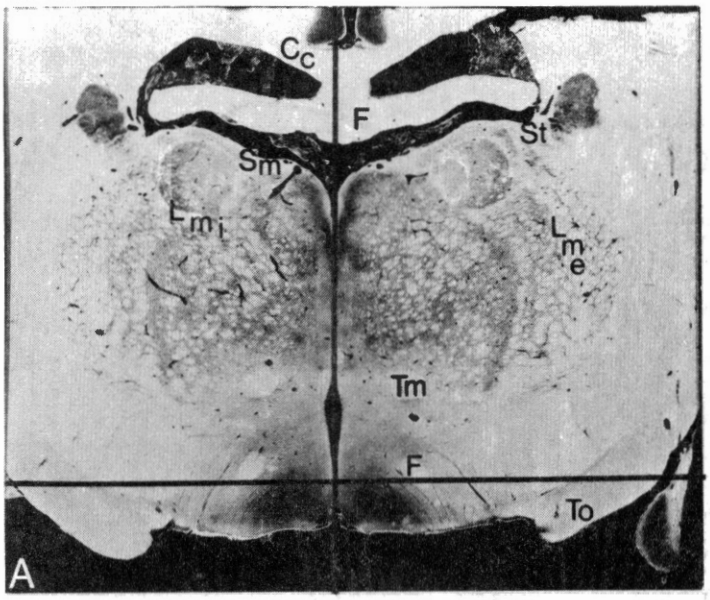

Corpus callosum

Fornix
Stria terminalis
Stria medullaris thalami
Lamina medullaris thalami interna
Lamina medullaris thalami externa

Tractus mamillothalamicus

Fornix
Tractus opticus

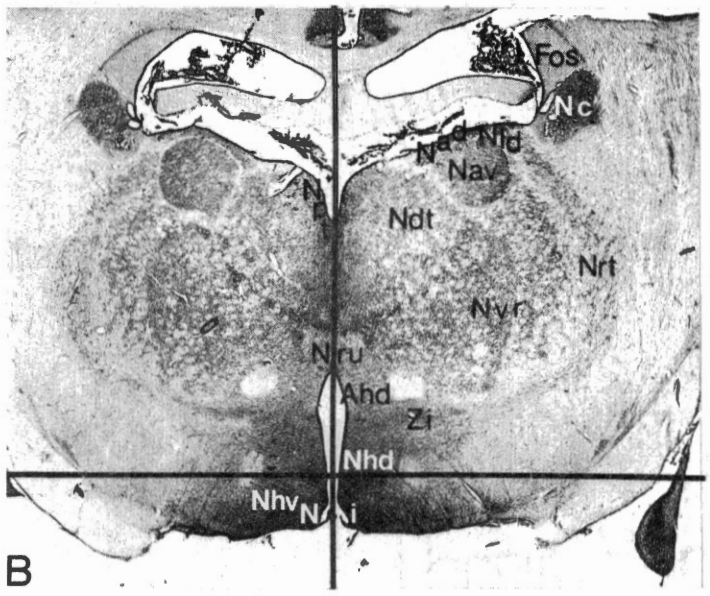

Fasciculus occipitoanterior superior
Nucleus caudatus
Nucleus anterior dorsalis
Nucleus lateralis dorsalis
Nucleus anterior ventralis
Nucleus paraventricularis thalami
Nucleus dorsomedialis thalami
Nucleus ventralis rostralis
Nucleus reticularis thalami
Nucleus reuniens thalami
Area hypothalamica dorsalis
Zona incerta
Nucleus hypothalamicus dorsomedialis
Nucleus hypothalamicus ventromedialis
Nucleus infundibularis

Plate 17. Section at Frontal 25.1. A. Unstained section; B. Thionin stained section.

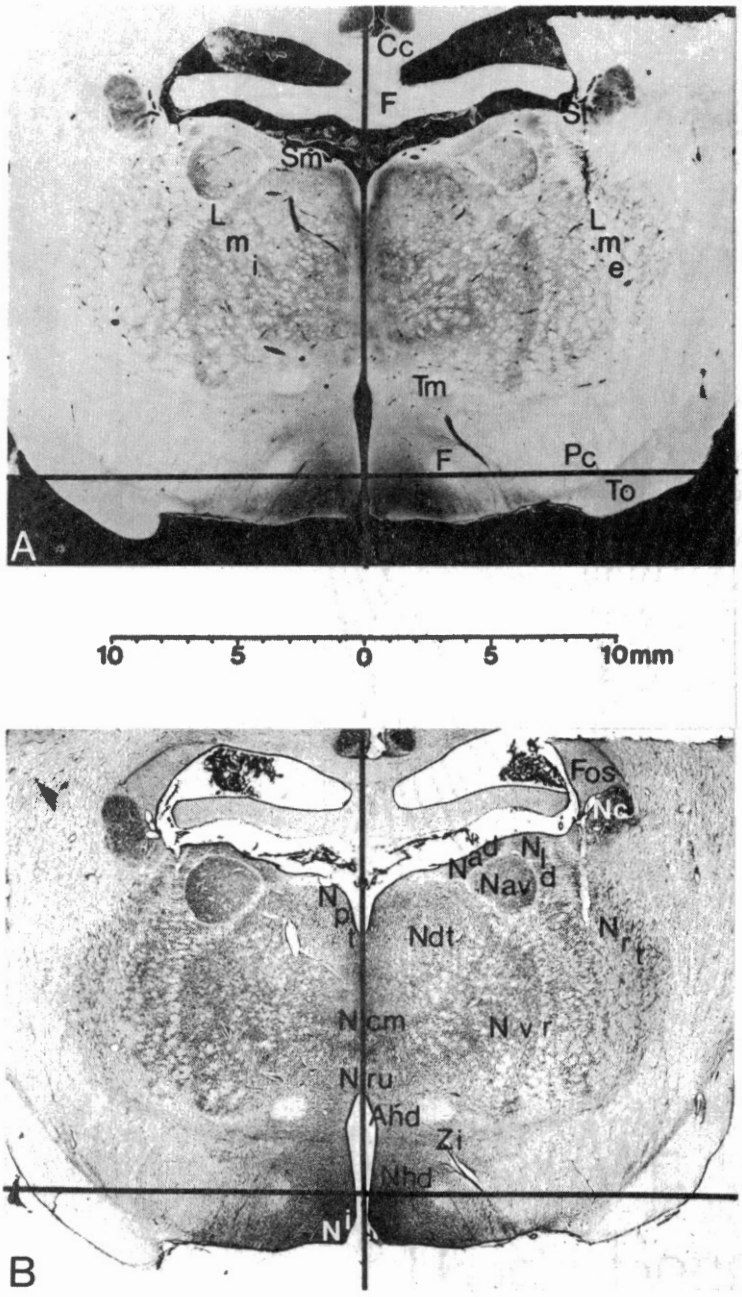

Corpus callosum

Fornix
Stria terminalis
Stria medullaris thalami
Lamina medullaris thalami interna
Lamina medullaris thalami externa

Tractus mamillothalamicus

Fornix
Pedunculus cerebri
Tractus opticus

Fasciculus occipitoanterior superior
Nucleus caudatus
Nucleus anterior dorsalis
Nucleus lateralis dorsalis
Nucleus anterior ventralis
Nucleus paraventricularis thalami
Nucleus dorsomedialis thalami
Nucleus reticularis thalami
Nucleus ventralis rostralis
Nucleus centralis medialis
Nucleus reuniens thalami
Area hypothalamica dorsalis
Zona incerta
Nucleus hypothalamicus dorsomedialis
Nucleus infundibularis

Plate 18. Section at Frontal 24.5. A. Unstained section; B. Thionin stained section.

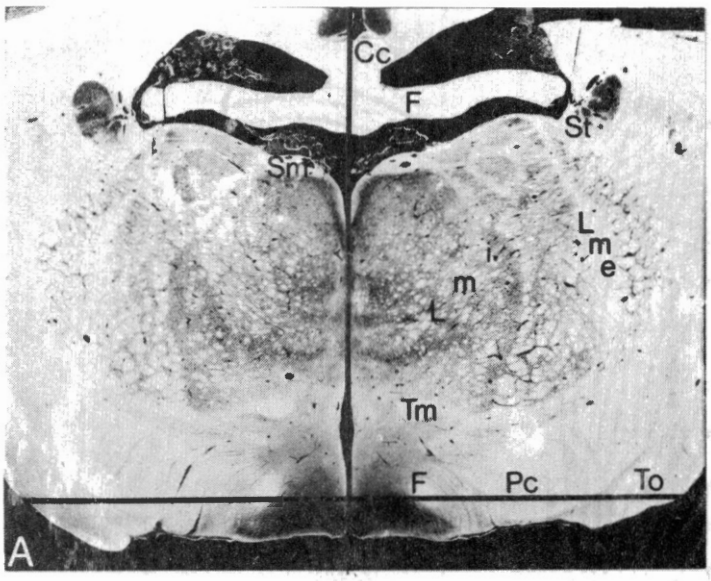

Corpus callosum

Fornix
Stria terminalis
Stria medullaris thalami
Lamina medullaris thalami interna
Lamina medullaris thalami externa

Tractus Mamillothalamicus

Fornix
Tractus opticus
Pedunculus cerebri

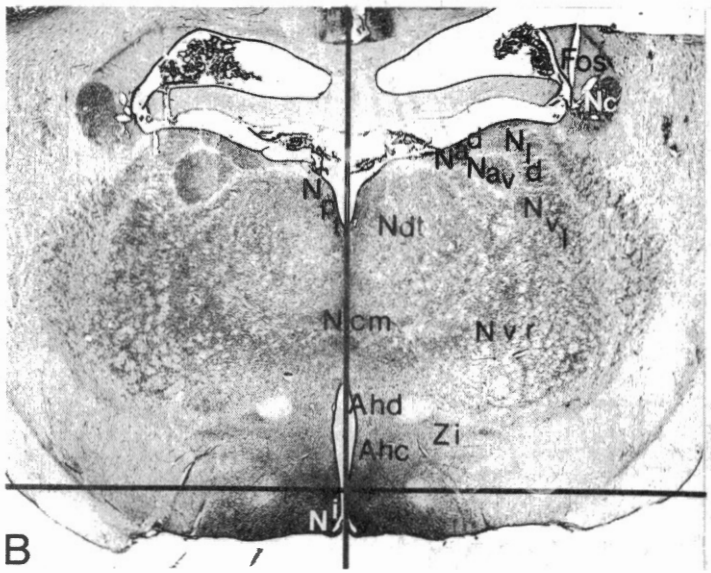

Fasciculus occipitoanterior superior
Nucleus caudatus
Nucleus anterior dorsalis
Nucleus lateralis dorsalis
Nucleus anterior ventralis
Nucleus ventralis lateralis

Nucleus dorsomedialis thalami
Nucleus paraventricularis thalami
Nucleus ventralis rostralis

Nucleus centralis medialis
Area hypothalamica dorsalis
Zona incerta
Area hypothalamica caudalis
Nucleus Infundibularis

Plate 19. Section at Frontal 24.0. A. Unstained section; B. Thionin stained section.

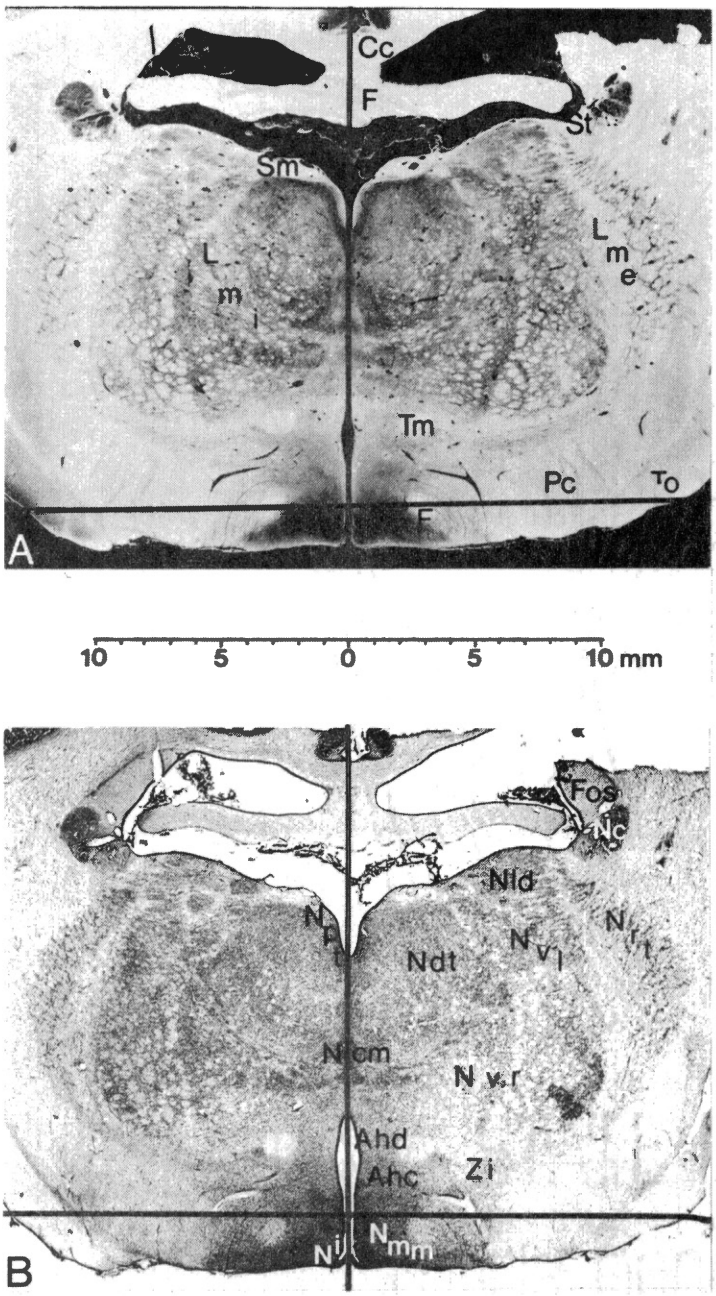

Corpus callosum

Fornix
Stria terminalis
Stria medullaris thalami
Lamina medullaris thalami interna
Lamina medullaris thalami externa

Tractus Mamillothalamicus

Tractus opticus
Fornix
Pedunculus cerebri

Fasciculus occipitoanterior superior
Nucleus caudatus
Nucleus lateralis dorsalis
Nucleus paraventricularis thalami
Nucleus reticularis thalami
Nucleus ventralis lateralis
Nucleus dorsomedialis thalami

Nucleus ventralis rostralis
Nucleus centralis medialis
Area hypothalamica dorsalis
Zona incerta
Area hypothalamica caudalis

Nucleus mamillaris medialis
Nucleus infundibularis

Plate 20. Section at Frontal 23.5. A. Unstained section; B. Thionin stained section.

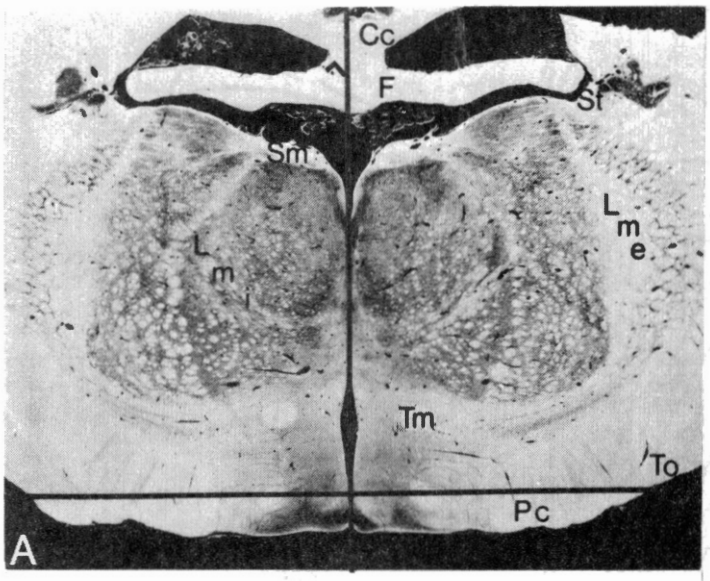

Corpus callosum

Fornix
Stria terminalis
Stria medullaris thalami

Lamina medullaris thalami interna
Lamina medullaris thalami externa

Tractus mamillothalamicus

Tractus opticus
Fornix
Pedunculus cerebri

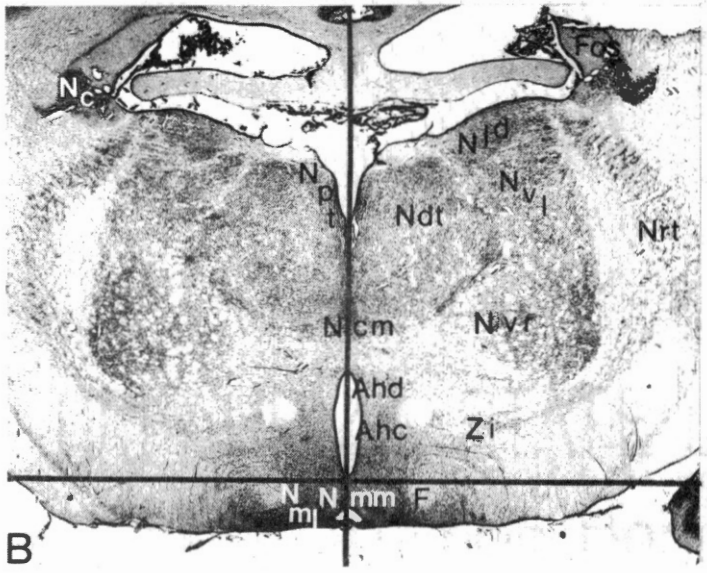

Fasciculus occipitoanterior superior
Nucleus caudatus
Nucleus lateralis dorsalis
Nucleus paraventricularis thalami
Nucleus ventralis lateralis
Nucleus dorsomedialis thalami

Nucleus reticularis thalami

Nucleus ventralis rostralis
Nucleus centralis medialis
Area hypothalamica dorsalis
Zona incerta
Area hypothalamica caudalis

Nucleus mamillaris medialis
Nucleus mamillaris lateralis

Plate 21. Section at Frontal 22.9. A. Unstained section; B. Thionin stained section.

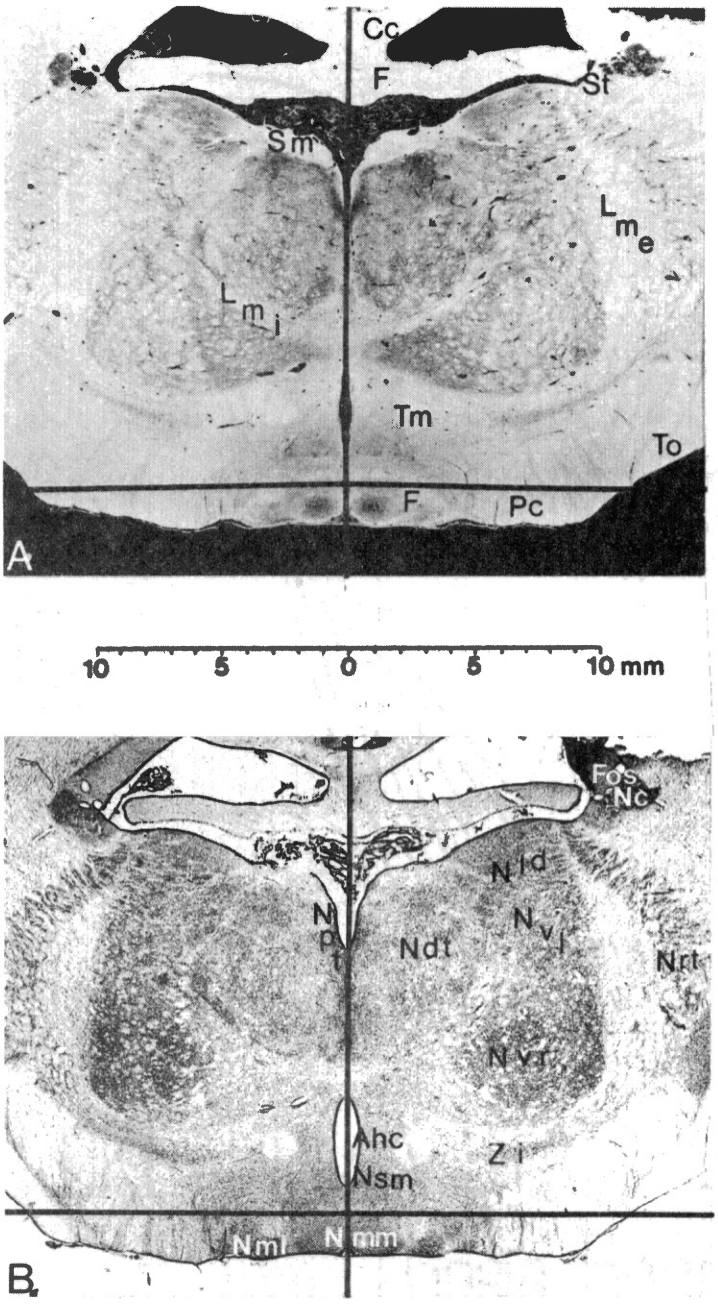

Corpus callosum

Fornix
Stria terminalis

Stria medullaris thalami

Lamina medullaris thalami interna
Lamina medullaris thalami externa

Tractus mamillothalamicus
Tractus opticus

Fornix
Pedunculus cerebri

Fasciculus occipitoanterior superior
Nucleus caudatus

Nucleus lateralis dorsalis
Nucleus paraventricularis thalami
Nucleus ventralis lateralis
Nucleus dorsomedialis thalami
Nucleus reticularis thalami
Nucleus ventralis rostralis

Area hypothalamica caudalis
Zona incerta
Nucleus supramamillaris
Nucleus mamillaris medialis
Nucleus mamillaris lateralis

Plate 22. Section at Frontal 22.4. A. Unstained section; B. Thionin stained section.

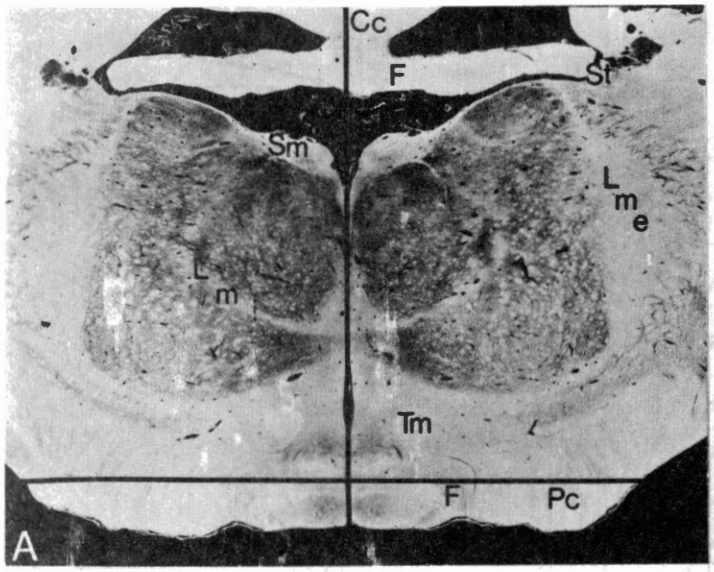

Corpus callosum

Fornix
Stria terminalis
Stria medullaris thalami
Lamina medullaris thalami externa

Lamina medullaris thalami interna

Tractus mamillothalamicus

Fornix
Pedunculus cerebri



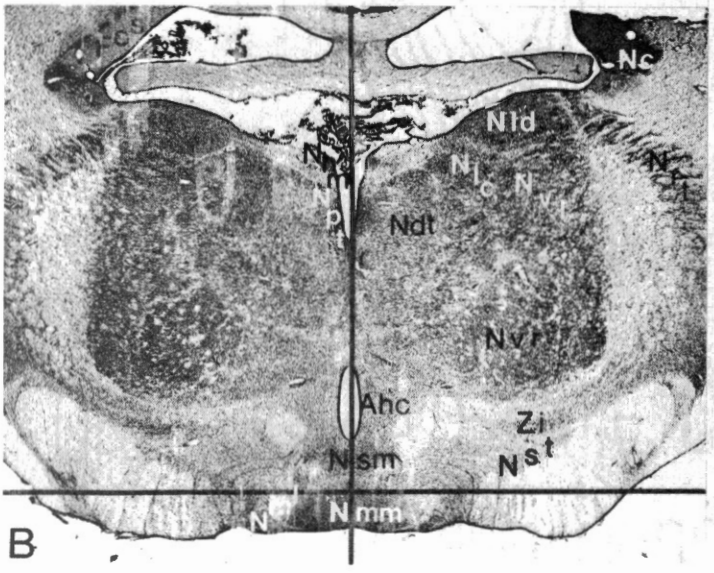

Fasciculus occipitoanterior superior
Nucleus caudatus
Nucleus lateralis dorsalis
Nucleus habenularis medialis
Nucleus lateralis caudalis
Nucleus reticularis thalami
Nucleus ventralis lateralis
Nucleus paraventricularis thalami
Nucleus dorsomedialis thalami

Nucleus ventralis rostralis
Area hypothalamica caudalis
Zona incerta
Nucleus supramamillaris
Nucleus subthalamicum
Nucleus mamillaris medialis
Nucleus mamillaris lateralis

Plate 23. Section at Frontal 21.9. A. Unstained section; B. Thionin stained section.

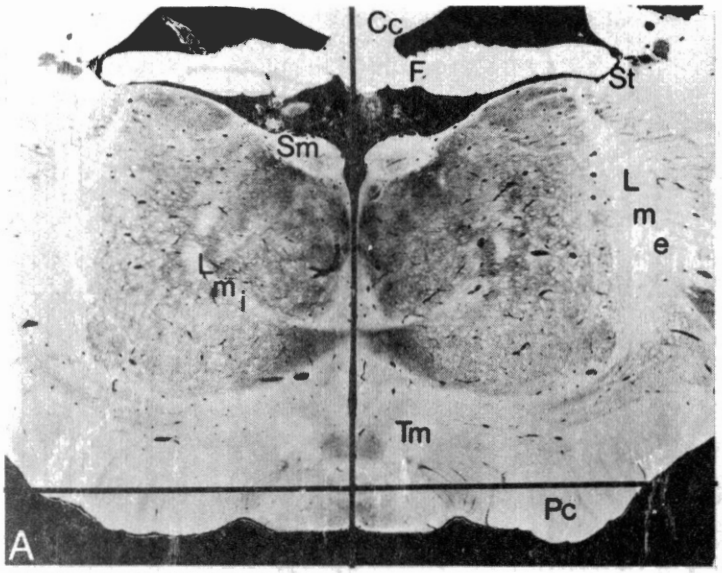

Corpus callosum
Fornix
Stria terminalis

Stria medullaris thalami

Lamina medullaris thalami interna
Lamina medullaris thalami externa

Tractus mamillothalamicus

Pedunculus cerebri



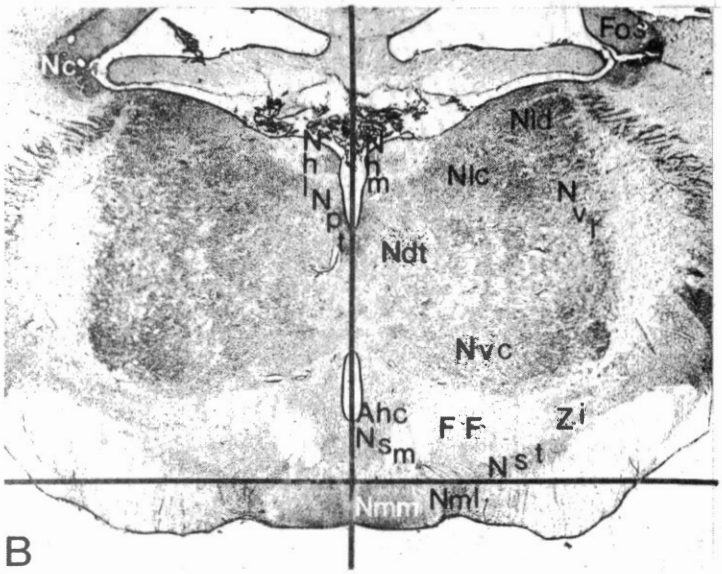

Fasciculus occipitoanterior superior
Nucleus caudatus
Nucleus lateralis dorsalis
Nucleus habenularis medialis
Nucleus habenularis lateralis
Nucleus lateralis caudalis
Nucleus ventralis lateralis
Nucleus dorsomedialis thalami
Nucleus paraventricularis thalami
Nucleus ventralis caudalis
Area hypothalamica caudalis
Fields of Forel
Zona incerta
Nucleus supramamillaris
Nucleus subthalamicum
Nucleus mamillaris medialis
Nucleus mamillaris lateralis

Plate 24. Section at Frontal 21.3. A. Unstained section; B. Thionin stained section.

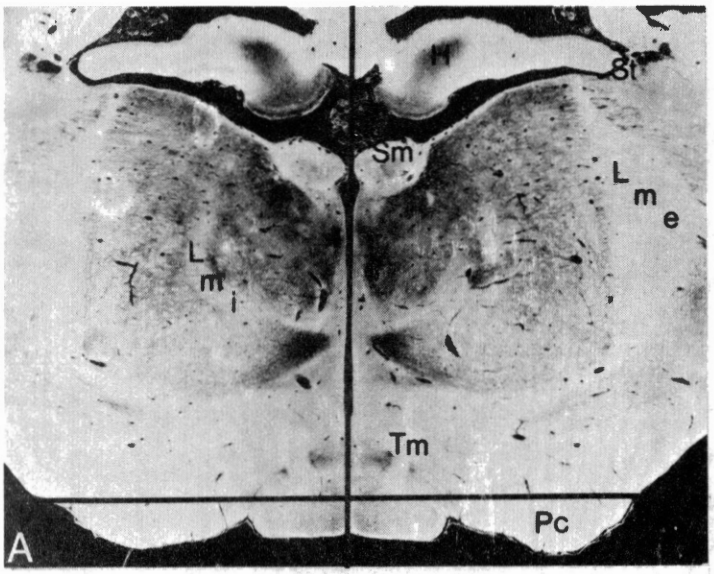

Hippocampus
Stria terminalis

Stria medullaris thalami

Lamina medullaris thalami interna
Lamina medullaris thalami externa

Tractus mamillothalamicus

Pedunculus cerebri

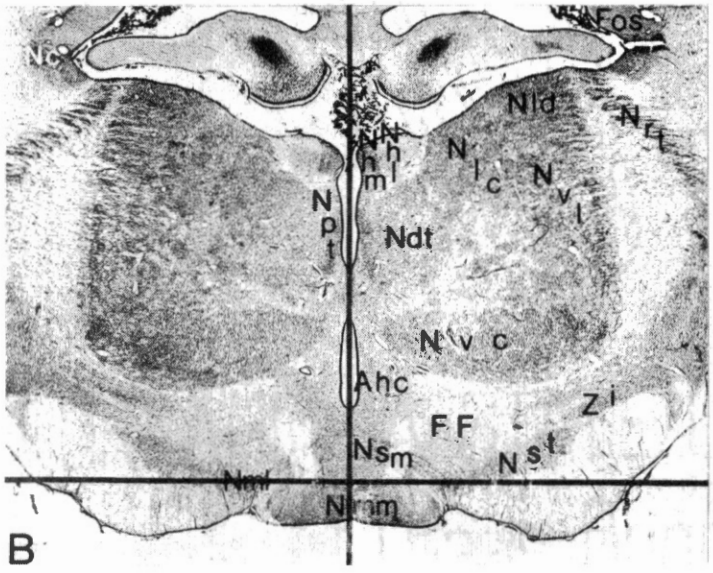

Fasciculus occipitoanterior superior
Nucleus caudatus
Nucleus lateralis dorsalis
Nucleus habenularis medialis
Nucleus habenularis lateralis
Nucleus reticularis thalami
Nucleus lateralis caudalis
Nucleus ventralis lateralis
Nucleus dorsomedialis thalami
Nucleus paraventricularis thalami
Nucleus ventralis caudalis
Area hypothalamica caudalis
Zona incerta
Fields of Forel
Nucleus supramamillaris
Nucleus subthalamicum
Nucleus mamillaris medialis
Nucleus mamillaris lateralis

Plate 25. Section at Frontal 20.8. A. Unstained section; B. Thionin stained section.

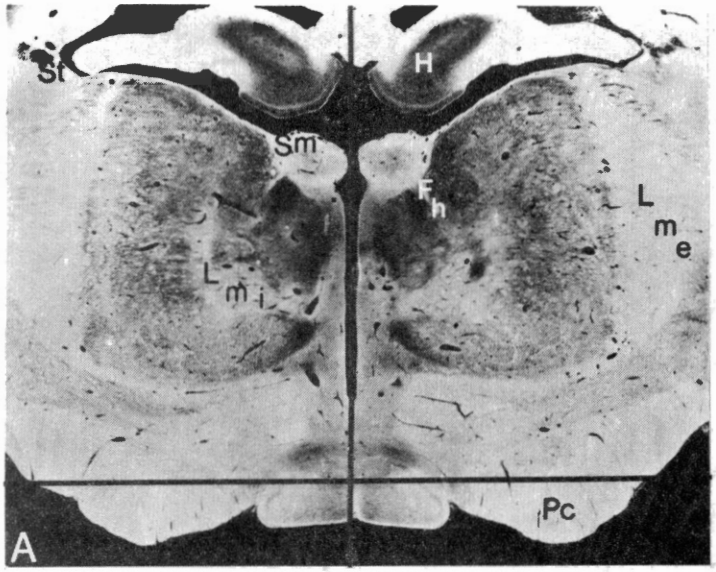

Hippocampus
Stria terminalis

Stria medullaris thalami

Fasciculus habenulointerpeduncularis

Lamina medullaris thalami interna
Lamina medullaris thalami externa

Pedunculus cerebri

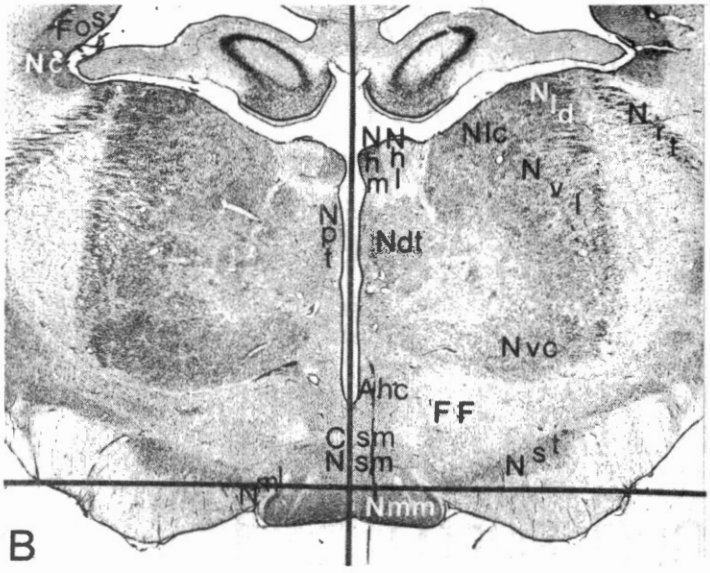

Fasciculus occipitoanterior superior
Nucleus caudatus
Nucleus lateralis dorsalis
Nucleus reticularis thalami
Nucleus habenularis medialis
Nucleus habenularis lateralis
Nucleus ventralis lateralis
Nucleus lateralis caudalis
Nucleus dorsomedialis thalami
Nucleus paraventricularis thalami
Nucleus ventralis caudalis
Area hypothalamica caudalis
Fields of Forel
Commissura supramamillaris
Nucleus supramamillaris
Nucleus subthalamicum
Nucleus mamillaris lateralis
Nucleus mamillaris medialis

Plate 26. Section at Frontal 20.3. A. Unstained section; B. Thionin stained section.

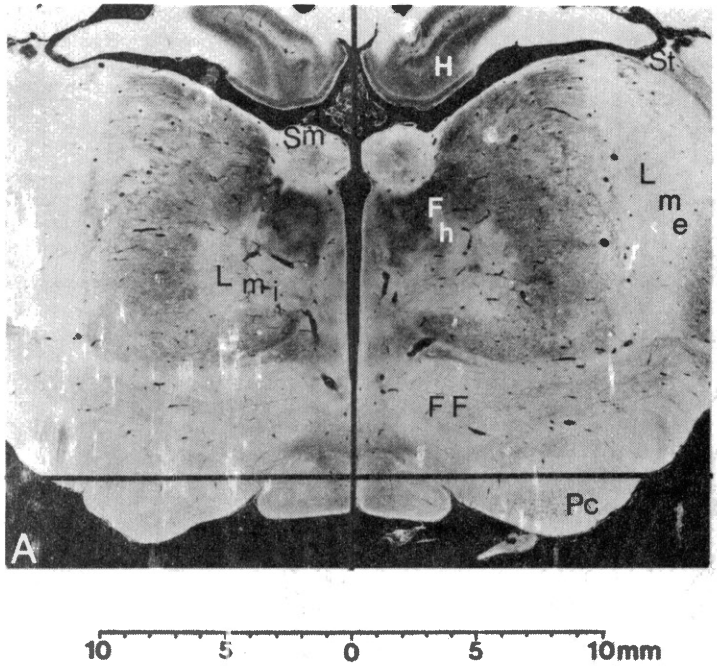

Hippocampus
Stria terminalis

Stria medullaris thalami

Fasciculus habenulointerpeduncularis
Lamina medullaris thalami interna
Lamina medullaris thalami externa
Fields of Forel

Pedunculus cerebri

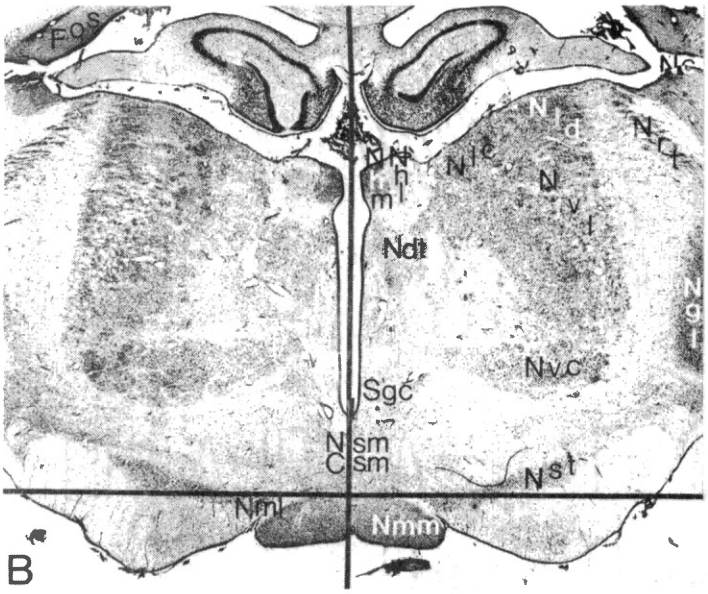

Fasciculus occipitoanterior superior
Nucleus caudatus
Nucleus reticularis thalami
Nucleus lateralis dorsalis
Nucleus habenularis medialis
Nucleus habenularis lateralis
Nucleus lateralis caudalis
Nucleus ventralis lateralis
Nucleus dorsomedialis thalami
Nucleus geniculatus lateralis
Nucleus ventralis caudalis
Substantia grisea centralis
Nucleus supramamillaris
Commissura supramamillaris
Nucleus subthalamicum
Nucleus mamillaris lateralis
Nucleus mamillaris medialis

Plate 27. Section at Frontal 19.7. A. Unstained section; B. Thionin stained section.

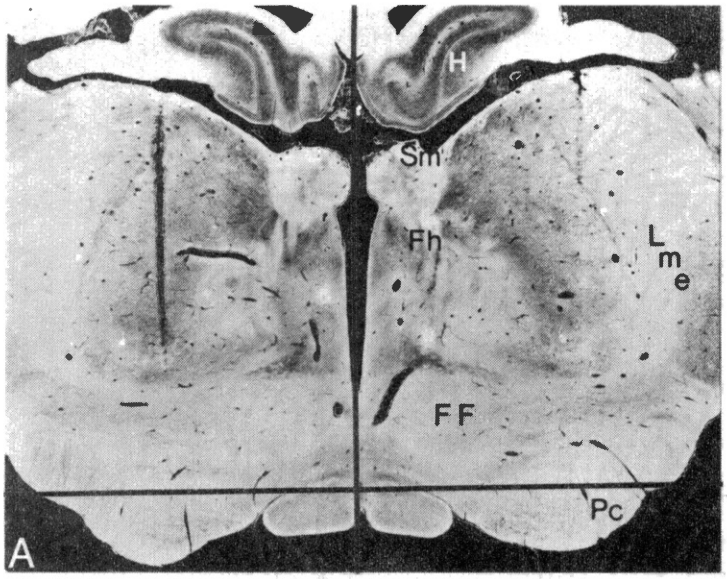

Hippocampus

Stria medullaris thalami

Fasciculus habenulointer-
peduncularis
Lamina medullaris thalami
externa

Fields of Forel

Pedunculus cerebri



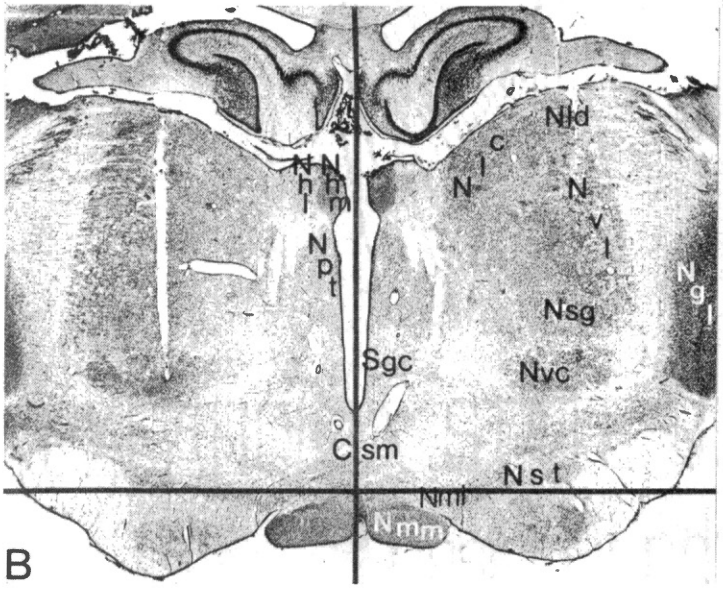

Nucleus lateralis dorsalis

Nucleus lateralis caudalis
Nucleus habenularis medialis
Nucleus habenularis lateralis
Nucleus ventralis lateralis
Nucleus paraventricularis
thalami
Nucleus supragenicularis
Nucleus geniculatus lateralis
Nucleus ventralis caudalis
Substantia grisea centralis

Commissura supramamillaris
Nucleus subthalamicum
Nucleus mamillaris lateralis
Nucleus mamillaris medialis

Plate 28. Section at Frontal 19.2. A. Unstained section;
B. Thionin stained section.

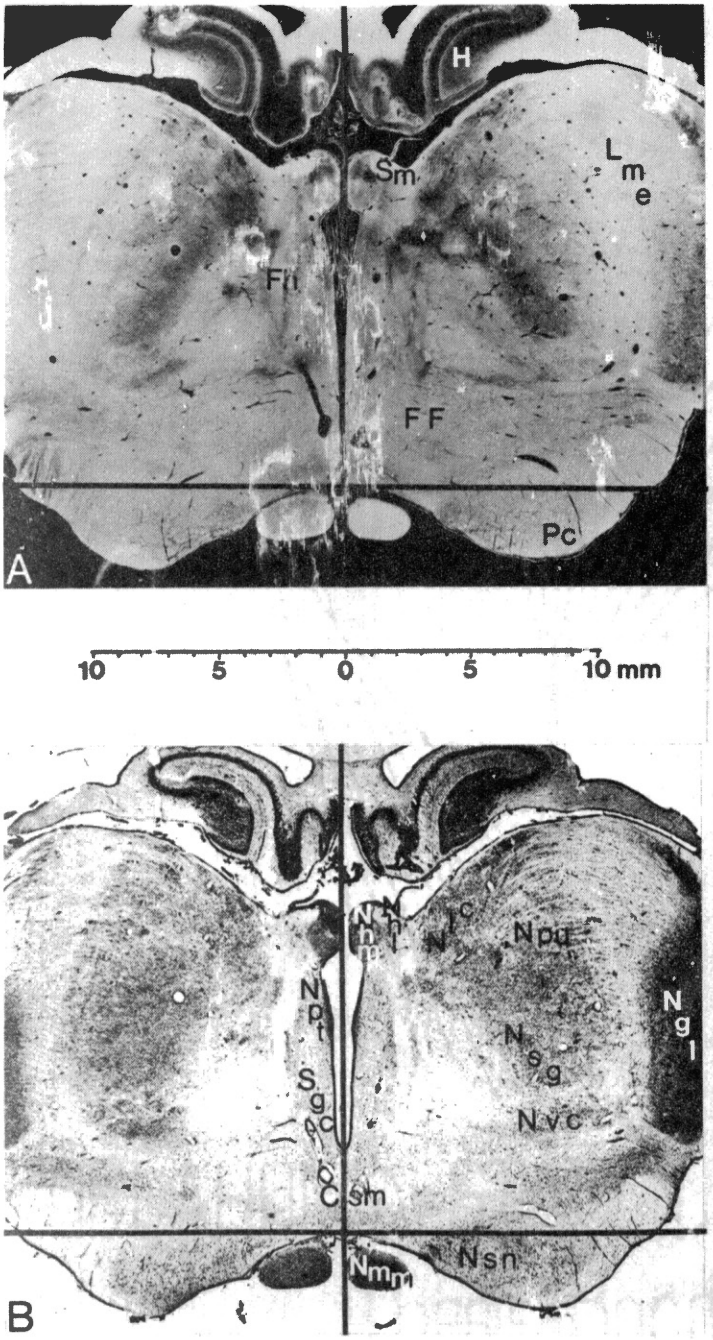

Hippocampus

Stria medullaris thalami

Lamina medullaris thalami externa
Fasciculus habenulointerpeduncularis

Fields of Forel

Pedunculus cerebri

Nucleus lateralis caudalis
Nucleus habenularis medialis
Nucleus habenularis lateralis
Nucleus pulvinaris
Nucleus suprageniculatus
Nucleus paraventricularis thalami
Nucleus geniculatus lateralis
Nucleus ventralis caudalis
Substantia grisea centralis

Commissura supramamillaris
Nucleus substantia nigra

Nucleus mamillaris medialis

Plate 29. Section at Frontal 18.6. A. Unstained section; B. Thionin stained section.

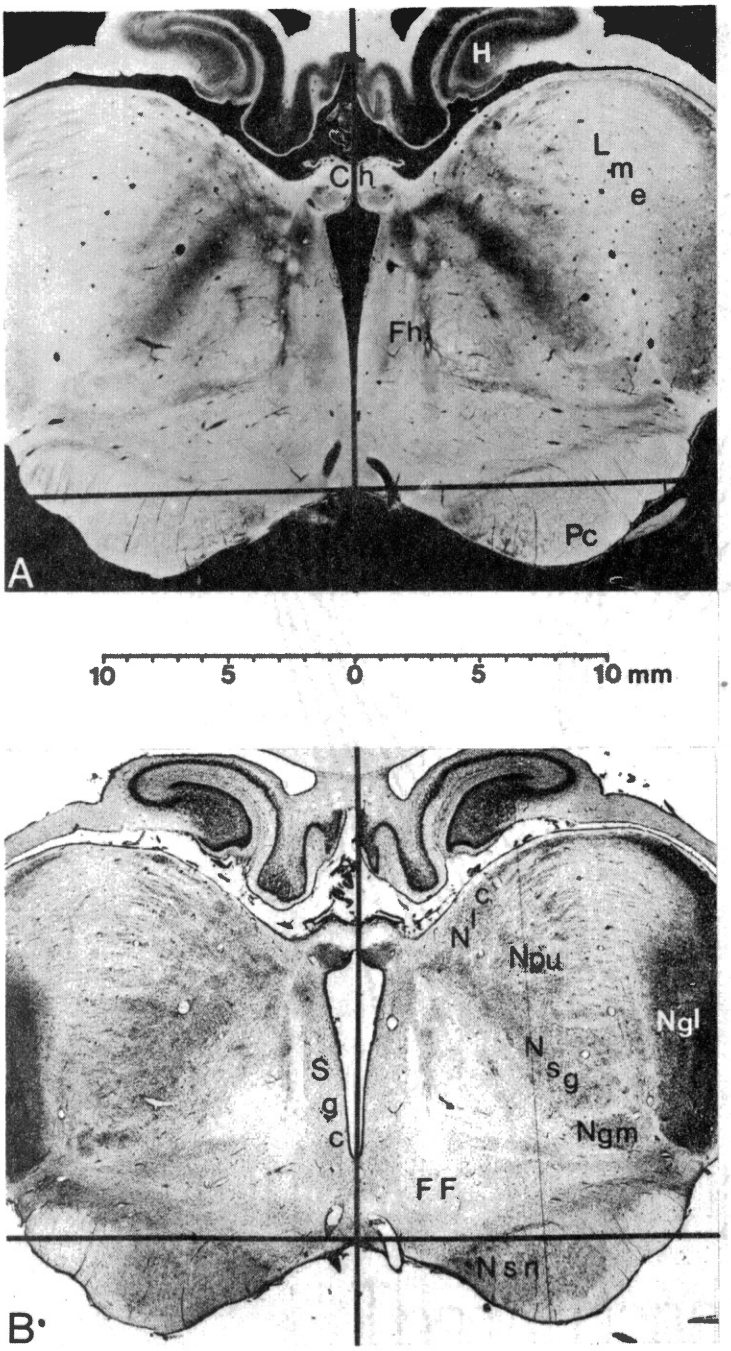

Hippocampus

Commissura habenularum
Lamina medullaris thalami externa

Fasciculus habenulointerpeduncularis

Pedunculus cerebri

Nucleus lateralis caudalis
Nucleus pulvinaris

Nucleus geniculatus lateralis

Nucleus supragenicularis
Substantia grisea centralis
Nucleus geniculatus medialis

Fields of Forel

Nucleus substantia nigra

Plate 30. Section at Frontal 18.1. A. Unstained section; B. Thionin stained section.

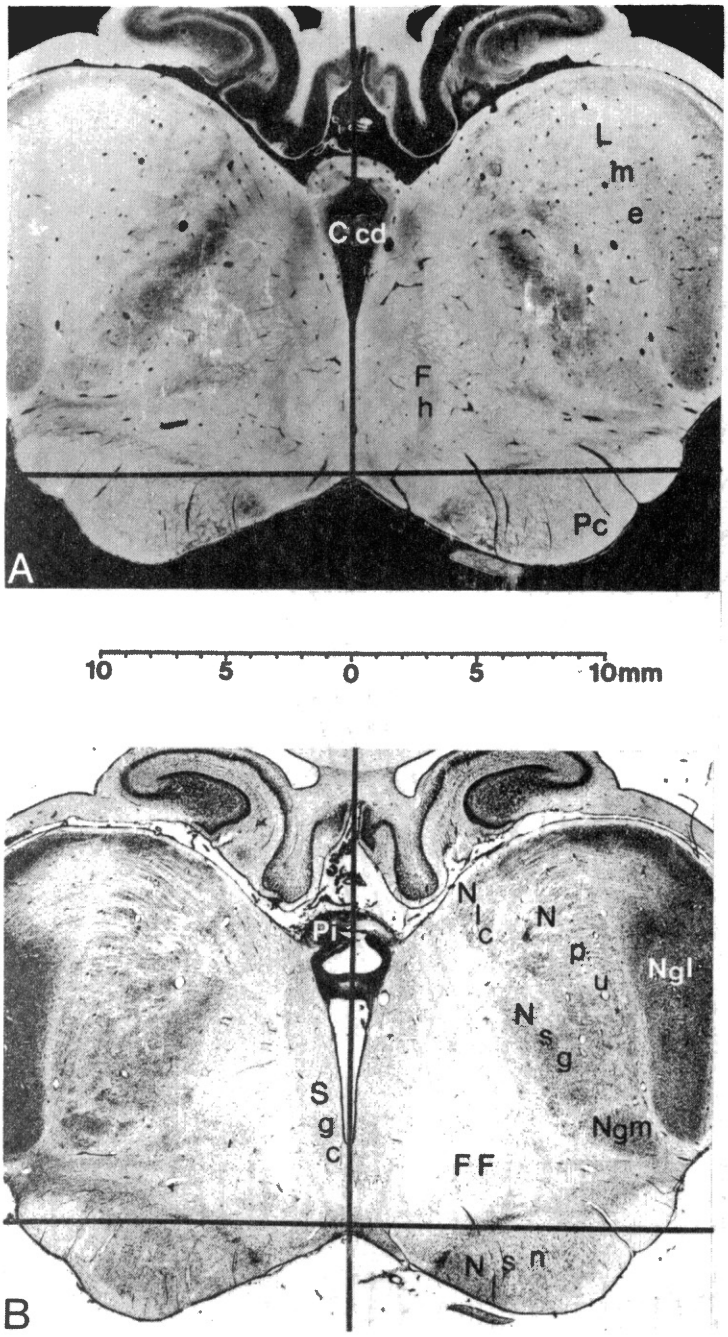

Hippocampus

Commissura caudalis
Lamina medullaris thalami externa

Fasciculus habenulointerpeduncularis

Pedunculus cerebri

Nucleus lateralis caudalis
Glandula pineale
Nucleus pulvinaris

Nucleus geniculatus lateralis
Nucleus supragenicularis
Substantia grisea centralis

Nucleus geniculatus medialis

Fields of Forel

Nucleus substantia nigra

Plate 31. Section at Frontal 17.6. A. Unstained section; B. Thionin stained section.

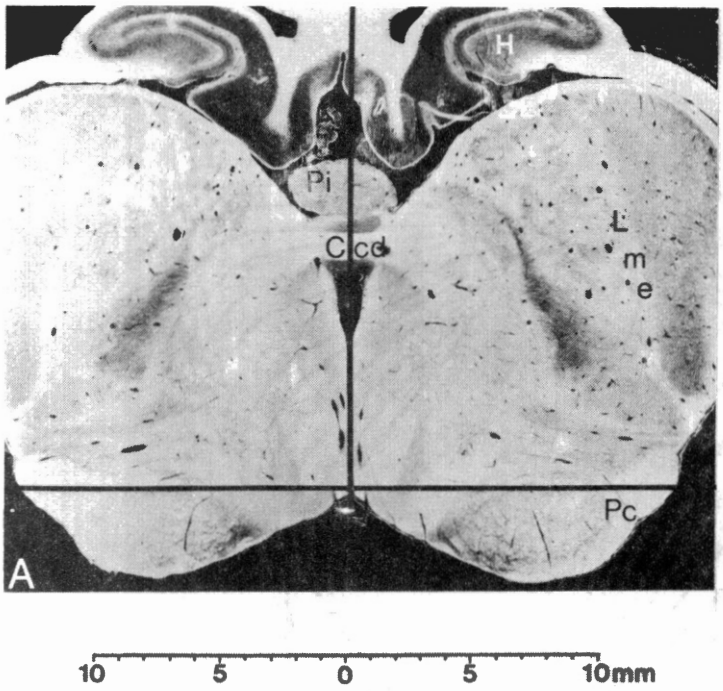

Hippocampus

Glandula pineale

Commissura caudalis
Lamina medullaris thalami externa

Pedunculus cerebri

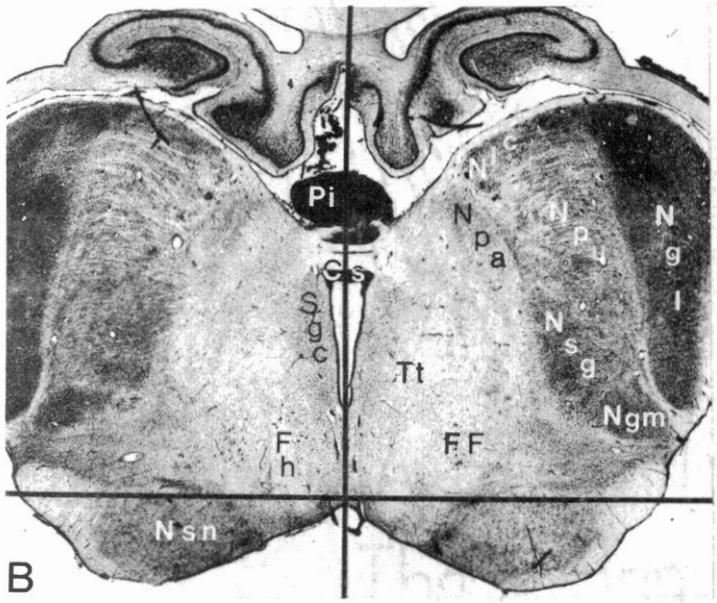

Nucleus lateralis caudalis
Glandula pineale
Nucleus pulvinaris
Nucleus pretectalis anterior
Corpus subcommissuralis
Nucleus geniculatus lateralis
Substantia grisea centralis
Tractus tegmenti centralis
Nucleus supragenicularis
Nucleus geniculatus medialis

Fields of Forel
Fasciculus habenulointerpeduncularis
Nucleus substantia nigra

Plate 32. Section at Frontal 17.0. A. Unstained section; B. Thionin stained section.

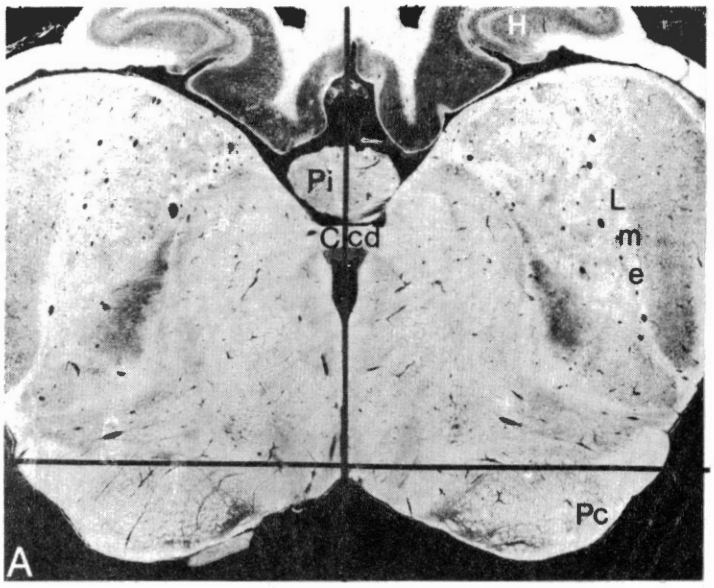

Hippocampus

Glandula pineale

Commissura caudalis
Lamina medullaris thalami externa

Pedunculus cerebri

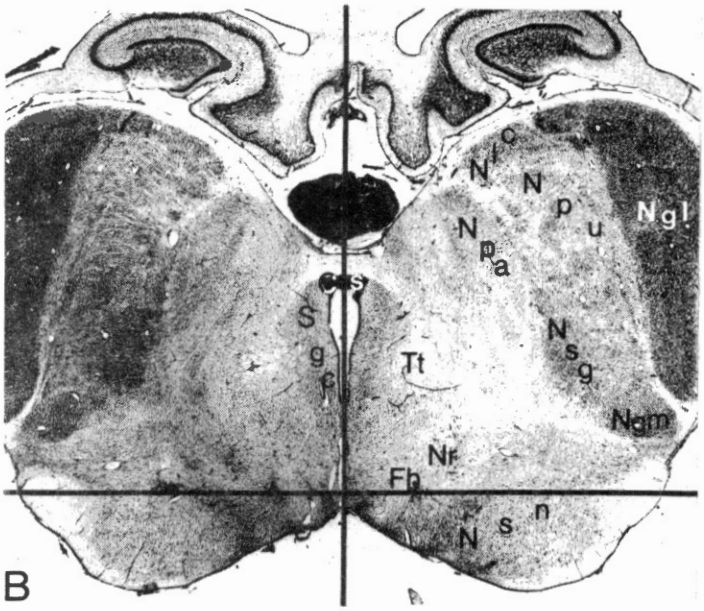

Nucleus lateralis caudalis

Nucleus pulvinaris
Nucleus geniculatus lateralis
Nucleus pretectalis anterior
Corpus subcommissuralis
Substantia grisea centralis
Nucleus suprageniculatus
Tractus tegmenti centralis

Nucleus geniculatus medialis
Nucleus ruber
Fasciculus habenulointerpeduncularis
Nucleus substantia nigra

Plate 33. Section at Frontal 16.5. A. Unstained section; B. Thionin stained section.

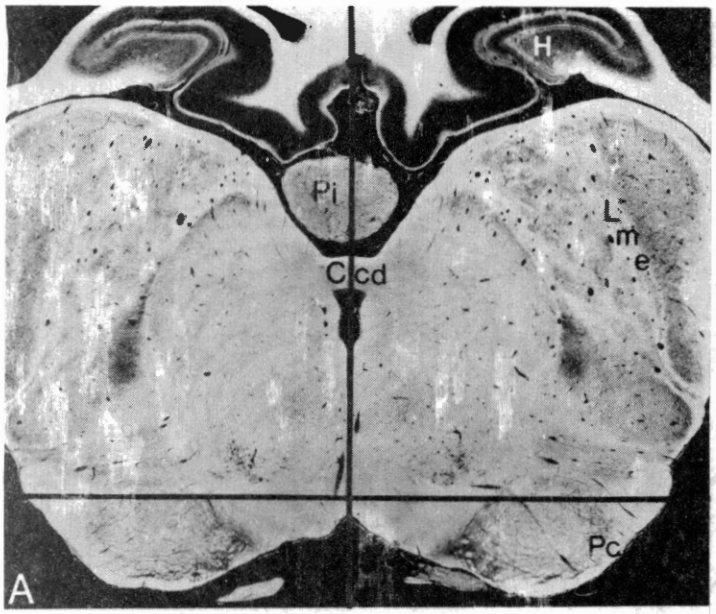

Hippocampus

Glandula pineale

Commissura caudalis
Lamina medullaris thalami
externa

Pedunculus cerebri

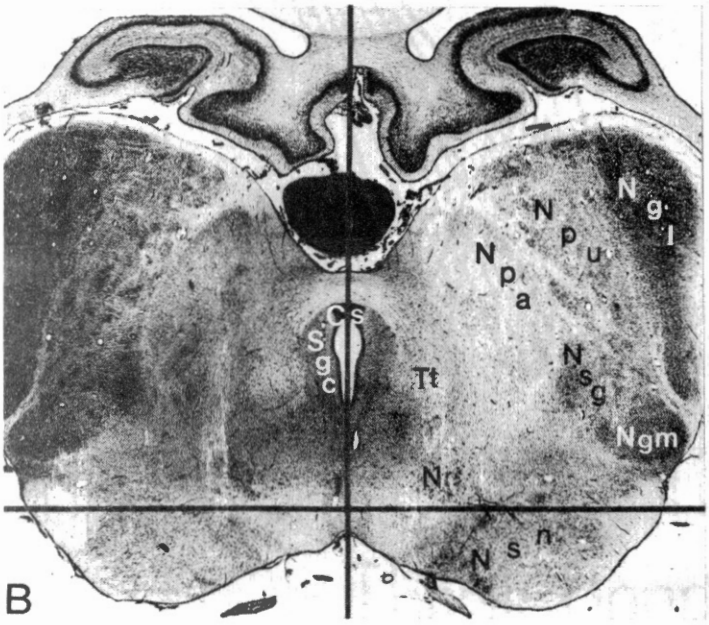

Nucleus pulvinaris
Nucleus geniculatus lateralis
Nucleus pretectalis anterior
Corpus subcommissuralis
Substantia grisea centralis
Tractus tegmenti centralis
Nucleus supragenicularis
Nucleus geniculatus medialis

Nucleus ruber

Nucleus substantia nigra

Plate 34. Section at Frontal 16.0. A. Unstained section; B. Thionin stained section.

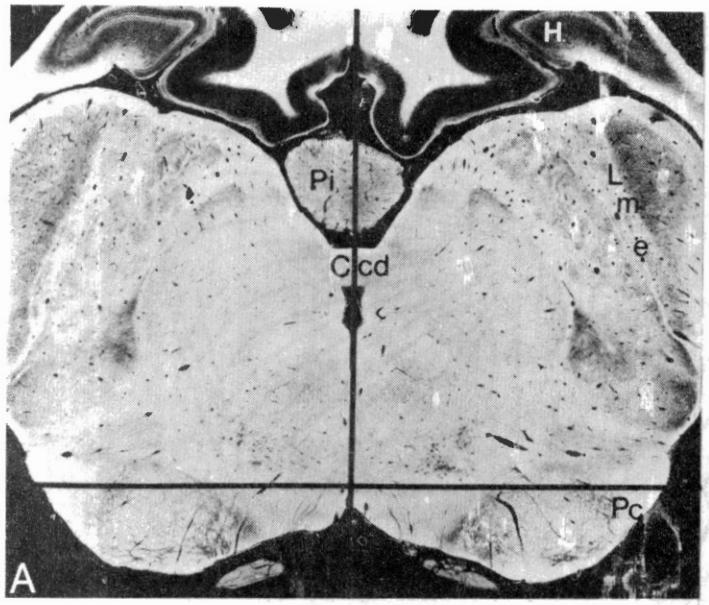

Hippocampus

Glandula pineale

Commissura caudalis
Lamina medullaris thalami externa

Pedunculus cerebri

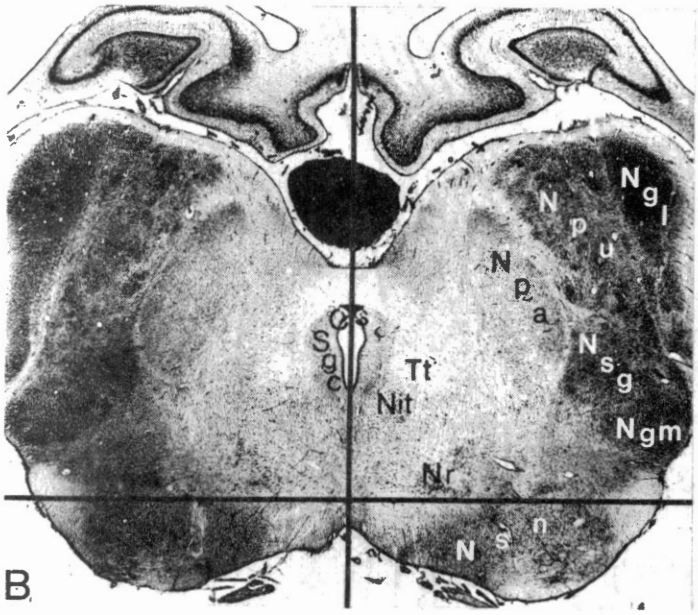

Nucleus pulvinaris
Nucleus geniculatus lateralis
Nucleus pretectalis anterior
Corpus subcommissuralis
Substantia grisea centralis
Nucleus supragenicularis
Tractus tegmenti centralis
Nucleus interstitialis
Nucleus geniculatus medialis

Nucleus ruber

Nucleus substantia nigra

Plate 35. Section at Frontal 15.4. A. Unstained section; B. Thionin stained section.

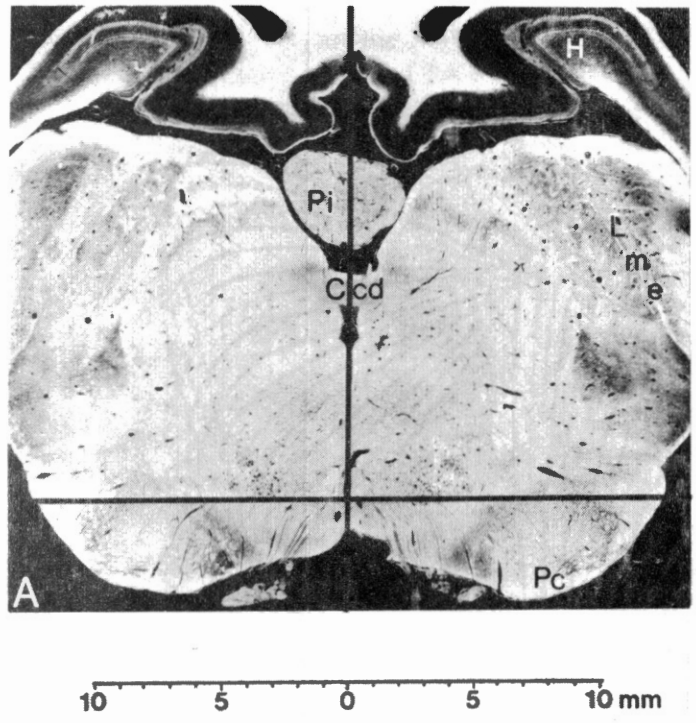

Hippocampus

Glandula pineale

Commissura caudalis
Lamina medullaris thalami externa

Pedunculus cerebri

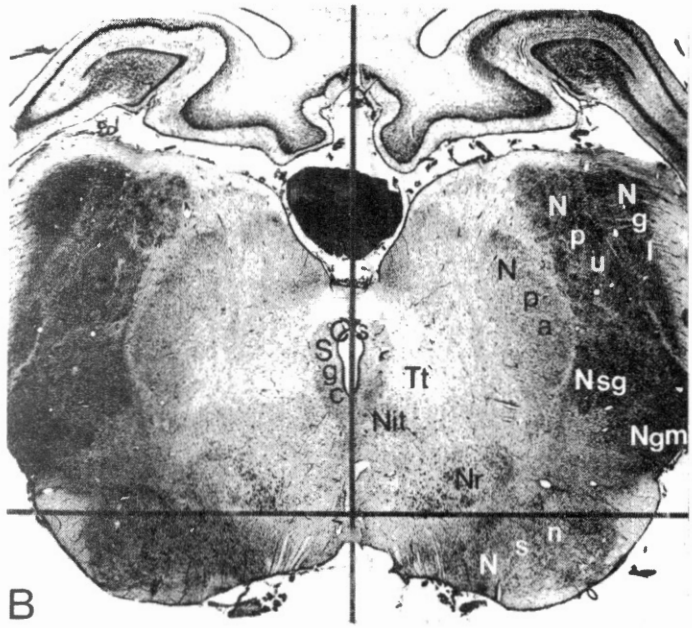

Nucleus geniculatus lateralis
Nucleus pulvinaris
Nucleus pretectalis anterior
Corpus subcommissuralis
Substantia grisea centralis
Nucleus supragenicularis
Tractus tegmenti centralis
Nucleus interstitialis
Nucleus geniculatus medialis
Nucleus ruber

Nucleus substantia nigra

Plate 36. Section at Frontal 14.9. A. Unstained section; B. Thionin stained section.

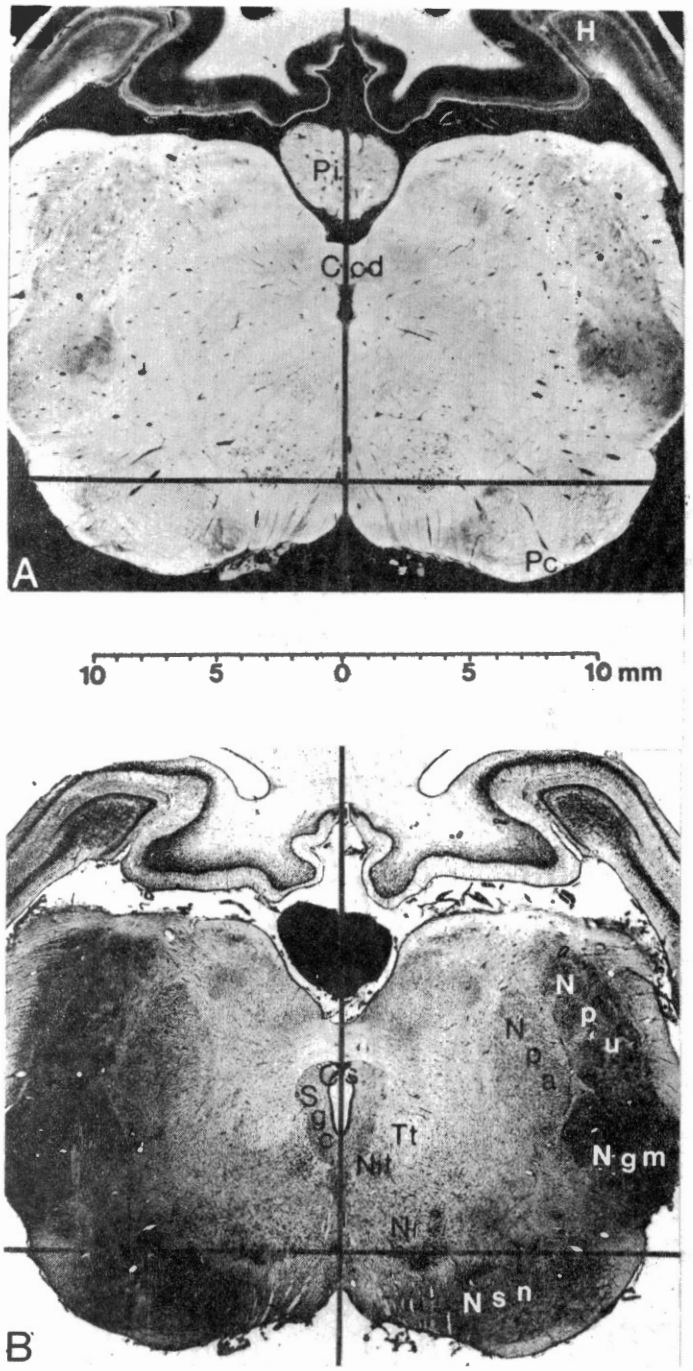

Hippocampus

Glandula pineale

Commissura caudalis

Pedunculus cerebri

Nucleus pulvinaris
Nucleus pretectalis anterior
Corpus subcommissuralis
Substantia grisea centralis
Tractus tegmenti centralis
Nucleus geniculatus medialis
Nucleus interstitialis

Nucleus ruber

Nucleus substantia nigra

Plate 37. Section at Frontal 14.4. A. Unstained section; B. Thionin stained section.

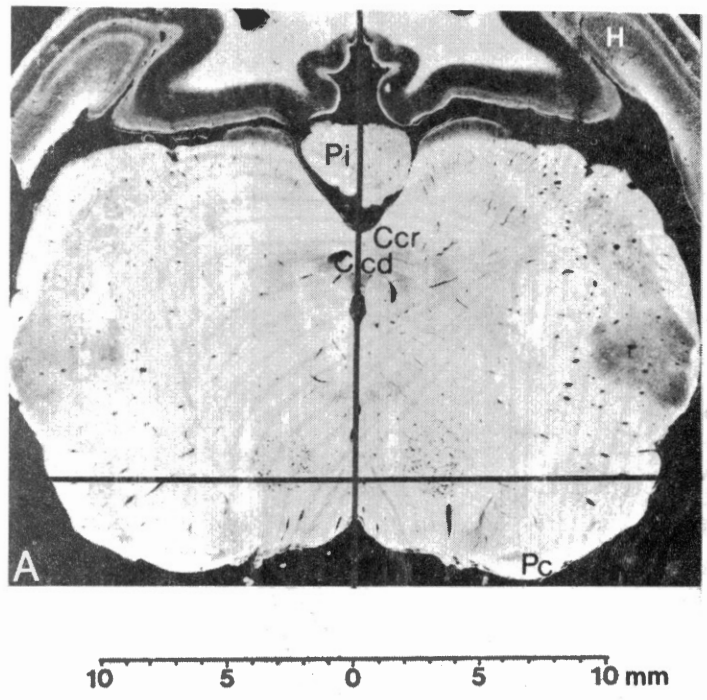

Hippocampus

Glandula pineale

Commissura colliculorum rostralis
Commissura caudalis

Pedunculus cerebri

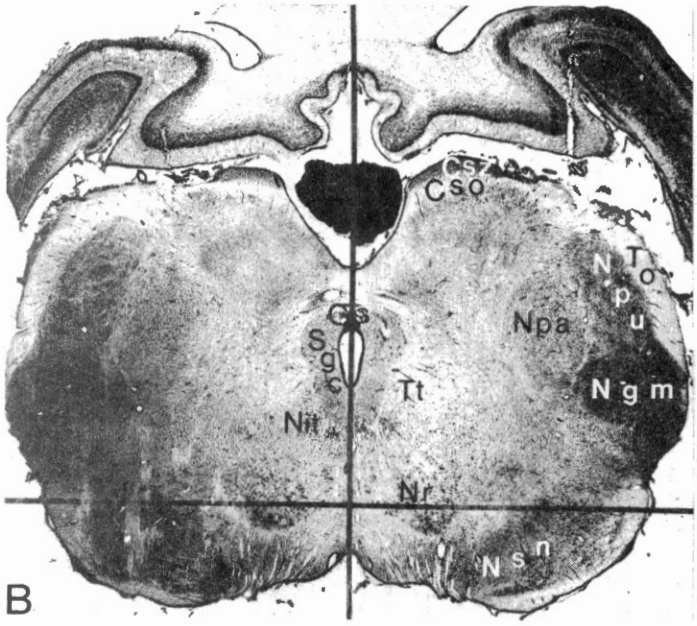

Colliculus rostralis stratum zonale
Colliculus rostralis stratum opticum
Tractus opticus
Nucleus pulvinaris
Nucleus pretectalis anterior
Corpus subcommissuralis
Substantia grisea centralis
Nucleus geniculatus medialis
Tractus tegmenti centralis
Nucleus interstitialis

Nucleus ruber

Nucleus substantia nigra

Plate 38. Section at Frontal 13.8. A. Unstained section; B. Thionin stained section.

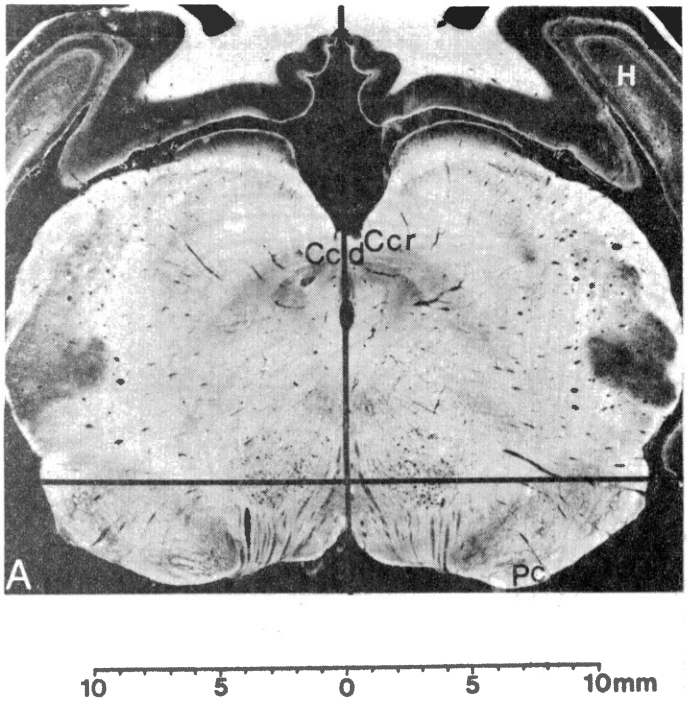

Hippocampus

Commissura colliculorum rostralis
Commissura caudalis

Pedunculus cerebri

Colliculus rostralis stratum zonale
Colliculus rostralis stratum opticum
Tractus opticus
Nucleus pulvinaris
Corpus subcommissuralis
Nucleus pretectalis anterior
Substantia grisea centralis
Nucleus geniculatus medialis
Tractus tegmenti centralis

Nucleus ruber

Nucleus substantia nigra

Plate 39. Section at Frontal 13.3. A. Unstained section; B. Thionin stained section.

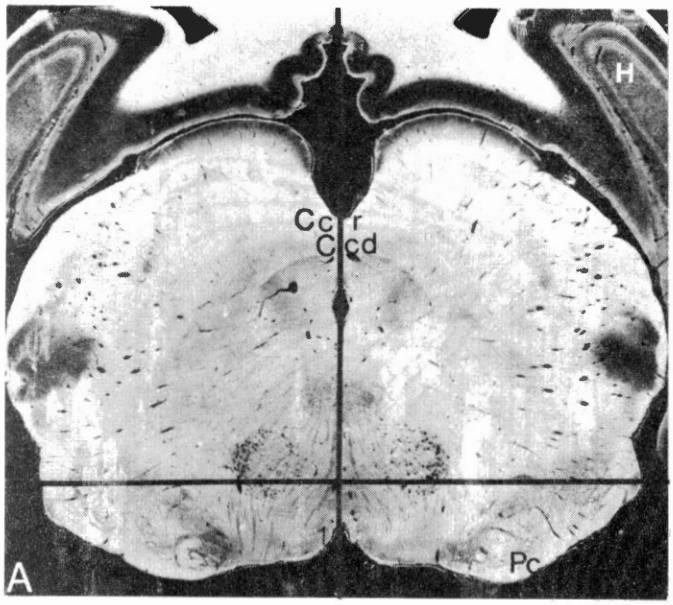

Hippocampus

Commissura colliculorum rostralis
Commissura caudalis

Pedunculus cerebri

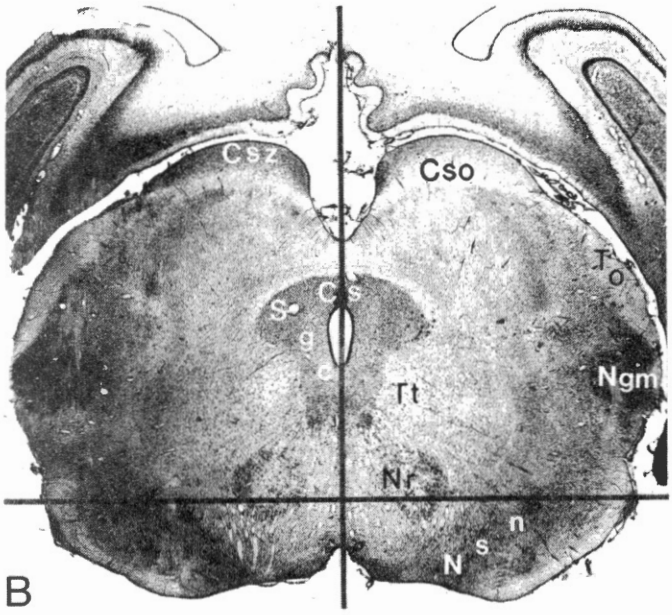

Colliculus rostralis stratum zonale
Colliculus rostralis stratum opticum

Tractus opticus
Corpus subcommissuralis
Substantia grisea centralis

Nucleus geniculatus medialis
Tractus tegmenti centralis

Nucleus ruber

Nucleus substantia nigra

Plate 40. Section at Frontal 12.8. A. Unstained section; B. Thionin stained section.

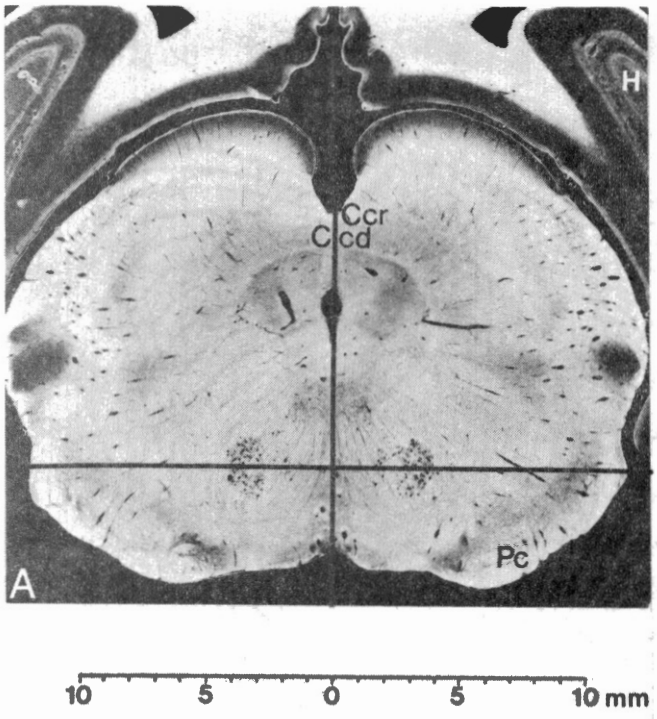

Hippocampus

Commissura colliculorum rostralis
Commissura caudalis

Pedunculus cerebri

Colliculus rostralis stratum zonale

Tractus opticus
Corpus subcommissuralis
Substantia grisea centralis

Nucleus geniculatus medialis
Tractus tegmenti centralis
Nuclei oculomotorii

Nucleus ruber

Nucleus substantia nigra

Plate 41. Section at Frontal 12.2. A. Unstained section; B. Thionin stained section.

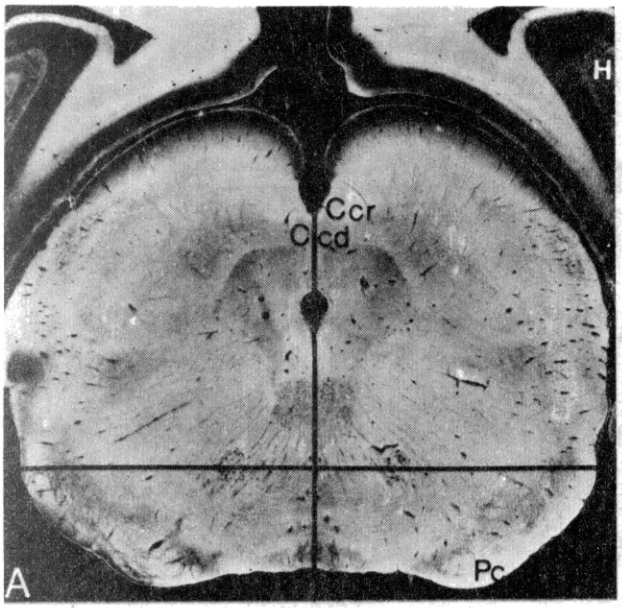

Hippocampus

Commissura colliculorum rostralis
Commissura caudalis

Pedunculus cerebri

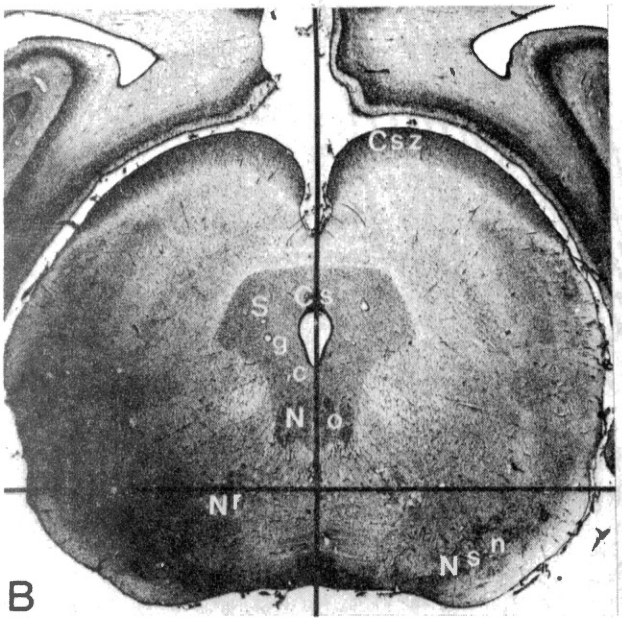

Colliculus rostralis stratum zonale

Corpus subcommissuralis
Substantia grisea centralis

Tractus tegmenti centralis
Nuclei oculomotorii

Nucleus ruber

Nucleus substantia nigra

Plate 42. Section at Frontal 11.7. A. Unstained section; B. Thionin stained section.

A SELECTED BIBLIOGRAPHY

Anderson, B., N. Persson, and L. Ström. (1960) "Functional Localization as an aid to Implantation of Permanent Electrodes Into the Hypothalamus of Horned Goats." Acta Physiol. Scand. 50:49-53.

Bleir, Ruth. (1961) The Hypothalamus of the Cat. Baltimore: The Johns Hopkins Press.

Breazile, James E. Personal communication to members of the Subcommittee on Histologic Nomenclature of the International Committee on Veterinary Anatomical Nomenclature, July 22, 1971.

Crosby, E. C., T. Humphrey, and E. W. Lauer. (1962) Correlative Anatomy of the Nervous System. New York: The Macmillan Company.

Gurr, Edward. (1971) Synthetic Dyes in Biology, Medicine, and Chemistry. New York: Academic Press, p. 45.

Guzmán, F. Carlos, Manuel Alcarez V., and Augusto Fernández G. (1958) "Rapid Procedure to Localize Electrodes in Experimental Neurophysiology." Boletin Del Instituto de Estudios Médicos y Biológicos (Mexico City). 16:26-31.

Haskins, J. T., D. P. Jennings, and J. M. Rogers. (1975) "Response of Supraoptic Neuroendocrine Cell Firing Pattern Types to Measured Changes in Plasma Osmolality." The Physiologist. 18(3):240.

Haymaker, Webb, Evelyn Anderson, and Walle J. H. Nauta. (1969) The Hypothalamus. Springfield: Charles C. Thomas.

Horsley, Victor, and R. H. Clark. (1908) "The Structure and Functions of the Cerebellum Examined by a New Method." Brain. 31:45-124.

Johnson, J. A., J. E. Zehr, and N. W. Moore. (1970) "Effects of Separate and Concurrent Osmotic and Volume Stimuli on Plasma ADH in Sheep." American Journal of Physiology. 218(5):1273-1280.

Larsson, S. (1954) "On Hypothalamic Organization of Nervous Mechanism Regulating Food Intake." Acta Physiol. Scand. 32(Suppl. 115):1-63.

Lim, Robert K. S., Chan-Nao Liu, and Robert L. Moffitt. (1960) A Stereotaxic Atlas of the Dog's Brain. Springfield: Charles C. Thomas.

Oswaldo-Cruz, E., and C. E. Rocha-Miranda. (1968) The Brain of the Opossum (Didelphis Marsupials). Rio de Janerio: Instituto de Biofisica, Universidade Federaldo Rio de Janerio.

Pearse, A. C. Everson. (1961) Histochemistry, Theoretical and Applied. Boston: Little, Brown, and Company, p. 204.

Radford, H. M. (1967) "The Effect of Hypothalamic Lesions on Reproductive Activity in Sheep." Journal of Endocrinology. 39:415-422.

Richard, Ph. (1967). Atlas Stéréotaxique du Cerveau de Brebis Préalpes-du-Sud. Paris: Paris Institut National de la Recherche Agronomique.

Richard, Ph. (1970) "An Electrophysiological Study in the Ewe of the Tracts Which Transmit Impulses From the Mammary Glands to the Pituitary Stalk." Journal of Endocrinology. 47:37-44.

Rose, Jerzy E. (1942) "The Thalamus of the Sheep: Cellular and Fibrous Structure and Comparison With Pig, Rabbit, and Cat." Journal of Comparative Neurology. 77:469-523.

Ruckenbush, Y. (1972) "The Relevance of Drowsiness in the Circadian cycle of Farm Animals." Animal Behavior. 20:637-643.

Singer, Marcus. (1962) The Brain of the Dog in Section. Philadelphia: W. B. Saunders Co.

Singh, Kiral, Khub Singh, B. K. Soni, and S. K. Manchanda. (1972) "Brain on the Buffalo in Stereotaxic Coordinates." Indian Journal of Physiology and Pharmacology. 16:127-138.

Snider, Ray S., and William T. Niemer. (1961) A Stereotaxic Atlas of the Cat Brain. Chicago: The University of Chicago Press.

Tindal, J. S., G. S. Knaggs, and A. Turvey. (1968) "The Forebrain of the Goat in Stereotaxic Coordinates." Journal of Anatomy. 103:457-469.

Traczyk, Wladyslaw, and Franciszek Przekop. (1963) "Methods of Investigation the Function of the Hypothalamus and Hypophysis in Chronic Experiments in Sheep." ACTA Physiologica Polonica. 14:217-226.

Welento, Janusz, Stanislaw Szteyn, and Zbizniew Milart. (1964) "Observation on the Stereotaxic Configuration of the Hypothalamus Nuclei in the Sheep." Anatomischer Anzliger. 124:1-27.

APPENDIX

FRONTAL COORDINATES OF SELECTED STRUCTURES

Sheep #	Frontal Coordinates					
	Commissura Anterior		Thalamic Adhesion		Nucleus Supraopticus	
	Rostral Edge	Caudal Edge	Rostral Edge	Caudal Edge	Rostral Edge	Caudal Edge
3	30.5	29.6	27.8	20.6		
right side					29.1	27.2
left side					29.1	27.2
5	30.3	29.4	27.6	----		
right side					29.1	27.7
left side					29.4	28.3
6	31.3	30.4	27.9	----		
right side					30.9	29.0
left side					30.5	28.4
8	30.9	30.1	28.1	20.6		
right side					30.7	28.6
left side					30.5	28.3
11	31.7	31.1	28.2	21.5		
right side					32.3	28.1
left side					32.7	28.1
Mean	30.90	30.10	27.92	20.90	30.43	28.09

VITA

John Miles Rogers

Candidate for the Degree of

Master of Science

Thesis: A STEREOTAXIC ATLAS OF THE DIENCEPHALON OF THE SOUTHDOWN SHEEP

Major Field: Physiological Sciences

Biographical:

Personal Data: Born in Fort Worth, Texas, August 19, 1944, the son of Mr. and Mrs. M. R. Rogers.

Education: Graduated from Arlington Heights High School, Fort Worth, Texas in 1962; received three years of college credit with a major in Civil Engineering from 1962-1966 at the University of Texas at Arlington, Arlington, Texas; received degree and license for Practical Nurse, March, 1968, from Clinical Specialist School, Fort Sam Houston, San Antonio, Texas; completed requirements for the Bachelor of Science degree in Biology from North Texas State University, Denton, Texas in 1971; entered the Graduate College of Oklahoma State University in 1972; completed requirements for the Master of Science degree at Oklahoma State University in May, 1976.

Professional Experience: Licensed Practical Nurse in the State of Texas and the State of Oklahoma at the following locations: W.I. Cook Childrens Hospital, Fort Worth, Texas, 1970-1972; Flo Memorial Hospital, Denton, Texas, February-May, 1972; and Stillwater Memorial Hospital, Stillwater, Oklahoma, July-September, 1973. Graduate Teaching Assistant from September, 1973 to May, 1975. Graduate Research Assistant from June to August, 1975.