

PERILLA FRUTESCENS TOXICITY IN CATTLE

By

LARRY ALAN KERR
"

Bachelor of Science
West Virginia University
Morgantown, West Virginia
1968

Doctor of Veterinary Medicine
Oklahoma State University
Stillwater, Oklahoma
1971

Submitted to the Faculty of the Graduate College
of the Oklahoma State University
in partial fulfillment of the requirements
for the Degree of
MASTER OF SCIENCE
December, 1983

Thesis
1983
K403p
cop. 2



PERILLA FRUTESCENS TOXICITY IN CATTLE

Thesis Approved:

George Burrows

Thesis Adviser

William C Edwards

S. L. Burbs

Norman D Durham

Dean of the Graduate College

PREFACE

This study characterizes Perilla frutescens toxicosis in the bovine. Clinical signs were closely monitored in four calves given various amounts of mint and the postmortem lesions noted. Different parts of the plant (both green and dry) were analyzed for perilla ketone content. This information will be helpful in diagnosing and in developing prevention regimens for Perilla frutescens poisoning in cattle.

The author wishes to express his appreciation to his major adviser, Dr. George E. Burrows, for his guidance and assistance throughout this study. Appreciation is also expressed to the other committee members, Dr. W. C. Edwards and Dr. S. L. Burks for their assistance in the preparation of the final manuscript.

A note of thanks is also given to Dr. Bill Johnson for assistance with the histopathology, and to Mr. Max Whaley for assistance with the toxicology. In addition, appreciation is extended to the Department of Physiological Sciences for supplying the calves and other necessary items for this interesting project.

TABLE OF CONTENTS

| Chapter | Page |
|--|------|
| I. THE RESEARCH PROBLEM | 1 |
| II. REVIEW OF THE LITERATURE | 3 |
| General Characteristics of Atypical Interstitial Pneumonia | 3 |
| Clinical Signs of Atypical Interstitial Pneumonia | 4 |
| Lesions of Atypical Interstitial Pneumonia | 5 |
| Reported Causes of Atypical Interstitial Pneumonia | 7 |
| Furans and Atypical Interstitial Pneumonia | 8 |
| Previous Work with Purple Mint | 13 |
| Cases of AIP at the Oklahoma Animal Disease Diagnostic Laboratory | 15 |
| III. MATERIALS AND METHODS | 19 |
| IV. RESULTS | 25 |
| Clinical Signs | 25 |
| Necropsy | 29 |
| Histopathology | 30 |
| Toxicology | 31 |
| V. DISCUSSION | 32 |
| VI. SUMMARY | 38 |
| BIBLIOGRAPHY | 40 |

LIST OF TABLES

| Table | Page |
|--|------|
| I. Amount of Green Mint Consumed and Symptoms of Calf #1 | 25 |
| II. Amount of Green Mint Consumed and Symptoms of Calf #2 | 27 |
| III. Amount of Mint Hay Consumed and Symptoms of Calf #3 | 28 |
| IV. Amount of Dried Mint Consumed and Symptoms of Calf #4 | 29 |

CHAPTER I

THE RESEARCH PROBLEM

Atypical interstitial pneumonia (AIP) is a noncontagious respiratory disease primarily affecting cattle. In some parts of the United States, AIP is a leading cause of respiratory related deaths, especially in the late summer or early fall.

There have been many etiologies posed for AIP. The most widely accepted causes are grasses which contain high levels of tryptophan. The conversion of tryptophan to 3-methylindole by microorganisms in the rumen is often accompanied by the development of atypical interstitial pneumonia. This syndrome has resulted in extensive cattle losses in the fall months when cattle have been moved from nonsucculent forage (low in tryptophan) to more succulent forage (high in tryptophan). Other agents associated with AIP include nitrous oxides (common around silos), allergins including those from moldy feed, and toxins from moldy sweet potatoes, crotalaria and purple mint.

Purple mint (Perilla frutescens) is a weed found in much of the Southeastern United States. Originally introduced from Asia as an ornamental, it has escaped gardens to become a very troublesome plant. Since the early 1960s, purple mint has been recognized as a potential cause of AIP. The association was based on evidence of affected cattle having grazed the plant or having found the square-stemmed purple mint material in their rumens. Attempts to reproduce the condition by

controlled feeding trials have been unsuccessful. However, AIP was produced in three cows allowed to graze a field that consisted largely of purple mint, but the amount each ingested was unknown. AIP has also been produced by injecting the suspected toxic agent (perilla ketone) intravenously into some heifers.

Because of the many uncertainties regarding the association between purple mint and AIP, the following study was undertaken to:

1. Conclusively show the association of feeding purple mint and the development of AIP.
2. Determine the amount of plant required to produce toxicity.
3. Determine the hazard with dried plants such as those in hay.
4. Determine which stages of plant growth are hazardous.

It was believed such a study would result in a better understanding of perilla mint toxicosis in cattle.

CHAPTER II

REVIEW OF THE LITERATURE

General Characteristics of Atypical Interstitial Pneumonia

Atypical interstitial pneumonia (AIP) is a noncontagious respiratory disease that primarily affects cattle (1). This condition has many etiologies as well as many names. Among the titles that have commonly been used for this condition are acute bovine pulmonary edema and emphysema (ABPE), fog fever (especially in Britain), bovine asthma, summer snuffles, hay fever and panting disease (2, 3, 4). Additional names employed for this disease include pulmonary adenomatosis, lungers disease, pulmonary rape poisoning, panters and lungers (5, 6).

Acute pulmonary emphysema in cattle was first reported in Canada, but has since become a commonly recognized problem in the United States, England, and Holland (7). A similar condition of sheep has been reported in Queensland with the same symptoms and lesions as those described for cattle (6). The term "acute bovine pulmonary edema and emphysema" (ABPE) was used in the western United States to describe a fulminating pulmonary emphysema that occurred in cattle subjected to a sudden change in forage (8). There have been reports of nearly 1,000 head of cattle being affected annually in the state of Utah of which most die (7). In Texas, increased recognition of ABPE in cattle has been associated

with intensive pasture operations involving fast growing, high yielding and high protein grasses (5). In Europe, this condition (referred to as fog fever) has been commonly associated with the fall grazing of lush second growth grasses (4, 5).

The incidence of AIP in the intermountain region of the western United States is reportedly highest in the fall when cattle are moved from dry summer pastures to the lush, succulent lowland pastures used during the fall months (1, 9). However, this condition has also been reported throughout the year, and in many different areas of the country. In recent years, the incidence of pulmonary emphysema has increased in the southern United States, but it is believed from a different cause than that associated with the condition in the western United States (10).

Clinical Signs of Atypical Interstitial Pneumonia

Atypical interstitial pneumonia is characterized by a sudden onset of severe dyspnea with an expiratory grunt. Both beef and dairy cattle have been affected with AIP, but Herefords are reported to be more susceptible (5). The condition has rarely been seen in Brahma or Brahma crossbred cattle (5). Symptoms usually commence five to ten days after a change of pasture with animals standing apart from the rest of the herd with their heads extended and having difficulty breathing. Body temperatures of animals with AIP are usually normal or only slightly elevated, pulse rates are increased (70 to 120 per minute), intestinal peristalsis is markedly reduced and constipation is common (10, 11). Froth is often apparent around the mouth and nose of affected animals. Unlike animals with a bacterial pneumonia, many animals with AIP continue to eat and drink (5). The majority of cases are described in animals three years

old or older, but a few cases have been reported in calves and yearlings (2). There has not been a tendency for one sex to be affected more than the other (11). The condition usually has a rapid course of one to three days. The morbidity has been reported as one to 100% and the case fatality rate as five to 50% (1, 2). Animals are often found dead without signs of struggle (2). Death reportedly occurs more rapidly if affected animals are forced to exert themselves (9). Clinical signs resemble those that accompany organophosphate toxicity with the exception of the absence of pupillary constriction, diarrhea, muscle tremors and limb stiffness (5).

Lesions of Atypical Interstitial Pneumonia

Characteristic lesions of AIP include lungs swollen to the extent that, when opening the thoracic cavity, an imprint of the ribs is observed (2). The affected lungs do not collapse. Emphysema is often prominent not only in the lungs but also in the mediastinum and the cervical, thoracic, and lumbar subcutaneous areas (2, 10). Emphysema, when present in the lung tissue and adjoining mediastinal tissues and muscle groups, often resembles a clostridial disease. The lungs, usually firmer and darker pink than normal, often have a marbled appearance (5, 12). Edema and froth in the trachea and bronchial passages are also frequently described. The interstitial septa are very distinct, being filled with a gelatinous fluid and gas (5). Typically, the pulmonary lobules separate quite easily. Observations of moderate congestion as well as distinct subpleural emphysematous bullae are common (6).

Histologically, some lobules are characterized by dilated and ruptured alveoli. Many alveoli reportedly contain a moderate amount of

edema while interlobular septa often have an accumulation of air and fluid (2, 5, 13, 14). Prominent cuboidal cells are usually observed lining the alveoli of AIP lungs and, in some cases, alveoli have a continuous lining composed of cuboidal epithelial cells. These cells, characterized by very prominent nuclei, are sometimes referred to as type II pneumocytes in contrast to the flat, squamous epithelial cells (type I pneumocytes) that normally predominate (5, 14). Large bullae are often seen where alveoli rupture into others and many capillaries are collapsed and ischemic (2). Infiltrations of neutrophils and eosinophils and the presence of hyaline membranes are commonly observed (3). Thus, hypertrophy and hyperplasia of alveolar lining cells with a thickening of interstitial tissues is characteristic (12). It has been postulated that agents such as 3-methylindole and other pulmonary toxins cause leakage of fluid from lung parenchymal capillaries (13, 14). This accumulated fluid may cause a partial blockage of the airways which could result in alveolar emphysema (6). Metaplasia of the alveolar squamous epithelium (type I pneumocytes) to low cuboidal epithelium (type II pneumocytes) is considered a basic reaction of the alveolar epithelium to irritation. The reaction is frequently followed by prolonged pulmonary edema.

Atypical interstitial pneumonia is defined as an inflammatory process resulting from diffuse alveolar septal damage without obvious orientation of the lesions around the small airways. The acute phase is thought to consist of an exudation into the alveolar lumens and subsequently, if the animal survives long enough, a more prominent interstitial component (15). Interstitial pneumonic changes are described as being widely distributed throughout the lung while bronchopneumonias have a more cranioventral distribution. Atypical interstitial pneumonia is

the term used to describe this condition since it has an acute exudative phase (16).

The shift from the exudative to the proliferative stage of pneumonia is characterized by a marked proliferation of type II pneumocytes (cuboidal epithelial cells) and the consequent sloughing of type I pneumocytes (squamous epithelial cells). Type I pneumocytes are thought to be more sensitive to damage because of poor repair processes. Type II cells are considered much less vulnerable, hence the resulting slough of type I cells and proliferation of type II cells. In summary, atypical interstitial pneumonia is characterized by damage to both capillary endothelial cells and alveolar epithelial cells (15, 16). Initially, fluid filled alveoli with hyaline membranes and interstitial edema are often observed. Secondly, there is described a sloughing of type I epithelial cells and a proliferation of type II epithelial cells followed by interstitial fibrosis. This syndrome results in scarred lung tissue of animals that survive (15, 17).

Reported Causes of Atypical Interstitial Pneumonia

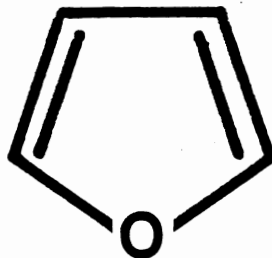
The many causes of atypical interstitial pneumonia have been grouped as follows (11, 16, 18, 19):

1. 3-methylindole from forages high in the amino acid tryptophan often produces AIP. There are many reports on the association of various forages such as alfalfa, clover, bermudagrass, and various weeds with atypical interstitial pneumonia (2, 3, 5). These lush forages are high in the amino acid tryptophan which is usually converted to 3-methylindole by rumen

- microorganisms (3). 3-methylindole causes atypical interstitial pneumonia (20, 31, 22, 23, 24, 25).
2. Chemicals such as nitrogen dioxide, high concentrations of oxygen (oxygen radicals damaged cell membranes by lipid peroxidation), and zinc oxide can produce AIP.
 3. Adverse drug reactions such as anaphylactic reactions to penicillin often produce AIP. The primary damage here is to the capillary endothelium as less damage occurs to type I pneumocytes.
 4. Irradiation can produce atypical interstitial pneumonia.
 5. Hypersensitivity to hay molds such as the actinomycetes agent Microsporysora, may result in AIP.
 6. The herbicide paraquat, pyrrolizidine alkaloids, ipomeanol from moldy sweet potatoes and perilla ketone from purple mint are all associated with atypical interstitial pneumonia (16, 19, 26).

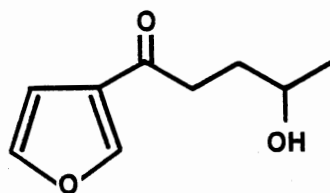
Furans and Atypical Interstitial Pneumonia

Furans are commonly found in the environment in both plant and animal products (27). They have the following basic structure that is often substituted (28):

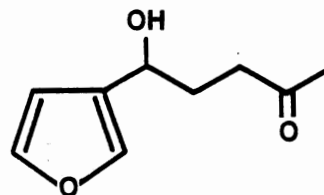


Coffee, cooked meat, fish, and many fruits contain furans. Peppermint oil contains up to eight percent methofuran (27). Several well known therapeutic agents such as furosemide and nitrofurantoin possess furans as their primary components. However, many of the 3-substituted furans are quite toxic (27). The Ngaio tree and the Elangowan bush in Australia contain hepatotoxic agents that consist of 3-substituted furans. These hepatotoxic compounds are chemical relatives of the toxic metabolites of the mold infected sweet potato and those believed to occur naturally in purple mint. Both of these contain 3-substituted furans. Thus, the 3-substituted furan group includes both liver and lung toxic compounds (27).

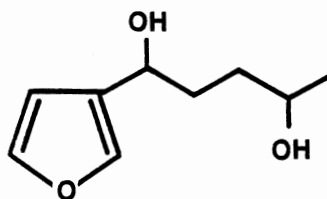
Moldy sweet potato poisoning has been reported for several decades in the United States and Japan. Infection of sweet potatoes by the fungus Fusarium solani often produces the lung toxins 4-ipomeanol and 1-ipomeanol, both 3-substituted furans. Several other fungi and some chemicals reportedly stimulate the formation of ipomeamarone which is a hepatotoxin. The structures of these compounds are described as follows (27):



4-ipomeanol



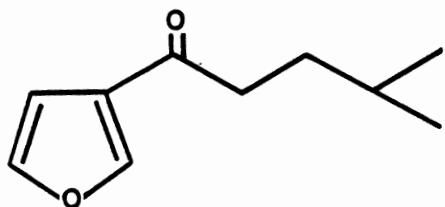
1-ipomeanol



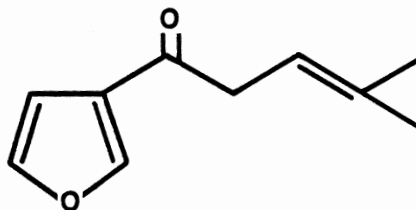
ipomeamarone

Animals that ingest moldy sweet potatoes often show varying degrees of dyspnea, rapid breathing and death from asphyxiation. On postmortem examination, the lungs are described as wet, heavy, and emphysematous. This observation is considered typical of AIP. Microscopically, there is described interstitial and alveolar edema and proliferation of the alveolar epithelium (27). Fusarium solani is thought to serve as the initial stressing agent and also as the metabolic convertor of the hepatotoxin (ipomeamarone) to the lung toxin (ipomeanol) (27). The gross and microscopic lesions vary depending upon the toxic dose and the survival time after dosing (27).

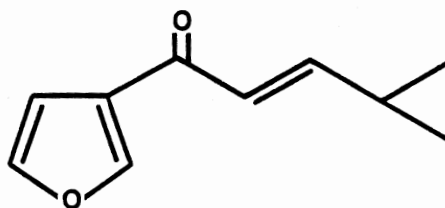
Perilla frutescens also contains 3-substituted furans. Common names for this plant include purple mint, wild coleus, perilla mint, perilla and beefsteak plant. 3-substituted furans isolated from this plant are closely related chemically to ipomeanol. The chemical structures of these 3-substituted furans follow (27):



Perilla Ketone



Egomaketone



Isoegomaketone

Perilla frutescens is an erect, branching, herbaceous, annual that grows to 0.3 to 2 meters in height. It thrives best in the summer when many plants are heat dormant. However, cattle usually ignore it if ample grass is available. The leaves of perilla are approximately 5 to 10 centimeters long and 4 to 8 centimeters wide (29, 30). They are coarsely serrated, obtuse to round at the base but cuneate at the apex. These leaves often attain a purple tint late in the season, hence the name. Racemes 5 to 15 centimeters long grow on the upper axils. Bracteal leaves appear oval and folded with the pedicels being one to three millimeters long. The calyx at the anthesis is approximately three millimeters long while the fruit usually measures 9 to 12 millimeters in length and is hairy within. The flowers of perilla are white (19, 29, 30, 31). Like all members of the mint family, perilla has square stems (29, 30).

Perilla frutescens is a native of Asia where the seed oil is used in commerce as a flavoring agent (32). In the United States, it is commonly found in light woods, along open wooded streams, along roadsides, in waste places and in seepage areas (29, 32).

It is thought that perilla was brought to this country as an ornamental, but escaped from gardens to become a very troublesome weed. This plant is found in much of the United States from southern New England to the Gulf of Mexico and as far west as the eastern parts of Texas, Oklahoma, and Kansas (Figure 1) (30, 31, 32).

Perilla frutescens is a member of the Labitae (mint) family. This family contains herbs which have square stems and opposite aromatic leaves. Labiatae is a large family with approximately 3,500 species in 180 genera of worldwide distribution (32). Flowers of mint family members are arranged in clusters that are often aggregated in terminal

spikes or racemes (32). These plants contain a four-lobed ovary which forms little seed-like nutlets or achenes, each filled with a single erect seed. The seeds or nutlets of perilla are small, smooth and somewhat four-parted (32).

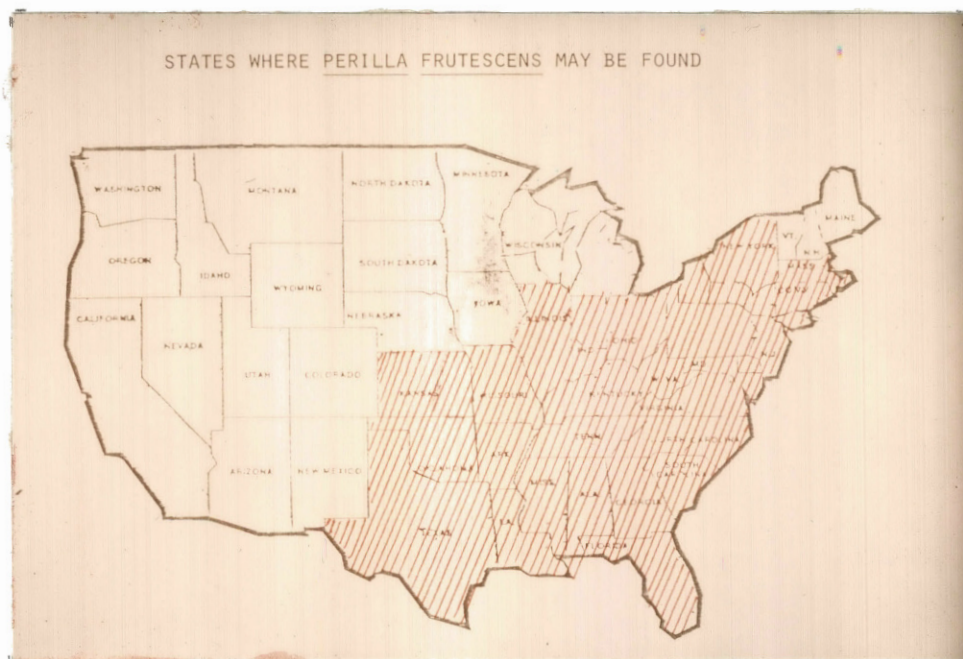

Figure 1. States where Perilla frutescens has been reported.

The foliage of purple mint is dotted with small glands that contain a volatile aromatic oil. The seed also possesses a high oil content from which perilla oil meal is produced. The oil meal contains approximately 38.4% protein but has only 62% total digestible nutrients (33). Thus, the seeds have been used as high protein animal supplements, as fertilizers, as flavoring agents, and as bird feed (19).

Previous Work with Purple Mint

In the late 1940s the occurrence of bovine pulmonary emphysema in eastern Oklahoma was recognized with increased frequency. In 1960, the problem had reached such a magnitude in this section of Oklahoma that a series of field investigations were undertaken (34). During the interval from 1961 to 1963, eight occurrences of AIP were investigated in which many animals had died. The plant common to all of these cases was Perilla frutescens. Observations of perilla plant parts in the rumens of dead animals and perilla seeds in the feces of others provided additional evidence that this plant was a primary cause of the problem (34). In some of the cases investigated, pasture was short and evidence indicated that perilla had been heavily grazed (34, 35). Observations made at this time revealed that perilla grew principally in river and creek bottoms where trees were thin enough to allow sunlight to penetrate. This point was particularly evident where loggers had removed some of the larger trees and farmers had killed many of the smaller ones. Up to 90% of the vegetation in these areas often consisted of purple mint (34). This plant was often seen around abandoned farmsteads and in old corrals. The observations made at this time were summarized as follows:

1. The disease was thought to be seasonal and occurred primarily in August, September, and October, the period often referred to as fair time to frost.
2. The seed stage of the plant appeared to favor the production of AIP.
3. The acceptance or rejection of this plant by cattle was believed to be related to the nutritional background (amount

of good pasture available) and to the palatability of the plant. Cattle that were deficient in total digestible nutrients were often found in a negative nitrogen balance and thus consumed perilla more readily (34).

4. It was thought that many of the Arkansas cattle deaths in the late 1940s diagnosed as pulmonary emphysema, might have been caused by perilla (34, 35).

A purple mint feeding trial was attempted in the fall of 1961. A Holstein steer weighing 243.6 kilograms was fed perilla collected in eastern Oklahoma. From September 28 to October 4 this steer ingested 10.5 kilograms of perilla, but no toxic symptoms were observed (34).

On September 25, 1963, three adult white-faced cows were placed on a five-acre plot where perilla was estimated to constitute 90% of the available forage. Suspicious toxic plants (other than perilla) were removed from this plot. By September 27, two cows had shown clinical signs of pulmonary problems. On September 28, one cow had died and one was clinically ill. The other cow was normal at this time. However, by October 1 all cows had died. A diagnosis of pulmonary emphysema on the three cows was confirmed by the Oklahoma State University Department of Veterinary Pathology (34). Similar symptoms were observed in all three cows. Frequent belching was detected first followed by saliva dripping from both sides of the mouth. Shallow respirations were common later with the characteristic expiratory grunt. The respiratory rate reportedly reached 70-80 per minute a few hours before death (34).

Perilla ketone, egomaketone, and isoegomaketone have all been synthesized and found to be potent lung toxins in rats and mice (27). The intraperitoneal LD₅₀ doses were 6 mg/kg and 2.5 mg/kg in male and

female white mice, respectively. The LD_{50} s in male rats were 10 mg/kg intraperitoneally and 25 mg/kg orally. All of these animals had post-mortem lesions that consisted of pulmonary edema and emphysema. The only difference reported in the pathological response of the mice to these three toxins and 4-ipomeanol was the lack of kidney damage with the perilla metabolites (27).

Experiments were conducted with synthetic perilla ketone in Angus heifers. Two heifers failed to develop any clinical signs of toxicity when 3 and 9 mg/kg were administered directly into the rumen. Intraruminal doses of up to 40 mg/kg were not accompanied by any clinical signs of illness. Another cow that was given 30 mg/kg perilla ketone intravenously developed symptoms of pulmonary emphysema and died three days later. Postmortem examination confirmed atypical interstitial pneumonia. A mature male sheep was also administered 19 mg/kg perilla ketone intravenously and developed labored breathing three days later. This respiratory difficulty had diminished in another two days, at which time the animal was sacrificed. The only reported lesions in the sheep were patches of intraalveolar edema (19, 27). Nanny goats given 40 mg/kg and 18 mg/kg of synthetic perilla ketone intravenously were dead in 12 hours. Another nanny goat given 10 mg/kg of this synthetic compound intravenously was dead in 36 hours. On postmortem examinations, all of these animals showed severe pulmonary emphysema and edema (19).

Cases of AIP at the Oklahoma Animal Disease Diagnostic Laboratory

During the interval from August 1978 to August 1981, 57 cases of AIP were diagnosed at the Oklahoma Animal Disease Diagnostic

Laboratory. These cases constituted 111 known dead animals with many more at risk. This number was thought to represent only a small percentage of the total number of cases involved as reported telephone conversations and personal consultations with field veterinarians disclosed many more presumptive cases of AIP. Of the 57 cases, three were attributed to the ingestion of purple mint by having found either square stemmed material in the rumen contents or having presented a history of ingestion of this plant. Several more cases may have been due to perilla, but there was no evidence to validate this theory. Two of the purple mint cases confirmed were from Arkansas and the third was from southeast Oklahoma (36).

In February 1982, two Angus females, a yearling heifer and a three-year-old cow, were submitted to the Oklahoma Animal Disease Diagnostic Laboratory from eastern Arkansas. Three mature cows from this herd had died approximately three weeks previously with no clinical signs of illness noted. At that time, the cattle had been eating large round bales of prairie grass hay and protein blocks. This hay had been baled in ungrazed pastures. After the three cows died, the other cattle (140 mature cows, 33 yearling heifers and 44 yearling bulls) were switched to square bales that were harvested at a different location and the losses ceased. However, when the supply of square bales was exhausted, the owner switched the cattle back to the large round bales and more deaths occurred. When the two cows were submitted to the laboratory for post-mortem examination, there had been 45 deaths involving primarily mature cows. Other cattle were reported to have shown moderate to severe dyspnea and wheezing, but most continued to eat and drink. The affected cattle were treated symptomatically with steroids, atropine, and

antihistamines with some success. In all, 81 deaths resulted over approximately a four-week period. Most of the dead animals were mature cows, but a few calves and three yearling bulls also died.

When the thorax was opened on the two animals submitted, the lungs failed to collapse and were heavier than normal. Interlobular septa were distended by gas bubbles and fluid in both cows. Scattered throughout the pulmonary parenchyma were lobules that were purple in contrast to the pink lobules of adjacent lobes. All of the affected lobules contained gas bubbles of variable size. There were several variably sized emphysematous bullae in the lungs of both animals. Some square stemmed material resembling purple mint was present in each rumen.

Histopathologic examination of the lungs showed extreme widening of the interlobular septa by gas bubbles and edema. Many alveoli were lined by cuboidal epithelial cells often referred to as type II pneumocytes. Within some of the alveolar lumens were accumulations of a very fine fibrillar (acellular) material alongside the epithelial cells. This material has been reported a precursor of hyaline membranes (15). All of the lesions seen are characteristic of atypical interstitial pneumonia (15, 16).

Water and hay samples from this case were submitted to the Oklahoma Animal Disease Diagnostic Laboratory for toxicant analysis. Many tests were performed including nitrate, heavy metals and mycotoxins. There were no mycotoxins detected in the hay sample and the nitrate content was well within acceptable limits. The water sample contained negligible amounts of lead and arsenic, an acceptable nitrate level for livestock consumption, and a normal pH and total salt content. However, a large amount of square stemmed plant material, subsequently identified

as Perilla frutescens, was observed in the hay sample (35). Although no mycotoxins were detected in the hay sample, a large amount of mold was noted. Further consultation with the owner revealed the following:

The hay crop on this farm in Arkansas in the summer of 1981 was "thinner" than usual. Therefore, the owners decided to harvest some of the pasture areas that were not normally baled. Although this resulted in some good hay near the center of the fields, areas that were baled near the woodline contained the plant identified as purple mint. Some of these plants were two meters in height. The field was harvested in early August 1981, a time when the mint would be in the seed stage. The owner estimated that he had 60 to 80 large round bales of hay that contained abundant amounts of mint. This hay had been set aside and used later in the year.

At this time it was difficult to make recommendations to the owners since little information was available in the literature on the amount of purple mint required to produce AIP. Also, no reports were present on whether dried purple mint even produced AIP.

CHAPTER III

MATERIALS AND METHODS

Three uncastrated male Holstein calves approximately five months old were used along with an eight-month-old uncastrated male Jersey calf and a one-year-old female sheep. The animals will hence be referred to as the sheep, calf #1, calf #2, calf #3, and calf #4. The sheep, calf #1, and calf #4 all had rumen fistulas. Physical examinations performed prior to beginning the experiment indicated that all animals were healthy. The animals were maintained on a ration of mixed corn and oats along with prairie grass hay twice daily.

Three large round bales of hay from the Arkansas case (referred to earlier) were obtained along with an abundant supply of green mint in the seed stage from eastern Oklahoma and western Arkansas (Figures 2 and 3).

Part of the mint obtained was dried in the sun to simulate mint hay. The rest was refrigerated to avoid drying. Observations recorded were clinical signs, rectal temperatures and respiratory rates which were made prior to physical manipulations of the animals. Complete necropsies were performed immediately after death. A Perkin-Elmer High Pressure Liquid Chromatograph¹ (HPLC) with a Series 2 Pump and a LC-75 Detector was used to analyze various portions of the mint for perilla ketone content.

¹High Pressure Liquid Chromatograph, Perkin-Elmer Co., Norwalk, CT.



Figure 2. Typical perilla plant that was obtained for the experiment.



Figure 3. Typical area where purple mint was obtained.

Approximately 10 kilograms of purple mint stems were sorted from the three large round bales of hay. The stems were ground in a Wylie hammer mill and inserted through the fistula of the sheep. The sheep weighed 57 kilograms and was given 1.4 kilograms of ground mint stems over a five-day period. During this period, the animal was removed from its maintenance diet of grain and hay and received only the mint stems and water.

Calf #1 weighed 88.2 kilograms and was fed between 2.3 and 5.5 kilograms (what it would eat in a 24-hour period) of green perilla mint for four days and the clinical signs, rectal temperatures and respiratory rates noted. This calf was also removed from its regular diet of grain and hay for this period and received only green mint and water.

Calf #2 weighed 79.1 kilograms and was fed 2.3 kilograms of mint for one day and the clinical signs, temperatures and respiratory rates noted. This calf was given the mint mixed with an equal amount (2.3 kilograms) of prairie hay and water but was removed from its grain.

Calf #3 weighed 71.4 kilograms and was fed from 0.9 to 1.4 kilograms of mint hay for eleven days and the clinical signs, temperatures and respiratory rates noted. This calf was given dried mint mixed in approximately 2.3 kilograms of prairie hay and water free choice, but no grain. The mint was dried by placing it in the sun for three days during which time it lost 75% of its green weight.

Calf #4 weighed 181.1 kilograms and was given 6.6 kilograms of ground dry mint collected in January. At the time of collection, the plants were dried, leafless stems with remnants of the open seedless inflorescences. The dried plants were ground in the Wylie hammer mill and 2.2 kilograms were administered through the rumen fistula daily for

three days. This calf was removed from its maintenance diet of grain and hay for the three-day experimental period and received only the mint and had free choice water.

In order to perform the high pressure liquid chromatographic analysis, an ether extraction of perilla mint was performed. Five mint samples were analyzed which included the freshly harvested green mint (stems, leaves, and seed parts), green mint seed parts only, dried mint hay (random sample), mint stems from the Arkansas hay, and mint collected in January. Ten grams of each sample were finely ground and covered with ether for four hours in a flask at room temperature. At the end of this period, the ether was evaporated with low heat (40°C) and the residue dissolved in a mobile phase. This phase consisted of 95 milliliters of hexane, 2.5 milliliters of tetrahydrofuran (THF), 0.5 milliliters of iso-butyl alcohol, and 0.5 milliliters of iso-amyl alcohol. The residue that was dissolved in the mobile phase was then passed through Silica Sep Paks² prior to analysis. High pressure liquid chromatographic analysis was then performed on this sample. The column used was a μ -Porasil, 10 μ ³. The flow rate was 1 milliliter per minute at a pressure of 2,800 pounds per square inch. The wavelength used was 253.7 nanometers. Injections consisted of 10 microliter samples.

Complete necropsies and histopathologic examinations were performed on each animal that died. Lung and liver tissue were fixed in 10% formalin for examination by light microscopy. These tissues were

²Sep Paks, Waters Co., Milford, Massachusetts.

³ μ -Porasil, Waters Co., Milford, Massachusetts.

blocked preparatory to processing and embedment, washed in six baths of absolute Cellusolve,⁴ three baths of toluene and three baths of paraffin. Tissue washing was done in a Lipshaw Trimatic⁵ automatic tissue processor. Tissues were then embedded in paraffin, sectioned with a microtome and stained with Hematoxylin and Eosin with an Ames Histotech Automatic Slide Stainer.⁶

⁴Cellusolve, McKesson Chemical Co., Crocker Plaza, One Post Street, San Francisco, California 94104.

⁵Lipshaw Trimatic, Lipshaw Manufacturing Corporation, Detroit, Michigan 48210.

⁶Ames Histotech, Miles Laboratories, Elkhart, Kansas.

CHAPTER IV

RESULTS

Clinical Signs

The sheep, given the old ground purple mint stems obtained from the large round bales of hay, remained asymptomatic during the period when the mint was given and for a month after, at which time observations were stopped.

Calf #1, given green mint, ingested between 2.3 and 5.5 kilograms daily for four days (TABLE I). The calf died on the seventh day after ingesting 15.6 kilograms of green mint.

TABLE I
AMOUNT OF GREEN MINT CONSUMED AND SYMPTOMS OF CALF #1

| | Day 1 | Day 2 | Day 3 | Day 4 | Day 5 | Day 6 | Day 7 |
|--------------------|---------|---------|---------|--------------|------------------|----------------|-------|
| AMOUNT OF MINT FED | 2.3 kg | 5.5 kg | 2.7 kg | 5.0 kg | None | None | None |
| SYMPTOMS | Normal | Normal | Normal | Mild dyspnea | Moderate dyspnea | Severe dyspnea | Died |
| TEMPERATURE | 101°F | 101°F | 101°F | 102°F | 102°F | 99°F | |
| RESPIRATORY RATE | 40/min. | 60/min. | 60/min. | 80/min. | 120/min. | 140/min. | |

Calf #1 consumed the mint readily. Signs of intoxication were not seen until the fourth day at which time the calf developed mild respiratory problems that consisted of an increased respiratory rate and a mild expiratory grunt. The calf was reluctant to move on this day unless forced.

On the fifth day, the calf was given its former diet of grain and prairie grass hay since the supply of mint was exhausted. However, on this day the calf showed moderate respiratory distress that included a pronounced expiratory grunt. The respiratory rate was increased to 120/minute. The calf was salivating excessively, held its head extended and low to the ground and, if made to move, would fall to lateral recumbency in extreme respiratory distress.

On the sixth day, the respiratory rate was increased to 140/minute, the calf was very cyanotic and stood with its mouth open gasping for breath. Very loud expiratory grunts were prominent and the rectal temperature had declined to 99°F. The animal would not move at this time and it died at 8:00 a.m. on the seventh day.

Calf #2 was started on a feeding trial with 2.3 kilograms of green mint (TABLE II). Because of the severe nature of the clinical signs the following day, additional mint was not fed. The calf died 23 hours after it had ingested 2.3 kilograms of mint.

This calf seemed to prefer the mint to the prairie grass hay as it was observed to pick it from the hay. It had consumed the entire 2.3 kilograms of mint one hour after it was fed. By 8:00 a.m. on the second day the calf was in extreme respiratory distress with its head held low to the ground. The calf was very cyanotic with an expiratory grunt, and a respiratory rate of 80/minute. The rectal temperature had fallen to

99°F. The animal at this time was very depressed and could not be forced to move. It had selectively eaten all of the mint, but most of the prairie grass hay which had been fed the previous day remained. The calf became progressively worse and died at 3:00 p.m. on the second day.

TABLE II
AMOUNT OF GREEN MINT CONSUMED AND SYMPTOMS OF CALF #2

| | Day 1 | Day 2 - 8:00 a.m. | Day 3 - 3:00 p.m. |
|--------------------|---------|-------------------|-------------------|
| AMOUNT OF MINT FED | 2.3 kg | None | None |
| SYMPTOMS | Normal | Very dyspneic | Died |
| TEMPERATURE | 101°F | 99°F | |
| RESPIRATORY RATE | 40/min. | 80/min. | |

To fulfill the third objective, 90.9 kilograms of green mint (wet weight) were dried in the sun for three days to simulate hay that would be ready to bale. When dry, 90.9 kilograms of green mint yielded 24.5 kilograms of mint hay. Thus, it was assumed that the mint was approximately 26% or less dry matter. Calf #3 was more reluctant to eat the dried mint than the other calves had been for the green mint, but it would consume between 0.9 and 1.4 kilograms daily (TABLE III). The calf consumed 11.8 kilograms of dried mint over a ten-day period and died on the twelfth day.

TABLE III
 AMOUNT OF MINT HAY CONSUMED AND SYMPTOMS OF CALF #3

| | Day 1 | Day 2 | Day 3 | Day 4 | Day 5 | Day 6 |
|--------------------|---------|---------|---------|-----------------|--------------------|----------------|
| AMOUNT OF MINT FED | 1.4 kg | 0.9 kg | 1.4 kg | 0.9 kg | 1.4 kg | 1.4 kg |
| SYMPTOMS | Normal | Normal | Normal | Normal | Normal | Normal |
| TEMPERATURE | 101°F | 101°F | 101°F | 103°F | 102°F | 100°F |
| RESPIRATORY RATE | 32/min. | 36/min. | 32/min. | 32/min. | 36/min. | 32/min. |
| | Day 7 | Day 8 | Day 9 | Day 10 | Day 11 | Day 12 |
| AMOUNT OF MINT FED | 14. kg | 0.9 kg | 1.4 kg | 0.9 kg | None | None |
| SYMPTOMS | Normal | Normal | Normal | Mildly dyspneic | Extremely dyspneic | Died 6:00 a.m. |
| TEMPERATURE | 100°F | 100°F | 100°F | 98°F | 98°F | |
| RESPIRATORY RATE | 36/min. | 40/min. | 40/min. | 48/min. | 80/min. | |

On the first day of the experiment, the calf had a rectal temperature of 101°F and a respiratory rate of 32/minute. The values changed very little over the first nine days. On the tenth day, the first symptoms of intoxication were noted. These symptoms consisted of a mild expiratory grunt, slight dyspnea, serous nasal discharge and a slightly increased respiratory rate (48/minute). On the eleventh day, the calf was very depressed, anorectic, and was severely dyspneic with a loud expiratory grunt. The respiratory rate was increased to

80/minute, the nasal discharge continued and the calf could not be forced to move. Calf #3 continued to worsen and died at 6:00 a.m. on day twelve.

Calf #4 was given mint collected in January. It received, by rumen fistula, 2.2 kilograms daily for three days for a total of 6.6 kilograms (TABLE IV). The calf remained asymptomatic throughout the experiment and was observed for the next four weeks with no clinical abnormalities noted. The limited supply of mint was exhausted after the third day and thus the experiment could not be continued.

TABLE IV
AMOUNT OF DRIED MINT CONSUMED AND SYMPTOMS OF CALF #4

| | Day 1 | Day 2 | Day 3 |
|----------------------|---------|---------|---------|
| AMOUNT OF MINT GIVEN | 2.2 kg | 2.2 kg | 2.2 kg |
| SYMPTOMS | Normal | Normal | Normal |
| TEMPERATURE | 102°F | 101°F | 101°F |
| RESPIRATORY RATE | 30/min. | 32/min. | 36/min. |

Necropsy

Postmortem examinations were performed on the three calves immediately following death. In calf #1, the lungs were swollen to such an extent that a prominent imprint of the ribs on the lung tissue was apparent when the thorax was opened. The lungs had several large bullous areas which were filled with air. The largest of these areas measured

7.5 centimeters across. Emphysema was prominent in the lungs, the mediastinum, and the pericardial sac. Although edema was present, it was less prominent than the emphysema. The interlobular septa were widened by both gas bubbles and fluid. A great variation in lung color was evident, ranging from various shades of purple to the normal light pink. The rumen contents contained several square-stemmed plant parts that were identified as Perilla frutescens.

The gross lesions in calf #2 were not as prominent as those in calf #1. The lungs were not as swollen and the large bullous areas that were so prominent in calf #1 were lacking. Like calf #1, there was little edema present grossly in comparison to the emphysema. Interstitial, mediastinal, and pericardial emphysema were prominent.

The lung changes of calf #3 were also not as grossly evident as those in calf #1. However, edema was more significant than in either of the first two calves. While pulmonary emphysema was not as prominent as in calves #1 and #2, it was still present and extended into the mediastinum and pericardium.

Histopathology

The lungs of calf #1 showed increased cellularity in all sections. The interlobular septae were moderately to markedly thickened by a light pink homogenous material (edema) and emphysema. The pulmonary capillary bed was markedly engorged with blood. Alveolar spaces had a very adenomatosis-like appearance with a thickening of alveolar septae. The thickening was due to engorged capillaries, edema, and an extensive proliferation of type II pneumocytes which totally lined many alveolar spaces. Most alveolar spaces contained some macrophages and sloughed

type II pneumocytes. Neutrophils and eosinophils were present in many bronchioles and surrounding alveolar spaces. The histopathologic conclusion was atypical interstitial pneumonia.

The lungs of calf #2 revealed nearly the identical lesions as those of calf #1. The conclusion again was atypical interstitial pneumonia considered as severe as in calf #1 except that slightly less emphysema was noted.

The lungs of calf #3 showed more edema than either calf #1 or #2. Most of the alveolar spaces of calf #3 were flooded with edema. Some of the interlobular septae were moderately thickened by edema and trapped air. The histopathologic conclusion was extensive, severe pulmonary edema and emphysema.

There were no liver lesions noted in any of the three animals.

Toxicology

High pressure liquid chromatographic analysis on the five extracted samples revealed the following perilla ketone concentrations:

1. Old mint stems from Arkansas bales - no perilla ketone detected.
2. Green mint (assorted stems, leaves and seed parts) -
30 mg% perilla ketone.
3. Green perilla seed parts only - 45 mg% perilla ketone.
4. Dried mint "hay" (assorted stems, leaves, and seed parts) -
15 mg% perilla ketone.
5. Dried mint collected in January - 5 mg% perilla ketone.

CHAPTER V

DISCUSSION

Preliminary experiments with dry perilla stems from the Arkansas hay failed to produce any symptoms of AIP in the sheep. The lack of clinical signs could be explained following high pressure liquid chromatographic analysis of this mint since no perilla ketone was detected. When the mint was sorted from the hay, only the stems were removed to be ground and given to the sheep as the fragile leaves and seed parts fell off during this process. High pressure liquid chromatographic analysis of several specimens indicated that perilla ketone was more concentrated in the seed parts. Cattle feeding on the hay probably would have consumed the more palatable leaves and seed parts rather than the woody stems. Therefore, the failure of the experimental animal to develop AIP from the hay may be the result of a feeding error by giving stems (low in perilla ketone) rather than leaves and seed parts (high in perilla ketone). Cattle in a field situation would most likely consume leaves and seed parts rather than the woody stems. None of the leaves or flowering parts from the old bales were analyzed for perilla ketone content.

Additional factors which may have contributed to the cattle deaths in the field were the environmental conditions, the way the mint was given, and the extensive mold accumulation throughout the hay. The hay was fed in February when lower temperatures and wetter conditions may have added an additional stress to the cattle and made them more

susceptible to development of AIP. The owners reported that very foggy, humid conditions were present during the time the losses occurred.

The bales were harvested in late July or early August and remained unopened until they were fed. At this time of the harvest season, the forage is dry and does not need the lay time in the field that it would require earlier. Therefore, there was probably less time from mowing until baling and less opportunity for the aromatic perilla ketone to volatilize. When the mint was given to the sheep, the bales were spread out and the stems sorted and ground in a Wylie hammer mill which allowed ample time and conditions for the volatile perilla ketone to escape into the air.

The extensive mold scattered throughout the hay might have had a synergistic effect with the perilla and the environmental conditions in the production of atypical interstitial pneumonia. Since moldy feeds are often given as a cause of AIP, the combination of perilla and mold may have resulted in a greater response than either alone.

Finally, the use of a sheep in the experiment rather than a cow could have been responsible for the negative results. Sheep may be more resistant to perilla induced atypical interstitial pneumonia than cattle.

Calf #1 consumed 15.5 kilograms of green perilla over a four-day period and died on the seventh day. The clinical signs of intoxication did not develop until the fourth day after all of the mint had been ingested, but they rapidly worsened by day five. The second calf showed clinical signs of intoxication within hours of its first ingestion of green mint and died in 23 hours after having ingested only 2.3 kilograms. Individual variation was probably the primary factor involved in

this distinct difference in reaction as some animals are apparently more susceptible to perilla ketone than others. Thus, smaller quantities would be required to produce the syndrome in more sensitive animals than would be necessary to produce the same syndrome in more resistant animals.

Other factors might have been responsible such as different ruminal pH's in the two calves and a different batch of mint. Perilla ketone has been thought to be released from the plant in the rumen and absorbed intact to exert its pulmonary toxic action. It has been postulated that if rumen pH was manipulated, the absorption of perilla ketone could be increased or decreased. This theory has been demonstrated with other compounds, depending on whether the compound in the gastrointestinal tract exists in the ionized or unionized state at that particular pH. The unionized form of a compound is usually absorbed most rapidly. The ratio of ionized to unionized changes as the pH changes (37). It has been shown that calves which have received high concentrate rations tend to have lower ruminal pH's than others that have received high roughage diets. Thus the second calf might have had a different ruminal pH from the first allowing more perilla ketone to be in the unionized form and therefore, be more rapidly absorbed. However, all animals received the same diet prior to the feeding trials and would have likely had similar ruminal pH's.

Finally, the mint fed to the second calf was obtained at a different location and approximately a month later than that given to the first calf. The second lot was more mature as it had greater numbers of flowering parts than the first. Therefore, the perilla ketone content may have been greater in the second picking.

Calf #3 that consumed the dried mint required 11.8 kilograms (dry weight) over an eleven-day period to produce death. The increased

quantity required was expected since perilla ketone is quite volatile and large quantities undoubtedly escaped as the mint dried. This factor was verified by the HPLC analysis which showed that the dried mint contained approximately half the perilla ketone of the green mint (15 mg% to 30 mg%). Also, the calf refused to consume large quantities of mint at a feeding. Thus it received low daily doses which might have been detoxified before any significant lesions were produced while larger amounts could have overwhelmed the detoxification systems and produced pulmonary lesions more rapidly.

Calf #4, given 6.6 kilograms of dried mint collected in January, failed to develop any symptoms of intoxication. Several factors may have been responsible for the failure of signs of intoxication to develop. It had been previously theorized that mint allowed to stand in the field after a hard freeze became nontoxic (34). This calf was much larger than the other experimental calves and would have likely required more mint to produce intoxication. Also, the mint was ground in a Wylie hammer mill which could have allowed any remaining perilla ketone to volatilize. The HPLC analysis of this mint sample revealed only 5 mg% perilla ketone.

The clinical signs were nearly identical in all affected calves and were consistent with those described for AIP of other etiologies. The main difference was the duration of intoxicating symptoms as two calves lingered for several days, during which time they became weaker and more cyanotic while the other calf expired after several hours.

On postmortem examination, calf #1 had the most dramatic lung lesions with large bullae scattered over the pulmonary tissue. Both calf #1 and calf #2 showed more emphysema than edema. The difference in gross pathology in these two calves may have been due to length of illness

as the prolonged dyspnea of calf #1 might have destroyed more lung tissue and allowed the large bullae to develop. The necropsy of calf #3 showed less emphysema and more edema than calves #1 or #2.

Histopathologic examinations of the lungs from calf #1 and calf #2 showed that the lesions were nearly identical. In fact, several pathologists thought it impossible for such lesions present in calf #2 to have developed so rapidly. These pathologists considered three to four days a minimum for the development of lesions of such magnitude. However, calf #3, while not having as dramatic microscopic lesions as #1 or #2, did have more edema present in both the alveoli and in the interlobular septa.

From the experimental work it appears the flowering tops (seed parts) are the most toxic parts of perilla. Therefore, the toxicity of the plant would be increased during the flowering stage in late July through September. In addition, other forage often becomes scarce late in the growing season and therefore cattle would be more likely to eat perilla. The stems apparently are not as toxic as the flowering parts as they contain less perilla ketone. Also, the stems were not as readily consumed as the other more palatable parts of the plant. Dried mint was found to contain considerably less perilla ketone than green mint.

There appeared to be a great deal of variation between animals of the same age and breed regarding the toxicity of perilla ketone. Due to the economics of poisoning calves, a large number were not available for additional work; nor was the perilla easily administered to most animals. Therefore, the conclusions which could be drawn from this experiment were limited without additional animals. Some mint harvested early in the season before the plant flowers should be analyzed to determine the

perilla ketone content and the toxicity in calves at this time. Finally, an analysis of lung tissue should be performed in an animal immediately after death to determine if perilla ketone is present in the affected tissue. The results would be of considerable value in more completely implicating perilla ketone as the cause of the lesions.

CHAPTER VI

SUMMARY

In this study, Perilla frutescens or purple mint produced atypical interstitial pneumonia (AIP) in three of four calves to which it was given. The amount required to produce the syndrome ranged from 2.3 to 15.5 kilograms of green mint and 11.8 kilograms of dried mint. The clinical syndromes of intoxication were very similar in symptomatology but quite different in duration. One calf lived only 23 hours after initial ingestion of mint while the others lived seven and twelve days, respectively. Necropsy examinations showed varied amounts of pulmonary emphysema and edema. The lungs of the two calves that died from the green mint had more emphysema while those of the one that died from the dry mint had more edema. Two of the three animals displayed nearly identical microscopic lung lesions that were characterized by emphysema and a marked proliferation of type II pneumocytes. Edema was more prominent in the other calf's lungs and there was minimal proliferation of type II cells.

The flowering or seed parts of perilla were found by HPLC analysis to contain the highest concentration of perilla ketone which is considered the toxic agent. The flowered stage of perilla, from July until the first frost, has been observed as the most toxic period. Cattle may be forced to graze this plant during the late summer months when other forages are scarce. As the plant dries, considerable loss of

perilla ketone occurs since it is quite volatile. Thus, dried mint does not appear as hazardous as green perilla, but ample perilla ketone remains to cause intoxication.

We have presented in this paper an overview of the problem caused by purple mint and some experimental work conducted in an attempt to determine the quantity required to produce AIP and death. We found that many factors are involved in the production of this condition by perilla. We observed that both green and dried perilla mint produced atypical interstitial pneumonia and death in cattle.

BIBLIOGRAPHY

1. Tucker, J.O., L.R. Maki. "Acute Pulmonary Emphysema of Cattle." Am. J. of Vet. Res., Vol. 23 (1962), pp. 821-823.
2. Moulton, J.E., J. B. Harrold, M.A. Horning. "Pulmonary Emphysema in Cattle." J. Am. Vet. Med. Assoc., Vol. 139 (196), pp. 669-677.
3. Carlson, J.R., E.O. Dickinson. "Tryptophan Induced Pulmonary Edema and Emphysema in Ruminants." Effects of Poisonous Plants on Livestock, Vol. 1. Academic Press, New York, New York (1978), pp. 177-221.
4. Mackenzie, A., J.E. Ford, K.J. Scott. "Pasture Levels of Tryptophan in Relation to Outbreaks of Fog Fever." Res. in Vet. Sci., Vol. 19 (1975), pp. 227-228.
5. Jones, L.P. "A Perspective on Interstitial Pulmonary Emphysema and Edema (IPE) of Cattle." Southwestern Vet., Vol. 25 (1972), pp. 193-195.
6. Pascoe, R.R., M.D. McGavin. "Atypical Interstitial Pneumonia." Vet. Rec., Vol. 85 (1969), pp. 276-277.
7. Black, J.T., D.W. Thomas. "Acute Pulmonary Emphysema in Utah." J. Am. Vet. Med. Assoc., Vol. 158 (1971), pp. 2047-2052.
8. Williams, G.D., J. Hatkin, L.P. Jones. "Acute Respiratory Distress Syndrome Occurring in Texas Pastured Cattle." Am. Assoc. of Vet. Lab Diagnosticians - 20th Ann. Proceedings (1977), pp. 327-338.
9. Maki, L.R., J.O. Tucker. "Acute Pulmonary Emphysema of Cattle." Am. J. of Vet. Res., Vol. 23 (1962), pp. 824-826.
10. Schofield, F.W. "Acute Pulmonary Emphysema of Cattle." J. Am. Vet. Med. Assoc., Vol. 112 (1948), pp. 254-259.
11. Goodman, A.A. "Bovine Asthma." The North Am. Vet., Vol. 37 (1956), pp. 850-852.
12. Yokoyama, M.T., J.R. Carlson, E.R. Dickinson. "Ruminal and Plasma Concentrations of 3-Methylindole Associated with Tryptophan Induced Pulmonary Edema and Emphysema in Cattle." Am. J. Vet. Res., Vol. 36 (1975), pp. 1349-1352.

13. Bradley, G.J., J.R. Carlson. "3-MI Effects on Goat Lungs: Electron Microscopy." J. Am. Sci., Vol. 42 (1976), p. 1575.
14. Pirie, H.M., R.G. Breeze, I.E. Selman, A. Wiseman. "Fog Fever in Cattle." Vet. Rec., Vol. 95 (1974), pp. 479-483.
15. Dungworth, D.L., L.W. Schwartz. "The Reaction of the Lung to Injury." Advances in Veterinary Science and Comparative Medicine, Vol. 26 (1982), pp. 162-170.
16. Dungworth, D.L. "Interstitial Pulmonary Disease." Advances in Veterinary Science and Comparative Medicine, Vol. 26 (1982), pp. 173-199.
17. Hammond, A.C., J.R. Carlson, R.G. Breeze, I.E. Selman. "Progress in the Prevention of Acute Bovine Pulmonary Emphysema." Life Sciences, Vol. 14 (1979), pp. 9-14.
18. Addison, A.W. "Acute Pulmonary Emphysema in Cattle." Mod. Vet. Pract., Vol. 46 (1965), p. 78.
19. Linnabary, R.D., B.J. Wilson, J.E. Garst, M.A. Holscher. "Acute Bovine Pulmonary Emphysema (ABPE) - Perilla Ketone Another Cause." Am. Assoc. of Veterinary Diagnosticians - 20th Ann. Proceedings (1977), pp. 323-326.
20. Yokoyama, M.T., J.R. Carlson. "Dissimilation of Tryptophan and Related Indolic Compounds by Ruminal Microorganisms in vitro." Applied Microbiology, Vol. 27 (1972), pp. 540-548.
21. Hammond, A.C., J. R. Carlson. "3-Methylindole Metabolic Excretion in Goats." J. An. Sci., Vol. 42 (1976), p. 1575.
22. Terry, M.L., B.J. Bradley. "3-Methylindole and Naturally Occurring ABPE." J. An. Sci., Vol. 42 (1976), p. 1575.
23. Hammond, A.C., J.R. Carlson, R.G. Breeze. "Indole Toxicity in Cattle." Vet. Rec., Vol. 107 (1980), pp. 344-346.
24. Bray, T.M., J.R. Carlson. "Role of Mixed-Function Oxidase in 3-Methylindole Induced Acute Pulmonary Edema in Goats." Am. J. Vet. Res., Vol. 40 (1979), pp. 1268-1272.
25. Bradley, B.J., J.R. Carlson. "A Gas-Liquid Chromatographic Procedure for the Determination of Indole and 3-Methylindole in Bovine Plasma." Analytical Biochemistry, Vol. 59 (1974), pp. 214-219.
26. Acheson, R. "An Introduction to the Chemistry of Heterocyclic Compounds." 3rd Edition Interscience, Academic Press, New York, New York (1976), p. 151.

27. Wilson, B.J., J.E. Garst, R.D. Linnabary. "Pulmonary Toxicity of Naturally Occuring 3-Substituted Furans." Effects of Poisonous Plants on Livestock. Academic Press, New York, New York (1978), pp. 311-323.
28. The Merck Index. 9th Edition, Merck & Co., Inc. Rahway, New Jersey (1976), p. 553.
29. Fernald, M.L. Gray's Manual of Botany, 8th Edition. American Book Company, New York, New York (1950), p. 474.
30. Gleason, H.A. The New Britton and Brown Illustrated Flora of the Northeastern United States and Adjacent Canada, Vol. 3. Lancaster Press, Lancaster, Pennsylvania (1952), pp. 91-93.
31. Waterfall, V.T. Keys to the Flora of Oklahoma, 5th Edition. Student Union Bookstore, Stillwater, Oklahoma (1966), p. 41.
32. Cornell, D., M. Johnston. Manual of the Vascular Plants of Texas. Texas Research Foundation, Renner, Texas (1970), p. 97.
33. Morrison, F.B. Feeds and Feeding, 22nd Edition. The Morrison Publishing Co., Ithaca, New York (1956), p. 323.
34. Peterson, D.R. Proceedings, Symposium on Acute Bovine Pulmonary Emphysema (ABPE). Laramie, Wyoming (1965), pp. \$1-\$13.
35. Peterson, D.R. Personal Communication. Stillwater, Oklahoma. October 16, 1982.
36. Case Files, Oklahoma Animal Disease Diagnostic Laboratory, Stillwater, Oklahoma, August 10, 1982.
37. Klaassen, C.D. "Absorption, Distribution, and Excretion of Toxicants." Toxicology, The Basic Science of Poisons. Macmillan Publishing Co., Inc., New York, New York (1975), pp. 31-34.

VITA /

Larry Alan Kerr

Candidate for the Degree of

Master of Science

Thesis: PERILLA FRUTESCENS TOXICITY IN CATTLE

Major Field: Physiological Sciences

Biographical:

Personal Data: Born in Waynesburg, Pennsylvania, July 9, 1946,
the son of Mr. and Mrs. Kenneth Kerr.

Education: Graduated from Clay-Battelle High School, Blacksville,
West Virginia, in May 1964; received Bachelor of Science
degree in Animal Science from West Virginia University in
August 1968; received Doctor of Veterinary Medicine from
Oklahoma State University in May 1971; enrolled in Master
of Science in Physiological Sciences at Oklahoma State
University, 1982; completed requirements for the Master
of Science degree at Oklahoma State University in December,
1983.

Professional Experience: Practiced veterinary medicine, Veterinary
Associates, Inc., Bluefield, West Virginia, 1971-1980; Residency
in Veterinary Toxicology, Oklahoma Animal Disease Diagnostic
Laboratory, 1980-1983; Assistant Professor, Toxicology,
College of Veterinary Medicine, Mississippi State University,
1983-present.