

ISOLATION, PARTIAL CHARACTERIZATION, AND  
PATHOLOGIC EFFECTS OF A MYOTOXIN  
FROM BOTHROPS ASPER VENOM

By

JOSE MARIA GUTIERREZ

Bachelor of Science

Universidad de Costa Rica

San José, Costa Rica

1977

Submitted to the Faculty of the  
Graduate College of the  
Oklahoma State University  
in partial fulfillment of  
the requirements for  
the Degree of  
DOCTOR OF PHILOSOPHY  
May, 1984

Thesis  
1984D  
6984i  
COP. 2



ISOLATION, PARTIAL CHARACTERIZATION, AND  
PATHOLOGIC EFFECTS OF A MYOTOXIN  
FROM BOTHROPS ASPER VENOM

Thesis Approved:

*Charlotte L. Ownby*  
\_\_\_\_\_  
Thesis Adviser

*Everett Short Jr.*  
\_\_\_\_\_

*George V. Odell*  
\_\_\_\_\_

*Leota L. Roff, Jr.*  
\_\_\_\_\_

*Norman D. Durham*  
\_\_\_\_\_  
Dean of the Graduate College

## ACKNOWLEDGEMENTS

I thank Dr Charlotte L. Ownby, who has been an excellent guide and friend. She supported my efforts without any hesitation and has been an example of a hard-working and outstanding scientist. I would like to express my deep appreciation to Dr George V. Odell for his encouragement, friendship, and permanent support during these years. I would also like to thank Drs Everett Short and Lester Rolf, who were members of my committee and made valuable contributions to my plan of study and research project.

Thanks are due to the Departments of Physiological Sciences and Biochemistry of Oklahoma State University, and especially to the following persons who helped in different ways: Dr Bruce Lessley, Dr Subbiah Sangiah, Dr Ta-Hsiu Liao, Terry Colberg, Sue Ann Hudiburg, Denisse Rex, Jane Ramberg, Janice Green Pennington, Vinita Pill, Debbie Czarniecki, Suzanne Spears, and Michael Gleason.

I also acknowledge the support of the Oklahoma Agricultural Experiment Station, the National Institute of Allergy and Infectious Diseases, and the Office of International Programs, Oklahoma State University.

I am especially thankful to Universidad de Costa Rica for supporting my graduate work in a time of serious eco-

conomic crisis in my country. To Dr Luis Cerdas and the rest of the personnel of the Instituto Clodomiro Picado, Universidad de Costa Rica, for donating the venom and for being so helpful in many respects. Also, to Dr Róger Bolaños, who motivated me to work in the field of snake venoms and fully supported my first efforts in research.

I would like to thank my wife Irma, with whom life is so enjoyable, for her continual encouragement and understanding. I thank my parents for being sensitive and compassionate, and for having known what was really important.

This dissertation is dedicated to my wife, to my parents, and to my brothers and sisters.

## TABLE OF CONTENTS

Chapter	Page
I. INTRODUCTION . . . . .	1
II. REVIEW OF LITERATURE . . . . .	3
Snake Venoms: Introduction . . . . .	3
Local Effects Induced by Snake Venoms . . . . .	7
Cell Injury . . . . .	29
Skeletal Muscle Regeneration . . . . .	36
Venoms of <u>Bothrops atrox</u> and <u>Bothrops asper</u> . . . . .	40
III. ISOLATION OF A MYOTOXIN FROM BOTHROPS <u>ASPER</u> VENOM: PARTIAL CHARACTERIZATION AND ACTION ON SKELETAL MUSCLE . . . . .	54
Introduction . . . . .	54
Materials and Methods . . . . .	55
Results . . . . .	64
Discussion . . . . .	80
IV. PATHOGENESIS OF MYONECROSIS INDUCED BY CRUDE VENOM AND A MYOTOXIN OF <u>BOTHROPS</u> <u>ASPER</u> . . . . .	84
Introduction . . . . .	84
Materials and Methods . . . . .	85
Results . . . . .	86
Discussion . . . . .	103
V. SKELETAL MUSCLE REGENERATION AFTER MYONECROSIS INDUCED BY CRUDE VENOM AND A MYOTOXIN OF <u>BOTHROPS</u> <u>ASPER</u> . . . . .	111
Introduction . . . . .	111
Materials and Methods . . . . .	113
Results . . . . .	115
Discussion . . . . .	134
VI. SUMMARY AND CONCLUSIONS . . . . .	137
LITERATURE CITED . . . . .	141

LIST OF TABLES

Table	Page
I. Properties of Hemorrhagic Components Isolated from Snake Venoms . . . . .	9
II. Properties of Myotoxic Components Isolated from Snake Venoms . . . . .	20
III. Enzymes Present in <u>Bothrops atrox</u> and <u>Bothrops asper</u> venoms . . . . .	42
IV. Amino Acid Composition of <u>Bothrops</u> <u>asper</u> Myotoxin . . . . .	70
V. Effect of Verapamil on Myotoxicity Induced by <u>Bothrops asper</u> toxin . . . . .	76

## LIST OF FIGURES

Figure	Page
1. Ion Exchange Chromatography of <u>B. asper</u> Venom on CM-Sephadex . . . . .	66
2. Polyacrylamide Gel Electrophoresis of <u>B. asper</u> Myotoxin . . . . .	66
3. Molecular Weight Estimation of <u>B. asper</u> Myotoxin . . . . .	68
4. Ouchterlony Agarose Gel-Diffusion Plate of <u>B. asper</u> Myotoxin and Antivenom . . . . .	68
5. Light Micrographs of Skeletal Muscle After Injection of <u>B. asper</u> Venom and Myotoxin . . . . .	72
6. Changes in Plasma Creatine Kinase Levels After Injection of <u>B. asper</u> Venom and Myotoxin . . . . .	75
7. Effects of <u>B. asper</u> Myotoxin on Intracellular Calcium Levels . . . . .	75
8. Thin Layer Chromatogram of Phospholipids from Muscle Injected with <u>B. asper</u> Myotoxin . . . . .	79
9. Light Micrographs of Skeletal Muscle After Injection of <u>B. asper</u> Myotoxin . . . . .	89
10. Electron Micrograph of Skeletal Muscle 30 Minutes After Injection of <u>B. asper</u> Myotoxin . . . . .	91
11. Electron Micrograph of Skeletal Muscle Three Hours After Injection of <u>B. asper</u> Myotoxin . . . . .	94
12. Electron Micrograph of Skeletal Muscle 24 Hours After Injection of <u>B. asper</u> Myotoxin . . . . .	96
13. Mitochondrial Changes in Skeletal Muscle After Injection of <u>B. asper</u> Myotoxin . . . . .	96



Figure	Page
14. Light Micrographs of Skeletal Muscle After Injection of <u>B. asper</u> Venom . . . . .	99
15. Electron Micrograph of Skeletal Muscle 30 Minutes After Injection of <u>B. asper</u> Venom . . . . .	99
16. Electron Micrograph of Skeletal Muscle Three Hours After Injection of <u>B. asper</u> Venom . . . . .	102
17. Electron Micrographs of Skeletal Muscle Six Hours After Injection of <u>B. asper</u> Venom . . . . .	105
18. Development of Hemorrhage After Injection of <u>B. asper</u> Venom . . . . .	105
19. Light Micrographs of Regenerating Skeletal Muscle After Injection of <u>B. asper</u> Myotoxin . . . . .	117
20. Electron Micrograph of a Regenerating Muscle Cell One Week After Injection of <u>B. asper</u> Myotoxin . . . . .	119
21. Electron Micrograph of a Regenerating Muscle Cell Two Weeks After Injection of <u>B. asper</u> Myotoxin . . . . .	119
22. Light Micrographs of Skeletal Muscle One Week After Injection of <u>B. asper</u> Venom . . . . .	123
23. Electron Micrograph of Collagen Fibers Two Weeks After Injection of <u>B. asper</u> Venom . . . . .	125
24. Electron Micrograph of Adipocyte Precursor One Week After Injection of <u>B. asper</u> Venom . . . . .	128
25. Light Micrograph of Skeletal Muscle Four Weeks After Injection of <u>B. asper</u> Venom . . . . .	130
26. Light Micrograph of Skeletal Muscle Four Weeks After Injection of <u>B. asper</u> Venom . . . . .	130
27. Cell Diameters in Regenerating Muscle Cells After Injection of <u>B. asper</u> Venom and Myotoxin . . . . .	133

## NOMENCLATURE

A <sub>280</sub>	Absorbance at 280 nm
CK	Creatine kinase
CM	Carboxymethyl
DEAE	Diethylaminoethyl
DFP	Diisopropylfluorophosphate
DNA	Deoxyribonucleic acid
EDTA	Ethylene diaminetetraacetic acid
g	Gram
KCl	Potassium chloride
KOH	Potassium hydroxide
LD <sub>50</sub>	Lethal dose 50%
mA	Milliampere
mg	Milligram
ml	Milliliter
nm	Nanometer
nmol	Nanomole
PSS	Physiologic saline solution
RNA	Ribonucleic acid
SEM	Standard error of the mean
TEMED	N,N,N',N', tetramethylethylenediamine
Tris	Tris (hydroxymethyl)-amino methane
µg	Microgram
µl	Microliter

## CHAPTER I

### INTRODUCTION

From a medical point of view, Bothrops asper is the most important snake in Costa Rica (Picado, 1931; Jiménez and García, 1969). According to Bolaños (1982), there were 477 snakebite cases admitted to Costa Rican hospitals in 1979, of which 220 were attributed to B. asper. The action of this venom is highly complex and includes both local and systemic effects (Jiménez and García, 1969). Clinical experience indicates that the polyvalent antivenom produced in Costa Rica is effective in neutralizing systemic effects (Jiménez and García, 1969; Bolaños, 1971). However, an experimental study demonstrated that local effects (myonecrosis, hemorrhage, and edema) are neutralized only partially when antivenom is administered after B. asper inoculation (Gutiérrez et al., 1981). This finding has significant implications, since sequelae such as dysfunction and tissue loss have been observed in patients bitten by B. asper.

The pathogenesis of myonecrosis induced by this venom has been preliminarily studied at both light (Gutiérrez et al., 1980a) and electron (Arroyo and Gutiérrez, 1981) microscopic levels. These studies showed that the venom acts very rapidly on skeletal muscle cells, inducing myo-

necrosis in less than one hour after injection. However, no studies have been done using purified venom components. Since snake venoms are highly complex mixtures, it is necessary to work with purified myotoxic components in order to gain a better understanding on their mode of action.

In this study, the mode of action of crude B. asper venom and a purified myotoxin on skeletal muscle has been analyzed using a combined biochemical and morphological approach. The rationale behind this project was that a better understanding of the mechanism of action of the venom may result in improved treatment procedures. As a first step, a myotoxin was purified to homogeneity; it was partially characterized and used as a tool in the study of the pathogenesis of myonecrosis. One of the main objectives of these studies was to investigate the action of the toxin on the plasma membrane of skeletal muscle cells. Furthermore, in an attempt to understand the process of tissue loss resultant from the local action of the venom, a study was performed on the skeletal muscle regeneration that occurs after myonecrosis induced by injections of crude venom and purified myotoxin.

## CHAPTER II

### REVIEW OF LITERATURE

#### Snake Venoms: Introduction

Snakes (order Squamata, suborder Serpentes) are classified in the families Boidae, Aniliidae, Uropeltidae, Xenopeltidae, Leptotyphlopidae, Acrochordidae, Colubridae, Hydrophiidae, Elapidae, Viperidae, and Crotalidae (Goin and Goin, 1962). Only species belonging to the last five families are able to inject a poisonous secretion produced by specialized glands located in the oral cavity (Tu, 1977). Snakes from the family Colubridae have their fangs in a rear anatomical position. This fact decreases the possibility of bites in humans. However, there are reports of such cases, several which were fatal (Mebs et al., 1978). By far, the most important snakes from a medical point of view are those classified in the families Hydrophiidae, Elapidae, Viperidae, and Crotalidae, since they have front-located fangs and are able to inject their venoms in humans and other animals.

Snake venoms are highly complex biological substances composed of proteins, carbohydrates, amino acids, nucleotides, and inorganic ions (Tu, 1977). These venoms contain a wide variety of enzymes such as proteases, phospholipases,

nucleotidases, phosphodiesterases, esterases, L-amino acid oxidases, hyaluronidases, and acetylcholinesterases (Iwanaga and Suzuki, 1979). In addition, they contain nonenzymatic toxic peptides such as curarimimetic neurotoxins and cardiotoxins (Karlsson, 1979).

The action of snake venoms on mammals has been extensively studied (see reviews by Jiménez-Porras, 1968 and Mebs, 1978). Although no clear-cut classification can be made in regard to their pharmacological activity, it can be said that the venoms from species classified in the families Elapidae and Hydrophiidae induce three main effects: (a) Neurotoxicity due to the presence of neurotoxins. Some of them act at the presynaptic element of the neuromuscular junction (e.g. notexin, taipoxin,  $\beta$ -bungarotoxin and textilotoxin), whereas others have a curarimimetic, nondepolarizing, postsynaptic mode of action (e.g. short and long neurotoxins); (b) cardiovascular alterations, partially caused by cardiotoxins which are small basic peptides able to depolarize the plasma membrane of several kinds of cells and to induce fibrillation in cardiac muscle; and (c) myotoxicity, either due to myotoxic phospholipases A or to cardiotoxins.

On the other hand, venoms of snakes classified in the families Viperidae and Crotalidae are responsible for four main kinds of alterations: (a) Cardiovascular shock, mediated through acute loss of fluid from the vascular compartment and through the cardiotoxic action of some toxins;

(b) hemorrhage, both local and systemic; (c) necrosis of muscular tissue, due both to the direct action of myotoxins and as a consequence of tissue ischemia; and (d) alterations in the hemostatic mechanisms due to the action of coagulant and anticoagulant enzymes. Thus, besides the systemic effects, these venoms induce a very complex series of local effects (myonecrosis, hemorrhage, and edema) which often result in sequelae such as loss of tissue and dysfunction. Crotalus durissus terrificus and Crotalus scutulatus venoms are exceptions to this scheme, since they induce prominent neurotoxic effects due to the presynaptic toxins crotoxin and mojave toxin, respectively.

In Costa Rica there are 17 species of poisonous snakes classified in the families Crotalidae (12), Elapidae (4), and Hydrophiidae (1) (Savage, 1976). The majority of snakebite cases are due to species from the genus Bothrops. According to Bolaños (1982), 477 patients were admitted to Costa Rican hospitals in 1979 due to snakebites. Among them, 409 were caused by snakes from the genus Bothrops; there were 220 cases in which B. asper was responsible for the accident. This author stated that due to the large amount of venom that this snake is able to inject, it is responsible for the most serious cases. In addition, many snakebite cases are not treated in hospitals; taking these into account, it has been estimated that between 2000 and 3000 people are bitten annually by snakes in Costa Rica (Bolaños, 1971). Similar observations had been made ear-

lier by Picado (1931) and Jiménez and García (1969). The use of antivenom in the treatment of snakebites in Costa Rica started in the 1920's with an antivenom produced at the Instituto Butantan, Sao Paulo, Brazil (Picado, 1931; Bolaños, 1971). Later, a polyvalent antivenom was developed in Costa Rica (Bolaños, 1971). It is prepared in horses immunized with a mixture of the venoms of Bothrops asper, Crotalus durissus durissus, and Lachesis muta (Bolaños, 1971; Bolaños and Cerdas, 1978). The use of this antivenom has markedly reduced the mortality in snakebite accidents (Bolaños, 1971). However, it has been shown experimentally that this antivenom is only partially able to neutralize the local effects (myonecrosis, hemorrhage, and edema) induced by B. asper venom when antivenom is administered after venom injection (Gutiérrez et al., 1981). The reason for this partial lack of neutralization is not the absence of antibodies, because when venom and antivenom are incubated prior to injection, all three local effects are neutralized (Gutiérrez et al., 1981). The cause of poor neutralization "in vivo" is the rapid development of these effects; the three of them are evident one hour after injection in mice (Gutiérrez et al., 1980a). Therefore, it is reasonable to assume that they develop within minutes after envenomation making their neutralization very difficult. A better understanding of the pathogenesis of these effects is indeed a necessary step towards the development of new and more successful methods for the neutralization of local effects.



## Local Effects Induced by Snake Venoms

### Hemorrhage

Hemorrhage is one of the most extensively studied local effects (Jiménez-Porras, 1968; Tu, 1977; Ohsaka, 1979). All venoms of viperine and crotaline snakes tested so far induce hemorrhage, except those of Vipera russelli (Homma and Tu, 1971), newborn specimens of Crotalus durissus durissus (Lomonte et al., 1983), and some samples of Crotalus scutulatus (Glenn et al., 1983).

The mode of action of hemorrhagic components has been studied using purified toxins isolated from the venoms of Trimeresurus flavoviridis and Crotalus atrox. In the case of HR-I, a hemorrhagic component from T. flavoviridis venom, ultrastructural (Ohsaka, 1979), cinephotomicrographic (Ohsaka et al., 1971), and biochemical (Ohsaka et al., 1973) studies indicate that it induces hemorrhage per diapedesis. This means that erythrocytes escape through the intercellular junctions whereas endothelial cells are not destroyed. Since hemorrhagic components from T. flavoviridis venom are able to release proteins and carbohydrates from isolated glomerular basement membrane (Ohsaka et al., 1973) it has been proposed that the hemorrhagic activity of these components depends on their ability to hydrolyze the components of the basement membrane (Ohsaka et al., 1973).

On the other hand, hemorrhagic toxins a, b, and e from

the venom of Crotalus atrox induce hemorrhage per rhexis. Electron microscopic analysis indicates that the toxins are able to disrupt the integrity of endothelial cells, and that erythrocytes escape through gaps formed within the cells (Ownby et al., 1978). In their study, Ownby et al. (1978) observed that intercellular junctions were intact.

Several hemorrhagic components have been isolated and characterized from the venoms of a variety of species. Some of them are: hemorrhagic principles HR1a, HR1b, HR2a, and HR2b from the venom of Trimeresurus flavoviridis (Omori-Sato and Ohsaka, 1970; Takahashi and Ohsaka, 1970; Omori-Sato and Sadahiro, 1979); hemorrhagic factor I (HR-I) from Agkistrodon halys blomhoffii venom (Oshima et al., 1972); proteinases AC<sub>1</sub>, AC<sub>2</sub>, AC<sub>3</sub>, and AC<sub>4</sub> from Agkistrodon acutus venom (Sugihara et al., 1980); four hemorrhagic toxins from Vipera palestinae venom (Grotto et al., 1967; Ovadia, 1978); hemorrhagic toxins a, b, c, d, and e from Crotalus atrox venom (Bjarnason and Tu, 1978); hemorrhagic factor HF2 from Bothrops jararaca venom (Mandelbaum et al., 1975); viriditoxin from Crotalus viridis viridis venom (Fabiano and Tu, 1981); and a hemorrhagic proteinase from the venom of Crotalus horridus horridus (Civello et al., 1983a). Table I is a summary of their biochemical characteristics.

Although there are differences among these toxins, they possess several characteristics in common. For instance, they have relatively high molecular weights (range between 26,000 and 115,000 daltons), and many of them are

TABLE I  
 PROPERTIES OF HEMORRHAGIC COMPONENTS  
 ISOLATED FROM SNAKE VENOMS

Toxin	Species	Molecular Weight *	Isoelectric pH *	Proteolytic Activity **	Reference
Hemorrhagic factor I	<u>Agkistrodon blomhoffii</u> <u>halys</u>	85,000	4.7	(-)	Oshima et al. (1972)
AC <sub>1</sub>	<u>Agkistrodon acutus</u>	24,500	4.7	(+)	Nikai et al. (1982)
AC <sub>4</sub>	<u>Agkistrodon acutus</u>	33,000	4.4	(+)	Sugihara et al. (1980)
AaHI	<u>Agkistrodon acutus</u>	22,000	4.6	(+)	Xu et al. (1981)
AaHII	<u>Agkistrodon acutus</u>	22,000	5.3	(+)	Xu et al. (1981)
AaHIII	<u>Agkistrodon acutus</u>	22,000	>9	(+)	Xu et al. (1981)
HR-1	<u>Trimeresurus flavoviridis</u>	104,000	4.3	(-) casein (+) glomerular basement membrane	Omori-Satoh and Ohsaka (1970) Ohsaka et al. (1973)

TABLE I (Continued)

Toxin	Species	Molecular Weight	Isoelectric pH	Proteolytic Activity	Reference
HR-2a	<u>Trimeresurus flavoviridis</u>	n.d.	n.d.	{-} casein {+} glomerular basement membrane	Takahashi and Ohsaka (1970) Ohsaka et al. (1973)
HR-2b	<u>Trimeresurus flavoviridis</u>	n.d.	n.d.	{-} casein {+} glomerular basement membrane	Takahashi and Ohsaka (1970) Ohsaka et al. (1973)
HF-2	<u>Bothrops jararaca</u>	50,000	n.d.	{+}	Mandelbaum et al. (1975)
Hemorrhagin	<u>Vipera palestinae</u>	44,000	acidic	{+}	Grotto et al. (1967)
HR 1	<u>Vipera palestinae</u>	60,000	basic	{+}	Ovadia (1978)
HR 2	<u>Vipera palestinae</u>	60,000	acidic	{+}	Ovadia (1978)
HR 3	<u>Vipera palestinae</u>	60,000	acidic	{-}	Ovadia (1978)
Hemorrhagic toxin a	<u>Crotalus atrox</u>	68,000	acidic	{+}	Bjarnason and Tu (1978)

TABLE I (Continued)

Toxin	Species	Molecular Weight	Isoelectric pH	Proteolytic Activity	Reference
Hemorrhagic toxin b	<u>Crotalus atrox</u>	24,000	basic	(+)	Bjarnason and Tu (1978)
Hemorrhagic toxin c	<u>Crotalus atrox</u>	24,000	acidic	(+)	Bjarnason and Tu (1978)
Hemorrhagic toxin d	<u>Crotalus atrox</u>	25,700	acidic	(+)	Bjarnason and Tu (1978)
Hemorrhagic toxin e	<u>Crotalus atrox</u>	24,500	5.6	(+)	Bjarnason and Tu (1978)
HP IV	<u>Crotalus horridus</u> <u>horridus</u>	52,000	5.1	(+)	Civello et al. (1983a)
Viriditoxin	<u>Crotalus viridis</u> <u>viridis</u>	115,000	4.8	(+)	Fabiano and Tu (1981)

\* n.d. = not determined

\*\* (-) = absence of proteolytic activity; (+) = presence of proteolytic activity

acidic proteins. Furthermore, most of these toxins are proteinases, although some hemorrhagic principles of T. flavoviridis, a hemorrhagic factor from Agkistrodon halys, and a toxin from Vipera palestinae (Takahashi and Ohsaka, 1970; Oshima et al., 1972; Ovadia, 1978) showed very little, if any, proteolytic activity. Nevertheless, it has been pointed out (Bjarnason and Tu, 1978) that a toxin may have a very particular substrate specificity and that the casein assay may fail to detect this activity. Interestingly, the hemorrhagic components of T. flavoviridis venom had very little hydrolytic activity towards casein (Omori-Satoh and Ohsaka, 1970), but were able to hydrolyze glomerular basement membrane (Ohsaka et al., 1973). Furthermore, the hemorrhagic toxin from Crotalus horridus failed to show activity towards casein, but hydrolyzed glomerular basement membrane, hide powder azure, and fibrinogen (Civello et al., 1983b). It is therefore possible that with the proper substrates, all hemorrhagic toxins will eventually show proteolytic activity.

Several hemorrhagic components from A. acutus and C. atrox contain one mole of zinc per mole of protein (Bjarnason and Tu, 1978; Nikai et al., 1982). When this cation is removed, both the proteolytic and hemorrhagic activities are eliminated, and the secondary structure of the toxins is changed, as detected by Raman spectroscopy.

## Myonecrosis

Necrosis of skeletal muscle has been reported after bites of snakes from the families Viperidae (Efrati, 1979) and Crotalidae (Rosenfeld, 1971; Tu, 1977), as well as of some species of Elapidae (Campbell, 1979) and Hydrophiidae (Reid, 1979). These reports agree with many experimental studies. For instance, among 37 crotaline, viperine, and elapine snake venoms tested in mice, only the one from Ophiophagus hannah did not induce myonecrosis (Homma and Tu, 1971). Currently, the myotoxic activity of snake venoms and toxins is being quantitated by histological examination, i.e. determination of the myonecrotic index (Ownby et al., 1982) and by biochemical determinations, i.e. quantitation of plasma creatine kinase (CK) levels (Ownby et al., 1982; Mebs et al., 1983). Also, the presence of myoglobin in urine has been used as an indicator of myotoxicity induced by sea snake and elapid snake poisoning (Reid, 1961; Mebs and Samejima, 1980).

Biochemical studies have culminated with the isolation and characterization of several myotoxins present in snake venoms. Biochemically and pharmacologically they can be grouped in four categories: (a) Myotoxic phospholipases A<sub>2</sub>; (b) small basic toxins such as myotoxin a and crotamine; (c) cardiotoxins, also called "membrane active polypeptides"; and (d) toxins that induce both hemorrhage and myonecrosis that might be called "myotoxic hemorrhagins".

The biochemical properties of these toxins will be reviewed in the following section.

Myotoxic Phospholipases A<sub>2</sub>. Several very toxic phospholipases have been isolated from Australian elapid venoms. Notexin, present in the venom of the tiger snake Notechis scutatus was isolated by Karlsson et al. (1972) using ion-exchange chromatography on BioRex 70. This toxin is a phospholipase A<sub>2</sub> (Harris and MacDonell, 1981) which acts as a presynaptic neurotoxin affecting the release of acetylcholine from the motor nerve terminal. In 1975, Harris et al. reported that notexin was also a very potent myotoxin. It is comprised of a single chain of 119 amino acids and has a molecular weight of 13,574 (Karlsson et al., 1972). Halpert and Eaker (1976) purified another presynaptic neurotoxin, notechis-5, which is remarkably similar to notexin. It is able to induce both neurotoxicity and myotoxicity, although it is 10-20 times less potent than notexin (Halpert and Eaker, 1976; Harris and Johnson, 1978). The amino acid sequences of notexin and notechis-5 have been elucidated and they show a high degree of homology (Halpert and Eaker, 1976).

Taipoxin is another very potent presynaptic neurotoxin with phospholipase A<sub>2</sub> activity (intravenous LD<sub>50</sub> = 2 µg/Kg) isolated from the venom of Oxyuranus scutellatus (Fohlman et al., 1976). It induces neuromuscular blockade due to inhibition of neurotransmitter release from motor nerve



terminals (Fohlman et al., 1976). Harris and Maltin (1982) showed that taipoxin is myotoxic, too. It is a complex of three subunits ( $\alpha, \beta, \gamma$ ) with a molecular weight of 45,600. Although subunit  $\alpha$  is able to induce neurotoxicity and myotoxicity by itself, the ternary complex is more toxic than the individual subunits (Fohlman et al., 1976; Harris and Maltin, 1982). The primary structure of  $\alpha$  and  $\gamma$  subunits of taipoxin has been elucidated (Fohlman et al., 1977; Lind and Eaker, 1982).

Fohlman and Eaker (1977) isolated a myotoxic phospholipase A from the venom of the common sea snake Enhydrina schistosa. This was an experimental corroboration of the clinical observations made by Reid (1961) which indicated that myotoxicity may be more relevant than neurotoxicity in humans bitten by sea snakes (Reid, 1979). When injected in mice, the toxin is able to induce myoglobinuria at doses of 30  $\mu\text{g}/\text{Kg}$ . This myotoxin has a single chain of 120 amino acids with a molecular weight of 13,500 (Fohlman and Eaker, 1977). Its amino acid sequence was described by Lind and Eaker (1981). It is interesting that modification of one histidine residue results in the loss of both myotoxic and enzymatic activities (Fohlman and Eaker, 1977).

A series of highly myotoxic phospholipases A were isolated from venoms of the Australian elapid snakes Pseudechis australis (Leonardi et al., 1979), P. coletti and P. porphyriacus (Mebs and Samejima, 1980). They are all neutral or basic proteins with molecular weights around 14,000

and composed of 120-129 amino acids.

Two closely related presynaptic neurotoxins have been isolated from rattlesnake venoms. They have been named crotoxin and mojave toxin, and were isolated from the venoms of Crotalus durissus terrificus and Crotalus scutulatus, respectively (Slotta and Fraenkel-Conrat, 1939; Bieber et al., 1975; Cate and Bieber, 1978). Besides being neurotoxic, they have phospholipase A<sub>2</sub> activity and induce myonecrosis (Gopalakrishnakone et al., 1979, 1980). They are composed of two subunits, one of them has the phospholipolytic and toxic activities, whereas the other plays the role of "chaperone molecule", preventing the toxic subunit from binding to nonspecific receptor sites (Habermann and Breithaup, 1978).

These myotoxic phospholipases A differ quantitatively and also qualitatively in their pharmacological effects. Some of them are highly neurotoxic (e.g. notexin and taipoxin), whereas others have less neurotoxicity (Mebs and Samejima, 1980). Furthermore, the magnitude of their myotoxic action is very different, since even toxins as similar as notechis-5 and notexin differ markedly in their ability to promote muscle damage (Harris and Johnson, 1978). In the case of notexin (Harris and MacDonell, 1981), taipoxin (Harris and Maltin, 1982) and crotoxin (Hawgood, 1982), it has been proposed by these authors that their myotoxic effect is based on the ability of the toxins to hydrolyze phospholipids of the muscle cell plasma membrane,

affecting the regulation of membrane permeability to macromolecules and ions.

Small Basic Toxins Present in Rattlesnake Venoms. The second group of myotoxins is represented by crotamine and myotoxin a, isolated from the venoms of Crotalus durissus terrificus and Crotalus viridis viridis, respectively (Laure, 1975; Cameron and Tu, 1977). Similar toxins have been isolated from the venoms of Crotalus viridis concolor (Engle et al., 1983), C. v. helleri (Russell et al., 1978), and Crotalus durissus durissus (Eneff, 1982). Thus, this is a family of rattlesnake toxins. The biochemical similarities between myotoxin a and crotamine were demonstrated by Cameron and Tu (1978). All of these toxins are small, highly basic polypeptides with molecular weights around 4000-5000 daltons. Pharmacological studies with crotamine have led to the conclusion that it increases the permeability of the sarcolemma to  $\text{Na}^+$  by acting on the sodium channel (Chang and Tseng, 1978). These toxins are devoid of enzymatic activity; the primary structure of crotamine (Laure, 1975) and myotoxin a (Fox et al., 1979) have been elucidated.

Cardiotoxins. The third group of myotoxins includes the so called cardiotoxins, which are also referred to as "membrane active polypeptides" (Chang, 1979). From the pharmacological point of view, these toxins induce a broad spectrum of effects. They are directly hemolytic, induce

contraction of skeletal muscle, and have cardiotoxic as well as cytotoxic effects (Mebs, 1978; Karlsson, 1979). Morphological studies with the cardiotoxic fraction of Dendroaspis jamesoni venom show that it also induces myonecrosis (Duchen et al., 1974).

Chemically, cardiotoxins are small polypeptides that show some similarity to the curarimimetic postsynaptic neurotoxins. However, there are significant differences between them; cardiotoxins contain more lysines and about 25 hydrophobic amino acid residues, whereas the neurotoxins have less than 20 (Karlsson, 1979). Furthermore, the invariant residues that characterize neurotoxins are absent in cardiotoxins (Karlsson, 1979). It has been proposed that these toxins bind to the membrane by an electrostatic interaction. Then, the hydrophobic parts of the toxin penetrate into the hydrophobic components of the membrane, disrupting its structure (Klibansky et al., 1968). Experimental evidence in support of interaction between cardiotoxins and membranes includes elimination of the thermotropic behavior characteristic of normal membranes when they are incubated with cardiotoxins (Dufourcq et al., 1982) and induction of ultrastructural alterations in membranes which were detected by freeze-fracture studies (Gulik-Krzywicki et al., 1981).

Myotoxic Hemorrhagins. The fourth group of myotoxins is formed by the hemorrhagic toxins which have been reported

to induce myonecrosis. They are hemorrhagic toxin b from Crotalus atrox venom (Bjarnason and Tu, 1978; Ownby et al., 1978) and viriditoxin from the venom of Crotalus viridis viridis (Fabiano and Tu, 1981). Hemorrhagic toxin b has a molecular weight of 27,000 daltons and is made of a single polypeptide chain. Viriditoxin, on the other hand, is made of two subunits and has a molecular weight of 115,000 daltons. Both of them are proteolytic enzymes. It has been suggested by Gleason et al. (1983) that viriditoxin-induced myotoxicity is due to the ischemia which develops in skeletal muscle as a secondary effect of the hemorrhagic action of the toxin.

A summary concerning the biochemical and pharmacological characteristics of myotoxins isolated from snake venoms is presented in Table II.

#### Pathogenesis of Myonecrosis Induced by Snake Venoms and Toxins

Most snake venoms from species classified in the families Viperidae, Crotalidae, Elapidae, and Hydrophiidae induce myonecrosis after experimental inoculations (Homma and Tu, 1971; Tu, 1977). Homma and Tu (1971) classified venom-induced muscle necrosis into three groups according to the morphology of the cells: (a) Myolytic, in which the cytoplasm has dense clumps of myofibrillar material as well as empty spaces; (b) coagulative, in which the cell has a more hyaline and homogeneous appearance; and (c) mixed, in which

TABLE II  
 PROPERTIES OF MYOTOXIC COMPONENTS  
 ISOLATED FROM SNAKE VENOMS

Toxin	Species	Molecular Weight *	Enzymatic Activity**	Other Toxic Activities**	Reference
Notexin	<u>Notechis scutatus</u>	13,574	Phospholipase A	Neurotoxic	Karlsson et al. (1972)
Taipoxin	<u>Oxyuranus scutellatus</u>	45,600	Phospholipase A	Neurotoxic	Fohlman et al. (1976)
Mulgotoxin a	<u>Pseudechis australis</u>	13,484	n.d.	Neurotoxic	Leonardi et al. (1979)
Myotoxin VIII-A	<u>Pseudechis australis</u>	13,400	Phospholipase A	Neurotoxic	Mebis and Samejima (1980)
Myotoxin I-B	<u>Pseudechis porphyriacus</u>	13,400	Phospholipase A	Neurotoxic	Mebis and Samejima (1980)
Myotoxin IV	<u>Pseudechis colletti</u>	14,100	Phospholipase A	Neurotoxic	Mebis and Samejima (1980)
Myotoxin II	<u>Pseudechis colletti</u>	14,170	Phospholipase A	Neurotoxic	Mebis and Samejima (1980)
Myotoxin	<u>Enhydrina schistosa</u>	13,500	Phospholipase A	Neurotoxic	Fohlman and Eaker (1977)

TABLE II (Continued)

Toxin	Species	Molecular Weight *	Enzymatic Activity**	Other Toxic Activities**	Reference
Cardiotoxin	<u>Dendroaspis jamesoni</u>	n.d.	(-)	Cardiotoxic	Duchen et al. (1974)
Crotoxin	<u>Crotalus durissus terrificus</u>	24,000	Phospholipase A	Neurotoxic	Breithaupt et al. (1974)
Mojave toxin	<u>Crotalus scutulatus</u>	24,310	Phospholipase A	Neurotoxic	Cate and Bieber (1978)
Crotamine	<u>Crotalus durissus terrificus</u>	4,900	(-)	(-)	Laure (1975) Cameron and Tu (1978)
Myotoxin a	<u>Crotalus viridis viridis</u>	4,400	(-)	Hemolytic	Cameron and Tu (1977)
Peptide C	<u>Crotalus viridis helleri</u>	4,990	(-)	Vasculotoxic	Maeda et al. (1978) Russell et al. (1978)
Myotoxin	<u>Crotalus viridis concolor</u>	n.d.	(-)	(-)	Engle et al. (1983)

TABLE II (Continued)

Toxin	Species	Molecular Weight *	Enzymatic Activity**	Other Toxic Activities**	Reference
Myotoxin I	<u>Crotalus durissus durissus</u>	4,500	(-)	(-)	Eneff (1982)
Myotoxin II	<u>Crotalus durissus durissus</u>	3,800	(-)	(-)	Eneff (1982)
Viriditoxin	<u>Crotalus viridis viridis</u>	115,000	Protease	Hemorrhagic	Fabiano and Tu (1981)
Hemorrhagic toxin <b>b</b>	<u>Crotalus atrox</u>	27,500	Protease	Hemorrhagic	Bjarnason and Tu (1978) Ownby et al. (1978)

\* n.d. = not determined

\*\* (-) = absence of activity



both myolytic and coagulative areas are present. Their observations were made in tissues obtained 24 hr after venom injection. It was concluded that elapine venoms induce a myolytic type of necrosis, and that viperine and crotaline venoms from the genus Crotalus produce coagulative necrosis, whereas crotaline venoms from Agkistrodon, Bothrops, and Trimeresurus induce either myolytic or mixed necrosis. Nevertheless, it was pointed out by the authors that there was not a completely pure type of necrosis. The fact that tissue examination was performed at a single time after injection raises the possibility that the different types of necrosis may represent different stages in the dynamic process of cell degeneration. Until time sequence studies are done this alternative explanation cannot be disregarded.

The pathogenesis of myonecrosis following inoculation of several snake venoms and toxins has been studied at the ultrastructural level. These studies will be reviewed and some general conclusions will be drawn.

Naja naja kaouthia. Stringer et al. (1971) inoculated mice intramuscularly with a supralethal dose of 15  $\mu\text{g/g}$  of crude venom. Tissue was taken at the time of death which ranged from 30 to 70 minutes. At the light microscopic level, they observed necrotic cells with clumped masses of myofibrils filling the cellular space. Ultrastructurally, most of the organelles showed dramatic changes. Myofilaments coalesced into amorphous masses in which the sar-

comeric structure was severely altered. Sarcoplasmic reticulum became fragmented into swollen vacuoles, and nuclei underwent pycnosis and chromatolysis. Some mitochondria became swollen and showed alterations of the cristae, whereas others had dense material in their interior. In some cases, the integrity of mitochondria was clearly disrupted. The authors observed that the plasma membrane was the last cellular component to be affected.

Crotalus viridis viridis. The effects of intramuscular injections of this venom (1  $\mu\text{g/g}$ ) in mice were studied by Stringer et al. (1972). Tissue was obtained three hours after inoculation. The earliest pathological change was a conspicuous dilatation of the sarcoplasmic reticulum. Later on myofibrils were affected, the first changes taking place at the H band and M line, and then at the Z line. Myofibrillar organization was eventually lost and myofilaments became an amorphous mass. Mitochondrial alterations consisted of swelling and rupture of the cristae. Initially, nuclei became pycnotic; in later stages of degeneration, chromatin clumped around the nuclear envelope. In regard to the plasma membrane, the authors observed that it was destroyed only during the late stages of the degenerative process.

Myotoxin a is a low molecular weight basic polypeptide isolated from Crotalus viridis viridis venom (Cameron and Tu, 1977). It induces muscle degeneration without hem-

orrhage. The pathogenesis of its effect was studied by Ownby et al. (1976) by inoculating 1.5  $\mu\text{g/g}$  of this toxin. Tissue was examined at six time periods at both light and electron microscopic levels. The first changes were dilatation of sarcoplasmic reticulum and perinuclear space. The size of sarcoplasmic reticulum vacuoles increased up to a maximum at 24 hours, when they occupied a considerable portion of the cells. Later on, the size of the vacuoles decreased as the myofilaments underwent dissolution. By 48 hours there was some disintegration of myofibril structure, and by 72 hours degenerating myofibrils lacked their normal striated pattern. Mitochondria were not affected until 48-72 hours, when they became swollen and showed areas devoid of cristae. Both T tubules and plasma membrane remained intact when the rest of the organelles showed alterations. Myotoxin a did not affect blood vessels, erythrocytes, or connective tissue cells. It was concluded that the sarcoplasmic reticulum was the primary target of this toxin.

Myotoxin a increases the plasma levels of creatine kinase (CK) when injected intramuscularly into mice (Ownby et al., 1982). This is a biphasic increase, the first peak is related to a muscle contracture observed during the first three hours. The second peak correlated well with the vacuolation index which is a quantitative expression of myotoxicity. This means that when the cells are undergoing vacuolation at the sarcoplasmic reticulum, the permeability

of the plasma membrane is altered as it allows the escape of a macromolecule such as creatine kinase. Thus, although the plasma membrane does not show morphological abnormalities, it may be functionally impaired as a result of myotoxin action.

Bothrops asper. Arroyo and Gutiérrez (1981) examined muscle tissue one and three hours after intramuscular injections of this venom (2.5  $\mu\text{g/g}$ ) in mice. Two main types of affected cells were described. Some cells showed changes at the sarcoplasmic reticulum which was dilatated, whereas the rest of the organelles were normal. Other cells had prominent pathologic changes in different organelles. In these cells the myofibrillar structure was drastically affected, and myofilaments became amorphous dense masses. Mitochondria were initially swollen and then lost their integrity. Sarcoplasmic reticulum became fragmented into a large number of small vesicles; plasma membrane showed discontinuities and gaps in several places. Furthermore, the venom induced hemorrhage and edema, as well as a drastic increase in creatine kinase levels (Gutiérrez et al., 1980a) which peaked three hours after injection. This corroborated the rapid development of muscle damage.

Notechis scutatus. The mode of action of the myotoxic phospholipase  $A_2$  notexin has been investigated at the histological, histochemical, ultrastructural, physiological, and biochemical levels (Harris et al., 1975; Pluskal et al.,

1978; Harris and Johnson, 1978; Harris and Mac Donell, 1981). Within one to three hours after subcutaneous injection of 2  $\mu$ g of notexin in rats there were focal lesions in the plasma membrane, with hypercontraction of myofilaments and formation of clumped masses of myofibrillar material. By three to six hours the necrotic cells were invaded by phagocytes, and by 24 hours there were cell remnants enclosed by a basal lamina, whereas phagocytes were abundant inside necrotic cells. Simultaneously, during the first hours there was an increase in the wet weight of the muscle. By six hours the plasma creatine kinase levels were elevated five to ten fold. Interestingly, blood vessels and muscle spindles were not affected by the toxin. Harris and Mac Donell (1981) showed that notexin was able to hydrolyze muscle phospholipids "in vivo", since the presence of lysolecithin was demonstrated by thin layer chromatography in extracts obtained 24 hours after notexin injection. Therefore, it was proposed that notexin is able to hydrolyze the phospholipids of skeletal muscle plasma membrane, and that such enzymatic activity is the basis of the mode of action of notexin.

Oxyuranus scutellatus. Crude venom and the purified neurotoxin taipoxin induced very similar effects on skeletal muscle when injected subcutaneously in rats (Harris and Maltin, 1982). There was an early increase in wet weight of muscle. Evidence of myonecrosis at the ultrastructural

level was found one hour after injection. The plasma membrane was disrupted in some areas, whereas the basal lamina was preserved. Myofibrils were overcontracted and disorganized. By six hours necrosis was more intense and there was a phagocytic cell infiltrate. The membrane potential decreased from -77 mV in control samples to -16 mV in venomated muscle by the third hour, and it continued to decrease reaching values of -6 mV at 24 hours. It was suggested that taipoxin acts by affecting the integrity of the plasma membrane and that such effect may be related to the phospholipase A activity of the toxin. Neither crude venom nor taipoxin affected blood vessels and muscle spindles.

Dendroaspis jamesoni. Duchen et al. (1974) inoculated mice intramuscularly with 20  $\mu$ g of cardiotoxin isolated from this venom. Dense eosinophilic masses were observed inside the cells 30 minutes after injection. By three hours, there was an infiltrate of polymorphonuclear leukocytes which became abundant by 24 and 48 hours. Ultrastructural examination of the tissue revealed early changes by 30 minutes including sarcolemmal disruption, loss of Z line, dilatation of sarcoplasmic reticulum, disorganization of myofibrils with the presence of amorphous masses and empty spaces in between, and swollen mitochondria with condensed cristae. The changes induced by cardiotoxin on the neuromuscular junction were also studied. Axons were well preserved, but during the first four days there were

changes in the motor-end plates which often appeared irregularly shaped. As muscle cells underwent necrosis, the postsynaptic sarcolemmal membrane was often absent.

### Cell Injury

Cell death has been defined as an irreversible reaction to an injury (Trump et al., 1981). According to these authors, there are two general kinds of acute cell injury, namely, cell injury due to direct damage to the plasma membrane, and cell injury due to inhibition or uncoupling of mitochondrial oxidative phosphorylation. Both of them lead to a series of degenerative events at the cellular level that are initially reversible and later on become irreversible. The point where irreversibility is achieved has been called "point of no return" and theoretically it is the moment when a given cell is dead (Trump et al., 1981). It is important to differentiate which pathologic events characterize reversible changes in cell degeneration and which are typical of irreversible damage. A series of stages in the process of ischemic cell injury has been described by Trump et al. (1981, 1982). Although these stages have been studied in ischemic conditions, many of them occur during acute cell injury in general:

Stage 1: Oxygen tension decreases and the rate of anaerobic glycolysis is enhanced. This results in the production of lactic acid and a decrease in cellular pH. Simultaneously, ATP levels start to drop. The normal mitochondrial

matrix granules disappear and there is clumping of the nuclear chromatin, as well as decrease in RNA synthesis. Another significant early change is a decrease in active transport systems.

Stage 2: A decrease in the activity of  $\text{Na}^+ - \text{K}^+$ ATPase results in an influx of sodium and water. Morphologically, this causes enlargement of the endoplasmic reticulum, a phenomenon that has been observed in kidney cells treated with ouabain (Ginn et al., 1968). Blebs start to form at the cell surface probably due to changes in microtubules and microfilaments. The fall of the levels of ATP continues simultaneously with an accumulation of ADP, AMP, inosine, and lactic acid.

Stage 3: Mitochondria show conspicuous condensation in the inner compartment. Dilatation of endoplasmic reticulum continues as the plasma membrane is unable to maintain the normal ionic gradients.

Stage 4: It is at this stage that the transition to the "point of no return" starts. A significant change in mitochondria is the development of "high amplitude swelling" which probably represents impairment of inner membrane function. This effect may be the result of an increase in the cytosolic calcium levels as a consequence of the inability of active transport systems to keep the normal concentration gradient across the membrane. It has been reported that swelling of skeletal muscle mitochondria results from active uptake of calcium by this organelle (Publicover



et al., 1977). Also, calcium-activated phospholipases may be responsible for the disruption of mitochondrial membranes.

Stage 5: Besides being swollen, mitochondria show flocculent densities in the inner compartment. The intracellular membrane systems are severely affected, and hydroxyapatite crystals can be seen in mitochondria. It has been pointed out that mitochondrial flocculent densities constitute the hallmark of irreversibility in cell injury (Trump et al., 1981).

Stage 6: There is a rapid digestion of intracellular components. Lysosomal contents are released into the cytosol. At this stage, there is a change in the staining characteristics of the cytoplasm as a result of the degenerative processes.

Stage 7: This stage is characterized by a further degradation of cellular material.

The progression of these stages varies in different types of cell injury. Furthermore, all cells do not reach irreversible stages at the same time, since this depends on the type of injury as well as on the properties of the cell. However, there are common features in the process of cell death in a number of pathologic conditions.

There is a growing body of evidence which indicates that the key element in the process of cell death is an elevation in the cytosolic calcium levels (Trump et al., 1981; Farber, 1981; Farber, 1982). The calcium ion regulates a

wide variety of cellular processes and its concentration is carefully controlled by mechanisms such as active transport at the plasma membrane, mitochondria and sarcoplasmic reticulum (Carafoli, 1982). Normally, there is a one-thousand fold gradient in calcium concentration across the plasma membrane, extracellularly in the mM and intracellularly in the  $\mu\text{M}$  ranges. If the permeability of the plasma membrane to calcium is increased, as would happen in membrane damage, an influx of calcium occurs down its electrochemical gradient. Such an increase in cytosolic calcium levels would result, among other things, in: (a) Activation of calcium-dependent phospholipases and proteases (Trump et al., 1981; Shier, 1982). Phospholipases would further degrade phospholipids from the plasma membrane as well as from intracellular membranes such as mitochondria and endoplasmic reticulum. Also, the reaction product lysolecithin is itself a membrane-active agent; (b) alterations in the cytoskeleton which induce changes in the cellular shape; and (c) inhibition or alteration of several important metabolic pathways that are under calcium control.

The suggested role of calcium in cell death has been corroborated in several ways:

(a) When cells are incubated with the calcium ionophore A-23187, they undergo a series of degenerative changes that culminate in cell death (Publicover et al., 1978; Schanne et al., 1979). In the case of skeletal muscle, these changes resemble the ones observed in several pathologic

conditions (Publicover et al., 1978).

(b) Schanne et al. (1979) incubated rat hepatocytes with ten different membrane-active toxins in the presence and absence of calcium ions. All the toxins induced cell death when calcium was present in the medium. However, in the absence of this cation the cells were not killed, as judged by their ability to exclude Trypan blue. Thus, it was concluded that calcium influx is a determinant factor in the process of cell degeneration, since it can convert potentially reversible into irreversible cell injury.

(c) Chlorpromazine, which inhibits calcium fluxes across cellular membranes, is able to protect cultured hepatocytes incubated with the otherwise toxic galactosamine (Schanne et al., 1980). Also, the calcium antagonist verapamil prevents the myotoxicity that results after inoculation of the local anesthetic mepivacaine (Benoit et al., 1980).

Cellular injury in skeletal muscle has many features in common with the general model postulated above. However, there are some specific aspects that characterize cellular homeostasis in skeletal muscle. For instance, the regulation of calcium levels in muscle is accomplished partially by sarcoplasmic reticulum as well as by voltage-sensitive calcium channels located in the T tubules (Almers et al., 1981). To summarize, the ways through which skeletal muscle regulates its calcium levels are: (a) Plasma membrane: As in other cell types, there is a steep electrochemical gradient for calcium across the plasma membrane.

This gradient is maintained due to the relatively low permeability of the membrane to this cation, as well as by the action of active transport mechanisms that extrude calcium from the cytoplasm, and by the  $\text{Na}^+ - \text{Ca}^{2+}$  exchange system (Carafoli, 1982). (b) Sarcoplasmic reticulum: There is a high concentration of calcium in the terminal cisternae of the sarcoplasmic reticulum. When the depolarization wave arrives through the T tubules, calcium is released to the cytoplasm and muscle contraction takes place. Immediately afterwards, a  $\text{Ca}^{2+}$ -ATPase actively transports this cation which is accumulated in the sarcoplasmic reticulum (Carafoli, 1982). (c) Mitochondria: Skeletal muscle mitochondria are able to sequester calcium. Its accumulation takes priority over oxidative phosphorylation (Stadhouders, 1981). The mechanisms by which calcium influx and efflux from mitochondria take place are independent, as shown by the selective inhibition of influx by drugs such as ruthenium red (Stadhouders, 1981). Calcium influx takes place as a consequence of a transmembrane electrochemical gradient created by the vectorial extrusion of protons, according to the chemiosmotic hypothesis (Carafoli, 1982). On the other hand, calcium efflux from mitochondria takes place due to a sodium-calcium exchange system (Stadhouders, 1981; Carafoli, 1982).

There are two hypotheses which state that the increase in cytoplasmic calcium concentration is the key element in skeletal muscle cell injury. Wrogemann and Pena (1976)

suggested that such a calcium influx results in mitochondrial overload, whereas Duncan (1978) proposed that an increase in calcium levels activates a series of calcium-dependent proteolytic enzymes which are responsible for the degradation of cellular components, leading to cell death. Several calcium-dependent proteases have been isolated from skeletal muscle (Busch et al., 1972; Reddy et al., 1975; Ishiura, 1981).

According to the concepts developed by Trump et al. (1981), it can be said that most acute cell injuries in skeletal muscle derive either from alterations of the plasma membrane or from inhibition of oxidative phosphorylation in mitochondria. Three selected examples of cell injury in skeletal muscle follow.

(a) Myonecrosis induced by alpha toxin from Clostridium perfringens: It was observed in an ultrastructural study that lesions developed in the plasma membrane before any other organelle was morphologically affected (Strunk et al., 1967). Since the toxin is a phospholipase C, it is probably able to disrupt enzymatically the plasma membrane with the consequent disturbance to calcium homeostasis. The rest of the organelles degenerates as a consequence of this calcium influx.

(b) Myonecrosis in Duchenne muscular dystrophy (DMD): Although the etiology of this disorder is still a controversial subject, the currently most accepted view regards the basic genetic fault at the level of the plasma membrane

(Rowland, 1980). There is biochemical (Rowland, 1980) and ultrastructural (Mokri and Engel, 1975; Schotland et al., 1980) evidence that the plasma membrane is affected before the rest of the organelles, though the precise characterization of the basic defect has not been defined. Again, plasma membrane dysfunction results in the impairment of normal calcium permeability, as an increase in the cytosolic levels of this cation has been described in this disease (Bodensteiner and Engel, 1978). The pathologic changes described from biopsy material represent a consequence of the impaired calcium homeostasis.

(c) Myonecrosis after ischemia: This is an example of acute cell injury where there is a primary alteration in oxidative phosphorylation in mitochondria as a consequence of lack of oxygen supply. Ultrastructurally, it has been observed that pathologic changes develop at a slower rate than in other muscle diseases (Karpati et al., 1974; Hanzlíková and Schiaffino, 1977). In ischemia, the decrease in ATP synthesis results in the impairment of the active transport mechanisms that work in the regulation of calcium levels, as well as in the stoppage of many other ATP-dependent cellular reactions.

#### Skeletal Muscle Regeneration

The most widely accepted view regarding skeletal muscle regeneration is that the satellite cells first described by Mauro (1961) are the myogenic cells. These are small,

fusiform cells located within the basal lamina in skeletal muscle; they are separated from muscle cells by their plasma membranes. Satellite cell nuclei comprise one to five percent of the total nuclei located in a muscle cell (Allbrook, 1981). Morphologically, they are oval cells of about 25  $\mu\text{m}$  in length and characteristically have conspicuous and dense heterochromatin. In contrast, skeletal muscle myonuclei have more euchromatin. The cytoplasm of satellite cells is scant, with few mitochondria, small Golgi complex, and polyribosomes, but without myofilaments (Allbrook, 1981). It has been postulated that junctional complexes are not present between plasma membranes of satellite cells and muscle cells (Schmalbruch, 1978).

When muscle cells are injured, satellite cells undergo biochemical and morphological changes. These alterations are divided by Allbrook (1981) into: (a) Mitosis of reserve cells; (b) fusion of daughter cells; (c) myotube elongation; and (d) circumferential development. Using chambers "in vitro" and an inverted microscope, Bischoff (1979) studied these changes. After a lethal cell injury the plasma membrane was destroyed, but the basal lamina remained, forming a chamber within which regeneration took place. All the myonuclei regenerated during the first 24 hours, whereas the satellite cells enlarged and their nuclei became more euchromatic. After several cycles of division they became myoblasts. By five to seven days myoblasts fused to form myotubes which exhibited cross striations and contracted

spontaneously.

Morphologically, myoblasts are characterized by a large number of ribosomes which are not membrane-bound but instead are free in the cytoplasm. These structures are responsible for the basophilia that characterizes these cells. The nucleus has a higher proportion of euchromatin than in satellite cells; there is a Golgi complex usually located close to the nucleus. The presence of microtubules and microfilaments has been observed, the former running parallel to the longitudinal axis of the cells (Lipton, 1977).

Several factors are necessary for muscle regeneration to take place: (a) Basal lamina: The significance of the basal lamina has been emphasized as a scaffold for cell regeneration in skeletal muscle. Bischoff (1979) observed that when the basal lamina is mechanically disrupted "in vitro", regenerating cells escape and get lost; as a consequence, regeneration is impaired. Furthermore, Vracko and Benditt (1972) demonstrated that the basal lamina remains intact, serving as a support for regeneration after skeletal muscle injury. Once muscle cells develop, they secrete a new basal lamina. Thus, if the basal lamina is destroyed in any muscle disease, adequate regeneration is impaired. (b) Adequate blood supply: In clinical conditions it has been observed that muscle regeneration does not occur when there are ischemic conditions in the tissue (Allbrook, 1981). It is relevant to mention that studies with myoblasts grown



"in vitro" have shown that their morphology and differentiation can be modified by changing the culture conditions. For instance, in an ischemic environment the cells accumulate lipid and become indistinguishable from developing adipocytes (Lipton, 1977). Lipton (1979) proposed that impairment of regeneration in older patients suffering from Duchenne muscular dystrophy is due to increased disposition of collagen bundles and connective tissue which isolate regenerating cells from their oxygen and nutrient supply.

(c) A functional nerve supplying both afferent and efferent fibers is a necessary condition for regeneration of skeletal muscle (Hall-Craggs and Seyan, 1975).

Muscle regeneration was studied after notexin-induced myonecrosis (Harris and Johnson, 1978; Harris et al., 1980). In this case, regeneration took place within the old basal lamina tubes. In these morphological studies, regenerating cells were observed three days after toxin injection, and small immature cells were seen by the fifth or seventh day. Regeneration was complete by one month, but many cells still had centrally located nuclei, and there was a number of "split" cells in the regenerated muscle. It was pointed out that some cells showed central nuclei even six months after toxin administration. Harris (1982) observed that after muscle damage by notexin, the reconstruction of neuromuscular junctions was very rapid, since by five days functional innervation was identified in more than 50% of the cells, and by seven days 95% of

the cells showed it. Acetylcholine receptors were lost after toxin injection, but by the fourth day they were identified in regenerating muscle.

Regeneration was also studied after injections of Oxyuranus scutellatus venom and the purified neurotoxin taipoxin isolated from this venom (Harris and Maltin, 1982). As in the case of notexin-damaged muscle, regeneration proceeded fast after both venom and toxin inoculations. By three days there were small basophilic regenerating cells which developed into small immature cells by five to seven days; by thirty days the muscle was fully regenerated. At this time there were only two abnormal features: central nucleation in some cells and cell splitting. It was suggested that regeneration proceeded rapidly in part because there was no impairment of blood supply to the tissue, and also because the basal lamina was preserved.

#### Venoms of Bothrops atrox and Bothrops asper

Hoge (1966) proposed that the Central American populations of Bothrops atrox deserved a species status based on geographic origin, morphologic criteria, and immunologic properties of the venom. Since then, they have been classified in the species Bothrops asper Garman. Because many studies of this venom were done before the change in nomenclature took place, a review of the characteristics of Bothrops asper venom exclusively would exclude important

contributions related to the study of B. atrox venom. Thus, in the following section venoms from both species will be considered.

Biochemical Studies on Bothrops atrox  
and Bothrops asper venoms

A wide variety of enzymatic activities has been detected in B. atrox and B. asper venoms. Table III is a review of these activities. Also, several components present in these venoms have been purified to homogeneity. A description of their purification and properties follows.

Thrombin-like Proteinases. Batroxobin is a serine proteinase isolated from B. atrox venom which is able to convert fibrinogen into fibrin. Hence, it is a thrombin-like proteinase. Stocker and Barlow (1976) purified this protein by chromatography on DEAE-Sephadex and Sephadex G-100. Holleman and Weiss (1976) isolated two forms of it from subspecies B. a. moojeni and B. a. marojoensis by affinity chromatography on the inhibitor p-amino-benzamidine. Batroxobin is a glycoprotein made of a single polypeptide chain of 30,000 daltons. Its amino acid composition shows high content of aspartic acid and glycine. This proteinase resembles thrombin only partially, in the sense that although it is able to convert fibrinogen into fibrin, it cannot activate factor XIII nor can it aggregate platelets. Besides being a serine proteinase, batroxobin

TABLE III  
 ENZYMES PRESENT IN BOTHROPS ATROX  
 AND BOTHROPS ASPER VENOMS

Enzyme	Venom	Reference
L-Amino acid oxidase	<u>B. atrox</u>	Jiménez-Porras (1964); Kocholaty et al. (1971)
L-Amino acid oxidase	<u>B. asper</u>	Umaña (1982a)
Phosphodiesterase	<u>B. atrox</u>	Jiménez-Porras (1964); Kocholaty et al. (1971)
Endonuclease	<u>B. atrox</u>	Georgatsos and Laskowski (1962)
ATPase	<u>B. atrox</u>	Jiménez-Porras (1964)
AMPase	<u>B. atrox</u>	Jiménez-Porras (1964)
NADase	<u>B. atrox</u>	Jiménez-Porras (1964)
DNase	<u>B. atrox</u>	Jiménez-Porras (1964)
RNase	<u>B. atrox</u>	Jiménez-Porras (1964)
Phospholipase A	<u>B. atrox</u>	Kocholaty et al. (1971); Vidal and Stoppani (1971)
Phospholipase A	<u>B. asper</u>	Ferlan and Gubensek (1978); Alagón et al. (1980)
Hyaluronidase	<u>B. atrox</u>	Jiménez-Porras (1964)
Esterase	<u>B. atrox</u>	Oshima et al. (1969); Kocholaty et al. (1971)
Kininogenase	<u>B. atrox</u>	Geiger and Kortmann (1977)
Protease	<u>B. atrox</u>	Jiménez-Porras (1964); Oshima et al. (1969)
Protease	<u>B. asper</u>	Gutiérrez and Chaves (1980)

TABLE III (Continued)

---

Enzyme	Venom	Reference
Thrombin-like proteinase	<u>B. atrox</u>	Jiménez-Porras (1964); Stocker and Barlow (1976)
Thrombin-like proteinase	<u>B. asper</u>	Aragón and Gubensek (1978)
Fibrinolysin	<u>B. atrox</u>	Jiménez-Porras (1964)
Fibrinolysin	<u>B. asper</u>	Aragón et al. (1978)

---

has esterase activity.

An enzyme similar to batroxobin has been isolated from B. asper venom (Aragón and Gubensek, 1978; Aragón and Gubensek, 1981) by two methods: originally it was purified by chromatography on CM-Cellulose (Aragón and Gubensek, 1978); subsequently, it was isolated by affinity chromatography on agmatine-CH-Sepharose (Aragón and Gubensek, 1981). This protease is very similar to batroxobin, being a glycoprotein with high content of aspartic acid, and having esterase activity. Circular dichroism showed that the toxin lacks either alpha helical or beta pleated sheet structure in its secondary structure (Aragón and Gubensek, 1978).

Another thrombin-like proteinase was isolated from B. atrox venom (Kirby et al., 1979; Niewiarowski et al., 1979). This component, called thrombocytin, induces platelet aggregation, release of platelet contents, and activation of factors VIII and XIII. However, it does not convert fibrinogen into fibrin. Thus, B. atrox venom has two different enzymes, batroxobin and thrombocytin, which together have the same activities of thrombin. Thrombocytin is a glycoprotein with a molecular weight of 36,000. It is a serine proteinase, as it is inactivated by DFP and soybean trypsin inhibitor.

Factor X Activator. Hofmann et al. (1983) observed that even after incubation with DFP, B. atrox venom was able to coagulate plasma. The venom was fractionated on

DEAE-Cellulose and Sephadex G-100, and a procoagulant component with very low thrombin-like activity was isolated. This protein has a molecular weight of 77,000 and is composed of two subunits. Interestingly, the factor induced coagulation by enzymatically activating factor X, since it failed to clot plasma samples deficient in factors II, V, or X, but was able to reduce clotting time of plasma deficient in factor VII. Therefore, it resembles factor X-activator isolated from Vipera russellii venom.

Fibrinolytic Enzymes. Two fibrinolytic enzymes, named enzyme G and enzyme I, were isolated from B. asper venom by Aragón et al. (1978) through ion-exchange chromatography on CM-Cellulose and gel filtration on Sephadex G-100. Both components show proteolytic activity against casein, hemoglobin, fibrinogen, fibrin, and collagen. They are inhibited by EDTA, whereas leukocyte cytoplasmic inhibitors of neutral proteinases inhibit enzyme G but not enzyme I. Their molecular weights estimated by gel filtration are 23,500 for enzyme G and 15,300 for enzyme I. However, when estimated by SDS-polyacrylamide gel electrophoresis, the molecular weights are 18,000 for enzyme G and 10,000 for enzyme I.

Endonuclease. Georgatsos and Laskowski (1962) isolated an endonuclease from B. atrox venom by adsorption on calcium phosphate followed by ammonium sulfate fractionation and ion-exchange chromatography on DEAE-Cellulose and

Amberlite. This enzyme is able to hydrolyze both DNA and RNA at an optimal pH of 5.0.

Phosphodiesterase. By means of chromatography on phosphocellulose and affinity chromatography with O-(4-nitrophenyl)-O'-phenyl-thiophosphate ester coupled to activated Sepharose, Frischauf and Eckstein (1973) purified a phosphodiesterase from B. atrox venom. It is composed of a single polypeptide chain that has a molecular weight of 130,000.

Nerve Growth Factor. Glass and Banthorpe (1975) isolated two nerve growth factors from B. atrox venom in a three-step procedure: chromatography on QAE A-25 Sephadex, Sephadex G-100, and SPC-25 Sephadex. Both components are glycoproteins with molecular weights of 35,000. One has an isoelectric pH of 8.0 and the other of 9.0. They cross-react immunologically with nerve growth factor from V. russellii venom, but not with nerve growth factor from mouse salivary gland.

L-Amino Acid Oxidases. Umaña (1982a and 1982b) purified three isoenzymes of L-amino acid oxidase from B. asper venom. Isolation was accomplished by heating in the presence of leucine, followed by ion-exchange chromatography on DEAE-Cellulose. The three isoenzymes have similar molecular weights around 125,000, and two of them have subunits of 60,000 and 57,000 daltons. Studies on the amino



acid composition show very slight variation among these isoenzymes.

Phospholipases A. Five different phospholipases have been isolated from B. asper venom (Ferlan and Gubensek, 1978; Alagón et al., 1980). Ferlan and Gubensek (1978) performed their isolation by chromatography on Sephadex G-100, CM-Cellulose, and Sephadex G-50. Two phospholipases were isolated by this procedure. Both are toxic, and their molecular weights are 32,000 and 16,000. They differ in their amino acid composition and their optimum pH. Both phospholipases are thermally stable.

Alagón et al. (1980) were able to isolate three phospholipases A<sub>2</sub> in homogeneous state by fractionating the venom on Sephadex G-75, DEAE-Cellulose, and electrophoresis. Phospholipase type 1 has 97 amino acid residues and a molecular weight of 10,978; phospholipase type 2 has 96 residues and a molecular weight of 10,959; and type 3 enzyme contains 266 residues and has a molecular weight of 29,042. Amino acid composition corroborates the acidic nature of these proteins. Therefore, B. asper venom contains at least five different components with phospholipase A activity. Their toxic effects are yet to be studied.

A procedure for the isolation of phospholipases A present in B. neuwiedii venom was developed by Vidal and Stoppani (1971). Venom was fractionated on Sephadex G-50, Sephadex G-25 and DEAE-Sephadex. This procedure was used

by those authors to isolate phospholipases A from B. asper venom. Two active fractions were obtained from it, but they were not further characterized.

Ontogenic and Geographic Variations in the Composition of B. atrox and B. asper venoms

When venoms from newborn and adult specimens of B. asper from Costa Rica were compared, it was found that they are markedly different (Gutiérrez et al., 1980b). Electrophoretic analyses indicated that adult venoms have a band of anodic migration which is absent in venoms from newborn snakes. Also, their immunoelectrophoretic patterns were dissimilar. In regard to toxic activities, venoms from newborn specimens were more toxic since they had greater lethal, proteolytic, hemorrhagic, and edema-forming activities. Venoms from adult specimens showed higher myonecrotic and indirect hemolytic effects.

Biochemical comparisons of B. asper venoms from different Costa Rican geographic locations have demonstrated the presence of variations. Jiménez-Porrás (1964) showed that venoms from specimens collected in the Atlantic and Pacific regions of Costa Rica were clearly distinguishable on the basis of their electrophoretic pattern in starch gels. Similar observations have been made by Aragón and Gubensek (1981). Gutiérrez et al. (1980b) demonstrated that venoms from adult specimens collected in the Atlantic

slopes induce stronger hemorrhagic and myonecrotic effects than venoms from adult specimens collected in the Pacific region.

Pathophysiologic Effects Induced  
by B. atrox and B. asper Venoms

Clinical and experimental studies indicate that the pathophysiologic characteristics of envenomations by these snakes include both local and systemic effects. At the site of injection they induce hemorrhage, edema, and myonecrosis. The systemic effects are cardiovascular shock, hemorrhage, acute renal failure, and defibrination syndrome (Rosenfeld, 1971; Jiménez-Porrás et al., 1973).

Lethality. Bolaños (1972) studied the toxicity of venoms from 16 Costa Rican poisonous snakes. In the case of B. asper venom, the LD<sub>50</sub> was 18.8±3.2 µg/16-18 g mouse by the intravenous route, and 62.5±7.5 µg/16-18 g mouse by the intraperitoneal route. It was concluded that if toxicity and venom yield are taken into account, B. asper is the most dangerous snake in Costa Rica. Picado (1931) mentioned that in overall toxicity the venom of B. atrox (currently classified as B. asper) from Costa Rica is three and a half times more potent than the venom of B. atrox from South America.

Myonecrosis, Hemorrhage, and Edema. In clinical as well as in experimental conditions, a complex series of

local effects develops very fast after inoculations of B. atrox and B. asper venoms. The most important are myonecrosis, hemorrhage and edema (Picado, 1931; Jiménez and García, 1969; Gutiérrez et al., 1980a). Local effects are particularly significant since it has been observed that the polyvalent antivenom is only partially effective in neutralizing them (Gutiérrez et al., 1981).

Myonecrosis develops very fast after experimental injections of venom into mice. This is demonstrated by early histological observations of necrotic muscle cells (Tu and Homma, 1970; Gutiérrez et al., 1980a) and by rapid increase in plasma creatine kinase (CK) levels (Gutiérrez et al., 1980a). Hemorrhage and macroscopic edema develop simultaneously at the site of inoculation. The former peaks by 12 hours, and the latter shows maximum development at 24 hours; nevertheless, the three effects are conspicuous one hour after inoculation (Gutiérrez et al., 1980a). It has been proposed that the rapid development of these pathologic events is the main cause of the relative inability of the antivenom to neutralize them (Gutiérrez et al., 1981). Despite the significance of these effects, purified hemorrhagic or myotoxic components have not been isolated from these venoms.

Systemic hemorrhage is also a characteristic effect of B. atrox and B. asper envenomations (Picado, 1931; Jiménez and García, 1969; Tu and Homma, 1970; Rosenfeld, 1971). For instance, five hours after intravenous injec-

tions of B. atrox venom in mice, Tu and Homma (1970) observed hemorrhage in heart, lungs, and small intestine.

Alterations of Blood Coagulation. Picado (1931) observed that B. atrox venom induced coagulation of citrated blood in a short period of time. Jiménez-Porras (1967) performed a series of experiments in dogs by injecting intravenously a lethal dose of B. atrox venom. Coagulation time, recalcification time, and prothrombin time were infinite. Prothrombin concentration was normal, whereas fibrinogen levels were decreased, and thrombin was unable to coagulate blood from the envenomated dogs. It was proposed that the venom induces a defibrination syndrome due to its thrombin-like enzyme.

However, the situation may be more complex than that. Hofmann et al. (1983) demonstrated that even after incubation with DFP (which inhibits the thrombin-like enzyme of the venom), B. atrox venom was able to induce blood coagulation by activating factor X. It was suggested by these authors that the thrombin-like activity of the crude venom is not significantly responsible for its coagulating activity in plasma. Furthermore, these venoms also contain thrombocytin (Kirby et al., 1979) as well as fibrinolytic enzymes (Aragón et al., 1978) which affect blood coagulation mechanisms in different ways. Thrombocytin induces platelet aggregation, release of platelet contents, and activation of factor XIII. If the action of the hemorrhagic

components is taken into consideration, it can be said that these venoms simultaneously affect vascular integrity, platelet function, and plasma factors of coagulation. The clinical picture is very likely the result of the integration of these effects. Since this defibrination syndrome is a common result of envenomations due to B. atrox and B. asper, it has been recommended that routine laboratory determinations such as prothrombin time and coagulation time be used to monitor the severity of envenomations and the progress of treatment (Peña-Chavarría et al., 1970).

Cardiovascular Shock. A profound cardiovascular depression is one of the consequences of envenomations by B. atrox and B. asper (Jiménez-Porras et al., 1973; Bolaños, 1982). The pathogenesis of this effect may be related to alterations at both the cardiac and the vascular components of the system. Morales et al. (1976) demonstrated that crude B. asper venom was cardiotoxic, since it induced negative chronotropic and inotropic effects on toad hearts, as well as alterations in the conduction of the impulse. On the other hand, the fact that this venom is hemorrhagic and induces edema indicates that the vascular component is also compromised. A reduction in blood volume as a consequence of hemorrhage would contribute to the shock condition, as has been clearly demonstrated by Carlson et al. (1975) with the venom of Crotalus viridis helleri. Such reduction in blood volume may be induced directly by the

action of hemorrhagic components on the vascular integrity, or indirectly through the liberation of vasoactive compounds such as bradykinin, histamine, and prostaglandins.

Renal Alterations. Patients with severe envenomations due to B. atrox and B. asper usually develop acute renal failure (Mekbel and Céspedes, 1963; Vargas-Baldares, 1978). Mekbel and Céspedes (1963) studied the autopsies of 27 victims of snake bites in Costa Rica. In most of the cases, B. atrox (currently classified as B. asper) was responsible for the accident. Seven cases showed bilateral cortical renal necrosis; six cases had glomerular thrombi; four cases had tubular degeneration; and one case showed acute tubular necrosis. Renal changes were absent in only four cases.

Vargas-Baldares (1978) performed a similar study with 26 Costa Rican victims. Although it was not stated by the author, probably most of the cases were induced by B. asper. Sixty eight percent of the autopsies showed important renal lesions, which were divided into: distal nephron necrosis, seven cases; thrombotic microangiopathy, four cases; acute tubular necrosis, three cases; and renal cortical necrosis, three cases. These two studies emphasize the significance of renal alterations in severe cases of B. asper and B. atrox envenomations.

## CHAPTER III

### ISOLATION OF A MYOTOXIN FROM BOTHROPS ASPER VENOM: PARTIAL CHARACTERIZATION AND ACTION ON SKELETAL MUSCLE

#### Introduction

From a public health point of view Bothrops asper is the most important snake in Costa Rica (Jiménez and García, 1969). Its venom induces a complex and severe local tissue damage, characterized by edema, hemorrhage, and myonecrosis (Picado, 1931; Jiménez and García, 1969). Experimentally, these effects have been studied in mice at both light and electron microscopic levels (Tu and Homma, 1970; Gutiérrez et al., 1980a; Arroyo and Gutiérrez, 1981), as well as by quantitating the plasma concentration of creatine kinase (Gutiérrez et al., 1980a). Myonecrosis induced by this venom is particularly important, since experimental studies have shown that the polyvalent antivenom used in Costa Rica is only partially effective in neutralizing myotoxicity (Gutiérrez et al., 1981).

To provide a better understanding of this pathological phenomenon, and to improve antiserum treatment of B. asper snakebite cases, a myotoxin has been isolated from this



venom. The biochemical properties of the toxin and its physiologic effects on skeletal muscle are reported in the present chapter.

## Materials and Methods

### Venom and Chemicals

B. asper venom was generously provided by Dr. Luis Cerdas, Instituto Clodomiro Picado, Universidad de Costa Rica, San José, Costa Rica. The venom was obtained from adult specimens from the Atlantic region of Costa Rica. After collection, the venom was centrifuged at low speed, freeze-dried, and stored at  $-70^{\circ}\text{C}$ . All other drugs and chemicals were obtained from the usual commercial sources and were of the highest grade available.

### Isolation of the Myotoxin

Samples of 200 mg of venom were dissolved in 0.05 M Tris, 0.1 M KCl, pH 7.0 (Tris-KCl) buffer and chromatographed on a column of CM-Sephadex C-25 which had been equilibrated with the same buffer. The column was eluted with Tris-KCl buffer, followed by a linear salt gradient of 0.1 - 0.75 M KCl. Fractions were collected, and the absorbance of each tube at 280 nm was recorded. The tubes corresponding to each fraction were pooled, dialyzed against distilled water, and freeze-dried. Once checked for their biological activity, fraction 5 was dissolved in Tris-KCl

buffer, and applied to a Sephadex G-75 column that had been previously equilibrated with the same buffer. The major fraction was collected, its absorbance recorded at 280 nm, and it was pooled, dialyzed against distilled water, and freeze-dried.

### Homogeneity

Polyacrylamide disc gel electrophoresis was performed at pH 4.3 according to the method of Reisfeld et al. (1962). The composition of gel components was as follows: Stacking gel: 5% acrylamide, 1.25% BIS, 0.5% riboflavin, 0.24 ml 1 N KOH, 0.014 ml glacial acetic acid, 0.0023 ml TEMED per 4 ml of solution. Resolving gel: 15% acrylamide, 0.1% BIS, 0.1% ammonium persulfate, 0.72 ml 1 N KOH, 0.258 ml glacial acetic acid, 0.06 ml TEMED, in 12 ml of solution. The sample solution contained 5  $\mu$ l of 2.7% KOH in 2.9% glacial acetic acid solution, 5  $\mu$ l of 0.05% bromophenol blue solution, 10  $\mu$ l of 40% sucrose solution, and 20  $\mu$ l of sample solution. The electrophoretic run was performed for three hours at a current of 4 mA/tube. The gels were then stained with 0.5% aniline blue black in 7% acetic acid for 30 minutes, and were destained in 7% acetic acid.

### Immunodiffusion

The Ouchterlony double-diffusion technique was used (Clausen, 1969). It was performed in 1% agarose gels for 18 hours at room temperature. The following antigens were

used: B. asper myotoxin, B. asper crude venom, B. atrox crude venom, and myotoxin a isolated from the venom of Crotalus viridis viridis according to Ownby et al. (1979). Antigen concentration was 1 mg/ml. The polyvalent antivenom from the Instituto Clodomiro Picado, Costa Rica, was used; it is produced in horses immunized with a mixture of venoms of Bothrops asper, Crotalus durissus durissus, and Lachesis muta (Bolaños and Cerdas, 1978). In some experiments the anti-myotoxin a serum produced in this laboratory (Ownby et al., 1979) was also used.

#### Amino Acid Analysis

Amino acid analysis was done in a Beckman Model 120 C automatic amino acid analyzer, according to Liao et al., (1973). Samples were hydrolyzed with 6 N HCl at 110°C for 24, 48, and 72 hours. Values for threonine, serine, and tyrosine were extrapolated to time 0. In regard to the other amino acids, the corrected values were an average of the values of the three hydrolysis times.

#### Molecular Weight Estimation

Molecular weight was estimated by gel filtration in Sephadex G-75 in a column of 100 x 1.5 cm, using 0.05 M Tris, 0.1 M KCl, pH 7.0 as elution buffer. The following standards were used: Bovine serum albumin, ovalbumin, chymotrypsinogen A and Cytochrome C.

### Myotoxic Activity

Myotoxic activity was evaluated by histology and quantitation of the plasma levels of creatine kinase. Groups of four mice (20-24 g) were injected intramuscularly in the thigh with the toxin (2.5  $\mu\text{g/g}$ ). At seven time intervals after inoculation (30 minutes, 1 hour, 3 hours, 6 hours, 12 hours, 24 hours, and 48 hours) a blood sample was taken by cutting the tip of the tail. Blood was collected in heparinized capillary tubes, and plasma was obtained after centrifugation. Immediately, mice were killed and muscle sample was obtained from the injected thigh, cut into small pieces, and immersed in 2.5% glutaraldehyde for two hours. Tissue was washed three times and postfixed in osmium tetroxide for one hour. It was then dehydrated serially in ethanol, infiltrated with propylene oxide/polybed 812 (1:1), and embedded in polybed 812. Resin was polymerized by heating at 60°C for 48 hours. Thick (1  $\mu\text{m}$ ) sections were obtained in an LKB ultramicrotome, stained with Mallory's trichrome, and observed with the light microscope. Plasma creatine kinase was estimated according to Sigma Technical Bulletin 520 and was expressed in units/ml; one unit of creatine kinase results in the phosphorylation of 1 nmol of creatine per minute at 25°C. Creatine kinase determination was performed within 24 hours after sample collection.

### Hemorrhage

Mice (20-24 g) were injected intramuscularly in the thigh with the toxin (2.5 µg/g). At different time intervals they were killed, the skin of the thigh removed, and the presence of hemorrhage assessed by visual inspection. Then, tissue was processed for histology as described above, and examined for the presence of microscopic hemorrhage.

### Hemolytic Activity

Both direct and indirect hemolytic activities were evaluated by the method of Jeng et al. (1978). Indirect hemolytic assay was performed in tubes containing 10 µg of the toxin, 0.3 mg of egg yolk phosphatidylcholine, 0.6 ml of a 2.5% human erythrocyte suspension, and 50 µl of 10 mM CaCl<sub>2</sub> solution. The volume was made up to 3.0 ml with pH 7.5 physiologic saline solution. The incubation mixture for the direct hemolytic assay contained the same reagents, with the exception of phosphatidylcholine. The toxin was excluded from the blank tube. In order to have a 100% hemolysis value, erythrocytes were incubated with distilled water. Mixtures were incubated at 37°C for 30 minutes, then centrifuged in a clinical centrifuge for five minutes and the absorbances read at 540 nm.

### Phospholipase Activity "In Vitro"

The method of Habermann and Hardt (1972) was followed.

A suspension of egg yolk was incorporated into 0.6% agarose gels. Cylindrical holes were punched and emptied by suction. Each hole was filled with 10  $\mu$ l of toxin solution, and the plates were incubated at 50°C for 20 hours. Phospholipase A activity was indicated by clearing of the egg yolk in the plate. In some experiments erythrocytes were included in the gel, and the diameter of the hemolytic halo was measured in order to increase the specificity of the assay.

#### Proteolytic Activity

Hide powder azure was used as substrate for proteolytic activity, according to the method of Rinderknecht et al. (1968). In a final volume of 5 ml, using Tris 50 mM (pH 7.0) as diluent buffer, 20 mg of hide powder azure (Sigma) were incubated with different amounts of the toxin (1  $\mu$ g, 10  $\mu$ g, and 100  $\mu$ g) at 37°C for 30 minutes, with agitation at five minute intervals. At the end of the period the tubes were cooled in ice water and the contents filtered through Whatman #1 filter paper. The absorbance of the filtrates was read at 595 nm.

#### Calcium Studies

In order to follow changes in cytoplasmic calcium levels of skeletal muscle, a modification of the technique of Murphy et al. (1980) was developed using the metallochromic calcium indicator Arsenazo III (Scarpa et al., 1978).

Groups of four mice were injected intramuscularly in the thigh with the myotoxin (5  $\mu\text{g/g}$ ). At three different time intervals (one hour, three hours, and six hours) mice were killed, a sample of muscle obtained from the thigh, and blot dried in filter paper. The tissue (50 mg) was transferred to a vial containing Arsenazo III (0.1 mM), digitonin (200  $\mu\text{g/ml}$ ), NaCl (140 mM), KCl (5 mM), and imidazole (10 mM, pH 7.0) in a total volume of 2.0 ml. After exactly one minute, a one ml aliquot of the supernatant was transferred to another vial. The absorbance of this solution was recorded at 675 and 685 nm using a dual wavelength program in a Beckman DU-8 spectrophotometer. Calcium levels are directly proportional to the differential absorbance of Arsenazo III at 675-685 nm. Due to the presence of digitonin, calcium that is released to the medium is mainly cytoplasmic (Murphy et al., 1980). Therefore, this method follows changes in cytoplasmic calcium instead of total calcium. Groups of four mice were injected intramuscularly with 0.1 ml of physiologic saline solution as controls. At the same time intervals, pieces of muscle were taken and treated under the same experimental conditions described above.

Neutralization of Myotoxicity  
by Verapamil

Verapamil is a calcium antagonist which acts on the voltage-sensitive slow calcium channels. To investigate

if the calcium influx induced by the toxin takes place through these channels, several experiments were performed. Groups of four mice (20-24 g) were pretreated intramuscularly in the thigh with verapamil at doses of 2.5, 5, and 10  $\mu\text{g/g}$ . Five minutes later, the toxin (2.5  $\mu\text{g/g}$ ) was injected intramuscularly in the same site. In another experiment, verapamil (5  $\mu\text{g/g}$ ) and toxin (2.5  $\mu\text{g/g}$ ) were inoculated intramuscularly simultaneously. Three hours after injection blood samples were taken by cutting the tip of the tail, and the plasma levels of creatine kinase were quantitated as previously described. This time was selected since it is when the highest creatine kinase levels are observed after toxin inoculation. Twenty-four hours after injection, mice were killed; a muscle sample (primarily sartorius) was obtained from the injected thigh and placed in glutaraldehyde fixative solution. Tissue was cut in order to facilitate orientation for cross sections of the muscle and was processed for histological observation as described above. Once stained, muscle cells were counted using a Zeiss light microscope equipped with a Zeiss MOP 3 Image Analyzer. A total of five slides were counted from each mouse. Myonecrosis was expressed as myonecrosis index -number of necrotic cells divided by the total number of cells (Ownby et al., 1983b).

#### Hydrolysis of Phospholipids "In Vivo"

Groups of four mice were injected intramuscularly in



the thigh with myotoxin (5  $\mu\text{g/g}$ ). At 30 minutes, three hours, and six hours mice were killed and a piece of muscle removed from the thigh. It was immediately homogenized in a glass homogenizer with 200  $\mu\text{l}$  distilled water. Then, 1.5 ml of methanol/chloroform (2:1) were added and the suspension shaken and centrifuged for 10 minutes at 1200 g. The supernatant was collected, transferred to another tube, and 1.9 ml of methanol/chloroform/water (2:1:0.8) were added to the pellet. The suspension was shaken and centrifuged for 10 minutes at 1200 g. The second supernatant was added to the first one. Then, they were diluted with 1.0 ml chloroform and 1.0 ml distilled water and the mixture centrifuged at 2500 g for five minutes. The chloroform layer was collected with a Pasteur pipette and the solvent was evaporated. The resultant sediment was resuspended with 50  $\mu\text{l}$  of chloroform, and aliquots of 10 or 15  $\mu\text{l}$  were applied to precoated TLC silica gel 60F-254 plates (EM). Plates were run in chloroform/methanol/acetic acid/water (54:25:8:4). Pure phosphatidylcholine, phosphatidylethanolamine, and lysophosphatidylcholine (Sigma Chemical Co., St. Louis, Missouri) were also applied. At the end of the run, plates were dried, sprayed with concentrated sulfuric acid -30% formaldehyde (97:3 by volume), and heated at 90°C for 20 minutes in order to visualize the spots.

## Results

### Isolation

Figure 1 shows the profile of the ion exchange chromatographic (CM-Sephadex) separation of B. asper venom. Fractions 1, 4, and 5 showed myotoxic activity when tested in mice, whereas all of the hemorrhagic activity was located in fractions 1 and 2. When submitted to polyacrylamide disc gel eletrophoresis, fraction 5 showed a single band. However, in order to assure purity, this fraction was submitted to gel filtration with Sephadex G-75. A single symmetrical peak was obtained which was homogeneous according to polyacrylamide disc gel eletrophoresis (Figure 2). In some of the isolations, peak 5 of the CM-Sephadex chromatography had a minor impurity. In these cases, the toxin was purified by running a second CM-Sephadex column using the same conditions described,

### Molecular Weight Estimation

Figure 3 shows the molecular weight estimation using gel filtration in Sephadex G-75. B. asper myotoxin has an estimated molecular weight of 10,700.

### Immunodiffusion

The toxin formed a single precipitation band in the gel plates when tested against the polyvalent antivenom (Figure 4). This band showed a complete immunological i-

Figure 1. Ion exchange chromatography of B. asper venom on CM-Sephadex C-25. Venom (200 mg) was applied to the column which had been equilibrated with 0.05 M Tris, 0.1 M KCl (pH 7.0) buffer. The column was eluted with 200 ml of the same buffer. Then, a linear salt gradient of 0.1-0.75 M KCl was developed. Fractions of 3.5 ml were collected. Peak 5 (shaded) showed most of the myotoxic activity and was further purified by gel filtration on Sephadex G-75 (inset) using 0.05 M Tris, 0.1 KCl (pH 7.0) as elution buffer. The major peak induced myotoxicity in mice.

Figure 2. Polyacrylamide gel electrophoresis of B. asper myotoxin. Electrophoresis was carried out using 15% acrylamide at pH 4.3.

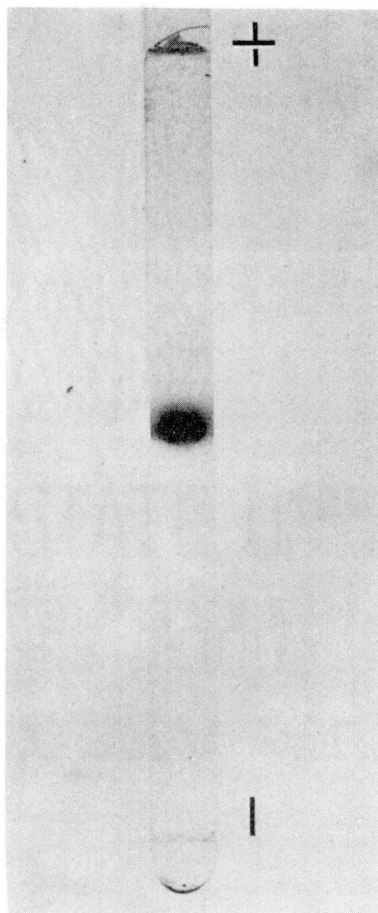
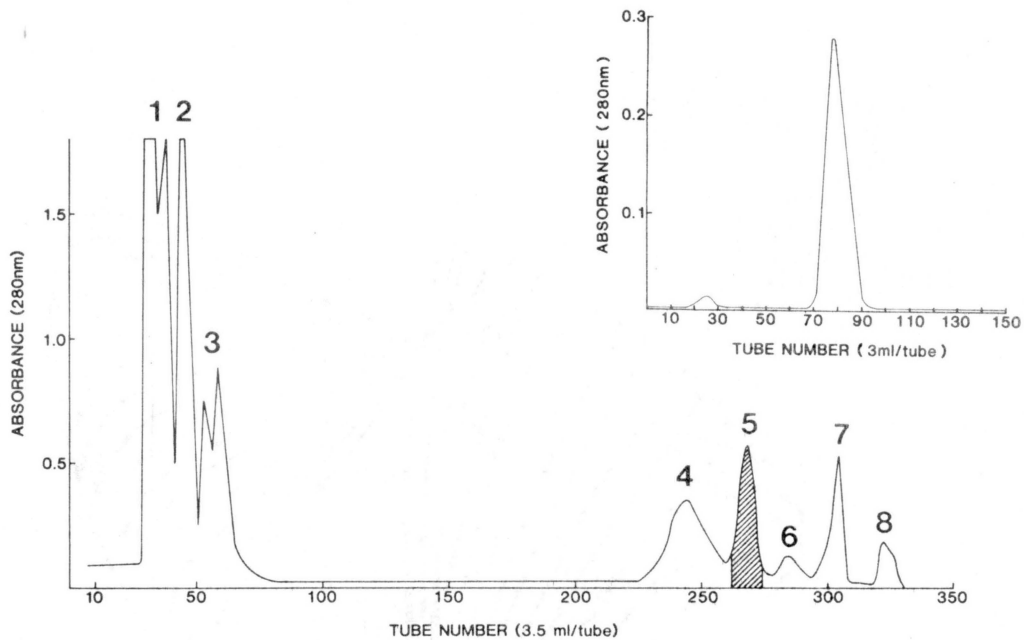
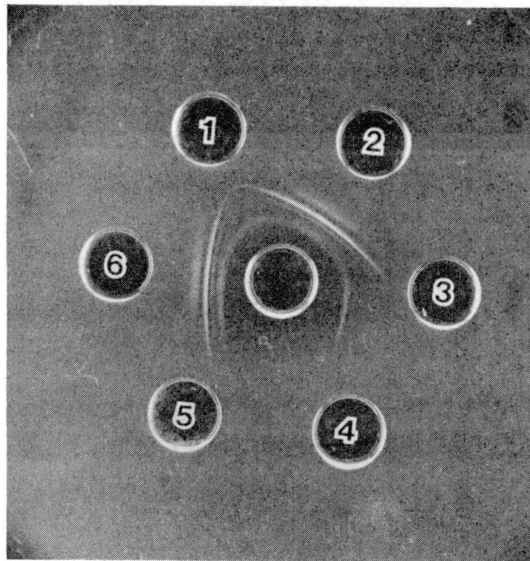
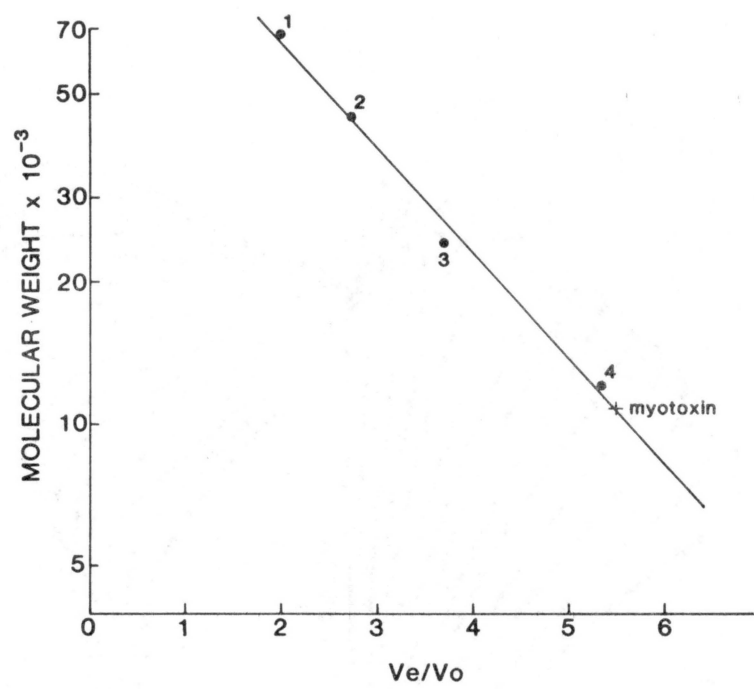


Figure 3. Molecular weight estimation of B. asper myotoxin by gel filtration in a Sephadex G-75 column (100 x 1.5 cm) using 0.05 M Tris, 0.1 M KCl (pH 7.0) as elution buffer. Standards: (1) Bovine serum albumin, (2) ovalbumin, (3) chymotrypsinogen A, (4) cytochrome C. The estimated molecular weight of the myotoxin was 10,700.

Figure 4. Ouchterlony agarose gel-diffusion plate. Center well: polyvalent antivenom. Peripheral wells: (1) and (3) B. asper myotoxin (1 mg/ml); (2) B. asper venom (1 mg/ml); (4) myotoxin a (1 mg/ml); (5) physiologic saline solution; and (6) B. atrox venom (1 mg/ml).



identity with one of the bands produced by the interaction of crude B. asper venom and antivenom. This precipitation band also showed identity with one band obtained between B. atrox crude venom and the antivenom. No immunological reaction was observed between B. asper myotoxin and anti-myotoxin a serum.

#### Amino Acid Composition

The amino acid composition of B. asper myotoxin is shown in Table IV. The toxin has a high content of lysine and aspartic acid.

#### Myotoxic Effect

Histologic evidence of myonecrosis, i.e. clumped myofibrillar material, was observed within 30 minutes after toxin injection (Figure 5). At 30 minutes and one hour many cells showed wedge-shaped lesions with the base located at the cell surface and the apex pointing to the interior of the cell. These lesions are very similar to the "delta lesions" observed in other muscle pathologies (e.g. Mokri and Engel, 1975). By three hours many cells were necrotic; by six hours the morphology of some cells had become more hyaline with a homogenization of the myofibrillar material. At six and 12 hours phagocytic cells were present in the necrotic cells while phagocytosis was well advanced by 24 and 48 hours (Figure 5). There were no histological changes in nerves, muscle spindles, or blood ves-

TABLE IV  
 AMINO ACID COMPOSITION OF BOTHROPS  
ASPER MYOTOXIN

Amino acid	Corrected value (mole %)*	Mole amino acid/mole protein **	Nearest integer
Asp	12.10	11.49	11
Thr	5.20	4.94	5
Ser	5.20	4.94	5
Glu	5.91	5.61	6
Pro	4.85	4.61	5
Gly	7.39	7.02	7
Ala	5.03	4.78	5
$\frac{1}{2}$ Cys	9.31	8.84	9
Val	4.86	4.62	5
Met	1.82	1.73	2
Ile	2.77	2.63	3
Leu	8.08	7.67	8
Tyr	6.89	6.54	7
Phe	1.05	0.99	1
His	0.85	0.81	1
Lys	15.49	14.71	15
Arg	3.66	3.48	3
Trp	n.d.***	n.d.	n.d.
Total			98

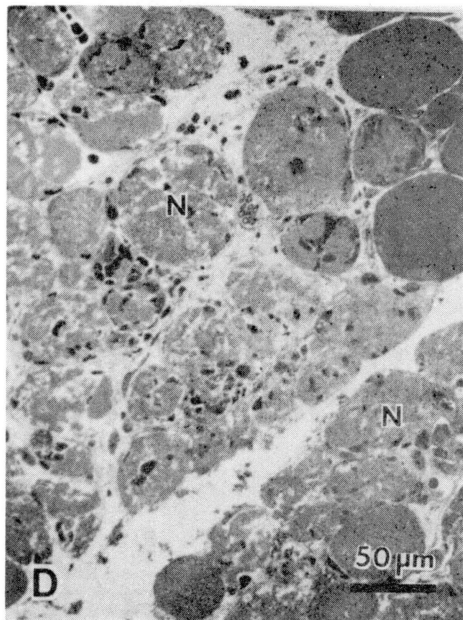
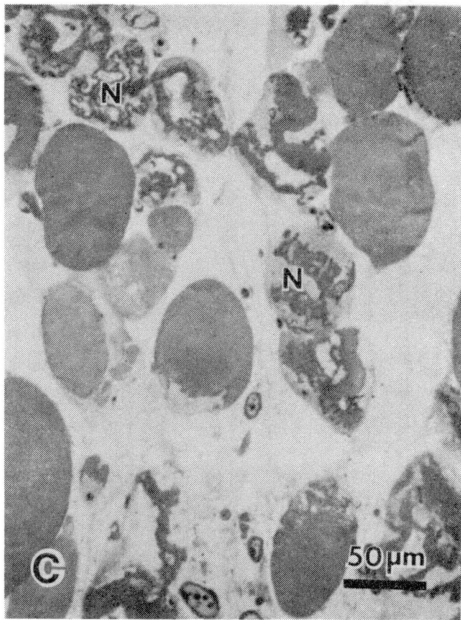
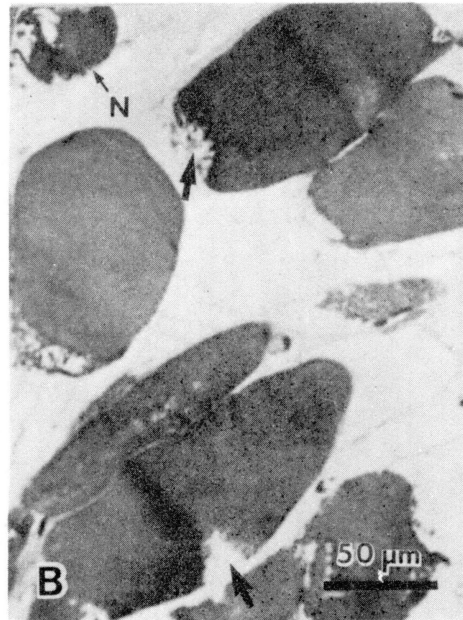
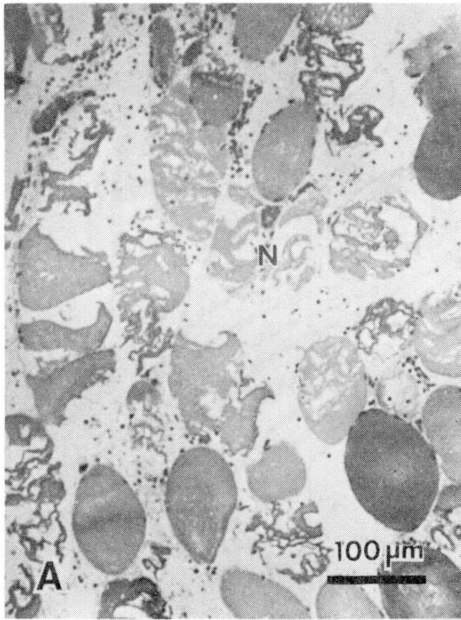
\* Hydrolysis values of threonine, serine, and tyrosine were extrapolated to time 0.

\*\* Assuming a molecular weight of 10,700.

\*\*\* n.d. = not determined.



Figure 5. Photomicrographs of mouse skeletal muscle taken at various time intervals after intramuscular injection of *B. asper* venom (2.5 ug/g) or toxin (2.5  $\mu$ g/g). (A) Venom, one hour. Note the presence of necrotic muscle cells (N), with clumped myofibrils. Hemorrhage is indicated by the presence of erythrocytes in the connective tissue. (B) Toxin, 30 minutes. Several cells show wedge-shaped lesions ("delta lesions") (arrow), whereas other cells are in a more advanced stage of degeneration (N). (C) Toxin, three hours. Necrotic muscle cells (N) show a conspicuous clumping of myofibrils. (D) Toxin, 24 hours. Most of the cells are necrotic (N), but the myofibrils are more homogeneous and hyaline in appearance. Phagocytic cells are observed within the necrotic cells and in the interstitial space. Sections stained with Mallory's trichrome.



sels. On the other hand, the crude venom induced a typical picture of myonecrosis and hemorrhage with a strong inflammatory reaction characterized by edema and the presence of phagocytic cells. A more detailed account of these histological findings will be presented in the next chapter. The pattern of creatine kinase increase was very similar after crude venom and myotoxin injections. In both cases creatine kinase peaked at three hours and then decreased towards normal levels. However, the levels were higher at all times in mice injected with venom than in those injected with toxin (Figure 6).

#### Calcium Influx

The intracellular calcium levels increased markedly after toxin injection as judged by the increase in the differential absorbance of the Arsenazo III solution at 675-685 nm. There was a significant increase in absorbance in samples taken 30 minutes after injection, but the highest levels were observed in samples obtained six hours after inoculation (Figure 7). The absorbance did not increase in solutions incubated with muscle obtained from control mice.

#### Inhibition by Verapamil

Table V shows that verapamil was ineffective in neutralizing the necrosis and the increase in plasma creatine kinase levels. Histologically, the sections obtained from mice injected with the toxin alone were indistinguishable

Figure 6. Profile of creatine kinase levels in mice injected intramuscularly with B. asper venom (2.5  $\mu\text{g/g}$ ) (○-----○), B. asper myotoxin (2.5  $\mu\text{g/g}$ ) (●-----●), and physiologic saline solution (□-----□). One creatine kinase unit results in the phosphorylation of one nanomole of creatine per minute at 25°C. Results are presented as mean  $\pm$  SEM (n=4).

Figure 7. Increase in calcium levels in muscle after intramuscular injections of B. asper myotoxin (5  $\mu\text{g/g}$ ). Muscle was obtained and blot dried. Approximately 50 mg of muscle were then transferred to a vial containing: Arsenazo III 0.1 mM, digitonin 200  $\mu\text{g/ml}$ , NaCl 140 mM, KCl 5 mM, and imidazole 10 mM (pH 7.0) in a total volume of 2 ml. After exactly one minute one ml of the supernatant was transferred to a separate vial. The absorbance of the solution at 675 and 685 nm was read in a Beckman DU-8 spectrophotometer using a dual wavelength program. Calcium levels are directly proportional to the differential absorbance at 675-685 nm. (●-----●) mice injected with toxin; (○-----○) mice injected with physiologic saline solution. Results are presented as mean  $\pm$  SEM (n=4).

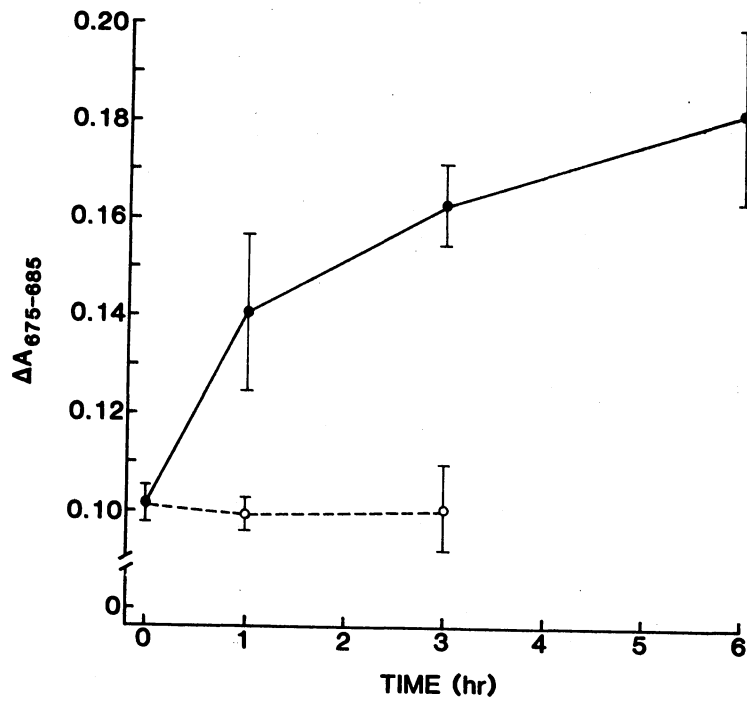
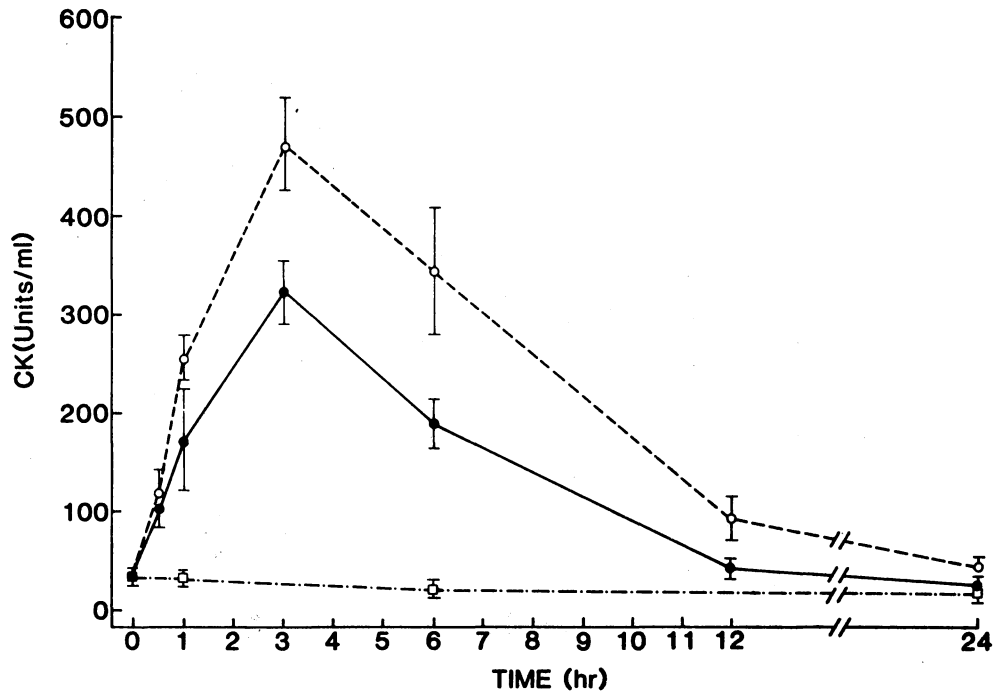


TABLE V  
EFFECT OF VERAPAMIL ON MYOTOXICITY INDUCED  
BY BOTHROPS ASPER TOXIN

Treatment *	Creatine kinase (units/ml) **	Myonecrosis index ***
PSS	28 ± 8	0
Verapamil (5 µg/g)	28 ± 3	0
Toxin (2.5 µg/g)	364 ± 36	0.38 ± 0.10
Pretreatment verapamil (10 µg/g); then toxin (2.5 µg/g)	384 ± 36	0.35 ± 0.06
Pretreatment verapamil (5 µg/g); then toxin (2.5 µg/g)	347 ± 37	0.42 ± 0.09
Pretreatment verapamil (2.5 µg/g); then toxin (2.5 µg/g)	387 ± 28	0.33 ± 0.12
Simultaneous injection: Verapamil (5 µg/g) plus toxin (2.5 µg/g)	345 ± 62	0.34 ± 0.12

\* In pretreatment experiments verapamil was injected intramuscularly five minutes before the toxin. In simultaneous injections, verapamil and toxin were injected intramuscularly at the same time. PSS = physiologic saline solution.

\*\* Expressed as units/ml ± standard error (n=4); one CK unit results in the phosphorylation of one nanomole of creatine per minute at 25°C.

\*\*\* Myonecrotic index = number of necrotic cells/number of total cells. Expressed as mean ± standard error (n=8). Verapamil did not cause any significant change (p > 0.1) in the myonecrotic index and creatine kinase levels when combined with the toxin.

from the sections obtained from mice that were pretreated with verapamil and then injected with toxin.

#### Hydrolysis of Phospholipids "In Vivo"

Figure 8 shows that lysophosphatidylcholine was increased in muscle extracts from mice that had been injected with the toxin when compared with muscle extracts from control mice. This phospholipid was detected in samples taken 30 minutes, three hours, and six hours after inoculation.

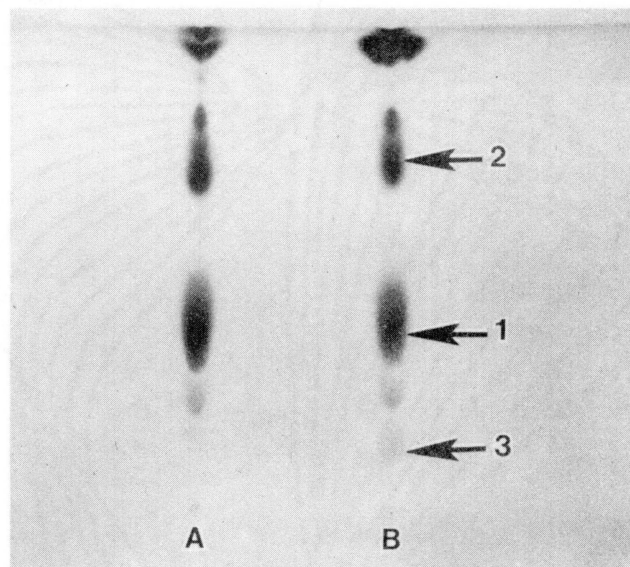
#### Other Activities of the Toxin

B. asper myotoxin showed phospholipase A activity "in vitro". When 2 µg of myotoxin (in 10 µl) were added to the wells of the egg yolk agarose plates, a clear halo of 18 mm diameter was observed after 20 hours of incubation at 50°C. When erythrocytes were added to the gel in order to increase specificity, the diameter of the hemolytic halo was the same as the diameter of the cleared egg yolk halo. The toxin induced indirect hemolysis in tubes; when 10 µg of the toxin were added to the suspension of erythrocytes and lecithin,  $87 \pm 3\%$  hemolysis (n=4) was observed after 30 minutes of incubation. When the phospholipids were excluded from the mixture, no hemolysis was observed. Thus, the toxin is not directly hemolytic.

The myotoxin lacked proteolytic activity when tested by the highly sensitive hide powder azure substrate. Fur-

Figure 8. Thin layer chromatogram of lipid extracts from muscle of mice injected with physiologic saline solution (A) and myotoxin at a dose of 5  $\mu\text{g/g}$  (B). (1) Phosphatidylcholine; (2) phosphatidylethanolamine; and (3) lysophosphatidylcholine. The chromatographic separation was performed in precoated TLC silica gel 60F-254 plates (EM reagents). Plates were run in chloroform/methanol/acetic acid/water (54:25:8:4). They were then dried, sprayed with concentrated sulfuric acid -30% formaldehyde (97:3 by volume) and heated at 90°C for 20 minutes.





thermore, the toxin was devoid of hemorrhagic activity, since both macroscopic and microscopic examination of muscular tissue revealed the absence of erythrocytes in connective tissue space.

#### Discussion

A homogeneous myotoxic phospholipase has been isolated from B. asper venom. The toxin induces myonecrosis in mice which resembles the action of the crude venom in two ways. First, the profile of creatine kinase levels in plasma is very similar, although the venom induces a greater elevation. Second, the histological picture observed after myotoxin injection partially resembles the histology of muscle inoculated with crude venom. However, the latter drastically affects the vasculature, and induces a necrotic pattern that is not identical to the one observed after myotoxin injection. This is probably due to the action of other components (i.e. myotoxins and hemorrhagic toxins) present in the crude venom.

Several myotoxins have been isolated from snake venoms. They can be placed into three main groups: (a) The myotoxic phospholipases, such as notexin (Harris et al., 1975), taipoxin (Harris and Maltin, 1982), crotoxin (Hawgood, 1982), mojave toxin (Gopalakrishnakone et al., 1980), and some isolated from Australian elapid venoms (Mebs and Samejima, 1980); (b) the "cardiotoxins", present in some elapid venoms (Chang, 1979), which have a broad

spectrum of pharmacological effects; and (c) small basic toxins such as myotoxin a (Ownby et al., 1976), crotamine (Cameron and Tu, 1978), a toxin isolated from Crotalus adamanteus (Mebs et al., 1983), and toxins isolated from the venoms of Crotalus durissus durissus (Eneff, 1982) and Crotalus viridis concolor (Pool et al., 1981). Bothrops asper myotoxin belongs to the first group, since it has phospholipase A activity and induces biochemical and histological alterations in skeletal muscle which resemble those induced by some myotoxic phospholipases such as notexin (Harris et al., 1975), taipoxin (Harris and Maltin, 1982), and crotoxin (Hawgood, 1982). However, the relative potency of these myotoxins is very different, since toxins isolated from Australian elapid venoms (Mebs et al., 1983) induce more drastic myonecrosis than crotoxin and B. asper myotoxin.

As regards the mode of action of the myotoxin, the following observations indicate that it may affect the integrity of the plasma membrane: (a) The toxin induces a rapid increase in plasma creatine kinase levels; (b) there is an elevation in cytosolic calcium levels after toxin injection. The experiments with verapamil indicate that this calcium influx does not occur through voltage-sensitive calcium channels which in skeletal muscle are located in the T tubules (Almers et al., 1981). This influx is probably a consequence of a generalized membrane disruption. (c) Ultrastructural studies show that there are focal dis-

ruptions in the integrity of the sarcolemma in tissue obtained 30 minutes after toxin injection. (d) Histologically, some cells show wedge-shaped lesions ("delta lesions") which have the base at the cell surface and the apex pointing towards the interior of the cells. These lesions have been described in other muscle diseases (e.g. Duchenne muscular dystrophy, Mokri and Engel, 1975). It has been shown that "delta lesions" represent focal areas of degeneration that underline portions of the cell where the plasma membrane is disrupted or lost. (e) There is an increase in the content of lysophosphatidylcholine in muscle after toxin injection. This might be due to the phospholipolytic activity of the toxin on muscle phospholipids. If this is the case, the toxin may be affecting the membrane integrity either by depleting the membrane phospholipids or by releasing lysophospholipids which are able to induce muscle necrosis themselves (Pestronk et al., 1982).

If the toxin acts by altering the structural and functional integrity of the plasma membrane, a generalized increase in membrane permeability to macromolecules and ions might occur. The observed calcium influx is particularly significant since it has been repeatedly proposed that an increase in cytosolic calcium levels is a critical step in the process of cell death in a wide variety of pathological conditions (Trump et al., 1981). In skeletal muscle, such an increase in calcium levels results in hypercontraction of the myofilaments, mitochondrial poisoning (Wrogemann and

Pena, 1976), activation of calcium-dependent proteases (Duncan, 1978) and phospholipases (Trump et al., 1981), and eventually cell death.

Is the phospholipase A activity relevant to the myotoxic action of the toxin? Although this question cannot be answered with our data, it seems very likely that the phospholipolytic activity is related to myotoxicity. Condrea et al. (1981) have questioned the correlation between phospholipase activity and toxicity in several phospholipases isolated from elapid venoms. Nevertheless, the facts that B. asper myotoxin is able to release lysolecithin "in vivo", and that this lipid can induce myonecrosis (Pestronk et al., 1982), support the idea that this necrosis is at least partially due to the phospholipase activity of the toxin. Harris and MacDonell (1981) demonstrated that notexin is able to hydrolyze phospholipids in rat skeletal muscle; they proposed that the myotoxicity of notexin is based on its phospholipase A activity. The same mechanism has been proposed for crotoxin (Hawgood, 1982) and taipoxin (Harris and Maltin, 1982). Alternatively, the phospholipid hydrolysis observed "in vivo" can be the result of the activation of intracellular phospholipases. There are calcium-dependent phospholipases which play a role in membrane function (Shier, 1982). Since B. asper myotoxin induces a calcium influx, a combination of extrinsic and intrinsic phospholipolytic activities may take place simultaneously in this pathologic event.

## CHAPTER IV

### PATHOGENESIS OF MYONECROSIS INDUCED BY CRUDE VENOM AND A MYOTOXIN OF BOTHRUPS ASPER

#### Introduction

Poisoning by pit vipers (family Crotalidae) induces myonecrosis, hemorrhage, and edema at the site of venom injection (Ownby, 1982). In Central America, Bothrops asper is the species responsible for the majority of snakebite cases (Bolaños, 1982). Its venom induces a drastic myotoxic effect which has been described in both experimental animals and humans (Gutiérrez et al., 1980a; Arroyo and Gutiérrez, 1981; Bolaños, 1982). Furthermore, it has been determined that the polyvalent antivenom available is only partially able to neutralize this effect (Gutiérrez et al., 1981).

As described in Chapter III, a myotoxin from B. asper venom was purified to homogeneity. It is a basic phospholipase A with a molecular weight of 10,700 daltons, induces myonecrosis in mice, and is able to hydrolyze muscle phospholipids "in vivo". This toxin may prove to be a useful tool in understanding the mode by which this venom affects skeletal muscle. In the present chapter, the pathogenesis

of myonecrosis induced by this toxin as well as by crude B. asper venom are described at the light and electron microscopic levels. Also, the development of hemorrhage in skeletal muscle induced by the crude venom was studied in an attempt to correlate changes in microcirculation with the pathogenesis of myonecrosis.

### Materials and Methods

#### Venom

Bothrops asper venom was a generous gift from Dr. Luis Cerdas, Instituto Clodomiro Picado, Universidad de Costa Rica. The venom is a pool obtained from more than 50 specimens collected in the Atlantic slopes of Costa Rica.

#### Toxin

The myotoxin was isolated according to the procedure described in Chapter III. Homogeneity was shown by disc-polyacrylamide gel electrophoresis (pH 4.3) as stated in the preceding chapter.

#### Histological and Ultrastructural Studies

Groups of four female mice (Charles River, CD-1) weighing  $20 \pm 2$  g were injected intramuscularly dorsolaterally in the thigh with venom (2.5  $\mu\text{g/g}$ ), toxin, (2.5  $\mu\text{g/g}$ ) or physiologic saline solution. At seven time intervals (30 minutes, 1 hour, 3 hours, 6 hours, 12 hours, 24 hours,

and 48 hours) mice were killed by cervical dislocation and a sample of muscle obtained from the ventromedial aspect of the thigh. The tissue was processed for light and electron microscopy as previously described (Ownby et al., 1976). Thick sections were stained with Mallory's trichrome, and thin sections (silver to light gold) were stained with methanolic uranyl acetate and lead citrate, and examined in a Philips EM 200 electron microscope. A total of 68 mice was used.

#### Quantitation of Hemorrhage

Local hemorrhage was quantitated according to the method of Ownby et al. (1983a) in which the amount of hemoglobin in muscle extracts is measured after intramuscular injections of venom (2.5 µg/g) in mice. Hemoglobin content is expressed as corrected hemoglobin (g %). This value is obtained by taking into consideration the weight of the muscle from which the extract is made.

### Results

#### Myonecrosis Induced by the Toxin

Light Microscopy. Samples obtained 30 minutes after injection contained degenerating as well as necrotic and normal cells. Many cells had focal, wedge-shaped lesions, the base of which was at the surface of the cell with the apex pointing towards the interior. These lesions closely



resemble the "delta lesions" described by Mokri and Engel (1975) in biopsies from Duchenne muscular dystrophy patients. Some cells had several of these lesions (Figure 9A). At 30 minutes, 1 hour, and 3 hours, many cells were necrotic, with conspicuous clumps of myofibrils alternating with empty spaces in the cytoplasm (Figure 9B). In these cells the striated pattern was absent. By 3 hours, but especially at 6, 12, 24, and 48 hours, the appearance of these cells gradually changed as the clumped morphology of the myofibrils disappeared (Figure 9C). The cytoplasm became more hyaline and homogeneous. Phagocytosis started at 3 hours, but was not prominent until 12, 24, and 48 hours (Figure 9D). The toxin did not affect blood vessels, nerves, or muscle spindles. No change was observed in muscle obtained from mice injected with physiologic saline solution.

Electron Microscopy. Examination of "delta lesions" at 30 minutes showed that the plasma membrane was focally or, more often, completely disrupted (Figure 10). Beneath these membrane lesions the myofibrils were clumped into dense masses, leaving many empty spaces in the cytoplasm. Mitochondria were swollen, disrupted, and contained vesiculated cristae (Figure 10). Alteration of the sarcoplasmic reticulum resulted in many small vesicles randomly located in the affected areas. At later time periods, there were cells in which practically all the organelles were severely

Figure 9. Light micrographs of skeletal muscle taken at various times after injection of *B. asper* myotoxin. (A) 30 minutes. "Delta lesions" (arrows) are the earliest changes observed. Other necrotic cells (\*) contain clumped myofibrils. (B) One hour. Necrotic cells (\*) with clumped myofibrils are present. (C) Six hours. Necrotic cells (\*) have a hyaline appearance in which the myofibrillar material has a more homogeneous pattern. (D) 48 hours. Necrotic cells (\*) with a hyaline appearance are located between normal muscle cells (M). Phagocytic cells (arrowheads) are observed in the connective tissue and within the basal lamina of necrotic cells. Sections stained with Mallory's trichrome.

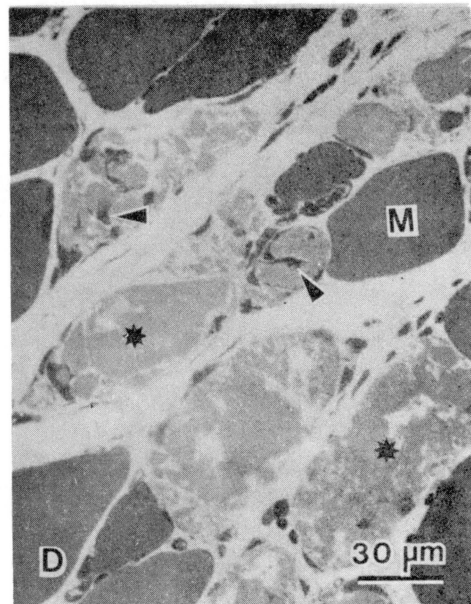
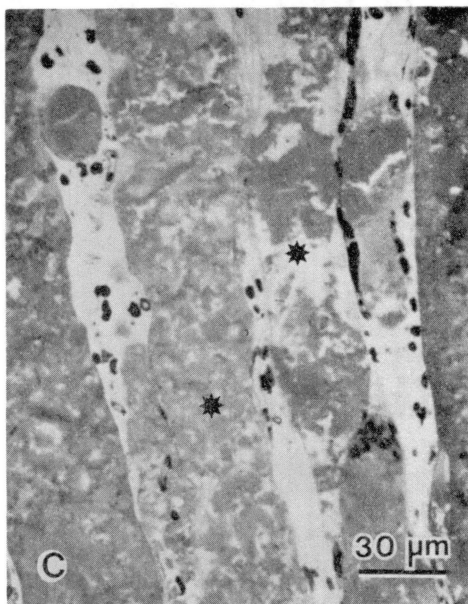
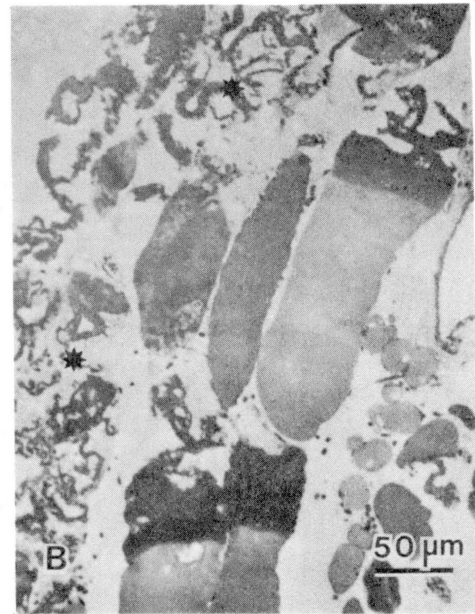
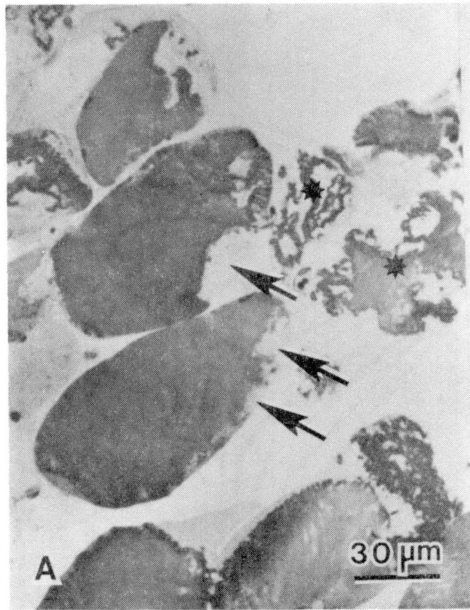
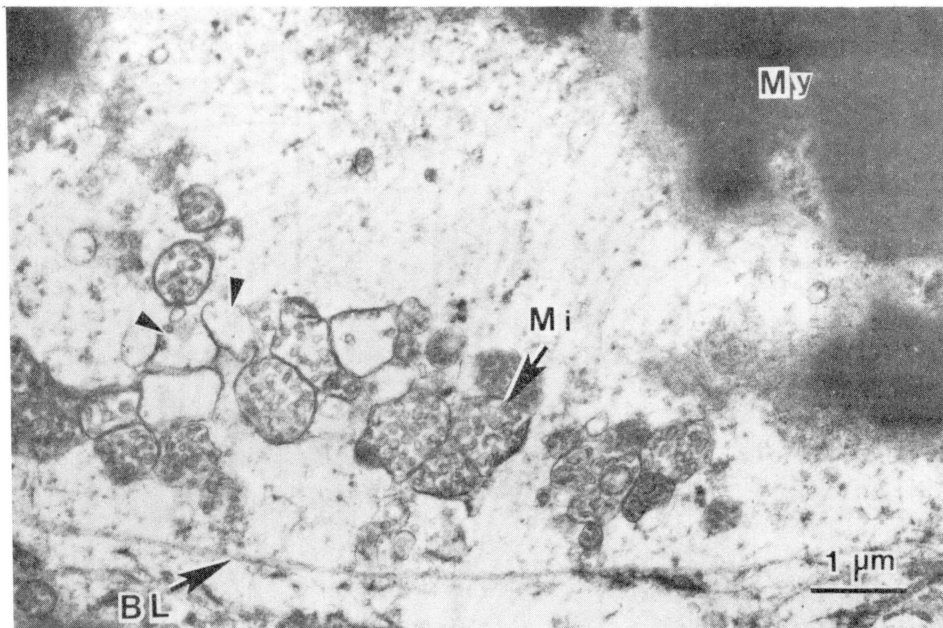


Figure 10. Electron micrograph of skeletal muscle 30 minutes after injection of B. asper myotoxin. Portions of a muscle cell with a "delta lesion". Note that the plasma membrane is no longer present, whereas the basal lamina (BL) is intact. Myofilaments (My) are clumped into dense masses. Some mitochondria (Mi) have vesiculated cristae, whereas others are disrupted (arrowheads). Section stained with uranyl acetate and lead citrate.



affected, with the exception of the basal lamina which was intact (Figure 11). This was the predominant pattern of necrosis at 30 minutes, one hour, and three hours. By three hours some cells appeared to be in a transition to a different necrotic stage, in which the cells no longer had a clumped appearance as myofilaments at the edge of the clumps became dispersed (Figure 11). These myofilaments were devoid of any pattern of organization. Later, at 6, 12, 24, and 48 hours, the myofibrillar material in all necrotic cells was loosely packed and disorganized. By 6, 12, 24, and 48 hours, muscle cells showed further degradation of the rest of the organelles, and the plasma membrane was almost completely absent (Figure 12). Normal sarcoplasmic reticulum and T tubules were rare, but there were many small, round vesicles randomly dispersed in the cytoplasm. Phagocytosis was observed at three hours, but it was more pronounced by 12, 24, and 48 hours. Phagocytic cells were observed inside the basal lamina, and mitochondria, vesicles, and myofilaments were present inside phagocytic vacuoles (Figure 12). Mitochondrial alterations were prominent at all time intervals. Many mitochondria were swollen and had dense intracrystal spaces, others contained flocculent densities, and most of them had vesiculated cristae and only one membrane which was frequently broken (Figure 13). Capillaries and connective tissue cells were not affected by the toxin. The ultrastructure of muscle injected with physiologic saline solution was normal.

Figure 11. Electron micrograph of skeletal muscle three hours after injection of B. asper myotoxin. Necrotic cell undergoing a transition from clumped to hyaline appearance. Myofilaments (My) are being dispersed from a clumped mass (CM). The plasma membrane is not present, but the basal lamina (BL) is intact. Many small vesicles are present in the cytoplasm (arrowheads), and mitochondria (Mi) are swollen and disrupted. Section stained with uranyl acetate and lead citrate.

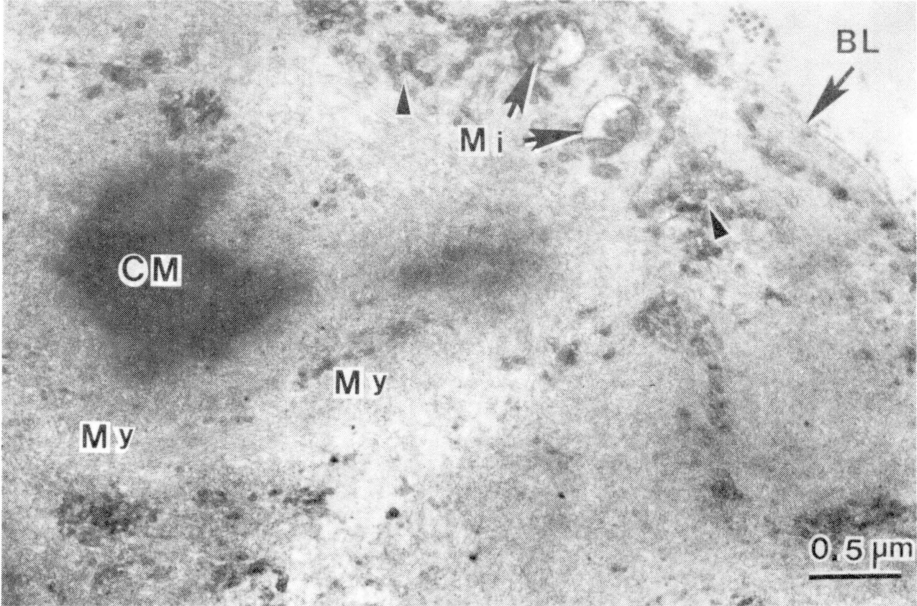
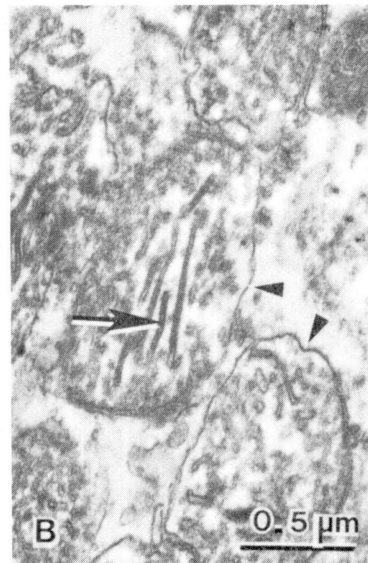
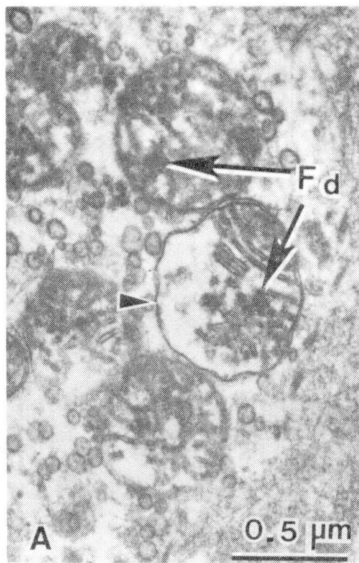
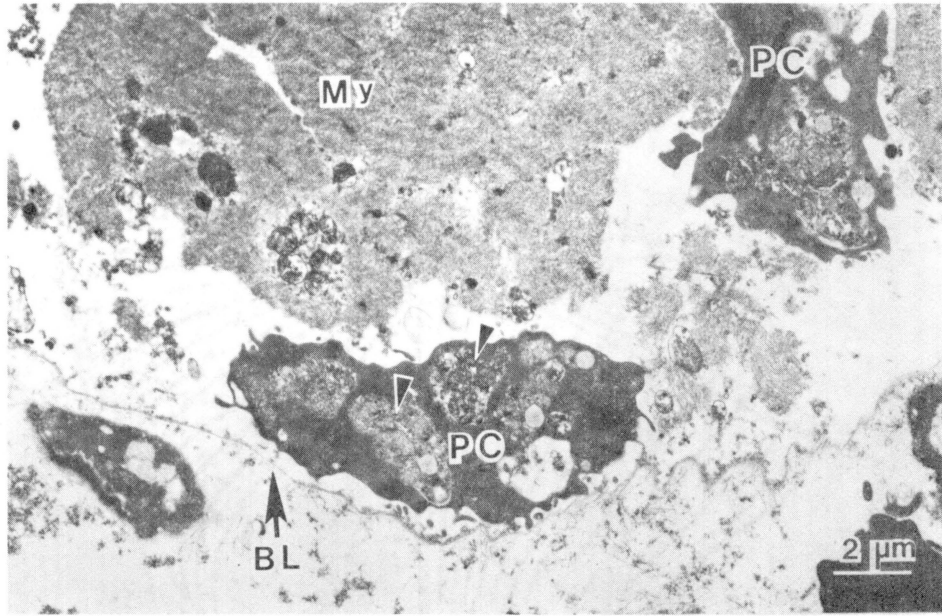




Figure 12. Electron micrograph of skeletal muscle 24 hours after injection of B. asper myotoxin. Necrotic muscle cell invaded by phagocytic cell (PC). Note the presence of mitochondria inside phagocytic cells (arrowheads). Myofibrillar material (My) appears as an amorphous mass. The plasma membrane is not present, but the basal lamina (BL) is intact. Section stained with uranyl acetate and lead citrate.

Figure 13. Mitochondrial changes in skeletal muscle after injection of B. asper myotoxin. (A) 24 hours after toxin injection. Swollen mitochondria containing flocculent densities (Fd) are present. There is only one membrane in some areas (arrowhead). (B) Six hours after toxin injection. Mitochondria are swollen and have only one membrane (arrowheads) as well as dense intracristal spaces (arrow). Sections stained with uranyl acetate and lead citrate.



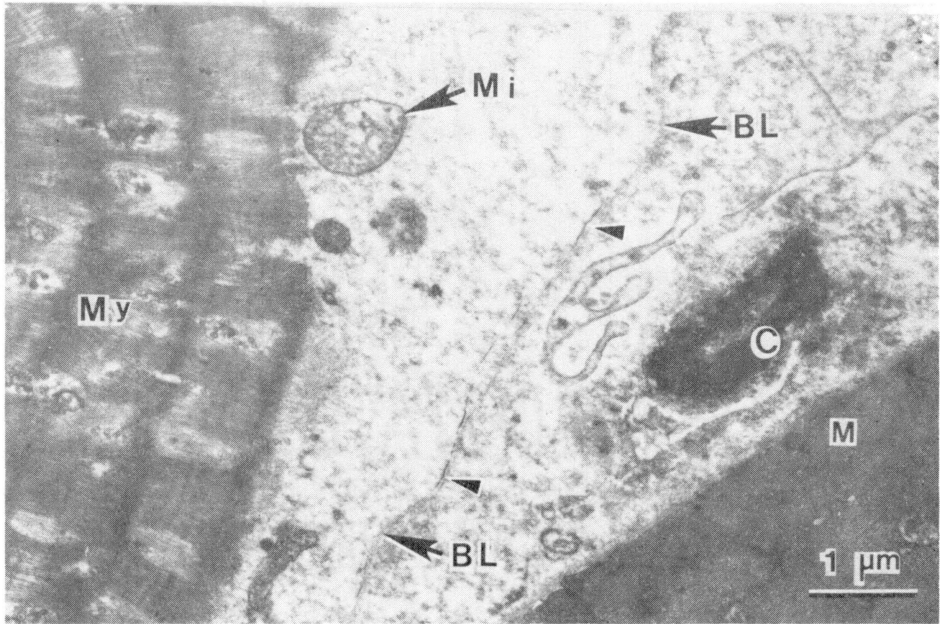
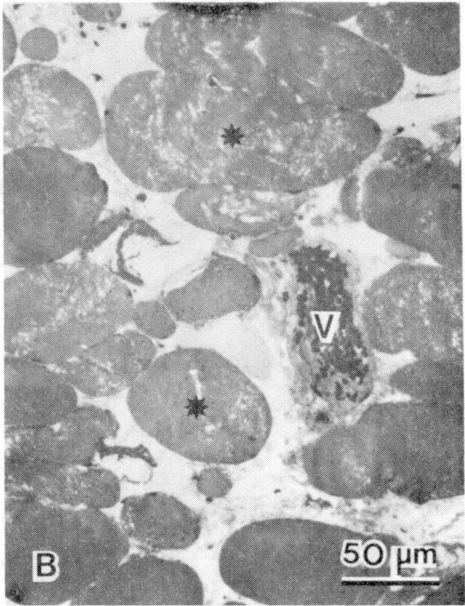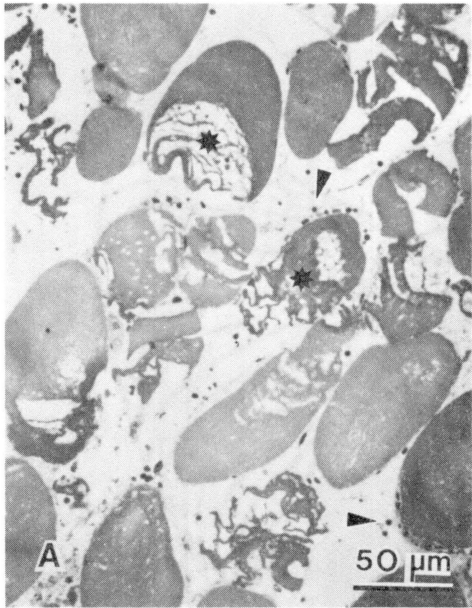
### Myonecrosis Induced by Crude Venom

Light Microscopy. Two different patterns of muscle cell necrosis were observed after crude venom injection. One of them closely resembles the action of the myotoxin. In this pattern, early changes were observed by 30 minutes, with the presence of "delta lesions". By one and three hours these cells developed the characteristic clumping of myofibrils (Figure 14A). On the other hand, by 3, 6, and 12 hours some cells were going through a different series of pathologic changes. Their myofibrils were neither clumped nor did they have a hyaline appearance. Instead, their striated appearance was partially lost, but the myofibrillar architecture seemed to be better preserved (Figure 14B). At later stages, necrotic cells appeared hyaline with an amorphous homogeneous cytoplasm. After the third hour, there was a phagocytic infiltration which peaked by 24-48 hours. Besides its action on muscle cells, B. asper venom induced prominent hemorrhage, as many erythrocytes were observed in the interstitial connective tissue.

Electron Microscopy. There were many necrotic cells that had almost identical characteristics to toxin-affected muscle cells. By 30 minutes many cells showed focal disruptions in the continuity of the plasma membrane (Figure 15). At 30 minutes, and especially at one and three hours, the predominant necrotic cell type had the following characteristics: disrupted plasma membrane, intact basal lam-

Figure 14. Light micrograph of skeletal muscle taken at various times after injection of B. asper crude venom. (A) One hour. Necrotic cells (\*) contain clumped myofibrils. Erythrocytes (arrowheads) are present in the endomysium. (B) Six hours. Necrotic cells (\*) in which the myofibrillar structure is partially preserved. This pattern of necrosis was observed in some areas at 3, 6, and 12 hours. A congested blood vessel (V) has many erythrocytes in its lumen. Sections stained with Mallory's trichrome.

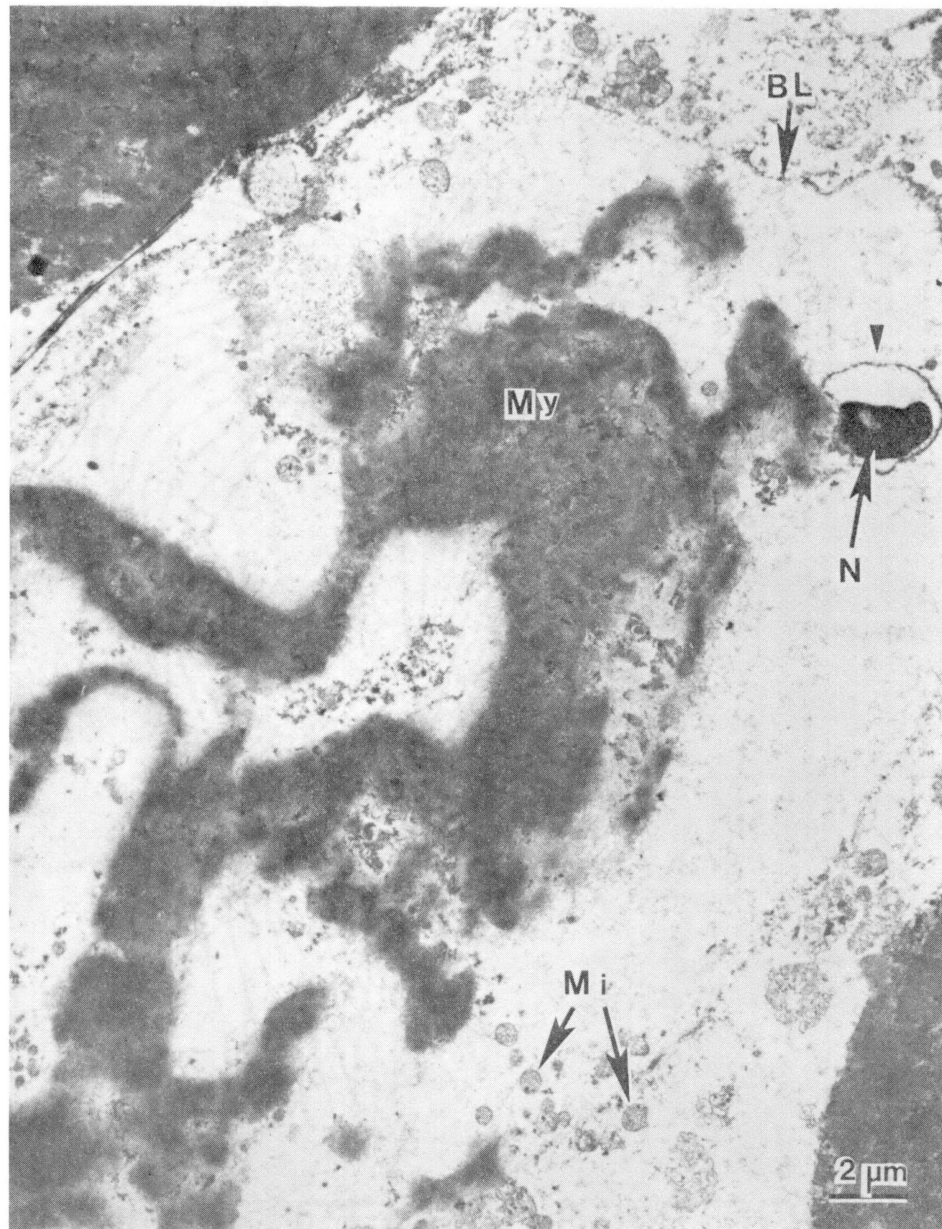
Figure 15. Electron micrograph of skeletal muscle taken 30 minutes after injection of crude B. asper venom. Portions of two cells, one of which is normal (M) whereas the other (left side of micrograph) is undergoing early pathologic changes. In the abnormal cell, the plasma membrane is present only in small patches (arrowheads), whereas the basal lamina (BL) is intact. Myofibrils (My) are disoriented and mitochondria (Mi) are swollen. Note the disrupted capillary (C) in the endomysium. Section stained with uranyl acetate and lead citrate.



ina, and myofilaments that were coalesced into dense, clumped masses in which it was impossible to differentiate individual myofilaments (Figure 16). Some mitochondria were swollen, others had flocculent densities, and still other mitochondria had lost their integrity, as was described for toxin-injected muscle (Figure 13). Sarco-plasmic reticulum disruption resulted in the formation of many small, rounded vesicles, whereas T tubules could not be observed. Nuclei showed clumping of chromatin and separation of chromatin from the nuclear envelope which was often discontinuous (Figure 16). By 6, 12, 24, and 48 hours these necrotic cells had a different morphology in which there was a gradual relaxation and redistribution of the clumped myofibrils so that individual myofilaments and groups of myofilaments were observed in the cytoplasm. Otherwise, the rest of the organelles had the same alterations described above. Erythrocytes were observed in the interstitial connective tissue as well as inside necrotic cells.

At three hours, and especially at six and 12 hours, many cells seemed to be going through a different series of pathologic changes. These cells were evidently altered, but their myofibrillar structure was better preserved than in other necrotic cells. In these cells the sarcomeric organization was preserved, with the exception of the Z line which was selectively absent. Otherwise, the rest of the sarcomeric structure, that is, the A, I, H, and M bands

Figure 16. Electron micrograph of skeletal muscle taken three hours after injection of crude B. asper venom. Typical necrotic cell with clumped myofibrils (My). Mitochondria (Mi) are swollen and contain flocculent densities; plasma membrane is absent in many areas, but the basal lamina (BL) is intact. Note that the nucleus (N) is pycnotic and the dense chromatin is separated from the nuclear envelope (arrowhead). Section stained with uranyl acetate and lead citrate.





could be identified (Figure 17A). As a consequence of Z line loss, the sarcomeres were disoriented and lacked the normal striated pattern. Thus, the mechanical integration of myofibrils was obviously impaired in these cells which were irreversibly damaged, since their plasma membrane was disrupted in many areas. Their mitochondria were swollen and had vesicles in their interior, whereas others showed dense intracristal spaces. Sarcoplasmic reticulum membranes were broken into small vesicles, but the basal lamina was intact (Figure 17B). This pattern of necrosis was absent by 24 and 48 hours, indicating that these cells progressed towards the hyaline, homogeneous morphology described for the action of the toxin at later time periods (Figure 12).

#### Quantitation of Hemorrhage

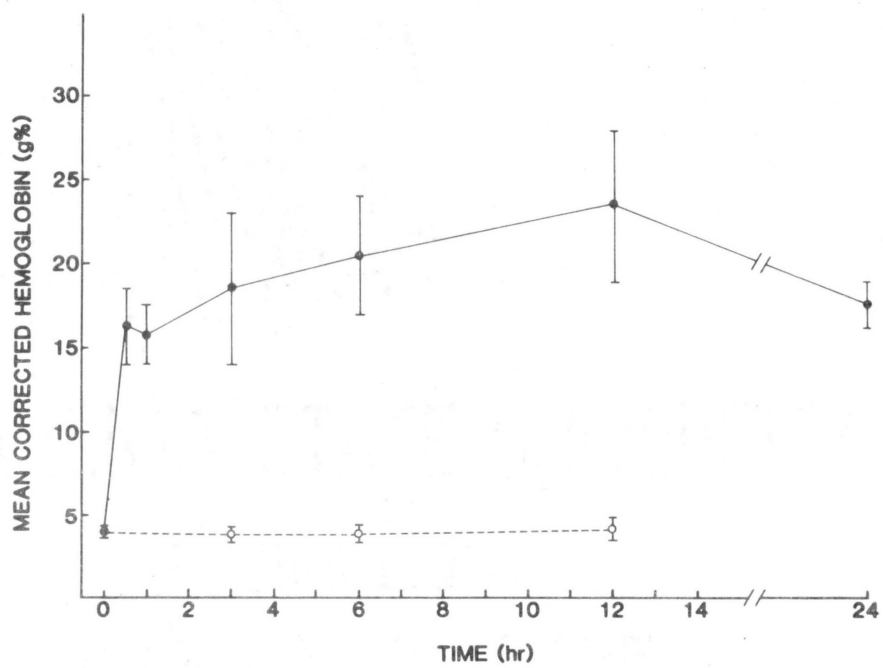
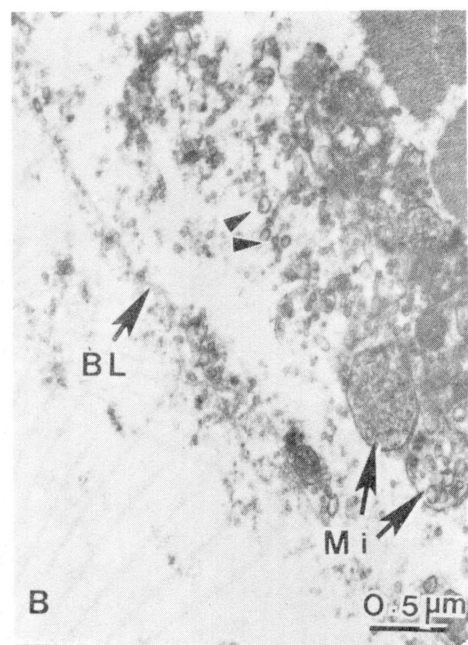
Hemorrhage developed very rapidly after B. asper venom injection. By 30 minutes there was a conspicuous increase in the hemoglobin content of the muscle. Local hemorrhage increased up to 12 hours at which time this activity reached its maximum level (Figure 18).

#### Discussion

A myotoxic phospholipase A has been isolated from B. asper venom. When injected intramuscularly into mice it induces necrosis of skeletal muscle. Both toxin and venom act very fast, as many cells are irreversibly damaged with-

Figure 17. Electron micrograph of skeletal muscle taken six hours after injection of crude B. asper venom. (A) Portion of a muscle cell to show alteration of sarcomere structure. Z line is absent (arrows), whereas A, I, H, and M bands are present. Some sarcomeres seem to be dispersed in the cytoplasm which contains many vesicles. (B) Mitochondria (Mi) are swollen, contain vesiculated cristae, and some have only one membrane. Many vesicles (arrowheads) are randomly dispersed in the cytoplasm, and the plasma membrane is not present; the basal lamina (BL) is intact. Sections stained with uranyl acetate and lead citrate.

Figure 18. Development of hemorrhage in muscular tissue after intramuscular injection of B. asper venom (2.5  $\mu\text{g/g}$ ). Tissue was homogenized and the hemoglobin content estimated according to the procedure of Ownby et al. (1983a)



in 30 minutes after injection.

In the pathogenesis of myonecrosis, the earliest changes in affected cells seem to be related to the plasma membrane. Thirty minutes after injection of both toxin and venom there were many wedge-shaped lesions in the cells. Such lesions have been called "delta lesions" and represent areas of cell degeneration located beneath portions of disrupted or discontinuous plasma membrane (Mokri and Engel, 1975). Our observations at the ultrastructural level indicate an almost total absence of plasma membrane in these areas. Similar lesions have been observed in biopsies from Duchenne muscular dystrophy patients (Mokri and Engel, 1975), as well as after injections of membrane-active substances such as lysolecithin, mellitin, deoxycholate, and Triton X-100 (Pestronk et al., 1982). In all of these cases the plasma membrane was affected both morphologically and functionally. A previous study showed that B. asper myotoxin induces a calcium influx into skeletal muscle cells and a rapid rise in plasma creatine kinase levels during the first hours after injection (Chapter III). Also, the toxin is able to hydrolyze muscle phospholipids "in vivo". These events are probably indications of membrane disruption and support the view that the plasma membrane is the primary site of action of this toxin.

It is interesting that the pathologic changes caused by B. asper myotoxin resemble those induced after inoculations of several venoms and toxins such as notexin (Harris

et al., 1975), taipoxin (Harris and Maltin, 1982), crotoxin (Hawgood, 1982), a cardiotoxin (Duchen et al., 1974), tarantula venom (Ownby and Odell, 1983), and phospholipase C from Clostridium perfringens (Strunk et al., 1967). Similar observations have been made in biopsies from Duchenne muscular dystrophy patients (Mokri and Engel, 1975; Cullen and Fulthorpe, 1975). In all these cases it has been postulated that the primary basic change consists in lesions of the plasma membrane, with a subsequent impairment of its ability to regulate the permeability to ions and molecules.

The most significant consequence of such membrane disruption is the influx of calcium following the electrochemical gradient that is normally maintained across the cell membrane (Trump et al., 1981; Carafoli, 1982). Calcium influx has been observed to occur after B. asper myotoxin injection (Chapter III). An increase in cytosolic calcium levels has been considered a key factor in the process of cell injury in many pathologic conditions (Trump et al., 1981; Farber, 1982). In skeletal muscle cells such a rise in calcium levels results in: (a) Hypercontraction and clumping of myofilaments; (b) mitochondrial overload which results in swelling and the formation of flocculent densities (Wrogemann and Pena, 1976; Publicover et al., 1977); (c) activation of calcium-dependent proteases (Duncan, 1978), such as the calcium-activated neutral proteinase isolated from skeletal muscle (Ishiura, 1981); and (d)

activation of calcium-dependent phospholipases, responsible for further degradation of membranes, not only plasma membrane, but also sarcoplasmic reticulum and mitochondrial membranes (Trump et al., 1981).

As a consequence of venom and toxin injections, necrotic cells showed a prominent clumping of myofilaments in dense masses. Later on, these clumps began to relax and there was a homogenization or redistribution of the myofibrillar material in the cellular space. This resulted in the hyaline, homogeneous appearance of cells which predominate at later time periods. A similar observation has been made in biopsies from Duchenne muscular dystrophy patients where a process of gradual homogenization of the clumped contractile material was described (Cullen and Fulthorpe, 1975). These two morphologic patterns seem to be stages of the same process of cell injury. This transition is demonstrated by the fact that at three hours there are cells in which the dense clumps are undergoing dissolution.

In regard to myonecrosis induced by crude venom, many cells had pathological features identical to those described for toxin-affected cells. Nevertheless, there were also groups of cells that presented different morphologic characteristics. In these cells, a dramatic clumping of myofilaments did not occur, and the myofibrillar structure was better preserved. Several lines of evidence indicate that these cells may be affected by ischemia. Morphologi-

cally they resemble the skeletal muscle cells described by Karpati et al. (1974) in experimentally-induced ischemia, which are characterized by disrupted plasma membrane, vesiculated sarcoplasmic reticulum, and pycnotic nuclei. Moreover, these authors also observed disappearance of Z line, although myofilaments were still bundled in myofibrils. All of these morphologic characteristics were observed in some cells three, six, and 12 hours after injection of B. asper venom. In venom-affected cells, mitochondria were swollen and some of them had intracristal plates similar to the ones observed by Karpati et al. (1974) in ischemic muscle. However, giant mitochondria which are characteristic of ischemic muscle according to Hanzlíková and Schiaffino (1977) were not observed in our experiments. In regard to Z line loss, it is significant that a calcium-activated neutral proteinase isolated from skeletal muscle releases several proteins upon incubation with myofibrils, with the disappearance of Z line (Ishiura, 1981).

Furthermore, B. asper venom induces local hemorrhage which reaches significant levels as early as 30 minutes after injection. Thus, this compromise of local microcirculation may impair the adequate blood supply to the tissue, inducing ischemia in some areas. It has been proposed that viriditoxin, a hemorrhagic toxin isolated from the venom of Crotalus viridis viridis, induces an ischemic condition in skeletal muscle which in turn is responsible for the muscle

necrosis observed after inoculation of this toxin (Gleason et al., 1983). Thus, the action of B. asper venom in muscle is a complex one, since there is direct damage to cells by the myotoxin, as well as indirect effects due to ischemia, perhaps induced by hemorrhagic toxins.



## CHAPTER V

### SKELETAL MUSCLE REGENERATION AFTER MYONECROSIS INDUCED BY CRUDE VENOM AND A MYOTOXIN OF BOTHRUPS ASPER

#### Introduction

Regeneration of skeletal muscle constitutes a well-described phenomenon observed after several types of injury (Allbrook, 1981). In some cases regeneration proceeds to completion, and there is no functional loss of muscle, e.g. after bupivacaine-induced myotoxicity (Nonaka et al., 1983). However, in other examples of muscle disease regeneration is impaired and the damaged muscle is substituted by adipose tissue and fibrosis, e.g. in older patients of Duchenne muscular dystrophy (Lipton, 1979). It has been demonstrated that skeletal muscle regeneration proceeds to completion when several requirements are met, such as adequate blood supply, presence of functional innervation, and presence of intact basal lamina (Allbrook, 1981).

Many snake venoms induce myonecrosis (Homma and Tu, 1971; Ownby, 1982). Experimental studies with the elapine toxins notexin and taipoxin, as well as with the venom of Oxyuranus scutellatus have shown that they induce a prom-

inent myotoxic effect after which regeneration proceeds rapidly and is completed by one month (Harris et al., 1980; Harris and Maltin, 1982; Maltin et al., 1983). However, venoms from pit vipers (family Crotalidae) induce a more complex picture of local effects since they affect the microvasculature in addition to being myotoxic (Homma and Tu, 1971; Ownby, 1982; Mebs et al., 1983). It has been shown clinically that in these cases regeneration is somehow impaired, and that sequelae such as tissue loss and dysfunction are frequently observed following poisoning by crotaline snakes (Okonogi et al., 1964; Rosenfeld, 1971; Ownby, 1982).

Bothrops asper, a crotaline snake, is responsible for most of the snakebite cases in Central America (Bolaños, 1982). Its venom induces prominent local effects which are only partially neutralized by the polyvalent antivenom (Gutiérrez et al., 1980a; Gutiérrez et al., 1981). It has been described in the clinical literature that tissue loss is a consequence of B. asper poisonings (Picado, 1931; Jiménez and García, 1969). In order to gain a better understanding of the phenomenon of tissue loss after B. asper envenomation, the characteristics of the regenerative process that takes place in skeletal muscle after injections of B. asper venom and myotoxin in mice have been investigated.

## Materials and Methods

### Venom and Toxin

Bothrops asper venom was a generous gift from Dr. Luis Cerdas, Instituto Clodomiro Picado, Universidad de Costa Rica. The venom is a pool obtained from more than 50 specimens collected in the Atlantic slopes of Costa Rica. Myotoxin was isolated as described in Chapter III. Homogeneity was demonstrated by disc-polyacrylamide gel electrophoresis (pH 4.3) as previously described.

### Histological and Ultrastructural Studies

Groups of four mice (Charles River, CD-1) weighing  $20 \pm 2$  g were injected intramuscularly dorsolaterally in the thigh with venom (2.5  $\mu\text{g/g}$ ), toxin (2.5  $\mu\text{g/g}$ ) or physiologic saline solution. At five time intervals (two days, four days, one week, two weeks, and four weeks) mice were killed by cervical dislocation and a sample of muscle obtained from the ventromedial aspect of the thigh. The tissue was processed as previously described by Ownby et al. (1976). Thick sections were stained with Mallory's trichrome, and thin sections (silver to light gold) were stained with methanolic uranyl acetate and lead citrate, and examined in a Philips EM 200 electron microscope. A total of 52 mice was used.

### Measurement of Cell Diameters

The diameter of regenerating muscle cells was measured using a Zeiss light microscope equipped with a Zeiss MOP 3 Image Analyzer in samples obtained one month after injection. The tissue was oriented to provide cross-sections of muscle cells. A regenerating cell was defined as a muscle cell with a centrally located nucleus. A total of 1000 cells was measured in each experimental group, and the mean and SEM of each group was determined. To determine the significance of the differences observed a t test was used comparing the calculated value to the Z table because of the large sample size.

### Estimation of Capillary/ Muscle Cell Ratio

In order to study the alterations induced by crude B. asper venom in the microvasculature, the capillary/muscle cell ratio was estimated in samples obtained 30 minutes after injection, as compared with control mice injected with physiologic saline solution. The ratio was estimated in envenomated muscle only in areas that had been affected by the venom (i.e. areas that showed either myonecrosis or hemorrhage). In order to study the revascularization of damaged muscle, the capillary/muscle cell ratio was estimated in samples obtained one month after injection. A blood vessel was counted as a capillary when it had a well

defined lumen and a diameter between five and 10  $\mu\text{m}$  (Simionescu and Simionescu, 1983). Four sections of tissue were studied from each mouse; in each section the total number of capillaries and skeletal muscle cells was counted using a Zeiss light microscope equipped with a Zeiss MOP 3 Image Analyzer. For each experimental group, the mean and SEM were determined, and the student's t test was used to determine the significance of the differences observed.

## Results

### Regeneration After Toxin-Induced Myonecrosis

Forty-eight hours after toxin injection there was a widespread necrosis of skeletal muscle cells. An active process of phagocytosis was indicated by the presence of many phagocytes in the interstitial connective tissue as well as inside necrotic muscle cells. The presence of many small, regenerating cells located within the basal lamina of necrotic cells at four days indicated that regeneration was underway (Figure 19A). At this time myotubes were evident in longitudinal sections. By one and two weeks there were many small regenerating cells with central nuclei (Figure 19B). These cells contained normal Golgi complexes, mitochondria, sarcoplasmic reticulum, and T tubules (Figures 20 and 21). The plasma membrane and basal lamina were intact. In some cells there were membrane whorls near

Figure 19. Light micrographs of thick sections of muscle taken after injection of myotoxin. (A) Four days. Small regenerating muscle cells (R) are observed within the basal lamina of necrotic muscle cells (N). (B) Two weeks. Regenerating muscle cells (R) with centrally-located nuclei are observed. Sections stained with Mallory's trichrome.

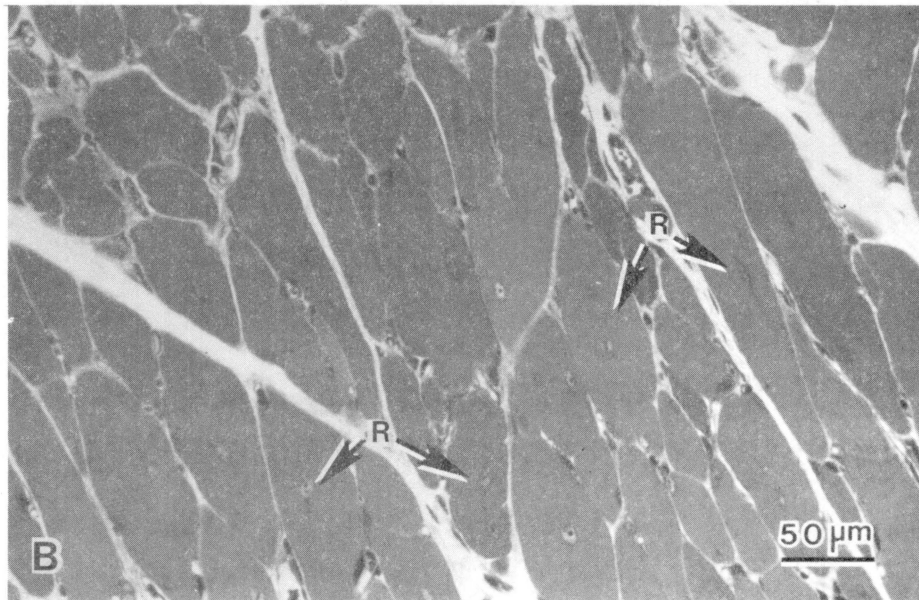
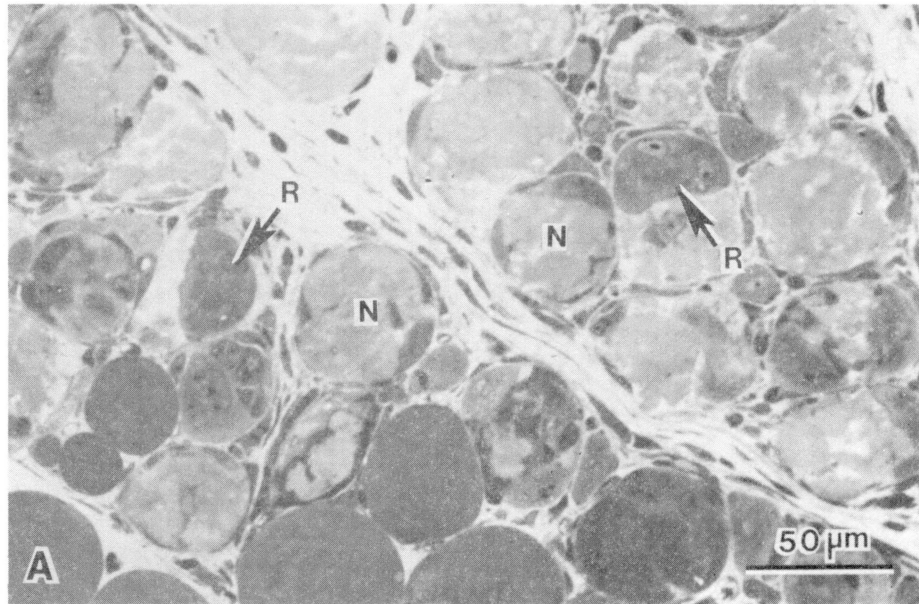
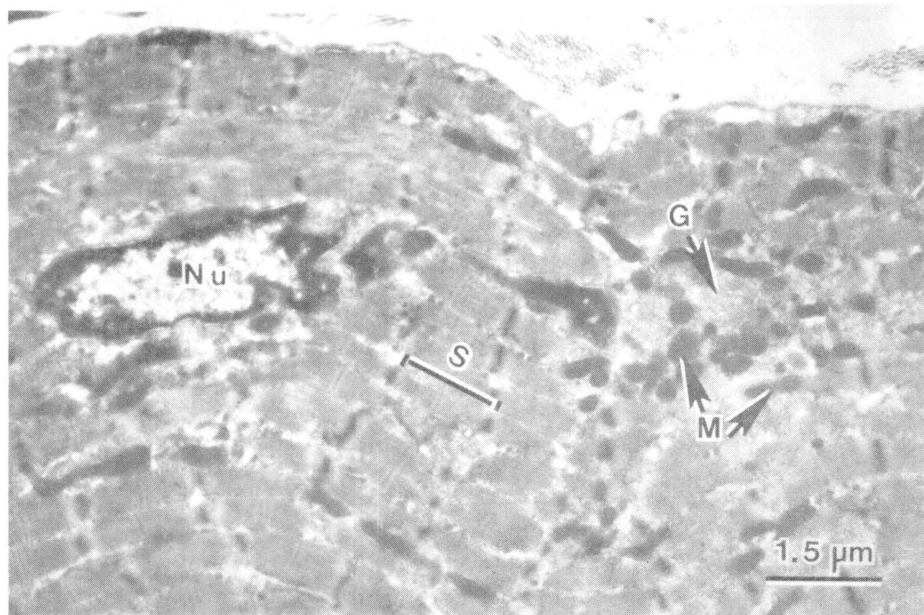
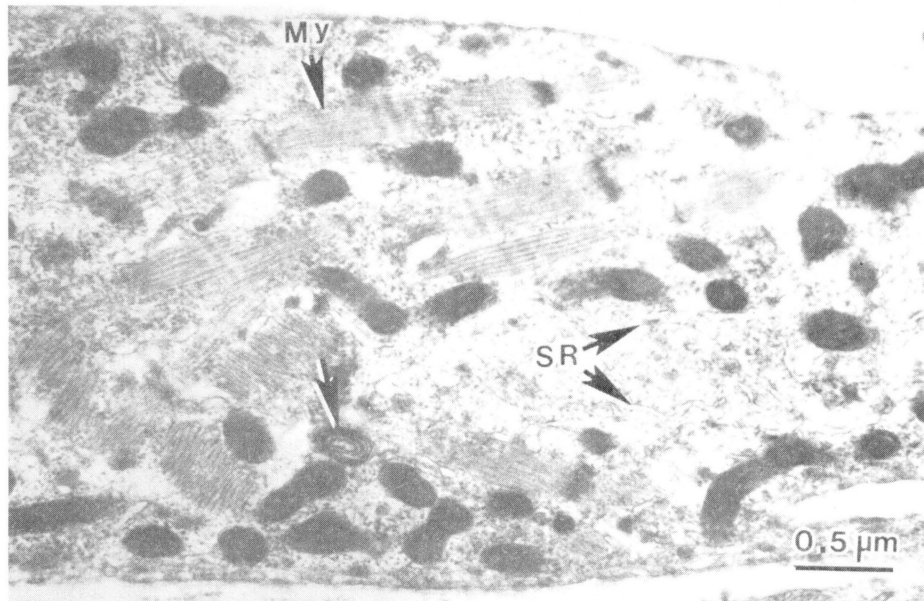


Figure 20. Electron micrograph of a portion of a regenerating muscle cell one week after injection of myotoxin. Myofibrils (My) appear in an early stage of organization. Mitochondria and ribosomes are abundant. Note the presence of sarcoplasmic reticulum (SR) and membrane whorl (arrow). Section stained with uranyl acetate and lead citrate.

Figure 21. Electron micrograph of a regenerating muscle cell two weeks after injection of myotoxin. Myofibrils are organized into sarcomeres (S), and the nucleus (N) is centrally located. The basal lamina and plasma membrane appear intact. Note the presence of Golgi complex (G) as well as mitochondria (M). Section stained with uranyl acetate and lead citrate.





the plasma membrane. Myofibrils were observed in different stages of development; some cells had short, randomly dispersed myofibrils that may have been undergoing a process of assembly (Figure 20). Other cells were in a more advanced stage of myofibrillar organization, with longitudinally oriented bundles of myofilaments and with a normal alignment of sarcomeres (Figure 21). Regenerating cells contained many ribosomes, either free or as polyribosomes.

At the fourth week muscle cells had all the characteristics of mature cells, with the exception of centrally located nuclei. Nerves and blood vessels remained intact throughout the process of regeneration, and the amount of interstitial collagen did not increase significantly.

#### Regeneration After Venom-Induced Myonecrosis

By 48 hours abundant phagocytes were located inside necrotic muscle cells. Four days after injection there were many fibroblasts as well as small myotubes located within the basal lamina of necrotic cells, indicating that regeneration was taking place. However, the process of regeneration after venom-induced myonecrosis did not show the same characteristics observed after toxin inoculation. Observations made at one and two weeks indicated that there were four main areas based on the predominant cell type present: (a) Necrotic muscle cells; (b) regenerating muscle cells; (c) fibroblasts and collagen; and (d) adipocytes.

Areas of Necrotic Muscle Cells. There were groups of necrotic muscle cells which lacked organized myofibrils (Figure 22A).

Areas of Regenerating Muscle Cells. At the light microscopic level these cells had centrally-located nuclei (Figure 22B). At the electron microscopic level there were many free ribosomes and polyribosomes in the cytoplasm, and the myofibrils showed various degrees of development. In some cells there were bundles of myofibrils which were apparently undergoing synthesis and longitudinal assembly, whereas in other cells the myofibrils had the typical fully-developed striated pattern. Thus, these cells had the same morphologic characteristics described for regenerating cells after toxin-induced myonecrosis (see Figures 20 and 21).

Areas of Fibroblasts and Collagen. There were areas in which fibroblasts were the predominant cell type (Figure 22C). In these areas there were isolated regenerating muscle cells which were usually of small diameter and surrounded by fibroblasts and dense bundles of collagen. These areas contained nerves in which nerve fibers were demyelinated (Figure 22C). At the electron microscopic level a well developed endoplasmic reticulum was observed in the fibroblasts, as well as abundant collagen fibers (Figure 23). Many fibroblasts had a ruffled surface with cellular

Figure 22. Light micrographs of thick sections of muscle taken one week after injection of B. asper venom. (A) Area of necrotic muscle cells (N). All the cells are necrotic, with disorganization of myofibrils. (B) Area of regenerating muscle cells. Note that regenerating cells (R) have centrally-located nuclei. (C) Area of fibroblasts and collagen. Note the numerous fibroblasts (F) and collagen fibers in contrast to the small number of regenerating muscle cells (R). Also note the presence of three nerves in which axons are demyelinated (arrows). (D) Area of adipocytes. Some adipocytes (Ad) contain large lipid inclusions. There are also many adipocyte precursors (arrows) which contain several small lipid inclusions in their cytoplasm. Sections stained with Mallory's trichrome.

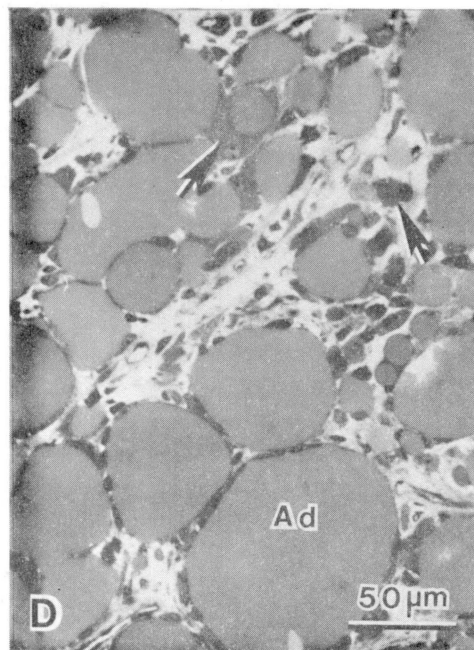
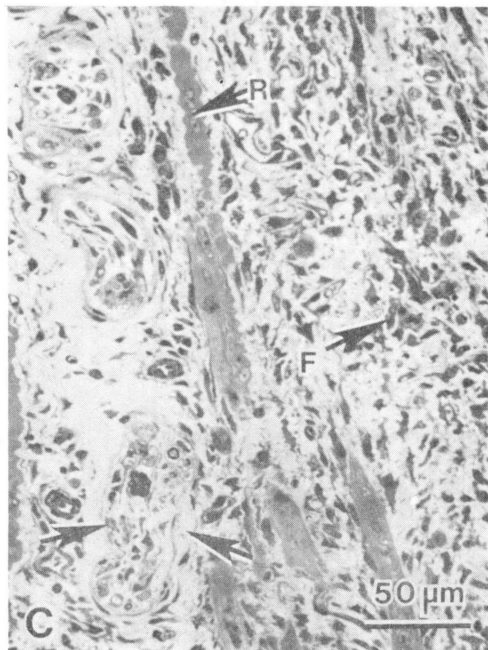
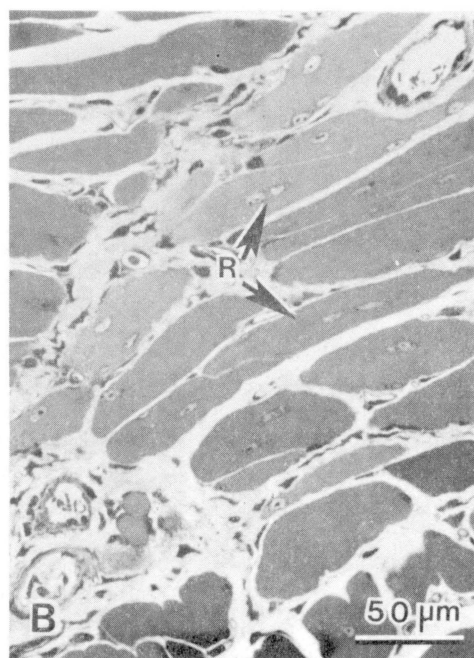
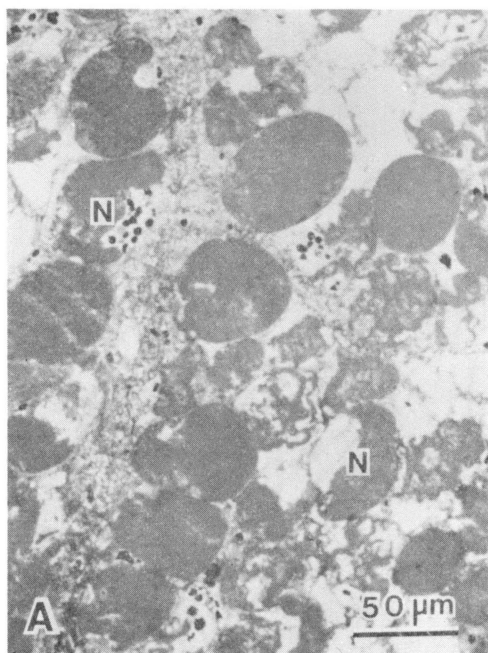


Figure 23. Electron micrograph of an area of fibroblasts and collagen fibers two weeks after injection of B. asper venom. Note the presence of abundant collagen fibers (arrows) and a portion of a fibroblast (F). Section stained with uranyl acetate and lead citrate.



projections in many directions.

Areas of Adipocytes. At the light microscopic level these areas contained cells with their cytoplasm filled with large lipid inclusions, as well as cells which resembled adipocyte precursors (Figure 22D). Other cells had a larger lipid droplet with a rim of cytoplasm surrounding it. These cells had an ovoid shape and a peripherally located nucleus (Figure 22D). Thus, they presented the characteristic features of mature adipocytes (Greenwood and Johnson, 1983). Ultrastructurally, these cells contained few mitochondria and scanty endoplasmic reticulum, and the lipid inclusions present in the precursor cells were of different sizes (Figure 24).

Samples obtained four weeks after venom injection showed an almost complete regeneration in most of the areas examined. However, in some zones regenerated cells were small. Moreover, in other areas there was an increase in collagen in the interstitial space (Figure 25) and nests of small regenerating cells were surrounded by adipose tissue and collagen (Figure 26).

#### Measurements of Cell Diameters

The diameter of regenerating cells in samples obtained four weeks after injection of crude venom ( $14.9 \mu\text{m} \pm 0.3$ ;  $n=1000$ ) was significantly smaller ( $p < 0.001$ ) than the diameter of regenerating cells in mice injected with toxin



Figure 24. Electron micrograph from muscle obtained one week after injection of B. asper venom. This adipocyte precursor contains many small lipid inclusions (L) of variable size. The nucleus (N) with peripheral chromatin is observed. Section stained with uranyl acetate and lead citrate.

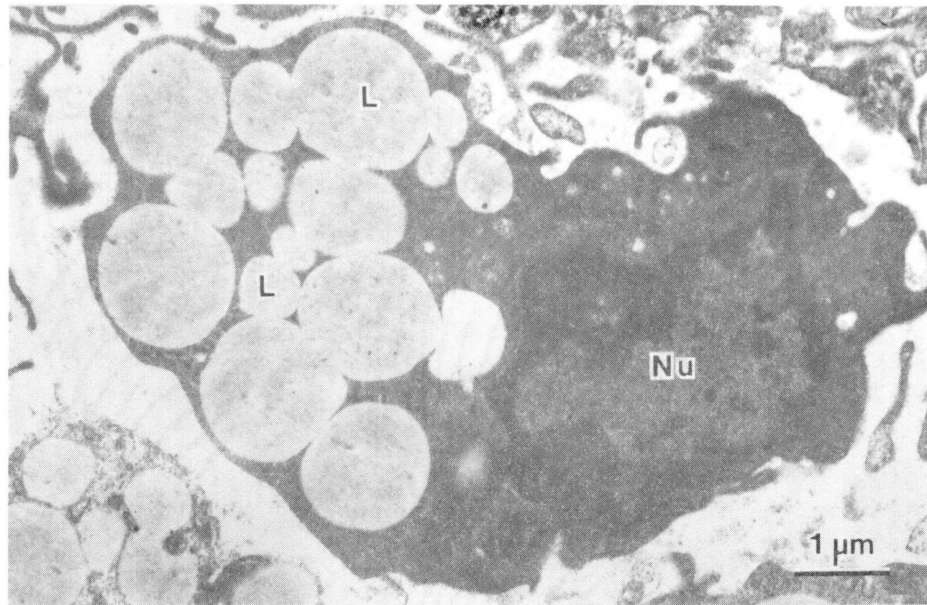
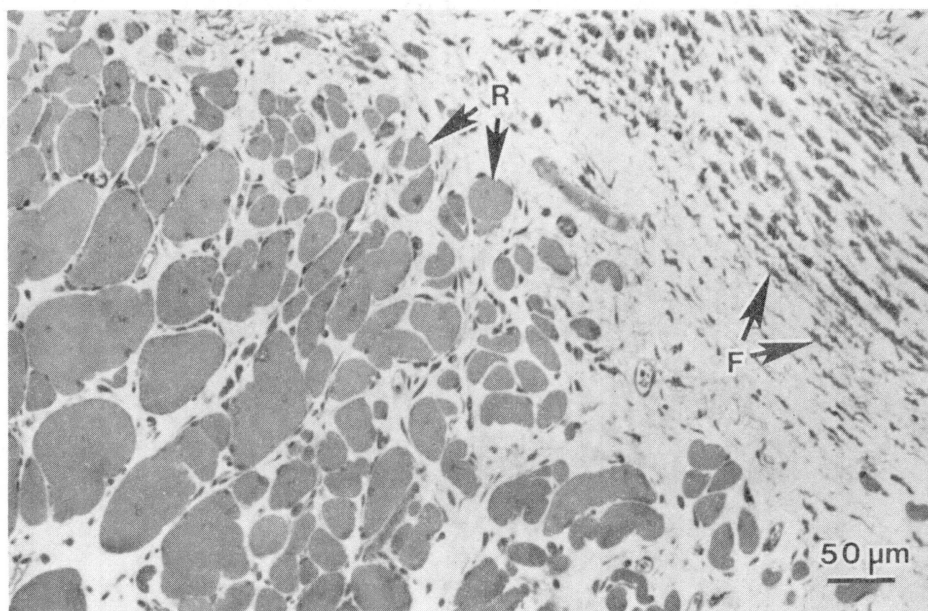
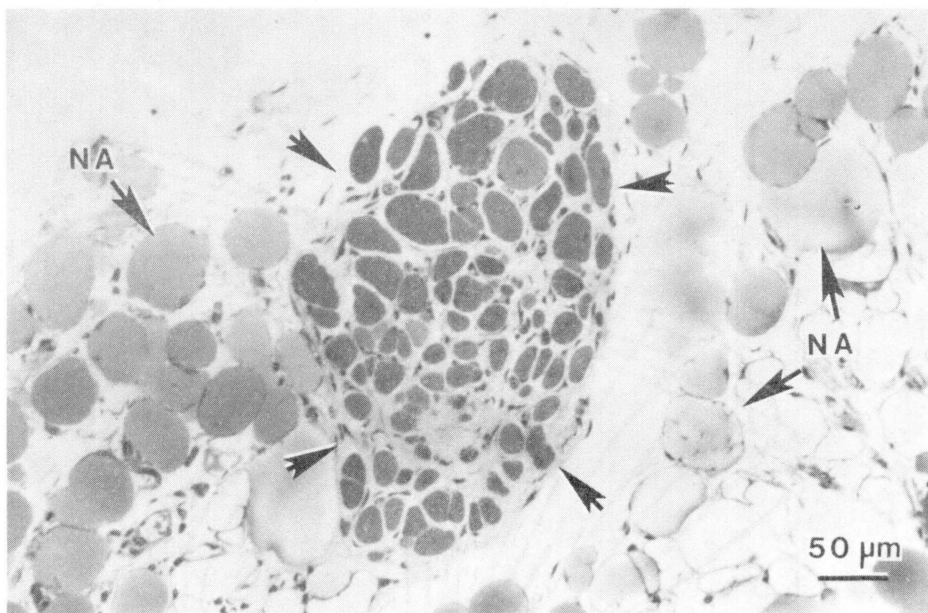


Figure 25. Light micrograph of a thick section of muscle taken four weeks after injection of B. asper venom. Small regenerating cells (R) are surrounded by a dense fibrotic area in which many fibroblasts (F) are present. Section stained with Mallory's trichrome.

Figure 26. Light micrograph of a thick section of muscle taken four weeks after injection of B. asper venom. A nest of small regenerating muscle cells (outlined by arrows) is surrounded by normal unilocular adipocytes (NA). Section stained with Mallory's trichrome.

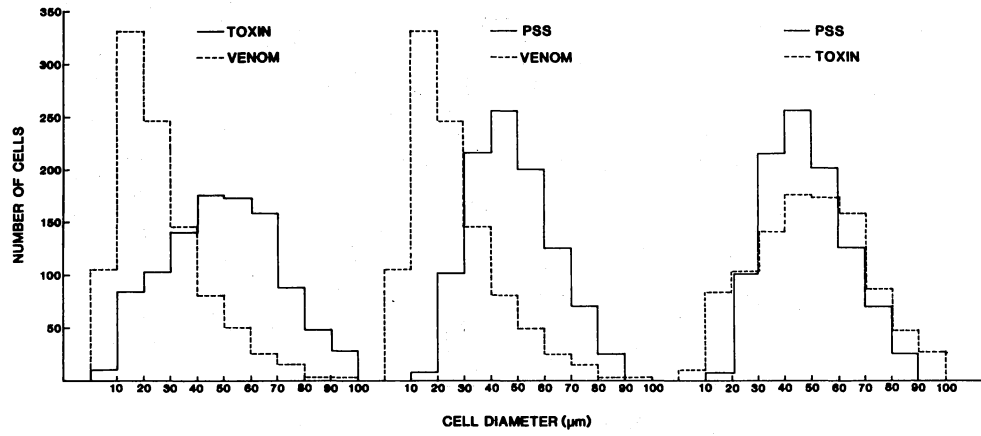


( $48.1 \mu\text{m} \pm 0.2$ ;  $n=1000$ ) and the diameter of normal muscle cells ( $46.6 \mu\text{m} \pm 0.2$ ;  $n=1000$ ) (Figure 27). On the other hand, no significant difference ( $p > 0.01$ ) was observed between the diameter of regenerating muscle cells in mice injected with toxin and the diameter of control muscle cells (Figure 27).

Estimation of Capillary/  
Muscle Cell Ratio

The capillary/muscle cell ratio in muscle injected with physiologic saline solution was  $1.45 \pm 0.04$  ( $n=4$ ). This is very similar to the value of  $1.49 \pm 0.07$  obtained for the same ratio in a variety of muscle from five mammalian species (Plyley and Groom, 1975). In contrast, the capillary/muscle cell ratio in muscle obtained 30 minutes after injection of B. asper venom was significantly lower ( $0.30 \pm 0.06$ ;  $p < 0.01$ ). This corroborates an earlier finding which indicates that B. asper venom induces a hemorrhagic effect as early as 30 minutes after injection. When the ratio was estimated in samples obtained four weeks after venom injection, a value of  $0.85 \pm 0.09$  ( $n=4$ ) was obtained. This indicates that there was revascularization; however, the ratio at four weeks was still significantly lower ( $p < 0.01$ ) than that from control muscle.

Figure 27. Distribution of cell diameters in regenerating muscle cells four weeks after intramuscular injection of B. asper venom, myotoxin, and physiologic saline solution.



## Discussion

In our experimental conditions, i.e. using a dose of 2.5 µg/g, regeneration after toxin-induced myonecrosis corresponds closely with normal regeneration (Allbrook, 1981), whereas in mice injected with crude venom regeneration was not normal. In muscle taken from mice injected with crude venom there were areas of fibrosis and adipocytes as well as areas of regeneration in which the diameter of regenerating muscle cells was abnormally small.

In order for muscle regeneration to proceed normally, several requirements must be met: (a) Adequate blood flow to the tissue (Allbrook, 1981); (b) the presence of an intact basal lamina which plays the role of a scaffold for regeneration (Vracko and Benditt, 1972); and (c) adequate innervation to muscle (Hall-Craggs and Seyan, 1975). It has been shown that B. asper myotoxin does not affect the integrity of blood vessels, nerves, or basal lamina (see Chapter IV); this may explain why regeneration proceeded in the normal way after myotoxin injection. Such observation correlates with other studies which showed that regeneration after myonecrosis induced by the elapine toxins notexin (Harris et al., 1980) and taipoxin (Harris and Maltin, 1982; Maltin et al., 1983) proceeded fast and was completed by one month. Similar findings were described in the case of myotoxicity induced by the local anesthetic bupivacaine (Nonaka et al., 1983). It is significant that in these



cases there was no damage to the microvasculature, and the basal laminae were preserved as well.

After crude B. asper venom injection there was prominent hemorrhage (see Chapter IV). These results show that there was a significant decrease in the capillary/muscle cell ratio in samples taken as early as 30 minutes after injection. This would obviously affect the blood supply to the regenerating muscle. However, the tissue examined four weeks after venom injection showed a partial revascularization of bundles of muscle cells. It has been shown that after transplantation of skeletal muscle most blood vessels degenerate initially, and revascularization takes place due to vessel growth either from the host tissue (Hansen-Smith et al., 1980) or from surviving vessels in the graft (Faulkner et al., 1983). Nevertheless, it is possible that in our experimental conditions revascularization after venom injection is not complete by the time critical steps in muscle regeneration are taking place. Thus, in some areas there may be a functional ischemia during regeneration; the fact that the capillary/muscle cell ratio is decreased even at one month after injection supports this view. Furthermore, the increased collagen deposition and fibrosis observed in some areas may affect the diffusion of oxygen to regenerating cells. In the case of Duchenne muscular dystrophy, it has been proposed that the decrease in muscle regeneration observed in older patients may be due to a progressive accumulation of intersti-

tial collagen which would affect oxygen diffusion and create local ischemia (Lipton, 1979). Also, in samples obtained after venom injection there were alterations in peripheral nerves; although the basis for this damage was not studied, this may be an additional factor that interferes with normal regeneration. Harris et al. (1975) observed that the diameter of regenerating skeletal muscle cells was small in denervated muscle as compared with normally innervated muscle.

In conclusion, this study shows that muscle regeneration does take place after myonecrosis induced by injections of B. asper venom and myotoxin, despite the fact that it is partially impaired when using the crude venom. These observations raise a question about the effectiveness of therapeutic devices based on the debridement of necrotic tissue after snakebite accidents, since such procedures probably eliminate the myogenic cells along with the necrotic tissue. On the other hand, these findings suggest that regeneration is partially impaired in muscle injected with venom perhaps as a consequence of diminished blood supply to some areas due to the action of some venom components on the microvasculature.

## CHAPTER VI

### SUMMARY AND CONCLUSIONS

A myotoxic phospholipase has been isolated from Bothrops asper venom by ion-exchange chromatography on CM-Sephadex followed by gel filtration on Sephadex G-75. The toxin is a basic polypeptide with an estimated molecular weight of 10,700. It has both phospholipase A and indirect hemolytic activities, but is devoid of proteolytic, direct hemolytic, and hemorrhagic effects. When injected intramuscularly into mice the toxin induces a rapid increase in plasma creatine kinase levels and a series of degenerative events in skeletal muscle which lead to myonecrosis. The toxin induces an increase in intracellular calcium levels, and is able to hydrolyze muscle phospholipids "in vivo". Pretreatment with the calcium antagonist verapamil failed to prevent myotoxic activity.

Furthermore, the pathogenesis of skeletal muscle necrosis induced by crude Bothrops asper venom and the isolated myotoxic phospholipase was studied using light and electron microscopy. White mice were injected intramuscularly with a dose of 2.5 µg/g and tissue samples were taken at 30 minutes, 1, 3, 6, 12, 24, and 48 hours. Toxin-injected muscle showed localized wedge-shaped lesions

("delta lesions") by 30 minutes, which included disrupted plasma membranes. At one and three hours the predominant type of necrotic cell contained clumped myofibrils in which individual myofilaments were indistinguishable. At later time periods there was a relaxation and redistribution of myofilaments resulting in a more homogeneous and hyaline appearance of necrotic cells. Some mitochondria were swollen and had flocculent densities, and most of them were disrupted, having only one membrane and vesiculated cristae. The basal lamina was intact at all time intervals. Phagocytosis of muscle cell debris started at three hours and was prominent by 24-48 hours. In crude venom-injected muscle many cells showed pathologic features identical to those observed after myotoxin injection. Crude venom also induced hemorrhage which was evident 30 minutes after injection, reaching its highest level by 12 hours. At 3, 6, and 12 hours some cells were undergoing different pathologic changes which appeared to be due to ischemia. Although these cells were irreversibly damaged, as indicated by ruptured plasma membrane, their myofibrillar structure was better preserved than that of toxin-affected cells. The Z line was absent, but A, I, H, and M bands were intact. As a result of Z line loss, sarcomeres were disoriented. It was proposed that the myotoxin induces myonecrosis by first altering the integrity of the plasma membrane, thereby increasing the permeability to calcium, other ions, and molecules, all of which leads to death of the cell. It was

also suggested that myotoxicity is at least partially due to the phospholipase A activity of the toxin. Crude venom has been shown to affect muscle in two ways: by direct action of myotoxin(s) and by ischemia due to hemorrhage.

In addition, skeletal muscle regeneration was studied following injections of Bothrops asper venom and the myotoxin isolated from the crude venom. In toxin-injected muscle regeneration proceeded normally. By four days there were myotubes and small regenerating cells. The size of the cells increased by one and two weeks, and by four weeks regenerating cells were fully developed, except for centrally located nuclei. The regenerative process in venom-injected muscle was somewhat different; by one and two weeks four main areas were observed in the tissue, based on the predominant cell type present: (a) Necrotic muscle cells; (b) regenerating muscle cells; (c) fibroblasts and collagen; and (d) adipocytes. Furthermore, some nerve fibers were demyelinated. Samples obtained four weeks after venom injection showed an almost complete regeneration in many areas, whereas in other areas nests of small regenerating cells were surrounded by portions of adipose tissue and collagen. At four weeks regenerating cells in venom-injected muscle were significantly smaller than cells in toxin-injected and saline-injected muscles. There was a significant reduction in capillary/muscle cell ratio 30 minutes after injection of B. asper venom. Since B. asper venom drastically affects the microvasculature, it was

proposed that the impairment of regeneration after injection of crude venom is a consequence of diminished blood supply to some areas of the muscle.

#### LITERATURE CITED

- Alagón, A.C., Molinar, R.R., Possani, L.D., Fletcher, P.L., Cronan, J.E. and Julia, J.Z. (1980) Venom from the snake Bothrops asper Garman. Purification and characterization of three phospholipases A<sub>2</sub>. Biochem. J. 185: 605-704.
- Allbrook, D. (1981) Skeletal muscle regeneration. Muscle & Nerve 4: 234-245.
- Almers, W., Fink, R. and Palade, P.T. (1981) Calcium depletion in frog muscle tubules: the decline of calcium current under maintained depolarization. J. Physiol. 312: 177-207.
- Aragón, F. and Gubensek, F. (1978) Characterization of thrombin-like proteinase from Bothrops asper venom. In: Toxins: Animal, Plant and Microbial, pp 107-111 (Rosenberg, P., Ed.). Oxford: Pergamon Press.
- Aragón, F. and Gubensek, F. (1981) Bothrops asper from the Atlantic and Pacific zones of Costa Rica. Toxicon 19: 797-805.
- Aragón, F., Kopitar, M., Babnik, J. and Gubensek, F. (1978) Some properties of two fibrinolytic enzymes from the venom of Bothrops asper. Period. biol. 80: 91-96.
- Arroyo, O. and Gutiérrez, J.M. (1981) Estudio ultraestructural de la mionecrosis inducida en ratón por el veneno de terciopelo (Bothrops asper) de Costa Rica. Toxicon 19: 773-782.
- Benoit, P.W., Yagiela, J.A. and Fort, N.F. (1980) Pharmacologic correlation between local anesthetic-induced myotoxicity and disturbances of intracellular calcium distribution. Toxicol. Appl. Pharmac. 52: 187-198.
- Bieber, A.L., Tu, T. and Tu, A.T. (1975) Studies of an acidic cardiotoxin isolated from the venom of Mojave rattlesnake (Crotalus scutulatus). Biochim. Biophys. Acta 400: 178-188.

- Bischoff, R. (1979) Tissue culture studies on the origin of myogenic cells during muscle regeneration in the rat. In: Muscle Regeneration, pp 13-29 (Mauro, A., Ed.). New York: Raven Press.
- Bjarnason, J.B. and Tu, A.T. (1978) Hemorrhagic toxins from Western diamondback rattlesnake (Crotalus atrox) venom: Isolation and characterization of five toxins and the role of zinc in hemorrhagic toxin e. Biochemistry 17: 3395-3404.
- Bodensteiner, J.B. and Engel, A.G. (1978) Intracellular calcium accumulation in Duchenne dystrophy and other myopathies: A study of 567,000 muscle fibers in 114 biopsies. Neurology 28: 439-446.
- Bolaños, R. (1971) Nuevos recursos contra el ofidismo en Centroamérica. San José: Ministerio de Salubridad Pública y Universidad de Costa Rica.
- Bolaños, R. (1972) Toxicity of Costa Rican snake venoms for the white mouse. Am. J. Trop. Med. Hyg. 21: 360-363.
- Bolaños, R. (1982) Las serpientes venenosas de Centroamérica y el problema del ofidismo. Primera parte. Aspectos zoológicos, epidemiológicos y biomédicos. Rev. Cost. Cienc. Méd. 3: 165-184.
- Bolaños, R. and Cerdas, L. (1978) The production and control of anti-venoms sera. Develop. Biol. Standard. 41: 109-114.
- Breithaupt, H., Rubsam, K. and Habermann, E. (1974) Biochemistry and pharmacology of the crotoxin complex. Biochemical analysis of crotapotin and the basic crotalus phospholipase A. Eur. J. Biochem. 49: 333-345.
- Busch, W.A., Stromer, M.H., Goll, D.E. and Suzuki, A. (1972)  $Ca^{2+}$ -specific removal of Z lines from rabbit skeletal muscle. J. Cell Biol. 52: 367-381.
- Cameron, D.L. and Tu, A.T. (1977) Characterization of myotoxin a from the venom of prairie rattlesnake (Crotalus viridis viridis). Biochemistry 16: 2546-2553.
- Cameron, D.L. and Tu, A.T. (1978) Chemical and functional homology of myotoxin a from prairie rattlesnake venom and crotamine from South American rattlesnake venom. Biochim. Biophys. Acta 532: 147-154.



- Campbell, C.H. (1979) Symptomatology, pathology and treatment of the bites of elapid snakes. In: Snake Venoms, pp 898-921 (Lee, C.Y., Ed.). Berlin: Springer-Verlag.
- Carafoli, E. (1982) Membrane transport and the regulation of the cell calcium levels. In: Pathophysiology of Shock, Anoxia, and Ischemia, pp 95-112 (Cowley, R.A. and Trump, B.F., Eds.). Baltimore: Williams & Wilkins.
- Carlson, R.W., Schaeffer, R.C., Whigham, H., Michaelis, S., Russell, F.E. and Weil, M.H. (1975) Rattlesnake venom shock in the rat: Development of a method. Am. J. Physiol. 229: 1668-1674.
- Cate, R.L. and Bieber, A.L. (1978) Purification and characterization of Mojave (Crotalus scutulatus scutulatus) toxin and its subunits. Arch. Biochem. Biophys. 189: 397-408.
- Chang, C.C. (1979) The action of snake venoms on nerve and muscle. In: Snake Venoms, pp 309-376 (Lee, C.Y., Ed.). Berlin: Springer-Verlag.
- Chang, C.C. and Tseng, K.H. (1978) Effect of crotamine, a toxin of South American rattlesnake venom, on the sodium channel of murine skeletal muscle. Br. J. Pharmac. 63: 551-559.
- Civello, D.J., Duong, H.L. and Geren, C.L. (1983a) Isolation and characterization of a hemorrhagic proteinase from timber rattlesnake venom. Biochemistry 22: 749-755.
- Civello, D.J., Moran, J.B. and Geren, C.L. (1983b) Substrate specificity of a hemorrhagic proteinase from timber rattlesnake venom. Biochemistry 22: 755-762.
- Clausen, J. (1969) Immunological techniques for the identification and estimation of macromolecules. In: Laboratory Techniques in Biochemistry and Molecular Biology, Vol 2, part III (Work, T.S. and Work, E., Eds.). Amsterdam: North Holland.
- Condrea, E., Fletcher, J.E., Rapuano, B.E., Yang, C.C. and Rosenberg, P. (1981) Dissociation of enzymatic activity from lethality and pharmacological properties by carbamylation of lysines in Naja nigricollis and Naja naja atra snake venom phospholipases A<sub>2</sub>. Toxicon 19: 705-720.

- Cullen, M.J. and Fulthorpe, J.J. (1975) Stages in fibre breakdown in Duchenne muscular dystrophy. An electron-microscopic study. J. neurol. Sci. 24: 179-200.
- Duchen, L.W., Excell, B.J., Patel, R. and Smith, B. (1974) Changes in motor end-plates resulting from muscle fibre necrosis and regeneration. A light and electron microscopic study of the effects of the depolarizing fraction (cardiotoxin) of Dendroaspis jamesoni venom. J. neurol. Sci. 21: 391-417.
- Dufourcq, J., Faucon, J.F., Bernard, E. and Pezolet, M. (1982) Structure-function relationships for cardiotoxins interacting with phospholipids. Toxicon 20: 165-174.
- Duncan, C.J. (1978) Role of intracellular calcium in promoting muscle damage: A strategy for controlling the dystrophic condition. Experientia 34: 1531-1535.
- Efrati, P. (1979) Symptomatology, pathology and treatment of the bites of viperid snakes. In: Snake Venoms, pp 956-977 (Lee, C.Y., Ed.). Berlin: Springer-Verlag.
- Eneff, K. (1982) Isolation and partial characterization of two muscle necrotic toxins from the venom of the Central American rattlesnake, Crotalus durissus durissus. M.Sc. Thesis. Oklahoma State University.
- Engle, C.M., Becker, R.R., Bailey, T. and Bieber, A.L. (1983) Characterization of two myotoxic proteins from venom of Crotalus viridis concolor. Fed. Proc. 42: 2187.
- Fabiano, R. and Tu, A.T. (1981) Purification and biochemical study of viriditoxin, tissue damaging toxin, from prairie rattlesnake venom. Biochemistry 20: 21-27.
- Farber, J.L. (1981) The role of calcium in cell death. Life Sciences 29: 1289-1295.
- Farber, J.L. (1982) Membrane injury and calcium homeostasis in the pathogenesis of coagulative necrosis. Lab. Invest. 47: 114-123.
- Faulkner, J.A., Weiss, S.W. and McGeachie, J.K. (1983) Revascularization of skeletal muscle transplanted into the hamster cheek pouch: Intravital and light microscopy. Microv. Res. 26: 49-64.

- Ferlan, I. and Gubensek, F. (1978) Phospholipases of Bothrops asper venom. Period. biol. 80: 31-36.
- Fohlman, J. and Eaker, D. (1977) Isolation and characterization of a lethal myotoxic phospholipase A from the venom of the common sea snake Enhydrina schistosa causing myoglobinuria in mice. Toxicon 15: 385-393.
- Fohlman, J., Lind, P. and Eaker, D. (1977) Taipoxin, an extremely potent presynaptic snake venom neurotoxin. Elucidation of the primary structure of the acidic carbohydrate-containing taipoxin subunit, a phospholipase homolog. FEBS Letters 84: 367-371.
- Fohlman, J., Eaker, D., Karlsson, E. and Thesleff, S. (1976) Taipoxin, an extremely potent presynaptic neurotoxin from the venom of the Australian snake taipan (Oxyuranus s. scutellatus). Isolation, characterization, quaternary structure and pharmacological properties. Eur. J. Biochem. 68: 457-469.
- Fox, J.W., Elzinga, M. and Tu, A.T. (1979) Amino acid sequence and disulfide bond assignment of myotoxin a isolated from the venom of prairie rattlesnake (Crotalus viridis viridis). Biochemistry 18: 678-684.
- Frischauf, A.M. and Eckstein, F. (1973) Purification of a phosphodiesterase from Bothrops atrox venom by affinity chromatography. Eur. J. Biochem. 32: 479-485.
- Geiger, R. and Kortmann, H. (1977) Esterolytic and proteolytic activities of snake venoms and their inhibition by proteinase inhibitors. Toxicon 15: 257-259.
- Georgatsos, J.G. and Laskowski, M. (1962) Purification of an endonuclease from the venom of Bothrops atrox. Biochemistry 1: 288-294.
- Ginn, F.L., Shelburne, J.D. and Trump, B.F. (1968) Disorders of cell volume regulation. I. Effects of inhibition of plasma membrane adenosine triphosphatase with ouabain. Am. J. Pathol. 53: 1041-1071.
- Glass, R.E. and Banthorpe, D.V. (1975) Properties of nerve growth factor from the venom of Bothrops atrox. Biochim. Biophys. Acta 405: 23-26.
- Gleason, M.L., Odell, G.V. and Ownby, C.L. (1983) Isolation and biological activity of viriditoxin and a viriditoxin variant from Crotalus viridis viridis. Toxin Rev. (in press).

- Glenn, J.L., Straight, R.C., Wolfe, M.C. and Hardy, D.L. (1983) Geographical variation in Crotalus scutulatus scutulatus (mojave rattlesnake) venom proteins. Toxicon 21: 119-130.
- Goin, C.J. and Goin, O.B. (1962) Introduction to Herpetology. San Francisco: W. H. Freeman.
- Gopalakrishnakone, P., Hawgood, B., Holbrooke, S.E., Marsh, N.A., Santana de Sa, S. and Tu, A.T. (1979) Sites of action of mojave toxin isolated from the venom of Crotalus scutulatus scutulatus in comparison with the action of crotoxin from the venom of Crotalus durissus terrificus. Toxicon (Suppl. 1): 56.
- Gopalakrishnakone, P., Hawgood, B., Holbrooke, S.E., Marsh, N.A., Santana de Sa, S. and Tu, A.T. (1980) Sites of action of mojave toxin isolated from the venom of the mojave rattlesnake. Br. J. Pharmac. 69: 421-431.
- Greenwood, M.R.C. and Johnson, P.R. (1983) The adipose tissue. In: Histology. Cell and Tissue Biology, pp 178-199 (Weiss, L., Ed.). New York: Elsevier Biomedical.
- Grotto, L., Moroz, C., de Vries, A. and Goldblum, N. (1967) Isolation of Vipera palestinae hemorrhagin and distinction between its hemorrhagic and proteolytic activities. Biochim. Biophys. Acta 133: 356-362.
- Gulik-Krzywicki, T., Balerna, M., Vincent, J.P. and Lazdunski, M. (1981) Freeze-fracture study of cardiotoxin action on axonal membrane and axonal membrane lipid vesicles. Biochim. Biophys. Acta 643: 101-114.
- Gutiérrez, J.M. and Chaves, F. (1980) Efectos proteolítico, hemorrágico y mionecrótico de los venenos de serpientes costarricenses de los géneros Bothrops, Crotalus y Lachesis. Toxicon 18: 315-321.
- Gutiérrez, J.M., Arroyo, O. and Bolaños, R. (1980a) Mionecrosis, hemorragia y edema inducidos por el veneno de Bothrops asper en ratón blanco. Toxicon 18: 603-610.
- Gutiérrez, J.M., Chaves, F. and Bolaños, R. (1980b) Estudio comparativo de venenos de ejemplares recién nacidos y adultos de Bothrops asper. Rev. Biol. Trop. 28: 341-351.

- Gutiérrez, J.M., Chaves, F., Bolaños, R., Cerdas, L., Rojas, E., Arroyo, O. and Portilla, E. (1981) Neutralización de los efectos locales del veneno de Bothrops asper por un antiveneno polivalente. Toxicon 19: 493-500.
- Habermann, E. and Hardt, K.L. (1972) A sensitive and specific plate test for the quantitation of phospholipases. Analyt. Biochem. 50: 163-173.
- Habermann, E. and Breithaupt, H. (1978) The crotoxin complex- An example of biochemical and pharmacological protein complementation. Toxicon 16: 19-30.
- Hall-Craggs, E.C.B. and Seyan, H.S. (1975) Histochemical changes in innervated and denervated skeletal muscle fibers following treatment with bupivacaine (Marcain). Exp. Neurol. 46: 345-354.
- Halpert, J. and Eaker, D. (1976) Isolation and amino acid sequence of a neurotoxic phospholipase A from the venom of the Australian tiger snake Notechis scutatus scutatus. J. Biol. Chem. 251: 7343-7347.
- Hansen-Smith, F.M., Carlson, B.M. and Irwin, K.L. (1980) Revascularization of the freely grafted extensor digitorum longus muscle in the rat. Am. J. Anat. 158: 65-82.
- Hanzlíková, V. and Schiaffino, S. (1977) Mitochondrial changes in ischemic skeletal muscle. J. Ultrastr. Res. 60: 121-133.
- Harris, J.B. (1982) Restitution of neuromuscular transmission in regenerating rat muscles following assault by the myotoxic neurotoxin notexin. Toxicon 20: 116-117.
- Harris, J.B. and Johnson, M.A. (1978) Further observations on the pathological responses of rat skeletal muscle to toxins isolated from the venom of the Australian tiger snake, Notechis scutatus scutatus. Clin. Exp. Pharmacol. Physiol. 5: 587-600.
- Harris, J.B. and MacDonell, C.A. (1981) Phospholipase A<sub>2</sub> activity of notexin and its role in muscle damage. Toxicon 19: 419-430.
- Harris, J.B. and Maltin, C.A. (1982) Myotoxic activity of the crude venom and the principal neurotoxin, taipoxin of the Australian taipan, Oxyuranus scutellatus. Br. J. Pharmac. 76: 61-75.

- Harris, J.B., Johnson, M.A. and Karlsson, E. (1975) Pathological responses of rat skeletal muscle to a single subcutaneous injection of a toxin isolated from the venom of the Australian tiger snake, Notechis scutatus scutatus. Clin. Exp. Pharmacol. Physiol. 2: 383-404.
- Harris, J.B., Johnson, M.A. and MacDonell, C.A. (1980) Muscle necrosis induced by some presynaptically active neurotoxins. In: Natural Toxins, pp 569-578 (Eaker, D. and Wadstrom, T., Eds.). Oxford: Pergamon Press.
- Hawgood, B.J. (1982) Physiological and pharmacological effects of rattlesnake venoms. In: Rattlesnake Venoms, Their Actions and Treatment, pp 121-162 (Tu, A.T., Ed.) New York: Marcel Dekker.
- Hofmann, H., Dumarey, C. and Bon, C. (1983) Blood coagulation induced by Bothrops atrox venom: Identification and properties of a factor X activator. Biochimie 65: 201-210.
- Hoge, A.R. (1966) Preliminary account of neotropical Crotalinae (Serpentes, Viperidae). Mem. Inst. Butantan 32: 109-184.
- Holleman, W.H. and Weiss, L.J. (1976) The thrombin-like enzyme from Bothrops atrox snake venom. Properties of the enzyme purified by affinity chromatography on p-aminobenzamidine-substituted agarose. J. Biol. Chem. 251: 1663-1669.
- Homma, M. and Tu, A.T. (1971) Morphology of local tissue damage in experimental snake envenomation. Br. J. exp. Pathol. 52: 538-542.
- Ishiura, S. (1981) Calcium-dependent proteolysis in living cells. Life Sciences 29: 1079-1087.
- Iwanaga, S. and Suzuki, T. (1979) Enzymes in snake venom. In: Snake Venoms, pp 61-158 (Lee, C.Y., Ed.). Berlin: Springer-Verlag.
- Jeng, T.W., Hendon, R.A. and Fraenkel-Conrat, H. (1978) Search for relationships among the hemolytic, phospholipolytic, and neurotoxic activities of snake venoms. Proc. Natl. Acad. Sci. USA 75: 600-604.
- Jiménez, E. and García, I. (1969) Análisis de 86 casos de ofidismo en niños. Rev. Méd. Hosp. Nal. Niños 4: 91-99.

- Jiménez-Porras, J.M. (1964) Venom proteins of the fer-de-lance, Bothrops atrox, from Costa Rica. Toxicon 2: 155-166.
- Jiménez-Porras, J.M. (1967) Action of Bothrops atrox (fer-de-lance) venom on blood clotting "in vivo". Abstract. Seventh International Congress of Biochemistry.
- Jiménez-Porras, J.M. (1968) Pharmacology of peptides and proteins in snake venoms. Ann. Rev. Pharmacol. 8: 299-318.
- Jiménez-Porras, J.M., Gómez-Leiva, M.A., Rodríguez-Barquero, J.A., Minton, S.A., Graydon, J.J. and Amaral, A. (1973) Reptile toxins. In: Biology Data Book, Second Ed., Vol II, pp 697-723. Federation of American Societies for Experimental Biology (FASEB).
- Karlsson, E. (1979) Chemistry of protein toxins in snake venoms. In: Snake Venoms, pp 159-212 (Lee, C.Y., Ed.). Berlin: Springer-Verlag.
- Karlsson, E., Eaker, D. and Ryden, L. (1972) Purification of a presynaptic neurotoxin from the venom of the Australian tiger snake Notechis scutatus scutatus. Toxicon 10: 405-413.
- Karpati, G., Carpenter, S., Melmed, C. and Eisen, A.A. (1974) Experimental ischemic myopathy. J. neurol. Sci. 23: 129-161.
- Kocholaty, W.F., Ledford, E.B., Daly, J.G. and Billings, T.A. (1971) Toxicity and some enzymatic properties and activities in the venoms of Crotalidae, Elapidae and Viperidae. Toxicon 9: 131-138.
- Kirby, E.P., Niewiarowski, S., Stocker, K., Kettner, C., Shaw, E. and Brudzynski, T.M. (1979) Thrombocytin, a serine protease from Bothrops atrox venom. I. Purification and characterization of the enzyme. Biochemistry 18: 3564-3570.
- Klibansky, C., London, Y., Frenkel, A. and de Vries, A. (1968) Enhancing action of synthetic and natural basic polypeptides on erythrocyte-ghost phospholipid hydrolysis by phospholipase A. Biochim. Biophys. Acta 150: 15-23.
- Laure, C.J. (1975) Die primärstruktur des crotamins. Hoppe-Seyler's Z. Physiol. Chem. 356: 213-215.

- Leonardi, T.M., Howden, M.E.H. and Spence, I. (1979) A lethal myotoxin isolated from the venom of the Australian king brown snake (Pseudechis australis). Toxicon 17: 549-555.
- Liao, T.H., Robinson, G.W. and Salnikow, J. (1973) Use of narrow-bore columns in amino acid analysis. Anal. Chem. 45: 2268-2288.
- Lind, P. and Eaker, D. (1981) Aminoacid sequence of a lethal myotoxic phospholipase A<sub>2</sub> from the venom of the common sea snake (Enhydrina schistosa). Toxicon 19: 11-24.
- Lind, P. and Eaker, D. (1982) Amino-acid sequence of the  $\alpha$  subunit of taipoxin, an extremely potent presynaptic neurotoxin from the Australian snake taipan (Oxyuranus s. scutellatus). Eur. J. Biochem. 124: 441-447.
- Lipton, B.H. (1977) A fine-structural analysis of normal and modulated cells in myogenic cultures. Develop. Biol. 60: 26-47.
- Lipton, B.H. (1979) Skeletal muscle regeneration in muscular dystrophy. In: Muscle Regeneration, pp 31-40 (Mauro, A., Ed.). New York: Raven Press.
- Lomonte, B., Gené, J.A., Gutiérrez, J.M. and Cerdas, L. (1983) Estudio comparativo de los venenos de serpiente cascabel (Crotalus durissus durissus) de ejemplares adultos y recién nacidos. Toxicon 21: 379-284.
- Maeda, N., Tamiya, N., Pattabhiraman, T.R. and Russell, F.E. (1978) Some chemical properties of the venom of the rattlesnake, Crotalus viridis helleri. Toxicon 16: 431-441.
- Maltin, C.A., Harris, J.B. and Cullen, M.J. (1983) Regeneration of mammalian skeletal muscle following the injection of the snake-venom toxin, taipoxin. Cell Tissue Res. 232: 565-577.
- Mandelbaum, F.R., Reichl, A.P. and Assakura, M.T. (1975) Some physical and biochemical characteristics of HF<sub>2</sub>, one of the hemorrhagic factors in the venom of Bothrops jararaca. Toxicon 13: 109.
- Mauro, A. (1961) Satellite cell of skeletal muscle fibers. J. Biophys. Biochem. Cytol. 9: 493.
- Mebis, D. (1978) Pharmacology of reptilian venoms. In: Biology of the Reptilia, Vol 8, pp 437-560 (Gans, C., Ed.). London: Academic Press.



- Mebs, D. and Samejima, Y. (1980) Purification, from Australian elapid venoms, and properties of phospholipases A which cause myoglobinuria in mice. Toxicon 18: 443-454.
- Mebs, D., Ehrenfeld, M. and Samejima, Y. (1983) Local necrotizing effect of snake venoms on skin and muscle: Relationship to serum creatine kinase. Toxicon 21: 393-404.
- Mebs, D., Scharrer, I., Stille, W. and Hauk, H. (1978) A fatal case of snake bite due to Thelotornis kirtlandii. In: Toxins: Animal, Plant and Microbial, pp 477-479 (Rosenberg, P., Ed.). Oxford: Pergamon Press.
- Mekbel, S.T. and Céspedes, R. (1963) Las lesiones renales en el ofidismo. Acta Méd. Cost. 6: 111-118.
- Mokri, B. and Engel, A.G. (1975) Duchenne dystrophy: Electron microscopic findings pointing to a basic or early abnormality in the plasma membrane of the muscle fiber. Neurology 25: 1111-1120.
- Morales, O., Sandí, M. and Calderón, M. (1976) Efectos cardiovasculares del veneno de Bothrops asper en corazón de anfibios. Rev. Biol. Trop. 24: 69-83.
- Murphy, E., Coll, K., Rich, T.L. and Williamson, J.R. (1980) Hormonal effects on calcium homeostasis in isolated hepatocytes. J. Biol. Chem. 255: 6600-6608.
- Niewiarowski, S., Kirby, E.P., Brudzynski, T.M. and Stocker, K. (1979) Thrombocytin, a serine protease from Bothrops atrox venom. 2. Interaction with platelets and plasma-clotting factors. Biochemistry 18: 3570-3577.
- Nikai, T., Ishizaki, H., Tu, A.T. and Sugihara, H. (1982) Presence of zinc in proteolytic hemorrhagic toxin isolated from Agkistrodon acutus venom. Comp. Biochem. Physiol. 72C: 103-106.
- Nonaka, I., Takagi, A., Ishiura, S., Nakase, H. and Sugita, H. (1983) Pathophysiology of muscle fiber necrosis induced by bupivacaine hydrochloride (Marcaine). Acta Neuropathol. 60: 167-174.
- Ohsaka, A. (1979) Hemorrhagic, necrotizing and edema-forming effects of snake venoms. In: Snake Venoms, pp 480-546 (Lee, C.Y., Ed.). Berlin: Springer-Verlag.

- Ohsaka, A., Just, M. and Habermann, E. (1973) Action of snake venom hemorrhagic principles on isolated glomerular basement membrane. Biochim. Biophys. Acta 323: 415-428.
- Ohsaka, A., Ohashi, M., Tsuchiya, M., Kamisaka, Y and Fujishiro, Y. (1971) Action of Trimeresurus flavoviridis venom on the microcirculatory system of rat: Dynamic aspects as revealed by cinephotomicrographic recording. Jpn. J. Med. Sci. Biol. 24: 34-39.
- Okonogi, T., Homma, M. and Hoshi, S. (1964) Pathological studies on Habu-snake bite. Gunma J. med. Sci. 13: 101-120.
- Omori-Sato, T. and Ohsaka, A. (1970) Purification and some properties of hemorrhagic principle I in the venom of Trimeresurus flavoviridis. Biochim. Biophys. Acta 207: 432-444.
- Omori-Sato, T. and Sadahiro, S. (1979) Resolution of the major hemorrhagic component of Trimeresurus flavoviridis venom into two parts. Biochim. Biophys. Acta 580: 392-404.
- Oshima, G., Sato-Omori, T. and Suzuki, T. (1969) Proteinase, arginineester hydrolase and a kinin releasing enzyme in snake venoms. Toxicon 7: 229-233.
- Oshima, G., Omori-Sato, T., Iwanaga, S. and Suzuki, T. (1972) Studies on snake venom hemorrhagic factor I (HR-I) in the venom of Agkistrodon halys blomhoffii. J. Biochem. 72: 1483-1494.
- Ovadia, M. (1978) Isolation and characterization of three hemorrhagic factors from the venom of Vipera palestinae. Toxicon 16: 479-487.
- Ownby, C.L. (1982) Pathology of rattlesnake envenomation. In: Rattlesnake Venoms, Their Actions and Treatment, pp 163-209 (Tu, A.T., Ed.). New York: Marcel Dekker.
- Ownby, C.L. and Odell, G.V. (1983) Pathogenesis of skeletal muscle necrosis induced by tarantula venom. Exp. Molec. Pathol. 38: 283-296.
- Ownby, C.L., Cameron, D. and Tu, A.T. (1976) Isolation of myotoxic component from rattlesnake (Crotalus viridis viridis) venom. Electron microscopic analysis of muscle damage. Am. J. Pathol. 85: 149-166.

- Ownby, C.L., Bjarnason, J. and Tu, A.T. (1978) Hemorrhagic toxins from rattlesnake (Crotalus atrox) venom. Pathogenesis of hemorrhage induced by three purified toxins. Am. J. Pathol. 93: 201-218.
- Ownby, C.L., Woods, W.M. and Odell, G.V. (1979) Antiserum to myotoxin from prairie rattlesnake (Crotalus viridis viridis) venom. Toxicon 17: 373-380.
- Ownby, C.L., Gutiérrez, J.M., Colberg, T.R. and Odell, G.V. (1982) Quantitation of myonecrosis induced by myotoxin a from prairie rattlesnake (Crotalus viridis viridis) venom. Toxicon 20: 877-885.
- Ownby, C.L., Colberg, T.R. and Odell, G.V. (1983a) A new method for quantitating hemorrhage induced by rattlesnake venoms: Ability of polyvalent antivenom to neutralize hemorrhagic activity. Toxicon (in press).
- Ownby, C.L., Odell, G.V., Woods, W.M. and Colberg, T.R. (1983b) Ability of antiserum to myotoxin a from prairie rattlesnake (Crotalus viridis viridis) venom to neutralize local myotoxicity and lethal effects of myotoxin a and homologous crude venom. Toxicon 21: 35-45.
- Peña-Chavarría, A., Villarejos, V.M. and Zomer, M. (1970) Clinical importance of prothrombin time determination in snake-venom poisoning. Am. J. Trop. Med. Hyg. 19: 342-344.
- Pestronk, A., Parhad, I.M., Drachman, D.B. and Price, D.L. (1982) Membrane myopathy: morphological similarities to Duchenne muscular dystrophy. Muscle & Nerve 5: 209-214.
- Picado, C. (1931) Serpientes venenosas de Costa Rica. Sus venenos. Seroterapia antiofidica. 222 pp. San José: Imprenta Alsina.
- Pluskal, M.G., Harris, J.B., Pennington, R.J. and Eaker, D. (1978) Some biochemical responses of rat skeletal muscle to a single subcutaneous injection of a toxin (notexin) isolated from the venom of the Australian tiger snake Notechis scutatus scutatus. Clin. Exp. Pharmacol. Physiol. 5: 131-141.
- Plyley, M.J. and Groom, A.C. (1975) Geometrical distribution of capillaries in mammalian striated muscle. Am. J. Physiol. 228: 1376-1383.

- Pool, W.R., Engle, C.M. and Bieber, A.L. (1981) Isolation and characterization of two myotoxins from the venom of the midget faded rattlesnake (Crotalus viridis concolor). Fed. Proc. 40: 1579.
- Publicover, S.J., Duncan, C.J. and Smith, J.L. (1977) Ultrastructural changes in muscle mitochondria "in situ", including the apparent development of internal septa, associated with the uptake and release of calcium. Cell Tissue Res. 185: 373-385.
- Publicover, S.J., Duncan, C.J. and Smith, J.L. (1978) The use of A23187 to demonstrate the role of intracellular calcium in causing ultrastructural damage in mammalian muscle. J. Neuropathol. Exp. Neurol. 37: 544-557.
- Reddy, M.K., Etlinger, J.D., Rabinowitz, M., Fischman, D.A. and Zak, R. (1975) Removal of Z-lines and  $\alpha$ -actinin from isolated myofibrils by a calcium-activated neutral protease. J. Biol. Chem. 250: 4278-4284.
- Reid, H.A. (1961) Myoglobinuria and sea snake bite poisoning. Br. Med. J. 1: 1284-1289.
- Reid, H.A. (1979) Symptomatology, pathology and treatment of the bites of sea snakes. In: Snake Venoms, pp 922-955 (Lee, C.Y., Ed.). Berlin: Springer-Verlag.
- Reisfeld, R.A., Lewis, U.J. and Williams, D.E. (1962) Disk electrophoresis of basic proteins and peptides on polyacrylamide gels. Nature 195: 281-283.
- Rinderknecht, H., Geokas, M.C., Silverman, P. and Hauerback, B.J. (1968) A new ultrasensitive method for the determination of proteolytic activity. Clin. Chim. Acta 21: 197-203.
- Rosenfeld, G. (1971) Symptomatology, pathology and treatment of snake bites in South America. In: Venomous Animals and Their Venoms, Vol II, Venomous Vertebrates, pp 345-384 (Bücherl, W. and Buckley, E., Eds.). New York: Academic Press.
- Rowland, L.P. (1980) Biochemistry of muscle membranes in Duchenne muscular dystrophy. Muscle & Nerve 3: 3-20.
- Russell, F.E., Pattabhiraman, T.R., Schaeffer, R.C., Tamiya, N. and Maeda, N. (1978) Some properties of the venom of Crotalus viridis helleri. Toxicon 16: 425.
- Savage, J.M. (1976) A preliminary handlist of the herpetofauna of Costa Rica. Second Edition, 19 pp. San José: Universidad de Costa Rica.

- Scarpa, A., Brinkley, F.J., Tiffert, T. and Dubyak, G.R. (1978) Metallochromic indicators of ionized calcium. Ann. N. Y. Acad. Sci. 307: 86-112.
- Schanne, F.A.X., Pfau, R.G. and Farber, J.L. (1980) Galactosamine-induced cell death in primary cultures of rat hepatocytes. Am. J. Pathol. 100: 25-38.
- Schanne, F.A.X., Kane, A.B., Young, E.E. and Farber, J.L. (1979) Calcium dependence of toxic cell death: a final common pathway. Science 206: 700-702.
- Schmalbruch, H. (1978) Satellite cells of rat muscles as studied by freeze-fracturing. Anat. Rec. 191: 371-376.
- Schotland, D.L., Bonilla, E. and Wakayama, Y. (1980) Application of the freeze fracture technique to the study of human neuromuscular disease. Muscle & Nerve 3: 21-27.
- Shier, W.T. (1982) Cytolytic mechanisms: Self-destruction of mammalian cells by activation of endogenous hydrolytic enzymes. Toxin Rev. 1: 1-32.
- Simionescu, N. and Simionescu, M. (1983) The cardiovascular system. In: Histology. Cell and Tissue Biology, pp 371-433 (Weiss, L., Ed.). New York: Elsevier Biomedical.
- Slotta, K.H. and Fraenkel-Conrat, H. (1939) Crotoxin. Nature 144: 290-291.
- Stadhouders, A.M. (1981) Cellular calcium homeostasis, mitochondria and muscle cell disease. In: Mitochondria and Muscle Diseases, pp 77-88 (Busch, H.F.M., Jennekens, F.G.I. and Scholte, H.R., Eds.). The Netherlands: Mefar.
- Stocker, K. and Barlow, G.H. (1976) The coagulant enzyme from Bothrops atrox venom (Batroxobin). In: Methods in Enzymology, Vol 45, pp 214-223 (Laszlo, L., Ed.). New York: Academic Press.
- Stringer, J.M., Kainer, R.A. and Tu, A.T. (1971) Ultrastructural studies of myonecrosis induced by cobra venom in mice. Toxicol. Appl. Pharmacol. 18: 442-450.
- Stringer, J.M., Kainer, R.A. and Tu, A.T. (1972) Myonecrosis induced by rattlesnake venom. An electron microscopic study. Am. J. Pathol. 67: 127-140.

- Strunk, S.W., Smith, C.W. and Blumberg, J.M. (1967) Ultrstructural studies on the lesion produced in skeletal muscle fibers by crude type A Clostridium perfringens toxin and its purified alpha fraction. Am. J. Pathol. 50: 89-107.
- Sugihara, H., Nikai, T., Kinoshita, G. and Tanaka, T. (1980) Enzymochemical studies on snake venoms. VII. Purification of hemorrhagic principle Ac<sub>4</sub>-proteinase in the venom of Agkistrodon acutus. Yakugaku Zasshi 100: 855-861.
- Takahashi, T. and Ohsaka, A. (1970) Purification and some properties of two hemorrhagic principles (HR2a and HR2b) in the venom of Trimeresurus flavoviridis; complete separation of the principles from proteolytic activity. Biochim. Biophys. Acta 207: 65-75.
- Trump, B.F., Berezesky, I. and Osornio-Vargas, A. (1981) Cell death and the disease process. The role of calcium. In: Cell Death in Biology and Pathology, pp 209-242 (Bowen, I.D. and Lockshin, R.A., Eds.). London: Chapman and Hall.
- Trump, B.F., Berezesky, I.K. and Cowley, R.A. (1982) The cellular and subcellular characteristics of acute and chronic injury with emphasis on the role of calcium. In: Pathophysiology of Shock, Anoxia and Ischemia, pp 6-46 (Cowley, R.A. and Trump, B.F., Eds.). Baltimore: Williams & Wilkins.
- Tu, A.T. (1977) Venoms: Chemistry and Molecular Biology. New York: John Wiley.
- Tu, A.T. and Homma, M. (1970) Toxicologic study of snake venoms from Costa Rica. Toxicol. Appl. Pharmacol. 16: 73-78.
- Umaña, V. (1982a) Purificación y separación de isoenzimas de L-aminoácido oxidasa del veneno de Bothrops asper. Rev. Biol. Trop. 30: 59-64.
- Umaña, V. (1982b) Estudio comparativo de las isoenzimas de L-aminoácido oxidasa del veneno de Bothrops asper. Rev. Biol. Trop. 30: 79-84.
- Vargas-Baldares, M. (1978) Renal lesions in snake bite in Costa Rica. In: Toxins: Animal, Plant and Microbial, pp 497 (Rosenberg, P., Ed.). Oxford: Pergamon Press.
- Vidal, J.C. and Stoppani, A.O.M. (1971) Isolation and purification of two phospholipases A from Bothrops venoms. Arch. Biochem. Biophys. 145: 543-556.

- Vracko, R. and Benditt, E.P. (1972) Basal lamina: the scaffold for orderly cell replacement. Observations on regeneration of injured skeletal muscle fibers and capillaries. J. Cell Biol. 55: 406-419.
- Wrogemann, K. and Pena, S.D.J. (1976) Mitochondrial calcium overload: a general mechanism for cell-necrosis in muscle diseases. The Lancet 1: 672-673.
- Xu, X., Wang, C., Lin, J. and Lu, Z. (1981) Purification and characterization of hemorrhagic components from Agkistrodon acutus (hundred pace snake) venom. Toxicon 19: 633-644.

VITA 2

José María Gutiérrez

Candidate for the Degree of  
Doctor of Philosophy

Thesis: ISOLATION, PARTIAL CHARACTERIZATION,  
AND PATHOLOGIC EFFECTS OF A MYOTOXIN  
FROM BOTHROPS ASPER VENOM

Major Field: Physiological Sciences

Biographical:

Personal Data: Born in San José, Costa Rica, November 17, 1954; the son of Jorge Gutiérrez Cooper and Margarita Gutiérrez Mangel. Married to Irma Arguedas Negrini on January 19, 1980.

Education: Graduated from Colegio de La Salle, San José, Costa Rica, in November, 1971; received Bachelor of Science Degree in Microbiology and Clinical Chemistry from Universidad de Costa Rica in August 1977; completed requirements for the Doctor of Philosophy degree at Oklahoma State University in May, 1984.

Professional Experience: Research Assistant, Instituto Clodomiro Picado, Universidad de Costa Rica, August, 1975, to August, 1977; Research Associate, Instituto Clodomiro Picado, Universidad de Costa Rica, August, 1977, to July, 1980; Professor, School of Microbiology, Universidad de Costa Rica, January, 1980, to July, 1980; Research Assistant, Department of Physiological Sciences, Oklahoma State University, August, 1982, to February, 1984.