

**1,3,5-TRINITROBENZENE-INDUCED ALPHA 2U-
GLOBULIN NEPHROPATHY**

By

SOOCHONG KIM

Doctor of Veterinary Medicine

Kyungpook National University

Taegu, Korea


1992

Submitted to the Faculty of the
Graduate College of the
Oklahoma State University
in partial fulfillment of
the requirements for
the Degree of
MASTER OF SCIENCE
May, 1996

**1,3,5-TRINITROBENZENE-INDUCED ALPHA 2U-
GLOBULIN NEPHROPATHY**


In a thesis to my advisor, Dr. Charles
W. Coffey, entitled "The
Effect of 1,3,5-Trinitrobenzene on the
Kidney of the Rat"

Thesis Approved:



Thesis Adviser





Thomas C. Collins

Dean of the Graduate College

ACKNOWLEDGMENTS

Page

I would like to express my sincere appreciation to my major advisor, Dr. Charles W. Qualls Jr. not only for his continuous guidance, concern, patience, and support, but also for giving me the opportunity to expand my study in Veterinary Pathology. I shall always be thankful for his help.

I would also like to thank my advisory committee members, Dr. Robert Jay Hoffman and Dr. Subbiah Sangiah for their helpful suggestions, encouragement, and guidance. I am grateful to Dr. Gunda Reddy at the U. S. Army Biomedical Research and Development Laboratory, Ft. Detrick, Maryland for his financial support for this study.

I wish to thank Dr. Jim Lish and Dr. Eric L. Stair for helping me to do the research. I appreciate all the help and friendship from other faculty members, staffs, and graduate students in my department, especially Dr. Nick Gatto and Dr. Karamjeet Pandher who encouraged me in difficult time.

Finally, I would like to express my deepest gratitude to my fiancée and my parents for their lifelong love, support, understanding, and encouragement throughout my life.

TABLE OF CONTENTS

Chapter	Page
I. INTRODUCTION AND LITERATURE REVIEW	1
Introduction	1
Comparison of Urinary Proteins	4
Factors Affecting Hyaline droplet Nephropathy	5
Abnormal Accumulation of Hyaline Droplets	5
Carcinogenesis Associated with Hyaline Droplet Nephropathy	6
Outline of Work	7
References	8
II. 1,3,5-TRINITROBENZENE-INDUCED ALPHA 2U-GLOBULIN NEPHROPATHY	15
Introduction	15
Materials and Methods	17
Results	19
Discussion	21
References	25

LIST OF TABLES

Table	Page
CHAPTER II	
1. Kidney Weights of Rats Exposed to TNB	30
2. Cell Proliferation in Renal Proximal Tubules of Male F-344 Rats Exposed to TNB	31

LIST OF FIGURES

Figure	Page
CHAPTER II	
1. Renal cortex from a male F-344 rat exposed to 35.5 mg/kg of TNB for 30 days.	32
2. Mallory Heidenhain staining of renal cortex from a male rat exposed to 35.5 mg/kg of TNB for 10 days.	33
3. Immunohistochemical staining of renal cortex from a control male F-344 rat. Several PCNA-positive	34
4. Immunohistochemical staining of renal cortex from a male F-344 rat exposed to 35.5 mg/kg of TNB for 30 days. Numerous PCNA-positive	35
5. Immunohistochemical staining of alpha 2u-G of kidney from a male NBR rat exposed to 71 mg/kg of TNB for 10-days.	36
6. Immunohistochemical staining of alpha 2u-G from a control male F-344 rat.	37
7. Immunohistochemical staining of alpha 2u-G from a male F-344 rat exposed to 35.5 mg/kg of TNB for 30 days.	38

CHAPTER I

INTRODUCTION AND LITERATURE REVIEW

1,3,5-trinitrobenzene (TNB), a process and environmental by-product of 2,4,6-trinitrotoluene (TNT), has been detected as a significant environmental pollutant of surface waters, ground waters, sediments and soils near munition manufacturing and loading facilities and waste sites (U. S. EPA, 1989). 1,3,5-TNB is known by the synonyms trinitrobenzene, *symmetrical* trinitrobenzene, sym trinitrobenzene (Budavari et al., 1989 ; Sax and Lewis, 1989 ; Weast, 1989). TNB is a dimorphic solid with a molecular weight of 213.11. It can be prepared by the decarboxylation of trinitrobenzoic acid or by the oxidation of TNT. TNB is a yellow crystalline solid at room temperature; it is soluble in both polar and nonpolar solvents and sparingly soluble in water (Sax and Lewis, 1987 ; Windholz et al., 1983). Recently, renal toxicity characterized by exacerbated formation and accumulation of hyaline droplet in proximal tubules in male rats due to administration of TNB has been observed (Qualls et al., 1995 ; Reddy et al., 1993, 1994). Dunnick et al.(1994) has demonstrated that nitrotoluene, a nitroaromatic compound, causes hyaline droplet nephropathy associated with the accumulation of alpha 2u-globulin (alpha 2u-G).

It has been reported that alpha 2u-G is a primary constituent of the hyaline droplets and the crucial factor which allows male rats to be susceptible to hyaline droplet

nephropathy following chemical exposure (Burnett et al., 1989 ; Karnerva et al., 1987c ; Olson et al., 1987). Although the precise physiological function of alpha 2u-G remains unclear, the possible role of this protein in pheromone transport has been suggested (Böcskei et al., 1992 ; Mancini et al., 1989). The complete amino acid sequence of alpha 2u-G has been determined by the nucleotide sequence of alpha 2u-G cDNA (Unterman et al., 1981). The structure of alpha 2u-G consists of an eight-stranded β -barrel and an α -helix, with loops between the β -strands (Böcskei et al., 1992). The interior of the β -barrel forms a binding pocket with a highly nonpolar lining believed to be ideal for the transportation of small hydrophobic molecules through hydrophilic media. The molecular weight of alpha 2u-G is variable between 16 and 20 kDa. Saito et al. (1991) have shown that the molecular weight of kidney-type alpha 2u-G is 16 kDa, whereas the molecular weight of native-type alpha 2u-G in the serum is approximately 19 kDa.

Alpha 2u-G is produced by the liver of male rats under androgenic stimulation but not female rats (Roy et al., 1976). In addition to the alpha 2u-G derived from the liver, alpha 2u-G also has been detected in the submaxillary, lacrimal, preputial, meibomian, and perianal glands in both sexes and the mammary gland during pregnancy (Laperche et al., 1983 ; MacInnes et al., 1986 ; Mancini et al., 1989). The mRNA sequences have been assumed different between hepatic and other glandular alpha 2u-G (Laperche et al., 1983). Hepatic synthesis of alpha 2u-G in the male rat is age dependent as manifested by the first detection of low levels of alpha 2u-G at about 35 days and maximum levels at about day 60. After 5 months of age there is a gradual decline of hepatic androgen receptivity with a gradual decrease in the hepatic synthesis of alpha 2u-G with increasing age (MacInnes et

al., 1986 ; Motwani et al., 1984 ; Murty et al., 1988 ; Roy et al., 1983). Prepubertal male rats do not synthesize alpha 2u-G and are resistant to hyaline droplet nephropathy (Kanerva et al., 1987c). Normally alpha 2u-G is filtered by glomeruli and at least 50% of this filtered protein is reabsorbed and catabolized in the proximal tubule segment of the nephron and the remainder is eliminated in the urine (Royce, 1968).

Alpha 2u-G or hyaline droplet nephropathy has been observed as the microscopic appearance of protein droplets in proximal tubules and is caused by the reversible and noncovalent binding of a variety of chemicals or their metabolites, such as 1,4-dichlorobenzene (Charbonneau et al., 1989), isophorone (NTP, 1986), PS-6 unleaded gasoline, 2,2,4-trimethylpentane (Olson et al., 1987 ; Short et al., 1986, 1987, 1989a, 1989b), 2,4,4-trimethyl-2-pentanol (Lock et al., 1987), lindane (Dietrich and Swenberg, 1990), 3,5,5-trimethylhexanoyloxybenzene sulfonate (Lehman-McKeeman et al., 1991), d-limonene (Kanerva et al., 1987b ; Lehman-McKeeman et al., 1989 ; Webb et al., 1989), decalin (Kanerva et al., 1987a, 1987c ; Stone et al., 1987a, 1987b), sodium barbital, diethylacetylurea (Kurata et al., 1994 ; Ward et al., 1993), tert-butyl alcohol (Takahashi et al., 1993), and several pharmacological agents (Read et al., 1988), to alpha 2u-G. The resulting alpha 2u-G - chemical complex is resistant to hydrolytic degradation in the phagolysosomes of the proximal convoluted tubule epithelial cells (Borghoff et al., 1990 ; Charbonneau et al., 1987 ; Lehman-McKeeman et al., 1990). This results in lysosomal overload characterized by massive accumulation of protein droplets in P2 segment of the proximal tubule and cytotoxicity followed by compensatory renal tubule cell proliferation (Short et al., 1987, 1989a ; Stone et al., 1987b ; Swenberg et al., 1989 ; Webb et al.,

1989). Sustained increase in cell proliferation is putatively associated with incidence of renal tubular neoplasms (Dietrich and Swenberg, 1991b ; Short, 1993 ; Short et al., 1987). This disease occurs in male rats, but not in female rats or either sex of mice, guinea pigs, hamsters, dogs, or monkeys (Alden, 1986 ; MacFarland, 1984 ; Phillips et al., 1987 ; Short et al., 1989a ; Stone et al., 1987b ; Swenberg et al., 1989 ; Webb et al., 1990). The only male rat strain known not to develop this renal disease is the NCI-Black-Reiter (NBR) rat (Dietrich and Swenberg, 1990, 1991a ; Kurata et al., 1994 ; Ridder et al., 1990) which does not synthesize the alpha 2u-G in the liver (Chatterjee et al., 1989).

Even though human serum and urine contain no alpha 2u-G, it has been known that there is a family of proteins isolated from serum and urine of other animals including humans which share extensive amino acid sequence homology with alpha 2u-G (Pevsner et al., 1988 ; Snyder et al., 1988). Alpha 2u-G has been included as a member of an extensive group of proteins known as lipocalins including retinol-binding protein, β -lactoglobulin, mouse major urinary protein, α 1-microglobulin, and α 1-acid glycoprotein, which has the ability to bind lipophilic ligands (Pervaiz and Brew, 1987). It is unlikely that there is a potential risk of hyaline droplet nephropathy and renal cancer to humans from exposure to hyaline droplet inducing agents (Borghoff and Lagarde, 1993 ; Hard and Whysner, 1994). *In vitro* binding experiments have identified that hyaline droplet inducers bind specifically to alpha 2u-G and do not bind other proteins with the structural homology, such as mouse urinary protein or human α 1-acid glycoprotein (Lehman-McKeeman and Caudill, 1992a, 1992b). Olson et al.(1990) have observed several factors that they have suggested as evidence for resistance to hyaline droplet nephropathy and resulting renal tumors in

humans. Among these are the very low protein content of human urine that is only 1 percent of the total concentration present in mature male rat urine, small cationic fraction of human urinary protein, and abundant high molecular weight protein in human urine.

There are several factors which have been suggested as the determinants of susceptibility of male rats to hyaline droplet nephropathy. It has been shown that male rats have relatively low renal lysosomal proteinase activity compared to female rats (Asan et al., 1986 ; Kugler and Vornberger, 1986). This is thought to result in the large amounts of urinary alpha 2u-G in male rats and to be indicative of intrinsic susceptibility of male rat kidneys to hyaline droplet nephropathy (Olson et al., 1990). Alpha 2u-G and alpha 2u-G - chemical complexes are resistant to proteolytic degradation in the kidney (Charbonneau et al., 1988). Viau et al.(1986) have demonstrated that alpha 2u-G inducing agents do not affect the rate of hepatic synthesis of alpha 2u-G and the protein resorptive capacity of renal proximal tubule cells, suggesting the role of decreased hydrolysis as a major factor affecting renal accumulation of protein droplets. It has been shown that the half-life of alpha 2u-G is 5-7hr and alpha 2u-G - chemical complexes extend the half-life by one-third, from 6.67 to 10hr (Geertzen et al., 1973 ; Lehman-McKeeman et al., 1990), compared to the half-lives of other low-molecular-weight proteins which are several minutes (Maack et al., 1985). Therefore, this increased resistance to lysosomal degradation could result in exacerbation of hyaline droplet accumulation leading to single cell necrosis in proximal tubules, cell sloughing, granular casts associated with tubule dilation at the junction of the inner and outer stripes of the outer medulla, linear mineralization in papillary tubules,

sustained proliferative response in proximal tubules, and finally renal tubule tumors (Alden et al., 1984 ; Borghoff et al., 1990 ; Swenberg et al., 1989 ; Trump et al., 1984).

Abnormal accumulation of hyaline droplets not associated with alpha 2u-G in renal tubules has been seen in several disease processes. Hyaline droplet accumulation has been observed in human epidemic hemorrhagic fever associated with the administration of large amounts of human serum albumin as a therapeutic measure (Oliver and MacDowell, 1958). Excess amounts of lysozyme are detected in the nephropathy of monocytic and myelomonocytic leukemia in humans (Muggia et al., 1969 ; Pruzanski and Platts, 1970). The hyaline droplets associated with histiocytic sarcoma in male and female rats and with multiple myeloma in humans have been identified as lysozyme and light-chain immunoglobulins, respectively (Hard and Snowden, 1991 ; Pirani et al., 1983). The kidney injury secondary to these neoplastic diseases is compatible with the nephropathy induced by decalin to male rats (Alden, 1986), including hyaline droplet accumulation in renal proximal tubules (Oliver and MacDowell, 1958 ; Pruzanski and Platts, 1970 ; Pirani et al., 1983). These neoplastic diseases have increased urinary excretion of low molecular weight proteins primarily caused by overproduction of specific proteins. Lysozyme and light-chain immunoglobulins are proteins that are also difficult to hydrolyze (Maack et al., 1985). The combination of difficulty of hydrolysis of protein coupled with an increased rate of protein delivery to tubular cells has been suggested as etiologic factors in the accumulation of hyaline droplets secondary to these neoplastic diseases (Hard et al., 1993). In almost every instance of proteinuria which is indicative of glomerular damage, protein droplets in the proximal tubule can be seen (Maack et al., 1985).

The toxicological significance of alpha 2u-G nephropathy-associated renal tubule tumors has been emphasized and it is believed that chronic exposure of hyaline droplet inducing agents results in sustained cell replication, leading to the development of renal tubule neoplasms. It has been suggested that a longer period of exposure (at least 6 months) and high concentration of chemicals, such as unleaded gasoline or d-limonene, are necessary for renal carcinogenesis (Short, 1993). But, it has been reported that 1-(aminomethyl) cyclohexaneacetic acid, an alpha 2u-G inducing agent, does not induce renal cancer in male rats treated for 2 years. This may be related to the insufficient renal tubular injury to effectively promote tumor formation (Dominick et al., 1991). Therefore, the magnitude of renal cell injury and duration of cell proliferation may contribute to the effective promotion of renal tumors in alpha 2u-G nephropathy.

No studies have been done to identify the nature of the protein droplets or to elucidate the role of alpha 2u-G in the pathogenesis of the hyaline droplet nephropathy induced by TNB. It is not known whether renal tubular neoplasms would develop in male rats with chronic exposure to TNB. The purpose of this study is to investigate whether TNB induces hyaline droplet nephropathy associated with alpha 2u-G, and to identify the nature of the accumulating protein by immunohistochemistry. The possible role of alpha 2u-G in this disease will be corroborated by comparing the renal lesions between male rats and female and NBR male rats. This experiment will determine whether TNB exacerbates renal hyaline droplet formation in male rats by binding to alpha 2u-G.

REFERENCES

- Alden, C.L. (1986) A review of unique male rat hydrocarbon nephropathy. *Toxicol. Pathol.* 14, 109-111.
- Alden, C.L., Kanerva, R.L., Ridder, G., and Stone, L.C. (1984) The pathogenesis of the nephrotoxicity of volatile hydrocarbons in the male rat. In *Renal Effects of Petroleum Hydrocarbons* (Mehlman, M.A., Hemstreet III, C.P., Thorpe, J.J., and Weaver, N.K. Eds.), Vol. VII, pp. 107-120. Princeton Scientific Publishers, Princetown, NJ.
- Asan, E., Kugler, P., and Schiebler, T.H. (1986) Sex-related differences in the handling of fluorescent ovalbumin by the proximal tubule of the rat kidney. *Histochemistry* 84, 408-417.
- Böcskei, Z., Groom, C.R., Flower, D.R., Wright, C.E., Phillips, S.E.V., Cavaggioni, A., Findlay, J.B.C., and North, A.C.T. (1992) Pheromone binding to two rodent urinary proteins revealed by X-ray crystallography. *Nature* 360, 186-188.
- Borghoff, S.J., and Lagarde, W.H. (1993) Assessment of binding of 2,4,4-trimethyl-2-pentanol to low-molecular-weight proteins isolated from kidneys of male rats and humans. *Toxicol. Appl. Pharmacol.* 119, 228-235.
- Borghoff, S.J., Short, B.G., and Swenberg, J.A. (1990) Biochemical mechanisms and pathobiology of α 2u-globulin nephropathy. *Annu. Rev. Pharmacol. Toxicol.* 30, 349-367.
- Budavari, S., O'Neil, M.J., and Smith, A. (1989) In: *The Merck Index*. Merck & Co., Inc., Rahway, NJ, p. 1530.
- Burnett, V.L., Short, B.G., and Swenberg, J.A. (1989) Localization of α 2u-globulin within protein droplets of male rat kidney: Immunohistochemistry using perfusion-fixed, GMA-embedded tissue sections. *J. Histochem. Cytochem.* 37, 813-818.
- Charbonneau, M., Strasser, J., Jr., Lock, E.A., Turner, M.J., and Swenberg, J.A. (1989) Involvement of reversible binding to α 2u-globulin in 1,4-dichlorobenzene-induced nephrotoxicity. *Toxicol. Appl. Pharmacol.* 99, 122-132.
- Chatterjee, B., Demyan, W.F., Song, C.S., Gara, B.D., and Roy, A.K. (1989) Loss of androgenic induction of α 2u-globulin gene family in the liver of NIH black rats. *Endocrinology* 125, 1385-1388.
- Dietrich, D.R., and Swenberg, J.A. (1991a) NCI-Black-Reiter (NBR) male rats fail to develop renal disease following exposure to agents that induce α -2u-globulin (α 2u) nephropathy. *Fundam. Appl. Toxicol.* 16, 749-762.

- Dietrich, D.R., and Swenberg, J.A. (1991b) The presence of α_2 -globulin is necessary for d-limonene promotion of male rat kidney tumors. *Cancer Res.* 51, 3512-3521.
- Dietrich, D.R., and Swenberg, J.A. (1990) Lindane induces nephropathy and renal accumulation of α_2 -globulin in male but not in female Fischer 344 rats or male NBR rats. *Toxicol. Lett.* 53, 179-181.
- Dominick, M.A., Robertson, D.G., Bleavins, M.R., Sigler, R.E., Bobrowski, W.F., and Gough, A.W. (1991) α_2 -Globulin nephropathy without nephrocarcinogenesis in male Wistar rats administered 1-(aminomethyl)cyclohexaneacetic acid. *Toxicol. Appl. Pharmacol.* 111, 375-387.
- Dunnick, J.K., Elwell, M.R., and Bucher, J.R. (1994) Comparative toxicities of o-, m-, and p-nitrotoluene in 13-week feed studies in F344 rats and B6C3F1 mice. *Fundam. Appl. Toxicol.* 22, 411-421.
- Hard, G.C., Rodgers, I.S., Baetcke, K.P., Richards, W.L., McGaughy, R.E., and Valcovic, L.R. (1993) Hazard evaluation of chemicals that cause accumulation of α_2 -globulin, hyaline droplet nephropathy, and tubule neoplasia in the kidneys of male rats. *Environ. Health Perspect.* 99, 313-349.
- Hard, G.C., and Snowden, R.T. (1991) Hyaline droplet accumulation in rodent kidney proximal tubules: An association with histiocytic sarcoma. *Toxicol. Pathol.* 19, 88-97.
- Hard, G.C., and Whysner, J. (1994) Risk assessment of d-limonene: An example of male rat-specific renal tumorigens. *Crit. Rev. Toxicol.* 24, 231-254.
- Kanerva, R.L., McCracken, M.S., Alden, C.L., and Stone, L.C. (1987a) Morphogenesis of decalin-induced renal alterations in the male rat. *Food Chem. Toxicol.* 25, 53-61.
- Kanerva, R.L., Ridder, G.M., Lefever, F.R., and Alden, C.L. (1987b) Comparison of short-term renal effects due to oral administration of decalin or d-limonene in young adult male Fischer-344 rats. *Food Chem. Toxicol.* 25, 345-353.
- Kanerva, R.L., Ridder, G.M., Stone, L.C., and Alden, C.L. (1987c) Characterization of spontaneous and decalin-induced hyaline droplets in kidneys of adult male rats. *Food Chem. Toxicol.* 25, 63-82.
- Kugler, P., and Vornberger, G. (1986) Renal cathepsin-B activities in rats after castration and treatment with sex hormones. *Histochemistry* 85, 157-161.
- Kurata, Y., Diwan, B.A., McKeeman, L.L., Rice, J.M., and Ward, J.M. (1994) Comparative hyaline droplet nephropathy in male F344/NCr rats induced by sodium barbital and diethylacetylurea, a breakdown product of sodium barbital. *Toxicol. Appl. Pharmacol.* 126, 224-232.

- Laperche, Y., Lynch, K.R., Dolan, K.P., and Feigelson, P. (1983) Tissue-specific control of α 2u globulin gene expression: Constitutive synthesis in the submaxillary gland. *Cell* 32, 453-460.
- Lehman-McKeeman, L.D., and Caudill, D. (1992a) Biochemical basis for mouse resistance to hyaline droplet nephropathy: Lack of relevance of the α 2u-globulin protein superfamily in this male rat-specific syndrome. *Toxicol. Appl. Pharmacol.* 112, 214-221.
- Lehman-McKeeman, L.D., and Caudill, D. (1992b) α 2u-Globulin is the only member of the lipocalin protein superfamily that binds to hyaline droplet inducing agents. *Toxicol. Appl. Pharmacol.* 116, 170-176.
- Lehman-McKeeman, L.D., Rivera-Torres, M.I., and Caudill, D. (1990) Lysosomal degradation of α 2u-globulin and α 2u-globulin-xenobiotic conjugates. *Toxicol. Appl. Pharmacol.* 103, 539-548.
- Lehman-McKeeman, L.D., Rodriguez, P.A., Caudill, D., Fey, M.L., Eddy, C.L., and Asquith, T.N. (1991) Hyaline droplet nephropathy resulting from exposure to 3,5,5-trimethylhexanoyloxybenzene sulfonate. *Toxicol. Appl. Pharmacol.* 107, 429-438.
- Lehman-McKeeman, L.D., Rodriguez, P.A., Takigiku, R., Caudill, D., and Fey, M.L. (1989) d-Limonene-induced male rat-specific nephrotoxicity: Evaluation of the association between d-limonene and α 2u-globulin. *Toxicol. Appl. Pharmacol.* 99, 250-259.
- Lock, E.A., Charbonneau, M., Strasser, J., Swenberg, J.A., and Bus, J.A. (1987) 2,2,4-Trimethylpentane-induced nephrotoxicity. II. The reversible binding of a TMP metabolite to a renal protein fraction containing α 2u-globulin. *Toxicol. Appl. Pharmacol.* 91, 182-192.
- Maack, T., Park, C.H., and Camargo, M.J.F. (1985) Renal filtration, transport, and metabolism of proteins. In *The Kidney: Physiology and Pathophysiology* (D.W. Seldin and G. Giesbisch, Eds.), pp. 1773-1803. Raven Press, New York.
- MacFarland, H.N. (1984) Xenobiotic induced kidney lesions: hydrocarbons. The 90-day and 2-year gasoline studies. In: Mehlman, M.A., Hemstreet, G.P., Thorpe, J.J., and Weaver, N.K. (eds.), *Advances in Modern Environmental Toxicology*. Vol. VII. Renal Effects of Petroleum Hydrocarbons. Princeton Scientific Publishers, Inc., Princeton, New Jersey, pp. 51-56.
- MacInnes, J.I., Nozik, E.S., and Kurtz, D.T. (1986) Tissue-specific expression of the rat alpha2u globulin gene family. *Molec. Cell. Biol.* 6, 3563-3567.

- Mancini, M.A., Miajumdar, D., Chatterjee, B., and Roy, A.K. (1989) α 2u-Globulin in modified sebaceous glands with pheromonal functions: Localization of the protein and its mRNA in preputial, meibomian, and perianal glands. *J. Histochem. Cytochem.* 37, 149-157.
- Motwani, N.M., Caron, D., Demyan, W.F., Chatterjee, B., Hunter, S., Poulik, M.D., and Roy, A.K. (1984) Monoclonal antibodies to α 2u-globulin and immunocytofluorometric analysis of α 2u-globulin-synthesizing hepatocytes during androgenic induction and aging. *J. Biol. Chem.* 259, 3653-3657.
- Muggia, F.M., Heinemann, H.O., Farhangi, M., and Osserman, E.F. (1969) Lysozymuria and renal tubular dysfunction in monocytic and myelomonocytic leukemia. *Am. J. Med.* 47, 351-366.
- Murty, C.V.R., Olson, M.J., Garg, B.D., and Roy, A.K. (1988) Hydrocarbon-induced hyaline droplet nephropathy in male rats during senescence. *Toxicol. Appl. Pharmacol.* 96, 380-392.
- National Toxicology Program (1986) Carcinogenesis studies of isophorone in F344/N rats and B6C3F1 mice. National Toxicology Program Technical Report Series No. 291. National Toxicology Program, Research Triangle Park, NC.
- Oliver, J., and MacDowell, M. (1958) Cellular mechanisms of protein metabolism in the nephron. VII. The characteristics and significance of the protein absorption droplets (hyaline droplets) in epidemic hemorrhagic fever and other renal diseases. *J. Exp. Med.* 107, 731-754.
- Olson, M.J., Garg, B.D., Ramana Murty, C.V., and Roy, A.K. (1987) Accumulation of α 2u-globulin in the renal proximal tubules of male rats exposed to unleaded gasoline. *Toxicol. Appl. Pharmacol.* 90, 43-51.
- Olson, M.J., Johnson, J.T., and Reidy, C.A. (1990) A comparison of male rat and human urinary proteins: Implications for human resistance to hyaline droplet nephropathy. *Toxicol. Appl. Pharmacol.* 102, 524-536.
- Pervaiz, S., and Brew, K. (1987) Homology and structure-function correlations between α 1-acid glycoprotein and serum retinol-binding protein and its relatives. *FASEB J.* 1, 209-214.
- Pevsner, J., Reed, R.R., Feinstein, P.G., and Snyder, S.H. (1988) Molecular cloning of odorant-binding protein: Member of a ligand carrier family. *Science* 241, 336-339.
- Phillips, R.D., Moran, E.J., Dodd, D.E., Fowler, E.H., Kary, C.D., and O'Donoghue, J. (1987) A 14-week vapor inhalation toxicity study of methyl isobutyl ketone. *Fundam. Appl. Toxicol.* 9, 380-388.

- Pirani, C.L., Silva, F.G., Appel, G.B. (1983) Tubulo-interstitial disease in multiple myeloma and other nonrenal neoplasias. In: Cotran, R.S., Brenner, B.M., and Stein, J.H. (eds.), Tubulo-Interstitial Nephropathies. Churchill Livingstone, New York. pp. 287-334.
- Pruzanski, W., and Platts, M.E. (1970) Serum and urinary proteins, lysozyme (muramidase), and renal dysfunction in mono- and myelomonocytic leukemia. *J. Clin. Invest.* 49, 1694-1708.
- Qualls, C.W.Jr., Reddy, G., and Chandra, A.M.S. (1995) Hematological and pathological effects of 1,3,5-trinitrobenzene (TNB) in F344 rats. *International Congress of Toxicology-VII*.
- Read, N.G., Astbury, P.J., Morgan, R.J., Parsons, D.N., and Port, C.J. (1988) Induction and exacerbation of hyaline droplet formation in the proximal tubular cells of the kidneys from male rats receiving a variety of pharmacological agents. *Toxicology* 52, 81-101.
- Reddy, T.V., Daniel, F.B., Robinson, M., Olson, G.R., Wiechman, B., and Reddy, G. (1993) Fourteen day toxicity evaluation of 1,3,5-trinitrobenzene (TNB). *Toxicologist* 13, 177.
- Reddy, T.V., Torsella, J., Daniel, F.B., Olson, G.R., Wiechman, B., and Reddy, G. (1994) Subchronic toxicity evaluation of 1,3,5-trinitrobenzene (TNB) in Fischer 344 rats. *Toxicologist* 14, 117.
- Ridder, G.M., Von Bargaen, E.C., Alden, C.L., and Parker, R.D. (1990) Increased hyaline droplet formation in male rats exposed to decalin is dependent on the presence of α 2u-globulin. *Fundam. Appl. Toxicol.* 15, 732-743.
- Roy, A.K., Schiop, M.J., and Dowbenko, D.J. (1976) Regulation of the hepatic synthesis of α 2u globulin and its corresponding messenger RNA in maturing male rats. *FEBS Lett.* 70, 137-140.
- Roy, A.K., Surend Nath, T., Motwani, N.M., and Chatterjee, B. (1983) Age-dependent regulation of the polymorphic forms of α 2u-globulin. *J. Biol. Chem.* 258, 10123-10127.
- Royce, P.C. (1968) Characterization of a renal-dependent rat serum protein. *Am. J. Physiol.* 215, 1429-1434.
- Saito, K., Uwagawa, S., Kaneko, H., and Yoshitake, A. (1991) Behavior of α 2u-globulin accumulating in kidneys of male rats treated with d-limonene: Kidney-type α 2u-globulin in the urine as a marker of d-limonene nephropathy. *Toxicology* 70, 173-183.
- Sax, N.I., and Lewis, R.J. (Eds) (1987) In: *Hawley's Condensed Chemical Dictionary*, Eleventh Ed., Van Nostrand Reinhold, New York, NY, p. 1190.

Sax, N.I., and Lewis, R.J. (Eds) (1989) In: *Dangerous Properties of Industrial Materials*, Seventh Ed., Volume III, Van Nostrand Reinhold, New York, NY, p. 3403.

Short, B.G. (1993) Cell proliferation and renal carcinogenesis. *Environ. Health Perspect.* 101(Suppl 5), 115-120.

Short, B.G., Burnett, V.L., and Swenberg, J.A. (1986) Histopathology and cell proliferation induced by 2,2,4-trimethylpentane in the male rat kidney. *Toxicol. Pathol.* 14, 194-203.

Short, B.G., Burnett, V.L., Cox, M.G., Bus, J.S., and Swenberg, J.A. (1987) Site-specific renal cytotoxicity and cell proliferation in male rats exposed to petroleum hydrocarbons. *Lab. Invest.* 57, 564-577.

Short, B.G., Burnett, V.L., and Swenberg, J.A. (1989a) Elevated proliferation of proximal tubule cells and localization of accumulated α_2 -globulin in F344 rats during chronic exposure to unleaded gasoline or 2,2,4-trimethylpentane. *Toxicol. Appl. Pharmacol.* 101, 414-431.

Short, B.G., Steinhagen, W.H., and Swenberg, J.A. (1989b) Promoting effects of unleaded gasoline and 2,2,4-trimethylpentane on the development of atypical cell foci and renal tubular cell tumors in rats exposed to N-ethyl-N-hydroxyethylnitrosamine. *Cancer Res.* 49, 6369-6378.

Snyder, S.H., Sklar, P.B., and Pevsner, J. (1988) Molecular mechanisms of olfaction. *J. Biol. Chem.* 263, 13971-13974.

Stone, L.C., Kanerva, R.L., Burns, J.L., and Alden, C.L. (1987a) Decalin-induced nephrotoxicity: Light and electron microscopic examination of the effects of oral dosing on the development of kidney lesions in the rat. *Food Chem. Toxicol.* 25, 43-52.

Stone, L.C., McCracken, M.S., Kanerva, R.N., and Alden, C.L. (1987b) Development of a short-term model of decalin inhalation nephrotoxicity in the male rat. *Food Chem. Toxicol.* 25, 35-41.

Swenberg, J.A., Short, B., Borghoff, S., Strasser, J., and Charbonneau, M. (1989) The comparative pathobiology of α_2 -globulin nephropathy. *Toxicol. Appl. Pharmacol.* 97, 35-46.

Takahashi, K., Lindamood, C., III, and Maronpot, R.R. (1993) Retrospective study of possible α_2 -globulin nephropathy and associated cell proliferation in male Fischer 344 rats dosed with t-butyl alcohol. *Environ. Health Perspect.* 101, 281-286.

Trump, B.F., Lipsky, M.M., Jones, T.W., Heatfield, B.M., Higginson, J., Endicott, K., and Hess, H.B. (1984) An evaluation of the significance of experimental hydrocarbon

toxicity to man. In *Renal Effects of Petroleum Hydrocarbons* (Mehlman, M.A., Hemstreet III, C.P., Thorpe, J.J., and Weaver, N.K. Eds.), Vol. VII, pp. 273-288. Princeton Scientific Publishers, Princetown, NJ.

Unterman, R.D., Lynch, K.R., Nakhasi, H.L., Dolan, K.P., Hamilton, J.W., Cohn, D.V., and Feigelson, P. (1981) Cloning and sequence of several α_2 -globulin cDNAs. *Proc. Natl. Acad. Sci. USA* 78, 3478-3482.

U.S. EPA (1989) Health and Environmental Effects Profile for 1,3,5-trinitrobenzene. Environmental Criteria and Assessment Office, Office of Health and Environmental Assessment, Cincinnati, OH, ECAO-CIN-G071

Ward, J.M., Kurata, Y., Lehman-McKeeman, L.D., Diwan, B.A., and Rice, J.M. (1993) Comparative renal tubular hyaline droplet induction by sodium barbital and its decomposition product, diethylacetylurea. *Toxicologist* 13, 132.

Weast, R.C. (Ed) (1989) In: *CRC (Chemical Rubber Company) Handbook for Chemistry and Physics*, 69th ed., Astle, M.J., and Beyer, W.H., Assoc. Ed., CRC Press, Inc., Boca Raton, FL., p. C-119.

Webb, D.R., Kanerva, R.L., Hysell, D.K., Alden, C.L., and Lehman-McKeeman, L.D. (1990) Assessment of the subchronic oral toxicity of d-limonene in dogs. *Food Chem. Toxicol.* 28, 669-675.

Webb, D.R., Ridder, G.M., and Alden, C.L. (1989) Acute and subchronic nephrotoxicity of d-limonene in Fischer 344 rats. *Food Chem. Toxicol.* 27, 639-649.

Windholz, M.S., Budavari, R.F., Blumetti, R.F., and Otterbein, E.S. (1983) In: *The Merck Index*. Merck and Co., Inc., Rahway, NJ, p. 1389.

CHAPTER II

1,3,5-TRINITROBENZENE-INDUCED ALPHA 2U-GLOBULIN

NEPHROPATHY

INTRODUCTION

The nitroaromatic compound 1,3,5-trinitrobenzene (TNB), a process and environmental by-product of 2,4,6-trinitrotoluene (TNT), has been detected as an environmental pollutant of surface water, ground water, and soil near munition plants and production waste disposal sites (U.S. EPA, 1989). Recently, it has been reported that TNB exposure can induce renal toxicity characterized by hyaline droplet accumulation in proximal tubules in male rats (Qualls et al., 1995 ; Reddy et al., 1993, 1994).

Alpha 2u-globulin (alpha 2u-G) is a primary constituent of hyaline droplets in male rats and the essential factor which renders male rats to be susceptible to chemically induced hyaline droplet nephropathy (Burnett et al., 1989 ; Kanerva et al., 1987c ; Olson et al., 1987). Hyaline droplet nephropathy has been manifested as protein droplets in proximal tubules and is caused by the reversible and noncovalent binding of a variety of chemicals or their metabolites to alpha 2u-G (Charbonneau et al., 1989 ; Dietrich and Swenberg, 1990 ; Kanerva et al., 1987a, 1987b, 1987c ; Kurata et al., 1994 ; Lehman-

McKeeman et al., 1989, 1991 ; Lock et al., 1987 ; NTP, 1986 ; Short et al., 1986, 1987, 1989a, 1989b ; Stone et al., 1987a, 1987b). The formation of alpha 2u-G-chemical complex results in decreased hydrolysis in lysosomes of the proximal convoluted tubules, subsequent lysosomal overload and degeneration and necrosis of the proximal tubule epithelial cells followed by compensatory renal tubule cell proliferation (Short et al., 1987, 1989a ; Stone et al., 1987b ; Swenberg et al., 1989 ; Webb et al., 1989). It is believed that sustained increase in cell proliferation leads to the development of renal tubule neoplasms (Dietrich and Swenberg, 1991b ; Short, 1993 ; Short et al., 1987). This renal disease occurs in male rats, but not in female rats or either sex of mice, guinea pigs, hamsters, dogs, or monkeys (Alden, 1986 ; MacFarland, 1984 ; Phillips et al., 1987 ; Short et al., 1989a ; Stone et al., 1987b ; Swenberg et al., 1989 ; Webb et al., 1990). The only male rat strain known not to develop this renal disease is the NCI-Black-Reiter (NBR) rat (Dietrich and Swenberg, 1990, 1991a ; Kurata et al., 1994 ; Ridder et al., 1990). Chatterjee et al. (1989) reported that the male NBR rat does not synthesize alpha 2u-G in the liver.

Since the renal toxicity of TNB is confined to a few reported abstracts, the purpose of the current study was 1) to determine the role of alpha 2u-G in the pathogenesis of the hyaline droplet nephropathy caused by TNB by comparing the renal lesions between male F-344 rats and female F-344 and male NBR rats 2) to identify the nature of the protein droplets by immunohistochemistry and 3) to evaluate the renal cell replication by immunohistochemistry using proliferating cell nuclear antigen (PCNA), an endogenous cell replication marker.

MATERIALS AND METHODS

Chemicals

1,3,5-trinitrobenzene (99.83% purity) was obtained from Naval Surface Center (Silver Springs, MD) and the purity of the compound was confirmed by high performance liquid chromatography (HPLC). TNB was mixed with corn oil in a Potter-Elvehjem grinder daily prior to dosing. The oral LD₅₀ value for TNB in rats has been determined to be 284 mg/kg for combined sexes (Fitzgerald et al., 1992). The one eighth (35.5 mg/kg) and one fourth (71 mg/kg) LD₅₀ doses were selected for these studies.

Animal treatment

Twenty-six male and twelve female Fischer 344 rats and twelve male NCI-Black-Reiter rats aged between 9 and 11 weeks were used in the experiment. The animals were housed singly and provided feed (Purina Rat Chow) and tap water *ad libitum*. After a 2-week acclimatization (12 h light/12 h dark cycle, 72°±2°F, 50±10% relative humidity), male NBR and female F-344 rats were exposed to TNB for 10 days. Male F-344 rats were randomly assigned by body weight to three exposure periods of 10, 20 and 30 days. Within 10 day-exposure periods, four rats were separated into three TNB dose groups of 0, 35.5 and 71 mg/kg. Within 20 and 30 day exposure periods, three rats served as controls and four rats were administered TNB at 35.5 mg/kg. The rats were gavaged with TNB in corn oil by feeding needle. Controls received the same volume of corn oil. All treatments were conducted once a day between 9:00 a.m. and 10:00 a.m. for 10, 20 and

30 days and body weights were recorded daily. All rats were fasted for 15 hours prior to termination.

Histological procedures

At the end of each experimental period, all rats were anesthetized with Metofane® (Pitman-Moore, Mandelein, IL) and a complete necropsy was performed. For renal morphology, all rats were perfused through the abdominal aorta with sodium phosphate buffer (pH 7.4) containing 2% paraformaldehyde and 1% glutaraldehyde. The right kidney of each animal was removed, flash frozen and stored at -80°C for analysis by electrophoresis. The left kidney was fixed in 10% neutral buffered formalin and embedded in paraffin. The following tissues were evaluated from all animals for gross and histologic lesions: liver, kidney, testicle, epididymis, spleen, heart, brain, pancreas, duodenum, jejunum, ileum, cecum, and colon. The liver, kidney, spleen, testicle, and brain were weighed at necropsy. Sections of all parenchymal organs were collected in 10% neutral buffered formalin, embedded in paraffin, sectioned at 5-6 μm , and stained with hematoxylin and eosin. Sections of kidney were stained with Mallory-Heidenhain stains (Cason, 1950) for hyaline droplets. Immunohistochemical staining with anti-alpha 2u-G antiserum (courtesy of Dr. Borghoff, CIIT) was performed on kidney sections as described by Burnett et al. (1989) and Kurata et al. (1994). Immunohistochemical staining for proliferating cell nuclear antigen (PCNA) was done on kidney sections. The staining procedure was modified from several sources (Foley et al., 1991 ; Greenwell et al., 1991, 1993 ; Shi et al., 1991). The percentage of S phase cells was determined by examining

35,000 to 45,000 cells in P₂ segments of proximal tubules per slide, two slides per animal, using light microscopy.

Statistical differences were determined by using PC-SAS (SAS Institute Inc. Cary, NC). All data were tested for homogeneity of variances prior to analysis of variances (Proc. GLM, SAS). When significant F-values were obtained, the method of Least Square Means (LSM) was used to determine significant differences between treatment means. P-values of ≤ 0.05 were considered to be significant, unless otherwise mentioned.

RESULTS

The kidney/body weight ratios showed a dose-related increases in all treated rats with TNB for 10 days (Table 1). The kidney weights were significantly ($P < 0.01$) increased in all treated male F-344 rats compared to controls. NBR rats receiving 71 mg/kg of TNB and all treated female F-344 rats showed significant ($P < 0.05$) increases in kidney weights while increased kidney weights were not statistically different between controls and treated (35.5 mg/kg) NBR rats. There were no statistically different changes in kidney weights between male F-344 rats receiving 0 or 35.5 mg/kg for 20 days. (There was one control rat which had extremely high kidney weights compared to other control rats and if this rat was regarded as a outlier there would be significant changes in rats dosed for 20 days.) The relative kidney weights of male F-344 rats receiving dose of 35.5 mg/kg for 30 days were significantly ($P < 0.05$) higher than controls.

Dose-related accumulation of hyaline droplets was observed in the H&E (Fig. 1) and Mallory-Heidenhain stains (Fig. 2) of male F-344 rats treated with TNB in comparison to female F-344 and male NBR rats. These changes were detected only in the renal proximal convoluted tubule epithelial cells. By immunohistochemistry, marked increases in alpha 2u-G staining area and intensity were detected in hyaline droplet accumulated regions of the kidney sections of treated male F-344 rats (Fig. 6). Alpha 2u-G was not detected in the renal sections from all of the male NBR and female F-344 rats (Fig. 7), regardless of treatment of TNB. Pathological changes were characterized by massive accumulation of protein droplets which increased in size and number, dilated tubules with tubular protein, exfoliation of epithelial cells and various stages of tubular necrosis. The protein droplets were pleomorphic, large, and globular to polyangular in shape. Control male F-344 rats showed a small numbers of hyalin droplets which were usually small and round (Fig. 5).

When comparing the dose-related changes in male F-344 rats among 10, 20, and 30 day treatment groups, the protein droplet accumulation and alpha 2u-G concentration increased with longer exposure period. No other differences between the kidneys of control male F-344 rats and control or treated female F-344 or male NBR rats and those of treated male F-344 rats were demonstrated by light microscopy.

PCNA immunostaining easily revealed S phase cells characterized by unequivocal dense nuclear immunoreactivity (Fig. 3). Only S phase cells in P₂ segment of renal proximal tubules were counted and the percentage of cells in S phase (Labeling Index: LI) of each group is summarized in Table 2. Male F-344 rats receiving 35.5 mg/kg (P<0.001)

or 71 mg/kg ($P < 0.05$) showed significant increases in PCNA LI at 10 days. Rats receiving 35.5 mg/kg for 20 days showed slightly decreased PCNA LI compared to controls. Significantly ($P < 0.001$) increased PCNA LI was observed in rats receiving 35.5 mg/kg for 30 days (Fig. 4).

DISCUSSION

Renal toxicity has been reported with the nitroaromatic compound nitrotoluene in male rats (Dunnick et al., 1994). They observed an increased accumulation of hyaline droplets within the cytoplasm and lumen of the renal tubules associated with an increased renal concentration of alpha 2u-G. The result from present study showed that exposure to TNB in male rats produced dose-related increases in hyaline droplet formation in the renal proximal convoluted tubule epithelium. There were dilated tubules with intratubular protein and necrosis of tubular cells. These observations have been reported following treatment with chemicals that cause hyaline droplet nephropathy (Charbonneau et al., 1989 ; Dietrich and Swenberg, 1990 ; Kanerva et al., 1987a, 1987b, 1987c ; Kurata et al., 1994 ; Lehman-McKeeman et al., 1989, 1991 ; Lock et al., 1987 ; NTP, 1986 ; Short et al., 1986, 1987, 1989a, 1989b ; Stone et al., 1987a, 1987b ; Takahashi et al., 1993 ; Ward et al., 1993).

Male NBR rats and all strains of female rats do not synthesize alpha 2u-G in the liver (Chatterjee et al., 1989). No hyaline droplets were detectable in female F-344 and male NBR rats at any doses and these results are comparable to those found in other

studies of alpha 2u-G inducers (Alden, 1986 ; Short et al., 1989a ; Stone et al., 1987b ; Webb et al., 1990). The lack of alpha 2u-G in kidneys of female F-344 and male NBR rats suggests the pivotal role of alpha 2u-G in the pathogenesis of hyaline droplet nephropathy induced by TNB.

Borghoff et al. (1992) reported that kidney/body weight ratios were not changed in rats exposed to hyaline droplet inducing agents, such as unleaded gasoline and 2,2,4-trimethylpentane. However, dose-respondered increases in kidney/body weight ratios were observed in all rats treated with TNB and these results are comparable to those reported following exposure to decalin, d-limonene, and TNB in male F-344 rats (Kanerva et al., 1987b ; Qualls, 1993). Kurata et al. (1994) observed dose-related increases in kidney/body weight ratios in male rats, but not in female rats, exposed to sodium barbital and diethylacetylurea. The mechanism of increased kidney/body weight ratio is unclear, but it is possibly due to the metabolism of TNB. It appears that it is not solely related to alpha 2u-G formation since similar changes were seen in female F-344 and male NBR rats that did not develop alpha 2u-G nephropathy.

A variety of chemicals bind reversibly to alpha 2u-G, which appears to reduce the hydrolysis of the protein in proximal tubule epithelium lysosomes. Viau et al. (1986) have demonstrated that alpha 2u-G inducing chemicals do not affect the rate of hepatic synthesis of alpha 2u-G and protein resorptive capacity of renal proximal tubule cells. This study supports the hypothesis that decreased hydrolysis of alpha 2u-G-chemical complex is the major factor affecting renal accumulation of protein droplets. The increased resistance to hydrolysis could result in exacerbation of hyaline droplet accumulation in P₂

segments of the proximal tubules and cytotoxicity followed by compensatory proliferative response in proximal tubules (Short et al., 1987, 1989a ; Stone et al., 1987b ; Swenberg et al., 1989 ; Webb et al 1989). It has been assumed that sustained proliferation of renal tubule cells is associated with incidence of renal tubular neoplasms in alpha 2u-G nephropathy (Dietrich and Swenberg, 1991b ; Short, 1993 ; Short et al., 1987). It is believed that at least 6 months of exposure to hyaline droplet inducing agents, such as unleaded gasoline or d-limonene, with resulting sustained cell replication leads to the development of renal tubular neoplasms (Short, 1993). Significant increases in proliferating cells (S phase) in P₂ segments of proximal tubules were observed in rats treated with TNB for 30 days and these results were comparable to those reported following exposure to hyaline droplet-inducing chemicals, such as unleaded gasoline, sodium barbital, and diethylacetylurea (Loury et al., 1987 ; Kurata et al., 1994). This study also revealed the changes in cell proliferation among 10, 20, or 30 day-dose groups. These changes have not been reported in any other studies, and the mechanism related to this result is not fully understood at this point. Although chronic renal toxicity evaluation of TNB was not performed in this study, it is hypothesized that TNB would contribute to the effective promotion of renal tumors in alpha 2u-G nephropathy based on other investigators' studies with other alpha 2u-G inducing chemicals (Dietrich and Swenberg, 1991b ; Short, 1989b). Further study is needed to confirm this hypothesis.

It was necessary to identify the nature of accumulating proteins in rat kidneys since abnormal accumulation of renal hyaline droplets which is not associated with alpha 2u-G has been observed in several disease processes. The renal injury including hyaline droplet

accumulation secondary to histiocytic sarcoma in male and female rats and to multiple myeloma in humans have been identified as lysozyme and light-chain immunoglobulins, respectively (Hard and Snowden, 1991 ; Pirani et al., 1983). Excess amounts of lysozyme have been detected in the nephropathy of monocytic and myelomonocytic leukemia in humans (Muggia et al., 1969 ; Pruzanski and Platts, 1970). Immunohistochemistry demonstrated the increase in renal alpha 2u-G accumulation in treated male rats. This indicates that alpha 2u-G is a primary constituent of the hyaline droplets induced by TNB.

It has been known that several proteins isolated from serum and urine of various species including humans share extensive amino acid sequence homology with alpha 2u-G (Pevsner et al., 1988 ; Snyder et al., 1988). It is unlikely that humans develop hyaline droplet nephropathy and renal cancer following treatment with alpha 2u-G inducing agents (Borghoff and Lagarde, 1993 ; Hard and Whysner, 1994). Thus we can assume that despite the presence of TNB as an environmental contaminants, humans are unlikely develop hyaline droplet nephropathy induced by TNB.

In conclusion, the current study confirms that alpha 2u-G is important for hyaline droplet accumulation in male F-344 rats after administration of TNB. TNB induced dose-related exacerbation of hyaline droplet and subsequent renal tubular cell proliferation. Further investigation is required to elucidate if TNB-induced alpha 2u-G nephropathy in rats causes an increased incidence of renal tumors after chronic exposure. The cause of the increased kidney/body weight ratio that was seen in all groups exposed to TNB even in the absence of alpha 2u-G needs to be determined.

REFERENCES

- Alden, C.L. (1986) A review of unique male rat hydrocarbon nephropathy. *Toxicol. Pathol.* 14, 109-111.
- Borghoff, S.J., and Lagarde, W.H. (1993) Assessment of binding of 2,4,4-trimethyl-2-pentanol to low-molecular-weight proteins isolated from kidneys of male rats and humans. *Toxicol. Appl. Pharmacol.* 119, 228-235.
- Borghoff, S.J., Youtsey, N.L., and Swenberg, J.A. (1992) A comparison of European high test gasoline and PS-6 unleaded gasoline in their abilities to induce α 2u-globulin nephropathy and renal cell proliferation. *Toxicol. Lett.* 63, 21-33.
- Burnett, V.L., Short, B.G., and Swenberg, J.A. (1989) Localization of α 2u-globulin within protein droplets of male rat kidney: Immunohistochemistry using perfusion-fixed, GMA-embedded tissue sections. *J. Histochem. Cytochem.* 37, 813-818.
- Cason, J.E. (1950) A rapid one-step Mallory-Heidenhain stain for connective tissue. *Stain Tech.* 25, 225-226.
- Charbonneau, M., Strasser, J., Jr., Lock, E.A., Turner, M.J., and Swenberg, J.A. (1989) Involvement of reversible binding to α 2u-globulin in 1,4-dichlorobenzene-induced nephrotoxicity. *Toxicol. Appl. Pharmacol.* 99, 122-132.
- Chatterjee, B., Demyan, W.F., Song, C.S., Gara, B.D., and Roy, A.K. (1989) Loss of androgenic induction of α 2u-globulin gene family in the liver of NIH black rats. *Endocrinology* 125, 1385-1388.
- Dietrich, D.R., and Swenberg, J.A. (1991a) NCI-Black-Reiter (NBR) male rats fail to develop renal disease following exposure to agents that induce α -2u-globulin (α 2u) nephropathy. *Fundam. Appl. Toxicol.* 16, 749-762.
- Dietrich, D.R., and Swenberg, J.A. (1991b) The presence of α 2u-globulin is necessary for d-limonene promotion of male rat kidney tumors. *Cancer Res.* 51, 3512-3521.
- Dietrich, D.R., and Swenberg, J.A. (1990) Lindane induces nephropathy and renal accumulation of α 2u-globulin in male but not in female Fischer 344 rats or male NBR rats. *Toxicol. Lett.* 53, 179-181.
- Dunnick, J.K., Elwell, M.R., and Bucher, J.R. (1994) Comparative toxicities of o-, m-, and p-nitrotoluene in 13-week feed studies in F344 rats and B6C3F1 mice. *Fundam. Appl. Toxicol.* 22, 411-421.

Fitzgerald, G.B., De Guillion, N., Desai, L.S., and Reddu, G. (1992) Acute toxicity evaluation of 1,3,5-trinitrobenzene. *J. Am. Coll. Toxicol. Part B. Acute Toxicity Data.* 3, 169-170.

Foley, J., Ton, T., Maronpot, R., Butterworth, B., and Goldsworthy, T.L. (1993) Comparison of proliferating cell nuclear antigen to tritiated thymidine as a marker of proliferating hepatocytes in rats. *Environ. Health Perspect.* 101, 199-206.

Greenwell, A, Foley, J.F., and Maronpot, R.R. (1991) An enhancement method for immunohistochemical staining of proliferating cell nuclear antigen in archival rodent tissues. *Cancer Lett.* 59, 251-256.

Greenwell, A, Foley, J.F., and Maronpot, R.R. (1993) Detecting proliferating cell nuclear antigen in archival rodent tissues. *Environ. Health Perspect.* 101, 207-210.

Hard, G.C., and Snowden, R.T. (1991) Hyaline droplet accumulation in rodent kidney proximal tubules: An association with histiocytic sarcoma. *Toxicol. Pathol.* 19, 88-97.

Hard, G.C., and Whysner, J. (1994) Risk assessment of d-limonene: An example of male rat-specific renal tumorigens. *Crit. Rev. Toxicol.* 24, 231-254.

Kanerva, R.L., McCracken, M.S., Alden, C.L., and Stone, L.C. (1987a) Morphogenesis of decalin-induced renal alterations in the male rat. *Food Chem. Toxicol.* 25, 53-61.

Kanerva, R.L., Ridder, G.M., Lefever, F.R., and Alden, C.L. (1987b) Comparison of short-term renal effects due to oral administration of decalin or d-limonene in young adult male Fischer-344 rats. *Food Chem. Toxicol.* 25, 345-353.

Kanerva, R.L., Ridder, G.M., Stone, L.C., and Alden, C.L. (1987c) Characterization of spontaneous and decalin-induced hyaline droplets in kidneys of adult male rats. *Food Chem. Toxicol.* 25, 63-82.

Kurata, Y., Diwan, B.A., McKeeman, L.L., Rice, J.M., and Ward, J.M. (1994) Comparative hyaline droplet nephropathy in male F344/NCr rats induced by sodium barbital and diethylacetylurea, a breakdown product of sodium barbital. *Toxicol. Appl. Pharmacol.* 126, 224-232.

Lehman-McKeeman, L.D., Rodriguez, P.A., Caudill, D., Fey, M.L., Eddy, C.L., and Asquith, T.N. (1991) Hyaline droplet nephropathy resulting from exposure to 3,5,5-trimethylhexanoyloxybenzene sulfonate. *Toxicol. Appl. Pharmacol.* 107, 429-438.

Lehman-McKeeman, L.D., Rodriguez, P.A., Takigiku, R., Caudill, D., and Fey, M.L. (1989) d-Limonene-induced male rat-specific nephrotoxicity: Evaluation of the association between d-limonene and α_2 -globulin. *Toxicol. Appl. Pharmacol.* 99, 250-259.

Lock, E.A., Charbonneau, M., Strasser, J., Swenberg, J.A., and Bus, J.A. (1987) 2,2,4-Trimethylpentane-induced nephrotoxicity. II. The reversible binding of a TMP metabolite to a renal protein fraction containing α_2 -globulin. *Toxicol. Appl. Pharmacol.* 91, 182-192.

Loury, D.J., Smith-Oliver, T., and Butterworth, B.E. (1987) Assessment of unscheduled and replicative DNA synthesis in rat kidney cells exposed *in vitro* or *in vivo* to unleaded gasoline. *Toxicol. Appl. Pharmacol.* 87, 127-140.

MacFarland, H.N. (1984) Xenobiotic induced kidney lesions: hydrocarbons. The 90-day and 2-year gasoline studies. In: Mehlman, M.A., Hemstreet, G.P., Thorpe, J.J., and Weaver, N.K. (eds.), *Advances in Modern Environmental Toxicology*. Vol. VII. Renal Effects of Petroleum Hydrocarbons. Princeton Scientific Publishers, Inc., Princeton, New Jersey, pp. 51-56.

Muggia, F.M., Heinemann, H.O., Farhangi, M., and Osserman, E.F. (1969) Lysozymuria and renal tubular dysfunction in monocytic and myelomonocytic leukemia. *Am. J. Med.* 47, 351-366.

National Toxicology Program (1986) Carcinogenesis studies of isophorone in F344/N rats and B6C3F1 mice. National Toxicology Program Technical Report Series No. 291. National Toxicology Program, Research Triangle Park, NC.

Olson, M.J., Garg, B.D., Ramana Murty, C.V., and Roy, A.K. (1987) Accumulation of α_2 -globulin in the renal proximal tubules of male rats exposed to unleaded gasoline. *Toxicol. Appl. Pharmacol.* 90, 43-51.

Pevsner, J., Reed, R.R., Feinstein, P.G., and Snyder, S.H. (1988) Molecular cloning of odorant-binding protein: Member of a ligand carrier family. *Science* 241, 336-339.

Phillips, R.D., Moran, E.J., Dodd, D.E., Fowler, E.H., Kary, C.D., and O'Donoghue, J. (1987) A 14-week vapor inhalation toxicity study of methyl isobutyl ketone. *Fundam. Appl. Toxicol.* 9, 380-388.

Pirani, C.L., Silva, F.G., and Appel, G.B. (1983) Tubulo-interstitial disease in multiple myeloma and other nonrenal neoplasias. In: Cotran, R.S., Brenner, B.M., and Stein, J.H. (eds.), *Tubulo-Interstitial Nephropathies*. Churchill Livingstone, New York. pp. 287-334.

Pruzanski, W., and Platts, M.E. (1970) Serum and urinary proteins, lysozyme (muramidase), and renal dysfunction in mono- and myelomonocytic leukemia. *J. Clin. Invest.* 49, 1694-1708.

Qualls, C.W.Jr. (1993) Effect of 1,3,5-trinitrobenzene and 2,4,6-trinitrophenylmethylnitramine (tetryl) in Fischer 344 rats. U. S. Army Research Office, Draft Report, Contract Number DAAL03-91-C-0034.

Qualls, C.W.Jr., Reddy, G., and Chandra, A.M.S. (1995) Hematological and pathological effects of 1,3,5-trinitrobenzene (TNB) in F344 rats. *International Congress of Toxicology-VII*.

Reddy, T.V., Daniel, F.B., Robinson, M., Olson, G.R., Wiechman, B., and Reddy, G. (1993) Fourteen day toxicity evaluation of 1,3,5-trinitrobenzene (TNB). *Toxicologist* 13, 177.

Reddy, T.V., Torsella, J., Daniel, F.B., Olson, G.R., Wiechman, B., and Reddy, G. (1994) Subchronic toxicity evaluation of 1,3,5-trinitrobenzene (TNB) in Fischer 344 rats. *Toxicologist* 14, 117.

Ridder, G.M., Von Bargaen, E.C., Alden, C.L., and Parker, R.D. (1990) Increased hyaline droplet formation in male rats exposed to decalin is dependent on the presence of α 2u-globulin. *Fundam. Appl. Toxicol.* 15, 732-743.

Shi, S-R., Key, M.E., and Kalra, K.L. (1991) Antigen retrieval in formalin-fixed, paraffin-embedded tissues: An enhancement method for immunohistochemical staining based on microwave oven heating of tissue sections. *J. Histochem. Cytochem.* 39, 741-748.

Short, B.G. (1993) Cell proliferation and renal carcinogenesis. *Environ. Health Perspect.* 101(Suppl 5), 115-120.

Short, B.G., Burnett, V.L., and Swenberg, J.A. (1986) Histopathology and cell proliferation induced by 2,2,4-trimethylpentane in the male rat kidney. *Toxicol. Pathol.* 14, 194-203.

Short, B.G., Burnett, V.L., Cox, M.G., Bus, J.S., and Swenberg, J.A. (1987) Site-specific renal cytotoxicity and cell proliferation in male rats exposed to petroleum hydrocarbons. *Lab. Invest.* 57, 564-577.

Short, B.G., Burnett, V.L., and Swenberg, J.A. (1989a) Elevated proliferation of proximal tubule cells and localization of accumulated α 2u-globulin in F344 rats during chronic exposure to unleaded gasoline or 2,2,4-trimethylpentane. *Toxicol. Appl. Pharmacol.* 101, 414-431.

Short, B.G., Steinhagen, W.H., and Swenberg, J.A. (1989b) Promoting effects of unleaded gasoline and 2,2,4-trimethylpentane on the development of atypical cell foci and renal tubular cell tumors in rats exposed to N-ethyl-N-hydroxyethylnitrosamine. *Cancer Res.* 49, 6369-6378.

Snyder, S.H., Sklar, P.B., and Pevsner, J. (1988) Molecular mechanisms of olfaction. *J. Biol. Chem.* 263, 13971-13974.

Stone, L.C., Kanerva, R.L., Burns, J.L., and Alden, C.L. (1987a) Decalin-induced nephrotoxicity: Light and electron microscopic examination of the effects of oral dosing on the development of kidney lesions in the rat. *Food Chem. Toxicol.* 25, 43-52.

Stone, L.C., McCracken, M.S., Kanerva, R.N., and Alden, C.L. (1987b) Development of a short-term model of decalin inhalation nephrotoxicity in the male rat. *Food Chem. Toxicol.* 25, 35-41.

Swenberg, J.A., Short, B., Borghoff, S., Strasser, J., and Charbonneau, M. (1989) The comparative pathobiology of α 2u-globulin nephropathy. *Toxicol. Appl. Pharmacol.* 97, 35-46.

Takahashi, K., Lindamood, C., III, and Maronpot, R.R. (1993) Retrospective study of possible α -2u-globulin nephropathy and associated cell proliferation in male Fischer 344 rats dosed with t-butyl alcohol. *Environ. Health Perspect.* 101, 281-286.

U.S. EPA (1989) Health and Environmental Effects Profile for 1,3,5-trinitrobenzene. Environmental Criteria and Assessment Office, Office of Health and Environmental Assessment, Cincinnati, OH, ECAO-CIN-G071

Ward, J.M., Kurata, Y., Lehman-McKeeman, L.D., Diwan, B.A., and Rice, J.M. (1993) Comparative renal tubular hyaline droplet induction by sodium barbital and its decomposition product, diethylacetylurea. *Toxicologist* 13, 132.

Webb, D.R., Kanerva, R.L., Hysell, D.K., Alden, C.L., and Lehman-McKeeman, L.D. (1990) Assessment of the subchronic oral toxicity of d-limonene in dogs. *Food Chem. Toxicol.* 28, 669-675.

Webb, D.R., Ridder, G.M., and Alden, C.L. (1989) Acute and subchronic nephrotoxicity of d-limonene in Fischer 344 rats. *Food Chem. Toxicol.* 27, 639-649.

Table 1. Kidney Weights of Rats Exposed to TNB

Dose per day (mg/kg)	Species	Sex	Days dosed	Kidney wt* (% of body wt)
0	NBR	M	10	0.78 ± 0.02
35.5		M	10	0.84 ± 0.06
71		M	10	0.93 ± 0.09**
0	F-344	F	10	0.79 ± 0.03
35.5		F	10	0.86 ± 0.05**
71		F	10	0.94 ± 0.10**
0	F-344	M	10	0.75 ± 0.01
35.5		M	10	0.87 ± 0.02***
71		M	10	0.90 ± 0.06***
0	F-344	M	20	0.85 ± 0.09
35.5		M	20	0.86 ± 0.05
0	F-344	M	30	0.78 ± 0.02
35.5		M	30	0.89 ± 0.05**

* Mean ± SD.

** Significantly different from control within the same exposure period at P < 0.05.

*** Significantly different from control within the same exposure period at P < 0.01.

Table 2. Cell Proliferation in Renal Proximal Tubules of Male F-344 Rats Exposed to TNB.

Dose per day (mg/kg)	Days dosed	Percentage of cells in S-phase*
0	10	0.13 ± 0.01
35.5	10	0.26 ± 0.02**
71	10	0.18 ± 0.03***
0	20	0.17 ± 0.04
35.5	20	0.13 ± 0.03
0	30	0.19 ± 0.01
35.5	30	0.65 ± 0.08**

* Mean ± SD.

** Significantly different from control within the same exposure period at $P < 0.001$.

*** Significantly different from control within the same exposure period at $P < 0.05$.

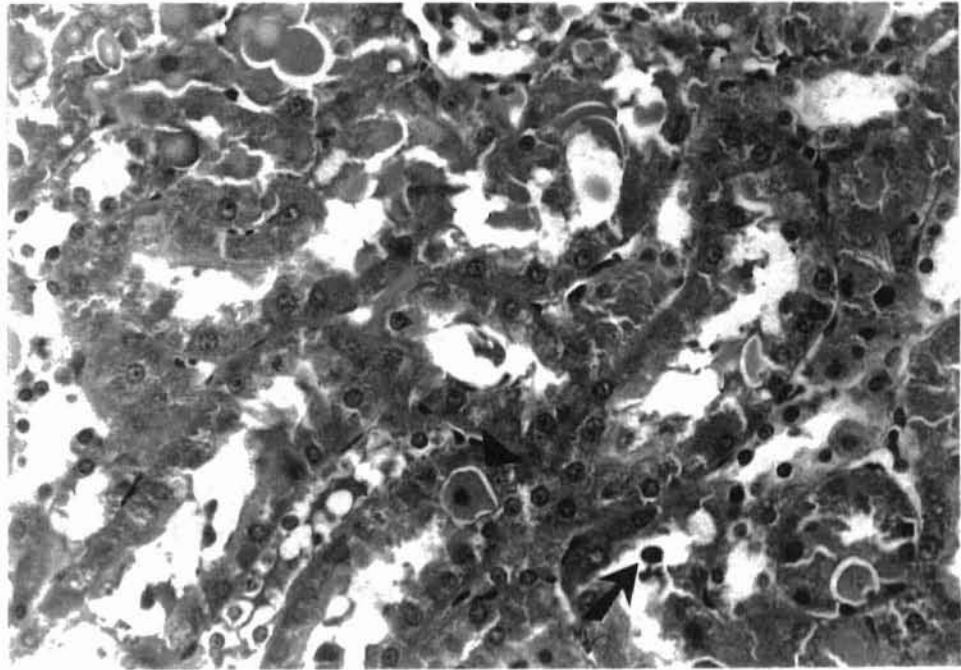


Figure 1. Renal cortex from a male F-344 rat exposed to 35.5 mg/kg of TNB for 30 days. Note the accumulation of hyaline droplets, exfoliation of renal tubule epithelial cells (arrow), and necrotic tubule epithelial cells (arrowhead). H&E, X383.

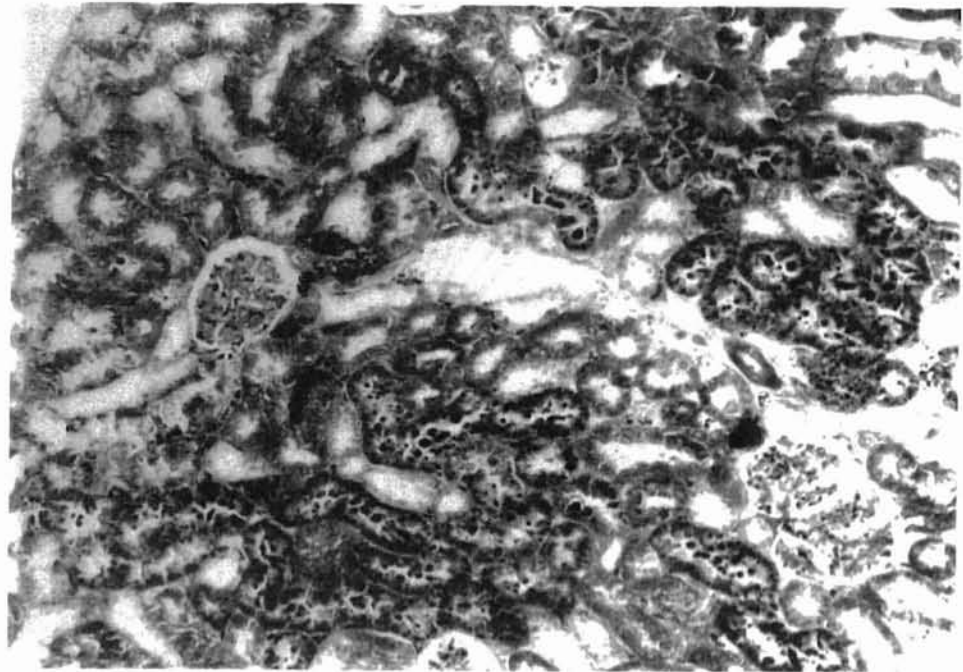


Figure 2. Mallory Heidenhain staining of renal cortex from a male F-344 rat exposed to 35.5 mg/kg of TNB for 10 days. Note the exacerbated globular to polyangular droplet accumulation in proximal convoluted tubules. X154.

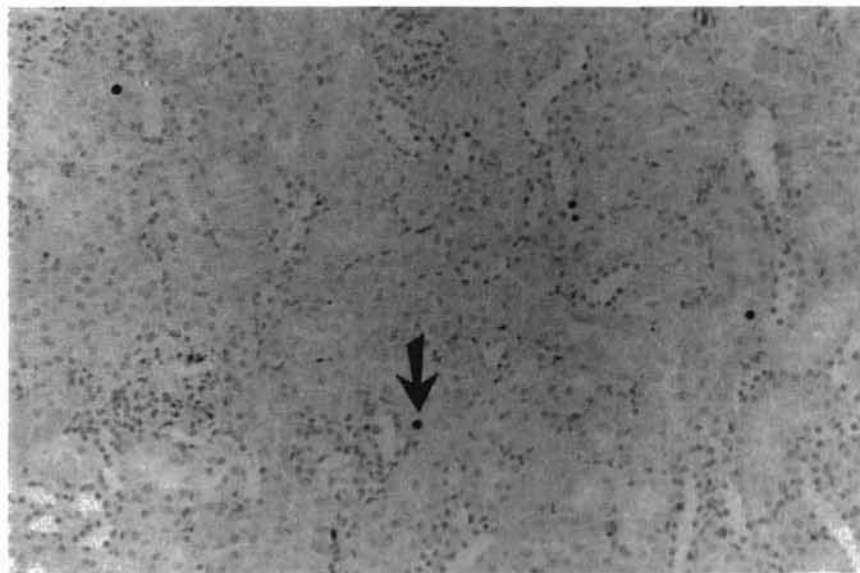


Figure 3. Immunohistochemical staining of renal cortex from a control male F-344 rat.

Several PCNA-positive nuclei (arrow) are present. X155.

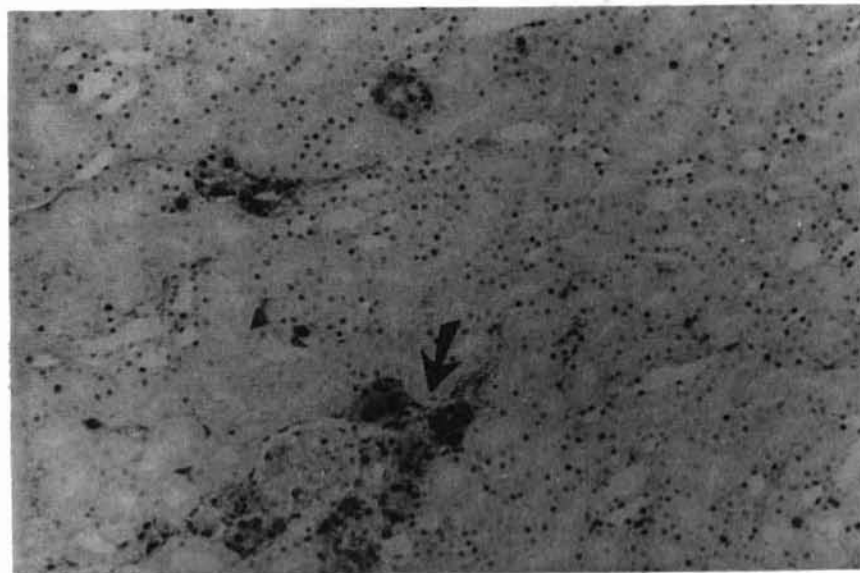


Figure 4. Immunohistochemical staining of renal cortex from a male F-344 rat exposed to 35.5 mg/kg of TNB for 30 days. Numerous PCNA-positive nuclei with several severely altered proximal tubules (arrow) are present (note increased numbers compared to the control in fig. 3). X132.

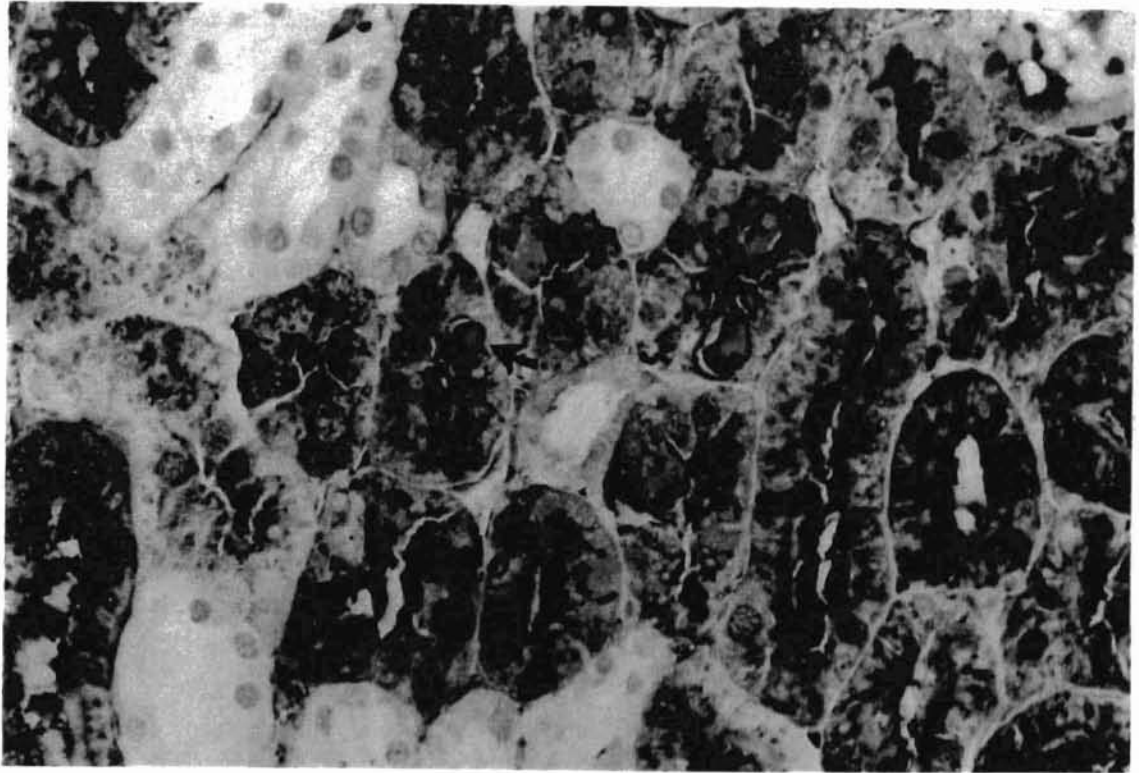


Figure 5. Immunohistochemical staining of alpha 2u-G from a control male F-344 rat.

Several small and round hyaline droplets (arrow) are present in proximal convoluted tubules. X589.

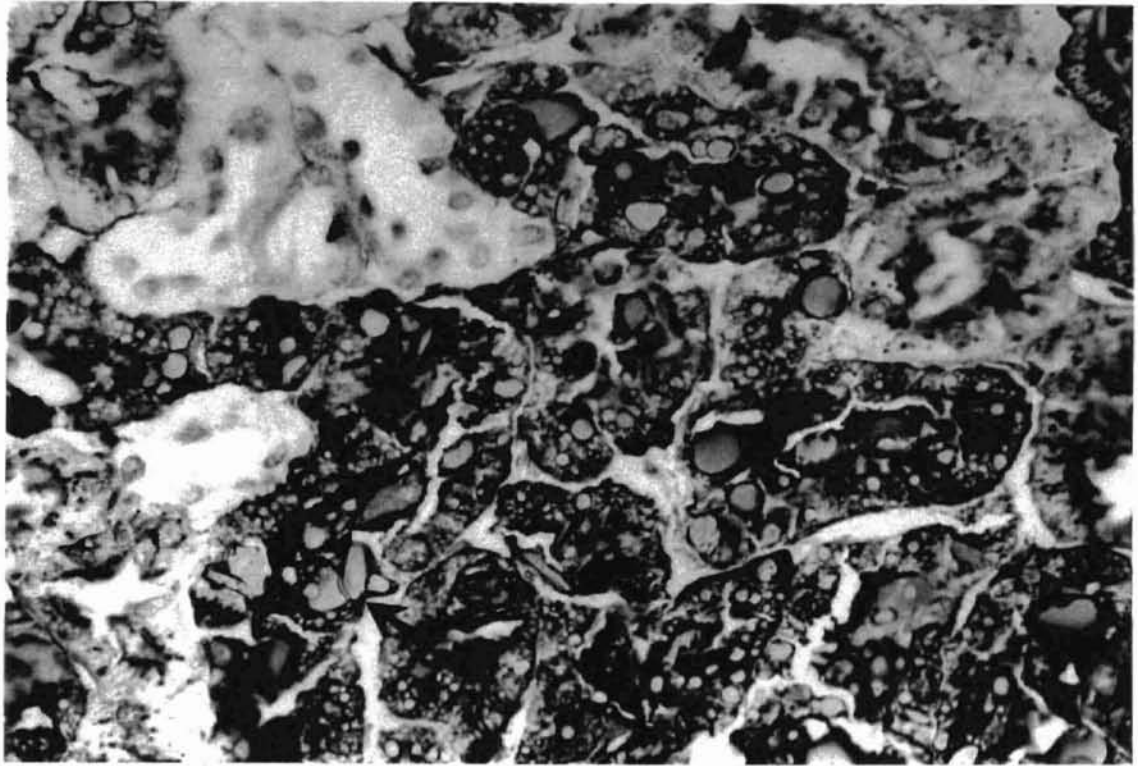


Figure 6. Immunohistochemical staining of alpha 2u-G from a male F-344 rat exposed to 35.5 mg/kg of TNB for 30 days. Note increased accumulation of pleomorphic polyangular to crystalline droplets (arrow) in proximal convoluted tubules. X581.

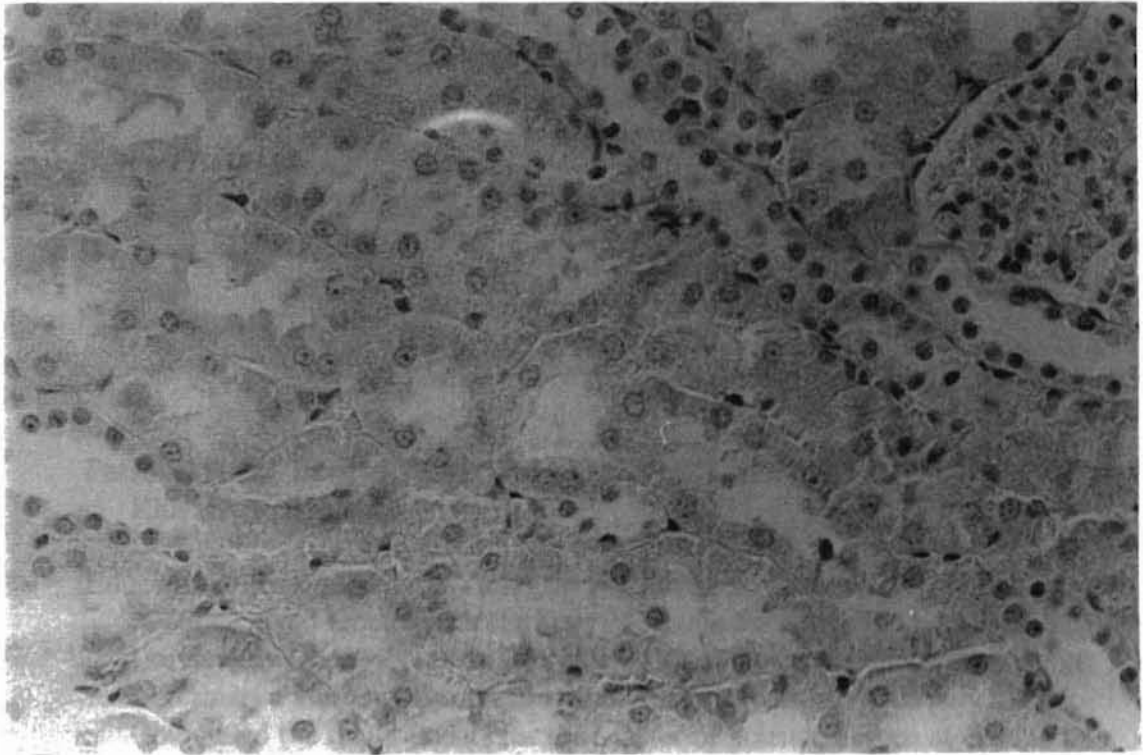


Figure 7. Immunohistochemical staining of alpha 2u-G of kidney from a male NBR rat exposed to 71 mg/kg of TNB for 10 days. Note the complete absence of alpha 2u-G-positive droplets. X467.

VITA

SOOCHONG KIM

Candidate for the Degree of

Master of Science

Thesis: 1,3,5-TRINITROBENZENE-INDUCED ALPHA 2U-GLOBULIN
NEPHROPATHY

Major Field: Veterinary Pathology

Biographical:

Personal Data: Born in Taegu, Korea, on April 1, 1967, the son of Youngchul Kim and Jungja Jang.

Education: Graduated from Youngsin High School, Taegu, Korea in February 1986; received Doctor of Veterinary Medicine from Kyungpook National University, Taegu, Korea in February 1992; received Graduate Training in Veterinary Pathology from Kyungpook National University in July 1993. Completed the requirements for the Master of Science degree at Oklahoma State University in May 1996.

Experience: Graduate research assistant, College of Veterinary Medicine, Kyungpook National University, March 1992 to July 1993; Graduate research assistant, Department of Veterinary Pathology, Oklahoma State University, August 1993 to present.

Professional Organizations: American Veterinary Medical Association, American Association of Veterinary Laboratory Diagnosticians, Inc., Charles Louis Davis D.V.M. Foundation.